

Medical Terminology - 2e

Medical Terminology - 2e

*ERNSTMEYER & CHRISTMAN - OPEN
RESOURCES FOR NURSING (OPEN RN)*

WISTECH OPEN



Medical Terminology - 2e Copyright © 2024 by Ernstmeyer & Christman - Open Resources for Nursing (Open RN) is licensed under a Creative Commons Attribution 4.0 International License, except where otherwise noted.

Contents

Introduction	1
Preface	2

Part I. Chapter 1 Foundational Concepts - Identifying Word Parts

1.1 Introduction to Identifying Word Parts	9
1.2 Components and Categories of Medical Terms	11
1.3 Common Prefixes	20
1.4 Common Word Roots and Combining Vowels	24
1.5 Common Suffixes	27
1.6 Foundational Concepts - Identifying Word Parts Learning Activities	31
1.7 Glossary	33

Part II. Chapter 2 Medical Language Related to the Whole Body

2.1 Medical Language Introduction	37
2.2 Levels of Organization	38
2.3 Body Cavities	43
2.4 Body Regions	46
2.5 Tissue Membranes	50

2.6 Anatomical View of the Body, Positions, Locations, and Directional Terms	54
2.7 Body Planes	59
2.8 Medical Language Related to the Whole Body Learning Activities	62
2.9 Glossary	64

Part III. Chapter 3 Integumentary System Terminology

3.1 Integumentary System Introduction	69
3.2 Word Components Related to the Integumentary System	71
3.3 Examples of Integumentary Terms Easily Defined By Their Word Components	75
3.4 Anatomy and Physiology of the Integumentary System	78
3.5 Diseases, Disorders, and Injuries of the Integumentary System	93
3.6 Medical Specialists and Procedures Related to the Integumentary System	122
3.7 Integumentary System Learning Activities	124
3.8 Glossary	127

Part IV. Chapter 4 Respiratory System Terminology

4.1 Respiratory System Introduction	139
4.2 Word Components Related to the Respiratory System	141
4.3 Examples of Respiratory Terms Easily Defined By Their Word Components	145
4.4 Anatomy of the Respiratory System	147
4.5 Physiology of the Respiratory System	161
4.6 Diseases and Disorders of the Respiratory System	170

4.7 Medical Specialists, Diagnostic Testing, and Procedures Related to the Respiratory System	193
4.8 Respiratory System Learning Activities	214
4.9 Glossary	217

Part V. Chapter 5 Urinary System Terminology

5.1 Urinary System Introduction	229
5.2 Word Components Related to the Urinary System	231
5.3 Examples of Urinary Terms Easily Defined By Their Word Components	234
5.4 Anatomy of the Urinary System	236
5.5 Physiology of the Urinary System	247
5.6 Diseases and Disorders of the Urinary System	258
5.7 Medical Specialists, Diagnostic Testing, and Procedures Related to the Urinary System	271
5.8 Urinary System Learning Activities	284
5.9 Glossary	286

Part VI. Chapter 6 Male Reproductive System Terminology

6.1 Male Reproductive System Introduction	295
6.2 Word Components Related to the Male Reproductive System	297
6.3 Examples of Male Reproductive Terms Easily Defined By Their Word Components	300
6.4 Anatomy of the Male Reproductive System	303
6.5 Physiology of the Male Reproductive System	310
6.6 Diseases and Disorders of the Male Reproductive System	314

6.7 Medical Specialists, Diagnostic Testing, and Procedures Related to the Male Reproductive System	338
6.8 Male Reproductive System Learning Activities	343
6.9 Glossary	345

Part VII. Chapter 7 Female Reproductive System Terminology

7.1 Female Reproductive System Introduction	355
7.2 Word Components Related to the Female Reproductive System	357
7.3 Examples of Female Reproductive System Terms Easily Defined By Their Word Components	360
7.4 Anatomy of the Female Reproductive System	363
7.5 Physiology of the Female Reproductive System	371
7.6 Diseases and Disorders of the Female Reproductive System	377
7.7 Medical Specialists, Diagnostic Testing, and Procedures Related to the Female Reproductive System	402
7.8 Female Reproductive System Learning Activities	410
7.9 Glossary	413

Part VIII. Chapter 8 Obstetrics Terminology

8.1 Obstetrics Introduction	425
8.2 Word Components Related to Obstetrics	427
8.3 Examples of Obstetrical Terms Easily Defined By Their Word Components	430
8.4 Fertilization, Pregnancy, Labor, Delivery, Newborn Care, and Postpartum Care	432
8.5 Complications of Pregnancy and Delivery	452

8.6 Medical Specialists, Diagnostic Testing, and Procedures Related to Pregnancy	458
8.7 Obstetrics Learning Activities	464
8.8 Glossary	465

Part IX. Chapter 9 Cardiovascular System Terminology

9.1 Cardiovascular System Introduction	475
9.2 Word Components Related to the Cardiovascular System	477
9.3 Examples of Cardiovascular Terms Easily Defined By Their Word Components	480
9.4 Anatomy of the Cardiovascular System	483
9.5 Physiology of the Cardiovascular System	491
9.6 Diseases and Disorders of the Cardiovascular System	498
9.7 Medical Specialists, Diagnostic Testing, and Procedures Related to the Cardiovascular System	520
9.8 Cardiovascular Learning Activities	539
9.9 Glossary	541

Part X. Chapter 10 Blood Terminology

10.1 Blood Introduction	551
10.2 Word Components Related to Blood	553
10.3 Examples of Blood Terms Easily Defined By Their Word Components	557
10.4 Anatomy of the Hematology System	560
10.5 Physiology of the Hematology System	574
10.6 Diseases and Disorders of the Blood	578
10.7 Medical Specialists, Diagnostic Testing, and Procedures Related to Blood	588

10.8 Blood Learning Activities	598
10.9 Glossary	600

Part XI. Chapter 11 Lymphatic & Immune Systems Terminology

11.1 Lymphatic & Immune Systems Introduction	609
11.2 Word Components Related to the Lymphatic and Immune Systems	611
11.3 Examples of Lymphatic and Immune Systems Terms Easily Defined By Their Word Parts	613
11.4 Anatomy of the Lymphatic and Immune Systems	616
11.5 Physiology of the Lymphatic and Immune Systems	623
11.6 Diseases and Disorders of the Lymphatic and Immune System	636
11.7 Medical Specialists, Diagnostic Testing, and Procedures Related to the Lymphatic and Immune Systems	648
11.8 Lymphatic and Immune System Learning Activities	653
11.9 Glossary	656

Part XII. Chapter 12 Digestive System Terminology

12.1 Digestive System Introduction	665
12.2 Word Components Related to the Digestive System	667
12.3 Examples of Digestive Terms Easily Defined By Their Word Components	671
12.4 Anatomy of the Digestive System	674
12.5 Physiology of the Digestive System	695
12.6 Diseases and Disorders of the Digestive System	704
12.7 Medical Specialists, Diagnostic Testing, and Procedures Related to the Digestive System	722

12.8 Digestive System Learning Activities	731
12.9 Glossary	734

Part XIII. Chapter 13 Skeletal System Terminology

13.1 Introduction to the Skeletal System	747
13.2 Word Components Related to the Skeletal System	749
13.3 Examples of Skeletal Terms Easily Defined By Their Word Components	753
13.4 Anatomy of the Skeletal System	756
13.5 Physiology of the Skeletal System	789
13.6 Diseases and Disorders of the Skeletal System	791
13.7 Medical Specialists, Diagnostic Testing, and Procedures Related to the Skeletal System	804
13.8 Skeletal System Learning Activities	817
13.9 Glossary	819

Part XIV. Chapter 14 Muscular System Terminology

14.1 Muscular System Introduction	831
14.2 Word Components Related To The Muscular System	833
14.3 Examples of Muscular Terms Easily Defined By Their Word Components	836
14.4 Anatomy of the Muscular System	839
14.5 Physiology of the Muscular System	847
14.6 Diseases and Disorders of the Muscular System	854
14.7 Medical Specialists, Diagnostic Testing, and Procedures Related to Muscular System	870
14.8 Muscular Learning Activities	881

14.9 Glossary	882
---------------	-----

Part XV. Chapter 15 Sensory System Terminology

15.1 Sensory System Introduction	891
15.2 Word Components Related to the Sensory Systems	893
15.3 Examples of Sensory Terms Easily Defined By Their Word Components	897
15.4 Anatomy and Physiology of the Sensory Systems	900
15.5 Diseases and Disorders Related to the Sensory Systems	912
15.6 Medical Specialties, Diagnostic Testing, and Procedures Related to the Sensory System	930
15.7 Sensory System Learning Activities	937
15.8 Glossary	940

Part XVI. Chapter 16 Nervous System Terminology

16.1 Nervous System Introduction	947
16.2 Word Components Related to the Nervous System	949
16.3 Examples of Nervous System Terms Easily Defined By Their Word Components	953
16.4 Anatomy of the Nervous System	955
16.5 Physiology of the Nervous System	968
16.6 Diseases and Disorders of the Nervous System	974
16.7 Medical Specialists, Diagnostic Testing, and Procedures Related to the Nervous System	990
16.8 Nervous System Learning Activities	997
16.9 Glossary	1000

Part XVII. Chapter 17 Endocrine System Terminology

17.1 Endocrine System Introduction	1009
17.2 Word Components Related to the Endocrine System	1011
17.3 Examples of Endocrine Terms Easily Defined By Their Word Components	1014
17.4 Anatomy of the Endocrine System	1017
17.5 Physiology of the Endocrine System	1025
17.6 Diseases and Disorders of the Endocrine System	1027
17.7 Medical Specialists, Diagnostic Testing, and Procedures Related to the Endocrine System	1042
17.8 Endocrine Learning Activities	1046
17.9 Glossary	1048
Appendix: Instructor Resource - How to Remix H5P Activities For Your Courses	1057

Introduction

This textbook is an open educational resource (OER) with CC-BY 4.0 licensing. It is aligned with the course competencies of Wisconsin Technical College System's Medical Terminology course (10-501-101). The Medical Terminology course focuses on learning the components of medical terms, including prefixes, suffixes, and word roots, and also introduces students to diagnostic, therapeutic, surgical, and symptomatic terminology of all body systems.

A workgroup of WTCS faculty, led by Chippewa Valley Technical College, created this second edition based on peer reviewer feedback received for the first edition of the WTCS *Medical Terminology* OER textbook. Here is a [summary of revisions and additions](#) made in the second edition.

This online book is free and can also be downloaded in multiple formats for offline use and for printing. The online version is required to complete interactive learning activities included in each chapter. The following video provides a quick overview of how to navigate the online version.



One or more interactive elements has been excluded from this version of the text. You can view them online here: <https://wtcs.pressbooks.pub/medterm/?p=4#oembed-1>

[i04c](#)

Preface

About This Book

Editors

This book was edited by:

Kimberly Ernstmeyer, MSN, RN, CNE, CHSE, APNP-BC
Dr. Elizabeth Christman, DNP, RN, CNE

Graphics Editor

Nic Ashman, MLIS, Librarian, Chippewa Valley Technical College

Developing Authors

Developing authors created new content and/or learning activities for this second edition:

Kim Ernstmeyer, MSN, RN, CNE, CHSE, APNP-BC
Jen Feltes, BA, RHIT, Chippewa Valley Technical College
Dr. Elaine Strachota, PhD, MS, OTR, Milwaukee Area Technical College
(emeritus)

Contributors

Several individuals contributed to the development of this second edition OER textbook:

Julia Brown, MS Biology & MS Education, Chippewa Valley Technical College
Jane Flesher, MST, Copy Editor, Chippewa Valley Technical College (emeritus)
Ashley McHose, MLIS Librarian, Lakeshore Technical College
Vince Mussehl, MLIS, Open RN Lead Librarian, Chippewa Valley Technical College

Krista Polomis, MSN, RN, CNE, Nicolet College

Samantha Rubenzer, Instructional Designer, Chippewa Valley Technical College

Dominic Slauson, Open RN Instructional Technologist

Laurie Zielinski, BA, NCLEC, ABOC, Milwaukee Area Technical College

We would like to acknowledge the work of the original workgroup members who created the first edition of the OER textbook and associated learning activities:

- Coleen Allee, Lakeshore Technical College
- Hilary Barker, Wisconsin Technical College System
- Heidi Belitz, Lakeshore Technical College
- Kelly Carpenter, Lakeshore Technical College
- Cindy Domaika, Nicolet College
- Traci Gotz, Gateway Technical College
- Stacey Grimm, Lakeshore Technical College
- Ashley McHose, Lakeshore Technical College
- Mike Randolph, Gateway Technical College
- Ellen Range, Western Technical College
- Elaine Strachota, Milwaukee Area Technical College
- Laurie Zielinski, Milwaukee Area Technical College

Peer Reviewers

We would like to acknowledge the contributions of the peer reviewers of this second edition:

- Dr. Kimberly A. Amos, Ph.D., M.S. (N), R.N., C.N.E. McDowell Technical Community College
- Smita Baman, MSN, RN, Excelsior University
- Ginger Becker, RN, BSN, Frontier Nursing University
- Nancy Bonard, MSN, RN, Ascend Learning
- Dr. Joan Buckley, Ph.D., RN, Nassau Community College
- Dr. Karen Colombo, DNP, RN-C, APRN, CCRN, AHCNS, FNP, NEA BC,

CUUNY Kingsborough Community College

- Jessica Dwork, MSN, RN, Maricopa Community College
- Jen Feltes, BA, RHIT, Chippewa Valley Technical College
- Stacey Grimm, BSN, RN, Lakeshore Technical College
- Dr. Saran Heron, DNP, MSN-Ed, BSN, RN, Nassau Community College
- Lisa Huehns, M.A. Ed., AHI/RMA (AMT), Lakeshore Technical College
- Dr. Jamie Murphy, PhD, RN, State University of New York at Delhi
- Dr. Grace Paul, DNP, RN, CNE, Glendale Community College
- Krista Polomis, MSN, RN, Nicolet College
- Cassandra Porter MSN, RN, Lake Land College
- Dr. Elaine Strachota, PhD, MS., OTR, Milwaukee Area Technical College
- Laurie Zielinski, BA, ABOC, NCLC, Milwaukee Area Technical College

Customization/Terms of Use

This textbook is licensed under a Creative Commons Attribution CC BY 4.0 International license unless otherwise indicated, which means that you are free to:

- SHARE – copy and redistribute the material in any medium or format
- ADAPT – remix, transform, and build upon the material for any purpose, even commercially

Licensing Terms

The licensor cannot revoke these freedoms as long as you follow the license terms.

- Attribution: You must give appropriate credit, provide a link to the license, and indicate if any changes were made. You may do so in any reasonable manner, but not in any way that suggests the licensor endorses you or your use.

- No Additional Restrictions: You may not apply legal terms or technological measures that legally restrict others from doing anything the license permits.
- Notice: You do not have to comply with the license for elements of the material in the public domain or where your use is permitted by an applicable exception or limitation.
- No Warranties Are Given: The license may not give you all of the permissions necessary for your intended use. For example, other rights such as publicity, privacy, or moral rights may limit how you use the material.

Attribution

Content for this textbook was remixed from the following open educational resources and information in the public domain:

- [Medical Terminology](#) by Stacey Grimm, Coleen Allee, Elaine Strachota, Laurie Zielinski, Traci Gotz, Micheal Randolph, and Heidi Belitz is licensed under [CC BY 4.0](#)
- [Building a Medical Terminology Foundation](#) by Kimberlee Carter and Marie Rutherford, published by eCampus Ontario is licensed under [CC BY 4.0](#)
- [Anatomy and Physiology](#) by [OpenStax](#) is licensed under [CC BY 4.0](#). Access for free at <https://openstax.org/books/anatomy-and-physiology/pages/1-introduction>
- [Nursing Skills](#) by [Open RN](#) is licensed under [CC BY 4.0](#)
- [Nursing Fundamentals](#) by [Open RN](#) is licensed under [CC BY 4.0](#)
- [Nursing Pharmacology 2e](#) by [Open RN](#) is licensed under [CC BY 4.0](#)
- [Lifespan Development](#) by Julie Lazzara is licensed under [CC BY 4.0](#)
- National Library of Medicine. [Understanding Medical Words Tutorial](#)
- Medline Plus. <https://medlineplus.gov/medwords/medicalwords.html>
- Medline Plus. *Medical Encyclopedia*. <https://medlineplus.gov/encyclopedia.html>
- National Cancer Institute. [SEER Modules: Anatomical Terminology](#)

Suggested Attribution Statement

Content that is not taken from OER sources or the public domain should include the following attribution statement:

Ernstmeyer, K., & Christman, E. (Eds.). (2024). *Open RN [Medical Terminology 2e](#)* by [Chippewa Valley Technical College](#) licensed under [CC BY 4.0](#).

Funding

This workforce product was funded by a grant awarded by the U.S. Department of Labor's Employment and Training Administration. The product was created by the grantee and does not necessarily reflect the official position of the U.S. Department of Labor. The U.S. Department of Labor makes no guarantees, warranties, or assurances of any kind, express or implied, with respect to such information, including any information on linked sites and including, but not limited to, accuracy of information or its completeness, timeliness, usefulness, adequacy, continued availability, or ownership. This product is copyrighted by the institution that created it.

This book was developed using Open RN workflows, processes, and standards. The Open RN project was funded by a \$2.5 million grant from the Department of Education and published several nursing OER textbooks that have been widely adopted across North America. More information about the Open RN project can be found at cvtc.edu/OpenRN.

Report Adoptions or Corrections

Please let us know if you have adopted this book for a course or would like to suggest a correction using this [form](#). We appreciate your feedback to help improve and advocate for WisTech Open and Open RN resources!

PART I

CHAPTER 1 FOUNDATIONAL CONCEPTS - IDENTIFYING WORD PARTS

1.1 Introduction to Identifying Word Parts

Learning Objectives

- Apply the basic rules for analyzing and building medical terms
- Identify four components of medical terms
- Define common prefixes, word roots, and suffixes
- Pronounce medical terms
- Apply the rules of medical language
- Identify meanings of key word components

Have you ever visited a health care professional and heard long, unfamiliar medical terms used to describe your condition? Many people feel as if medical professionals use a different language when talking about medical issues that can be difficult to understand. A medical term describes a word or condition that under normal circumstances would take several words to describe. Medical terminology facilitates effective and efficient communication by health care professionals by conveying a great quantity of information with precision in the fewest number of words.

This chapter will describe the components of medical terms, including common prefixes, word roots, and suffixes. By understanding the meaning of common components included in a medical term, you can easily construct the meaning of the term based on the meanings of its components. Specific

medical terms related to body systems will be further discussed in the remaining chapters of this book.

1.2 Components and Categories of Medical Terms

WORD COMPONENTS

Medical terms can be defined by breaking down the term into word components and defining each component. These word components include prefixes, word roots, and suffixes.

- The **prefix (P)** appears at the beginning of the medical term and adds meaning to the word root.
- The **word root (WR)** is the core of many medical terms and refers to the body part or body system to which the term is referring.
- The **suffix (S)** is at the end of the medical term and usually indicates a procedure, condition, or disease. When defining a medical term, start the definition with the suffix. For example, consider the common medical condition *tonsillitis*. The word root “tonsil” refers to the tonsils, an anatomical part of the body found in the throat. The suffix “-itis” refers to inflammation. Therefore, the definition of the medical term *tonsillitis* is “inflammation of the tonsils.”
- **Combining vowel (CV)** is typically the letter “o” that helps with pronunciation. A combining vowel can connect a word root and a suffix or two word roots. When a word root is combined with a combining vowel, the word part is referred to as a **combining form (CF)**. See examples of word components in Table 1.2a.

Table 1.2a. Components of Medical Terms

Component	Definition	Example
Word Root (WR)	Core of the word	hepat/itis hepat = liver
Prefix (P)	Attached to the beginning of the word root to alter its meaning	sub/hepatic sub- = below
Suffix (S)	Attached to the end of a word root to alter its meaning	hepat/ itis -itis = inflammation
Combining Vowel (CV)	Typically, an “o” is used to assist with pronunciation	hepat/ o /megaly
Combining Form (CF)	Word root with a combining vowel	hepat/o

By defining the meaning of each component of a medical term, you can easily construct the full meaning of the term based on the meanings of its components. See an example of defining a medical term by its components in the following box.

Defining a Medical Term by its Components

The medical term ***arthropathy*** contains the following word components:

- The word root “**arthr-**” that refers to a joint
- The combining vowel “**o**” that creates the combining form arthro-
- The suffix “**-pathy**” that refers to a disease

When putting the meaning of these components together, the medical term *arthropathy* means “**disease of a joint.**”

Definitions of common prefixes, word roots, suffixes, and combining vowels will be discussed in greater detail in the following sections of this chapter.

Check your knowledge of the components of medical terms on the right by dragging them to their corresponding definitions on the left.



An interactive H5P element has been excluded from this version of the text. You can view it online here:

<https://wtcs.pressbooks.pub/medterm/?p=85#h5p-1>

TYPES OF MEDICAL TERMS

Medical terms can be divided into three categories of terms, based on the origin of their components:

1. Terms built from word components of Greek and Latin origin
2. Terms NOT built from word components of Greek and Latin origin
3. Terms that look like they are made from word parts but are not easily translated

Definitions of medical terms built from word components of Greek and Latin origin can be easily identified by analyzing the components, defining each component, and then building the meaning of the term based on the meaning of its components.

Medical terms NOT built from word components of Greek and Latin origin, or terms that are not easily translated, must be learned by memorizing and recalling the definitions. See Table 1.2b for examples of these categories of medical terms.

Table 1.2b. Types of Medical Terms

Type	Origin	Examples	Methods
Terms That Can Be Easily Built From Word Components	Word components of Greek and Latin origin that are combined to create literal translations	Hepatitis Arthropathy	Definitions are identified by analyzing the word components, defining the word components, and then building the meaning of a medical term based on the meaning of its components
Terms NOT Easily Built From Word Components	Eponyms (i.e., a disease or procedure named after someone who discovered it)	Parkinson's disease – a disease first described by a physician named James Parkinson	Definitions are learned by memorizing and recalling definitions
	Acronyms (i.e., an abbreviation formed from the initial letters of other words and pronounced as a word)	AIDS – an acronym that stands for the disease called acquired immunodeficiency syndrome	
	Modern language (i.e., terms created in a language currently used)	Post-traumatic stress disorder – a mental health diagnosis created by using the English language	

DEFINING MEDICAL TERMS BY BREAKING DOWN COMPONENTS

Defining medical terms built from word components is easily accomplished by analyzing the components of the term, defining each component, and then building the overall definition of the medical term.

For example, see Table 1.2c for instructions on how the definition of the

medical term “osteoarthropathy” can be identified by breaking down its components and defining them.

Table 1.2c. Technique for Defining Medical Terms Based on Their Components

Technique	Instructions	Steps
Analyze Components	1. Divide into word parts. 2. Label the word parts. 3. Underline and label each combining form.	1. oste/o/arthr/o/pathy 2. oste = WR/; o = CV/; arthr = WR/; o = CV/; pathy = S 3. <u>oste/o/arthr/o/pathy</u>
Define Components	1. Define each word part in the term.	1. oste = bone; arthr = joint; pathy = disease
Build Definition	1. Place word parts together to define the term. Begin by defining the suffix, and then move to the beginning of the term in the order they appear. 2. Add combining vowels to pronounce the term.	1. Disease of the bone and joint 2. oste/o/arthr/o/pathy

When breaking down medical terms into its components, place slashes between the components and a slash on each side of a combining vowel. Notice how the term is defined by beginning with the meaning of the suffix and then shifts to the beginning of the term with the meaning of the word parts in the order they appear. Additional examples of identifying definitions of medical terms by analyzing their components are provided in the following box.

Additional Examples of Identifying Definitions of Medical Terms by Analyzing Their Components

Example: Osteoarthritis

1. Analyze Components: **oste/o/arthr/itis**

2. Define Components:

oste is a word root (WR) that means “bone”

/o/ is a combining vowel (CV)

arthr is a word root (WR) that means “joint”

-itis is a suffix (S) that means “inflammation”

3. Build Definition: **Inflammation of bone and joint**

Example: Intravenous

1. Analyze Components: **intra/ven/ous**

2. Define Components:

intra- is a prefix (P) that means “within”

ven is a word root (WR) that means “vein”

-ous is a suffix (S) that means “pertaining to”

3. Build Definition: **Pertaining to within a vein**

LANGUAGE RULES

Language rules are a good place to start when building foundational knowledge of medical terminology. Many medical terms are built from word parts and can be translated literally. At first, literal translations sound awkward. However, after you build a medical vocabulary and become proficient at using it, the awkwardness will slip away. Suffixes will no longer be stated and will be assumed. For example, the definition of *intravenous* can be condensed from “pertaining to within a vein” to “within the vein.” It should be noted that as with all language rules there are always exceptions, often referred to as “rebels.”

By the end of this book, by using these simple rules and processes, you will easily learn hundreds of medical terms.

PRONUNCIATION

Pronouncing complex medical terms can be challenging. When learning how to pronounce medical terms, special marking above vowels indicates the proper pronunciation. When you see a macron (i.e., straight line) above the vowel, that means the vowel sound is long. A u-shaped symbol above a vowel indicates a short vowel sound. Additionally, capital letters indicate where to place the emphasis when pronouncing a word. See examples of pronunciation markings in the Table 1.2d. Try pronouncing each example out loud.

Table 1.2d. Pronunciation Guidelines

Guidelines	Example
Markings indicate the proper phonetic sounds.	doctor (dŏk-tŏr)
A macron (a line above the letter) indicates a long vowel sound. Examples: ā in “play” ē in “bee” ī in “wine” ō in “go” ū in “mule”	prorate (prō-rāt)
A u-shaped mark above the vowel indicates a short sound. Examples: ă in “mad” ĕ in “bet” ĭ in “tip” ŏ in “mop” ŭ in “cup”	medical (mĕd-ĭ-căl)
Primary emphasis of pronunciation is indicated by capital letters.	debride (di-BRĒD) dehydration (dĕ-hī-DRĀ-shŏn)

CATEGORIES OF MEDICAL TERMS

Medical terms can be classified into the following general categories of terms:

- **Anatomical:** Terms used to describe specific areas and movement of the body, as well as the relation of body parts to each other.
 - An example of an anatomical term is *medial*, which describes the middle or direction toward the middle of the body.
- **Disease and Disorder:** Terms that describe deviation from the normal

structural or functional state of an organism, generally associated with certain signs and symptoms.

- An example of a disease is *bronchopneumonia*, an infection of the bronchi in the lungs.
- **Diagnostic/Procedural:** Terms related to the process of identifying a disease, condition, or injury.
 - An example of a diagnostic term is *transrectal ultrasound*, an ultrasound procedure used to diagnose prostate cancer.
- **Therapeutic:** Terms regarding the treating or curing of diseases.
 - An example of a therapeutic term is *nebulizer*, which is a device that creates a mist used to deliver medication for respiratory treatment.

These categories will be used to discuss medical terms by body systems throughout the remaining chapters of the book.

1.3 Common Prefixes

The prefix appears at the beginning of a medical term and adds meaning to the root word, like adjectives add meaning to nouns in the English language.

Prefixes often indicate:

- **Number**, such as *bi-*, meaning “two”
- **Position**, such as *sub-*, meaning “under”
- **Direction**, such as *intra-*, meaning “within”
- **Time**, such as *brady-*, meaning “slow”
- **Negation**, such as *a-* and *an-*, meaning “without”

COMMON PREFIXES

Here is a list of commonly used prefixes. It is helpful to memorize these common prefixes as you build your knowledge of medical terminology:

- **a-, an-**: Absence of, without, not
- **ab-**: Away from, take away
- **ad-**: Towards, to, near
- **ambi-, ambo-**: Both
- **amphi-**: Double, both sides
- **ana-**: Up, apart
- **ante-**: Before, in front of, forward
- **anti-**: Opposing, against
- **ap-, apo-**: Separated, derived from
- **aut-, auto-**: Self, by yourself
- **bi-**: Double, two, twice, both
- **brachy-**: Short
- **brady-**: Slow

- **cata-**: Lower, down, against
- **circum-**: Around
- **co-, con-, com-**: Together, with
- **contra-**: Against, opposed to
- **de-**: Down, from
- **di-**: Twice, two
- **dia-**: Through, apart, across, between
- **dis-**: Apart from, free from
- **dys-**: Bad, painful, difficult
- **e-, ec-, ex-**: From, away from, out of
- **ect-, exo-, ecto-**: Outside, outer, on
- **em-, en-**: In
- **end-, endo-, ent-, ento-**: Within, inner
- **epi-, ep-**: Upon, over, on
- **eu-**: Normal
- **extra-, extro-**: Beyond, outside of, outward
- **hemi-, semi-**: Half, half of
- **hyper-**: Above, excessive, beyond
- **hyp-, hypo-**: Below, beneath, deficient
- **im-, in-**: Intro, in, within
- **infra-**: Below, beneath
- **inter-**: Between
- **intra-**: Within, inside
- **intro-**: Into, within
- **iso-**: Same, equal
- **macro-**: Large
- **mal-**: Bad
- **mes-, meso-**: Middle
- **meta-**: Beyond, changing
- **micro-, micr-**: Tiny, small
- **mono-, uni-**: One
- **mult-, multi-**: Many, multiple
- **neo-**: New, recent
- **nulli-**: None

- **oligo-**: Small amount
- **ortho-**: Straight, normal
- **pan-**: All
- **para-**: Beyond, beside, after
- **per-**: Through
- **peri-**: Around
- **poly-**: Many, excessive
- **post-**: After, following, behind
- **pre-, pro-**: In front of, before, preceding
- **presby-**: Old age
- **pseudo-**: False
- **quadri-**: Four
- **re-**: Backward, again
- **retro-**: Behind, backward
- **semi-**: Half, partial
- **sub-**: Under, beneath
- **super-, supra-**: Above, excessive, superior
- **sym-, syn-**: With, together
- **tachy-**: Rapid, fast
- **trans-**: Through, across
- **tri-**: Three
- **ultra-**: Excessive, beyond
- **uni-**: One

See the following box for examples of commonly used prefixes in body-related medical terms. Additional prefixes will be discussed in each chapter related to specific body systems.

Examples of Common Prefixes in Medical Terms

- **Bilateral**: Both sides
- **Dysuria**: Painful urination

- **Hypertension:** Excessive/high blood pressure
- **Oliguria:** Small amount of urine production
- **Pericardial:** Around the heart
- **Tachycardia:** Rapid heart rate

1.4 Common Word Roots and Combining Vowels

A word root is the primary building block of a medical term and refers to the body part or body system to which the term is referring. Some words contain more than one word root. The order is generally dictated by common practice. As you practice throughout this course, you will learn more about how to determine the order of word roots. Word roots will be further discussed in more detail in each chapter as they relate to specific body systems.

A combining vowel is a word part, most often the letter “o,” that helps pronunciation.

COMMON WORD ROOTS AND THEIR COMBINING VOWEL

Here is a list of commonly used word roots and their combining vowel. It is helpful to memorize these components as you build your knowledge of medical terminology.

- **abdomin/o**: Abdomen
- **andr/o**: Male
- **angi/o**: Vessel
- **arteri/o**: Artery
- **arthr/o**: Joint
- **audi/o**: Hearing
- **bronch/i**, **bronch/o**: Bronchus/lung
- **carcin/o**: Cancer

- **cardi/o**: Heart
- **cholecyst/o**: Gallbladder
- **chondr/i**, **chondr/o**: Cartilage
- **col/o**: Colon
- **cysti**, **cyst/o**: Bladder or cyst
- **cyt/o**: Cell
- **duoden/o**: Duodenum
- **encephal/o**: Brain
- **erythr/o**: Red
- **esophag/**: Esophagus
- **gastr/o**: Stomach
- **glyc/o**: Sugar
- **gynec/o**: Female reproductive system
- **hemat/o**, **hem/o**: Blood
- **hist/o**: Tissue
- **hyster/o**: Uterus
- **laryng/o**: Larynx
- **leuk/o**: White
- **men/o**: Menstruation
- **my/o**: Muscle
- **nephr/o**: Kidney
- **neur/o**: Nerve
- **opt/o**: Vision
- **orch/o**: Testis, testicle
- **pneum/o**: Lungs
- **thorac/o**: Chest

See the following box for examples of common word roots in medical terms.

Examples of Common Word Roots in Medical Terms

Cardiomegaly: Enlargement of the heart

Encephalitis: Inflammation of the brain

Gynecologist: Specialist who treats disorders and diseases of female reproductive organs

Pneumonia: Disease state of the lung

MORE ON COMBINING VOWELS

A combining vowel is placed to connect two word roots or to connect a word root and a suffix. However, a combining vowel should not be used to connect a prefix and a word root. Note that not all medical terms will have combining vowels. See guidelines on using combining vowels in Table 1.4a.

Table 1.4a. Guidelines on Combining Vowels

Guideline	Example
When connecting a word root and a suffix, a combining vowel is used if the suffix DOES NOT begin with a vowel.	arthr/o/pathy
When connecting a word root and a suffix, a combining vowel is usually NOT USED if the suffix begins with a vowel.	hepat/ic
When connecting two word roots, a combining vowel is used even if vowels are present at the junction.	oste/o/arthr/itis
A combining vowel is NOT USED when connecting a prefix and a word root.	sub/hepat/ic

1.5 Common Suffixes

The suffix is at the end of the word and adds meaning. When building a definition of a medical term from its components, start with the meaning of the suffix. For example, *hepat/itis* is defined as “inflammation of the liver.”

Suffixes often indicate:

- **Procedures:** For example, *-scopy* means “visual examination”
- **Conditions:** For example, *-itis* means “inflammation”
- **Diseases:** For example, *-oma* means “tumor”

COMMON SUFFIXES

Here is a list of commonly used suffixes in medical terms. It is helpful to memorize these common suffixes as you build your knowledge of medical terminology.

- **-ac:** Pertaining to
- **-ad:** Toward
- **-al:** Pertaining to
- **-algia, -dynia:** Pain
- **-ar:** Pertaining to
- **-ary:** Pertaining to
- **-cele:** Protrusion
- **-centesis:** Surgical withdrawal of fluid
- **-cide, -cidal:** Kill, destroy
- **-coccus:** Berry shaped
- **-cyte:** Cell
- **-eal:** Pertaining to
- **-ectomy:** Surgical removal

- **-emia**: Pertaining to blood
- **-esis**: Condition
- **-gen**: Substance that produces/causes
- **-genic**: Produced by
- **-gram**: Record of
- **-graph**: Instrument used to record
- **-graphy**: A process of recording
- **-ia**: Condition of, diseased state, abnormal state
- **-ic, -ior**: Pertaining to
- **-ism**: State of, condition, theory
- **-itis**: Inflammation
- **-logist**: Specialist who studies and treats disorders
- **-logy**: Study of
- **-lysis**: Destruction, breakdown
- **-megaly**: Enlargement
- **-meter**: Instrument used to measure
- **-metry**: Process of measuring
- **-oid**: Resembling
- **-oma**: Tumor
- **-opia**: Vision condition
- **-opsy**: To view
- **-osis**: Abnormal condition
- **-ous**: Pertaining to
- **-pathy**: Disease, abnormality
- **-penia**: Lack of, deficiency
- **-pexy**: Surgical fixation, suspension
- **-phagia**: Eating
- **-phobia**: Intense fear of
- **-plasia**: Formation, development
- **-plasm**: Growth, substance, formation
- **-plasty**: Surgical reconstruction
- **-plegia**: Paralysis
- **-pnea**: Breathing
- **-poiesis, -poietic**: Production, manufacture of

- **-ptosis**: Drooping
- **-rrhage**: Excessive flow
- **-rrhagia**: Excessive flow
- **-rrhaphy**: Suturing in place, fixation
- **-rrhea**: Flow, discharge
- **-rrhexis**: Rupture or breaking away
- **-sclerosis**: Hardening
- **-scope**: Instrument used to visually examine
- **-scopic**: Visual examination
- **-scopy**: Process of visual examination
- **-spasm**: Sudden, involuntary
- **-stasis**: To stop
- **-stomy**: Artificial surgical opening
- **-tome**: Instrument used to cut
- **-tomy**: Process of incision, cutting into
- **-tripsy**: Crushing
- **-trophic, -trophy**: Growth, development

Note there are several suffixes that mean “pertaining to,” such as -ac, -al, -ar, -ary, -eal, -ic, -ior, and -ous.

Examples of Common Suffixes in Medical Terms

- Arachn**ophobia**: Fear of spiders
- Amnioc**entesis**: Procedure to withdraw fluid from the amniotic sac
- An**emia**: Low levels of hemoglobin in the blood
- Cardi**megaly**: Enlargement of the heart
- Colonos**copy**: Procedure that visually examines the colon
- Dys**pnea**: Difficulty breathing
- Hemip**legia**: Paralysis of one side of the body
- Mammog**raphy**: Radiological process of examining the

breast tissue

- My**algia**: Muscle pain

Additional suffixes will be discussed in each chapter related to specific body systems.

1.6 Foundational Concepts - Identifying Word Parts Learning Activities

Interactive Learning Activity: Study terms discussed in this chapter using these flashcards.



An interactive H5P element has been excluded from this version of the text. You can view it online here:

<https://wtcs.pressbooks.pub/medterm/?p=2634#h5p-170>

Interactive Learning Activity: Test your knowledge with this matching activity.



An interactive H5P element has been excluded from this version of the text. You can view it online here:

<https://wtcs.pressbooks.pub/medterm/?p=2634#h5p-160>

Interactive Learning Activity: Test your knowledge with this quiz.



An interactive H5P element has been excluded from this version of the text. You can view it online here:

<https://wtcs.pressbooks.pub/medterm/?p=2634#h5p-168>



Interactive Learning Activity: Practice identifying word parts with these interactive activities.



An interactive H5P element has been excluded from this version of the text. You can view it online here:

<https://wtcs.pressbooks.pub/medterm/?p=2634#h5p-169>

- ▶ You can also print this as a [Chapter 1 Practice Worksheet](#) and check your answers with this [Answer Key PDF](#).

1.7 Glossary

Combining form (CF): When a word root (WR) is combined with a combining vowel, the word part is referred to as a combining form. ([Chapter 1.2](#))

Combining vowel (CV): A word component, typically the letter “o,” that helps with pronunciation. A combining vowel can connect a word root and a suffix or two word roots. ([Chapter 1.2](#))

Prefix (P): A word component that appears at the beginning of the medical term and adds meaning to the word root. Prefixes often indicate number, position, direction, time, or negation. ([Chapter 1.2](#))

Suffix (S): A word component at the end of the medical term that usually indicates a procedure, condition, or disease. ([Chapter 1.2](#))

Word root (WR): A word component that is the core of many medical terms and refers to the body part or body system to which the term is referring. ([Chapter 1.2](#))

PART II

CHAPTER 2 MEDICAL LANGUAGE RELATED TO THE WHOLE BODY

2.1 Medical Language Introduction

Learning Objectives

- Use the anatomic reference system to identify the anatomic position of the body
- Use the anatomic reference system to identify the body planes
- Use the anatomic reference system to identify the body cavities
- Use the anatomic reference system to identify the directional terms
- Use the anatomic reference system to identify the divisions of the body
- Describe the structural organization of the body

In Chapter 1, the components of medical terms were introduced. As you continue to learn medical language, it is important to contextualize the meaning of these terms based on human anatomy. This chapter will review anatomical terminology related to organ systems, body cavities, body regions, and tissue membranes. It will also discuss the standardized anatomical position, directional terms, and planes of the body.

2.2 Levels of Organization

Anatomy focuses on structure, and **physiology** focuses on function. Much of the study of physiology centers on the body's tendency to maintain homeostasis. **Homeostasis** (hō-mē-ō-STĀ-sīs) refers to the body's biological processes that result in stable equilibrium.

LEVELS OF ORGANIZATION

The body has fundamental levels of organization that increase in complexity from chemical (atoms and molecules) to cells, tissues, organs, organ systems, to the organismal level. See Figure 2.1¹ for an illustration of these levels of organization.

1. "[101 Levels of Org in Body.jpg](https://openstax.org/books/anatomy-and-physiology-2e/pages/1-introduction)" by OpenStax is licensed under CC BY 4.0. Access for free at <https://openstax.org/books/anatomy-and-physiology-2e/pages/1-introduction>

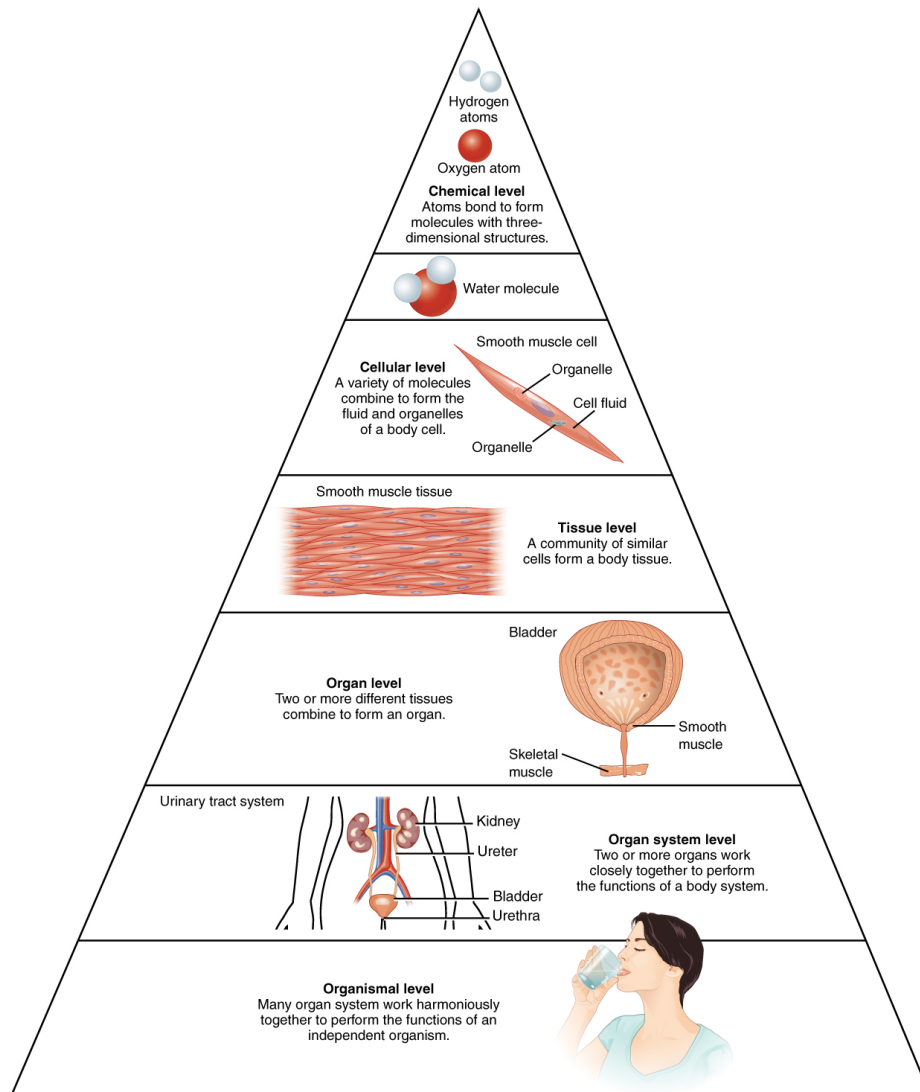


Figure 2.1 Levels of Structural Organization of the Human Body

The smallest unit of matter is an atom. Atoms are made up of subatomic particles, including protons, electrons, and neutrons. Two or more atoms combine to form a molecule, such as the water molecules, proteins, and sugars found in living things. Molecules are the chemical building blocks of all body structures.

A cell is the smallest independently functioning unit of a living organism. Even bacteria, which are extremely small, independently living organisms, have a cellular structure. Each bacterium is a single cell. All living structures of

the human body contain cells, and almost all functions of the human body are performed in cells or are initiated by cells.

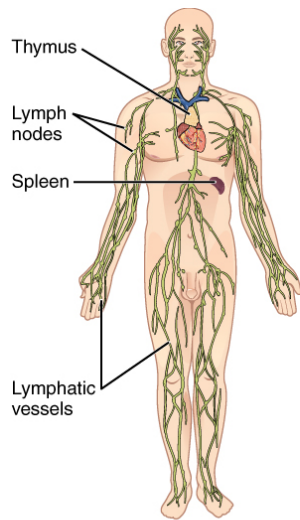
A tissue is a group of similar cells that work together to perform a specific function. An organ is an anatomically distinct structure of the body composed of two or more tissue types. Each organ performs one or more specific physiological functions. A system is a group of organs that work together to perform major functions or meet the physiological needs of the body.

The organism level is the highest level of organization. An organism is a living being that has a cellular structure and that can independently perform all physiologic functions necessary for life. In multicellular organisms, including humans, all cells, tissues, organs, and organ systems work together to maintain the life and health of the organism.

Organ Systems

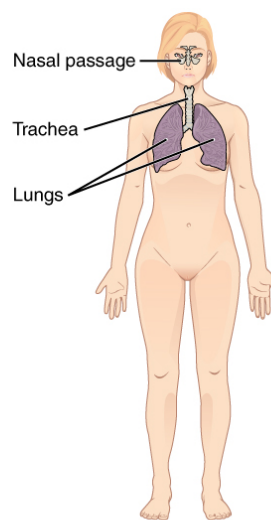
There are eleven distinct **organ systems** in the human body. See Figure 2.2² illustrations of organ systems, including the integumentary, skeletal, muscular, nervous, endocrine, cardiovascular, lymphatic, respiratory, digestive, urinary, and male and female reproductive systems.

2. “[Organ Systems II.jpg](https://openstax.org/books/anatomy-and-physiology-2e/pages/1-introduction)” by OpenStax is licensed under [CC BY 4.0](https://creativecommons.org/licenses/by/4.0/). Access for free at <https://openstax.org/books/anatomy-and-physiology-2e/pages/1-introduction>



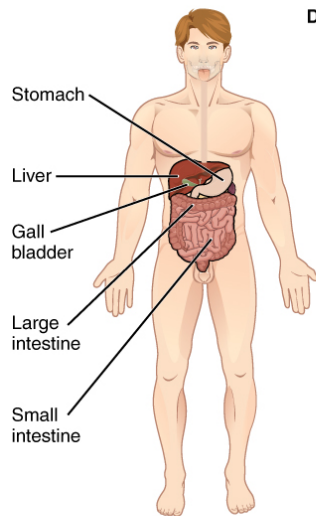
Lymphatic System

- Returns fluid to blood
- Defends against pathogens



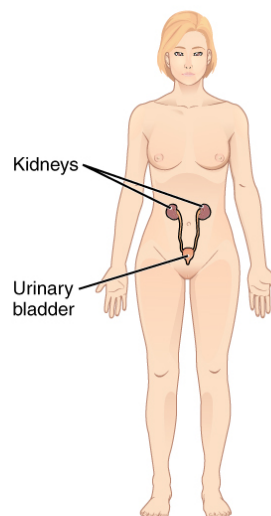
Respiratory System

- Removes carbon dioxide from the body
- Delivers oxygen to blood



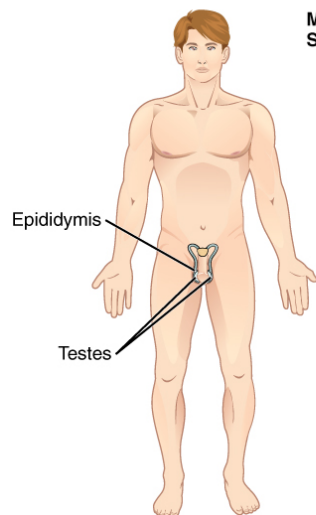
Digestive System

- Processes food for use by the body
- Removes wastes from undigested food



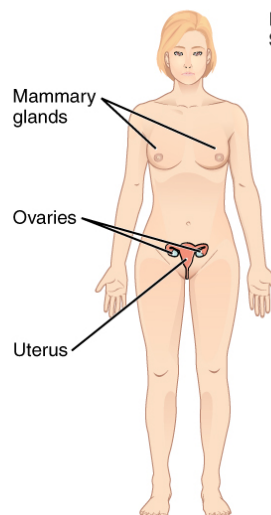
Urinary System

- Controls water balance in the body
- Removes wastes from blood and excretes them



Male Reproductive System

- Produces sex hormones and gametes
- Delivers gametes to female




Female Reproductive System

- Produces sex hormones and gametes
- Supports embryo/fetus until birth
- Produces milk for infant

Figure 2.2 Organ Systems of the Human Body

The remaining chapters of this book will discuss medical terms by organ system.

View a supplementary YouTube video³ for an
introduction to anatomy and physiology:
 [Introduction to Anatomy & Physiology: Crash Course
Anatomy & Physiology #1](https://youtu.be/uBGl2BujkPQ)

3. CrashCourse. (2015, January 6). *Introduction to anatomy & physiology: Crash course A&P #1* [Video]. YouTube. <https://youtu.be/uBGl2BujkPQ>

2.3 Body Cavities

BODY CAVITIES

The body maintains its internal organization by membranes and other structures that separate compartments. The dorsal (posterior) cavity and the ventral (anterior) cavity are the largest compartments of the body, as shown in Figure 2.3.¹ The **dorsal (posterior) cavity** includes the cranial and spinal (vertebral) cavities. The **ventral (anterior) cavity** includes the thoracic and abdominopelvic cavities.

1. “[Dorsal Ventral Body Cavities.jpg](#)” by OpenStax is licensed under [CC BY 4.0](#). Access for free at <https://openstax.org/books/anatomy-and-physiology-2e/pages/1-introduction>

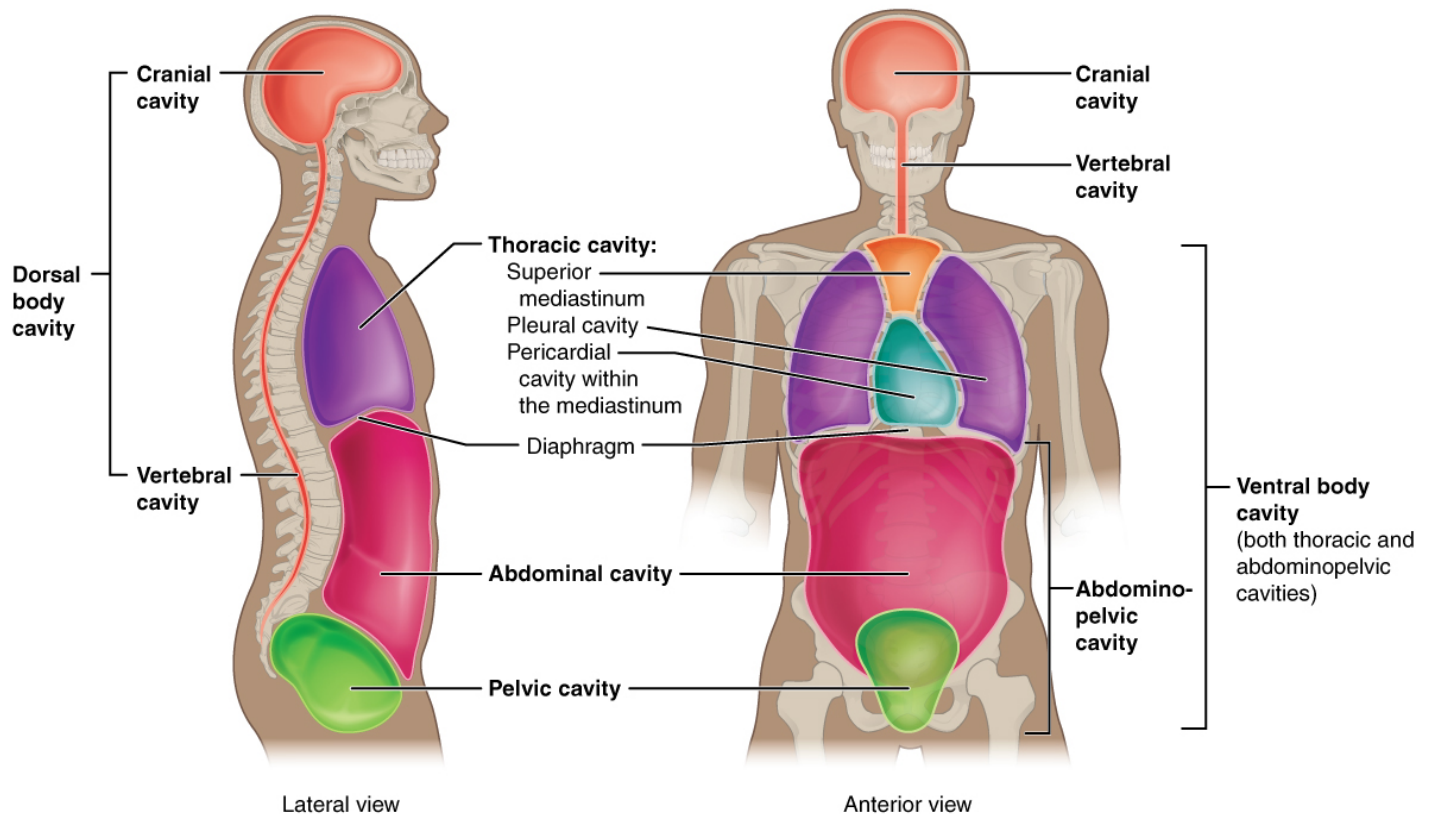


Figure 2.3 Dorsal and Ventral Body Cavities

In the dorsal cavity, the **cranial cavity** houses the brain. The brain is protected by the bones of the skulls and the cerebrospinal fluid. The **spinal cavity** (vertebral cavity) encloses the spinal cord. It is protected by the vertebral column and cerebrospinal fluid. In the ventral cavity, the **thoracic cavity** is superior in position to the abdominopelvic cavity, and it is enclosed by the rib cage. The thoracic cavity contains the lungs and the heart. The diaphragm forms the floor of the thoracic cavity and separates it from the abdominopelvic cavity. The **abdominopelvic cavity** is the largest cavity in the body. The abdominopelvic cavity houses the digestive organs, the pelvic cavity, and the reproductive organs. The ventral cavity also allows for significant changes in the size and shape of the organs as they perform their functions. For example, the lungs, heart, stomach, and intestines can expand and contract without distorting other tissues or disrupting the activity of nearby organs.



View a supplementary YouTube video² on body cavities and membranes:



One or more interactive elements has been excluded from this version of the text. You can view them online here: <https://wtcs.pressbooks.pub/medterm/?p=107#oembed-1>

2. RegisteredNurseRN. (2019, June 12). *Body cavities and membranes (Dorsal, Ventral) – Anatomy and physiology* [Video]. All rights reserved. Reused with permission. <https://www.youtube.com/watch?v=4GLMjSj4k9U>

2.4 Body Regions

BODY REGIONS

Body regions are used to specifically identify a body area, such as the abdominopelvic region and the spinal region.

Abdominopelvic Region

The abdominopelvic region can be divided into nine anatomic regions to assess and precisely communicate abdominal and pelvic locations. These regions include three across the top, three across the middle, and three across the bottom. See Figure 2.4¹ for an illustration of the abdominal region.

1. “[Abdominal Quadrant Regions.jpg](https://openstax.org/books/anatomy-and-physiology-2e/pages/1-introduction)” by OpenStax is licensed under [CC BY 3.0](https://creativecommons.org/licenses/by/3.0/). Access for free at <https://openstax.org/books/anatomy-and-physiology-2e/pages/1-introduction>

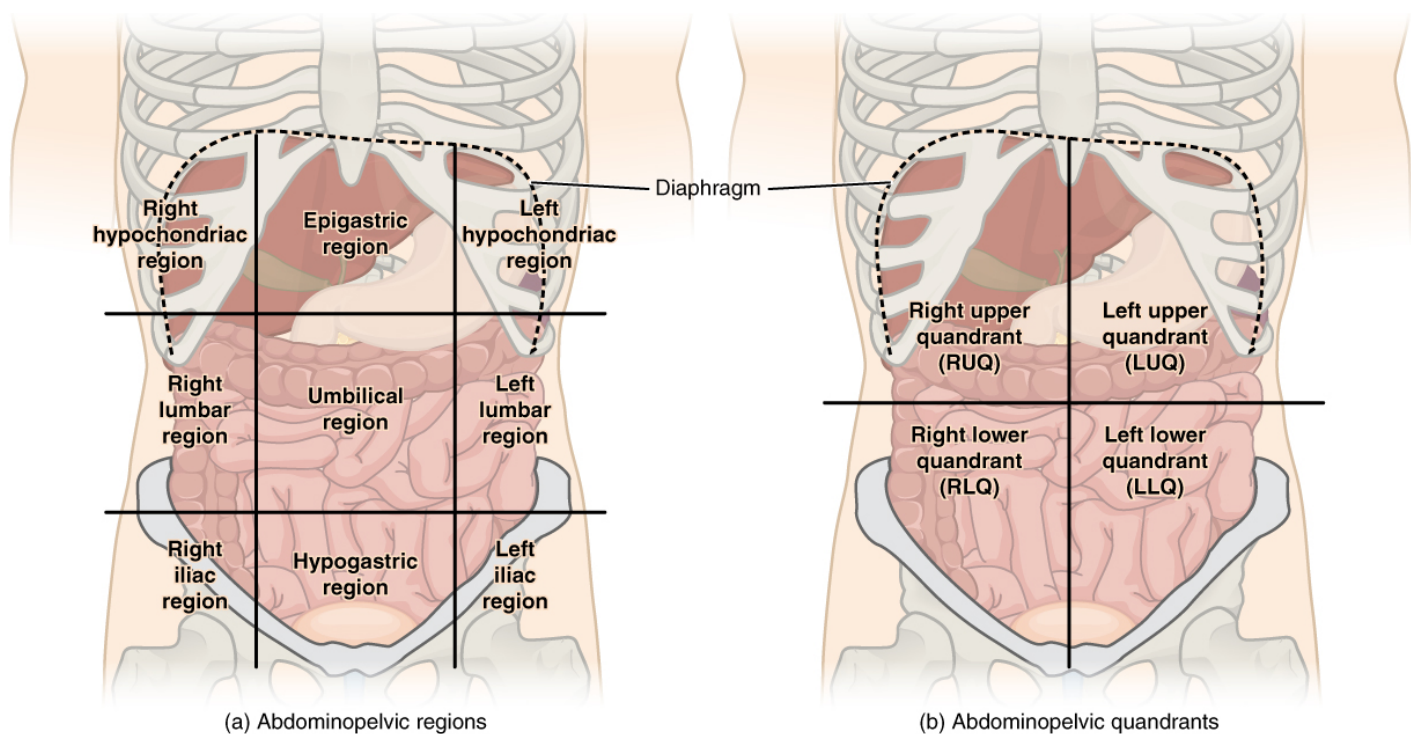


Figure 2.4 (a) Abdominopelvic Regions; (b) Abdominal Quadrants

The center portion of the nine squares is the umbilical region. Directly above the umbilical region is the epigastric region. Directly below the umbilical region is the hypogastric region. On either side of the epigastric region are the right and left hypochondriac regions. On either side of the hypogastric region are the right and left iliac regions. For example, a nurse may document that an individual has “pain in the epigastric region after eating spicy meals.”

As illustrated in Figure 2.4, the abdominopelvic area can also be divided into four abdominal quadrants:

- **Right upper quadrant (RUQ):** Contains the gallbladder, the right lobe of the liver, and parts of the small and large intestines.
- **Left upper quadrant (LUQ):** Contains the stomach, pancreas, spleen, left lobe of the liver, and parts of the small and large intestines.
- **Right lower quadrant (RLQ):** Contains the appendix, right ureter, right ovary and Fallopian tube, and parts of the small and large intestines.
- **Left lower quadrant (LLQ):** Contains the left ureter, left ovary and Fallopian tube, and parts of the small and large intestines.

For example, a nurse may document that a patient with severe constipation “has a firm mass in the left lower quadrant.” Keep in mind that “right” and “left” refer to the patient’s right and left side, not the examiner’s view of the individual.



View the following YouTube video² on abdominopelvic quadrants and organs contained in each quadrant:



One or more interactive elements has been excluded from this version of the text. You can view them online here: <https://wtcs.pressbooks.pub/medterm/?p=109#oembed-1>

Vertebral Cavity Regions

The vertebral (i.e., spinal) cavity is divided into five regions. From the top, near the head, to the bottom, near the tailbone, these regions are as follows³:

- **Cervical region:** The neck region with seven cervical vertebrae from C1 to C7.
- **Thoracic region:** The chest region, including the thoracic vertebrae from T1 to T12. Each vertebra in this region is joined to a rib.
- **Lumbar region:** The region between the ribs and the hip bones, including lumbar vertebrae L1 to L5.

2. RegisteredNurseRN. (2019, May 23). *Four abdominal quadrants and nice abdominal regions – Anatomy and physiology* [Video]. YouTube. All rights reserved. Reused with permission. <https://www.youtube.com/watch?v=ELRzBa-eAA>

3. This work is a derivative of [StatPearls](#) by Peabody, Black, & Das and is licensed under [CC BY 4.0](#)

- **Sacral region:** Five sacral vertebrae, S1 to S5, that are fused to form the sacrum.
- **Coccygeal region:** The coccyx (i.e., tailbone) that is composed of several fused bones.

For example, a physician may document that a patient has “chronic pain in the L4 region.”

Vertebrae are further discussed in the “[Anatomy of the Skeletal System](#)” section.

2.5 Tissue Membranes

TISSUE MEMBRANES

A tissue membrane is a thin layer of cells that covers the outside of the body, an organ, internal passageways that lead to the exterior of the body, or the lining of joint cavities. See Figure 2.5¹ for an illustration of tissue membranes. Consider these examples of tissue membranes:

- **Synovial membranes** line movable joints and produce fluid within the joint.
- **Epithelial membranes** can be found in the skin, which covers and protects the surface of the body.
- **Mucous membranes** are epithelial membranes that line and protect the digestive, respiratory, urinary, and reproductive tracts and are coated with mucous for protection.
- **Serous membranes** line body cavities such as the peritoneal, pleural, and pericardial cavities.

1. “413_Types_of_Membranes.jpg” by OpenStax is licensed under [CC BY 3.0](https://creativecommons.org/licenses/by/3.0/). Access for free at <https://openstax.org/books/anatomy-and-physiology-2e/pages/1-introduction>

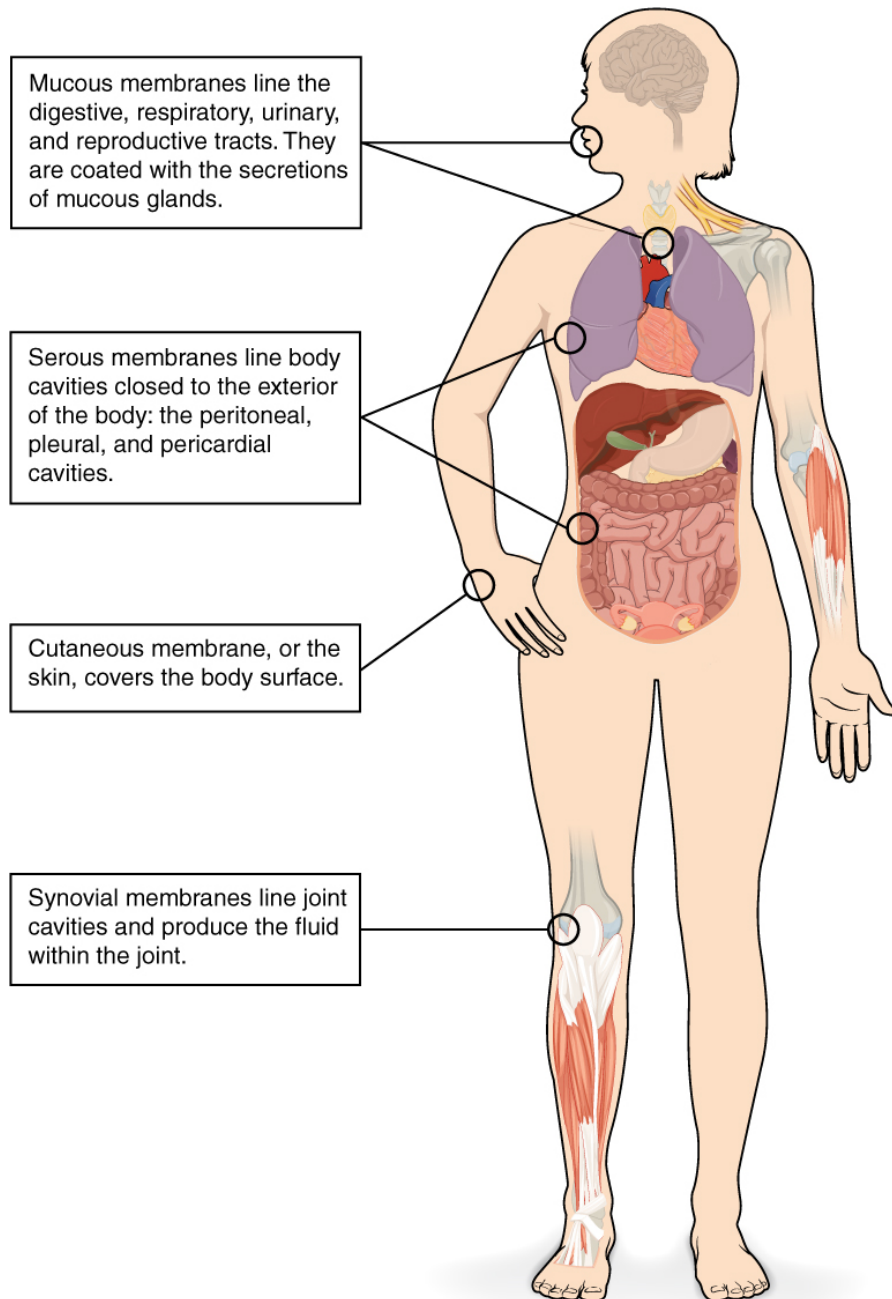


Figure 2.5 Tissue Membranes

Connective Tissue Membranes

Connective tissue membranes are formed solely from connective tissue and cover organs and line movable joints.

A synovial membrane is a type of connective tissue membrane that lines the cavities of joints that hold synovial fluid. Synovial fluid lubricates joints for movement. For example, synovial membranes surround the joints of the shoulder, elbow, and knee.

Epithelial Membranes

Epithelial membranes are composed of a thin layer of protective cells and are attached to a layer of connective tissue. Skin, mucous membranes, and serous membranes are types of epithelial membranes.

Skin is an epithelial membrane, also referred to as cutaneous membrane, that rests on top of connective tissue. The outer surface of the epithelial membrane is exposed to the external environment and is covered with dead, tough cells to protect the body from invading organisms and from desiccation (i.e., drying out).

Mucous membranes are another type of epithelial membrane that line body cavities and their passageways that open to the external environment. Mucus covers the epithelial membrane and provides protection. The digestive, respiratory, excretory, and reproductive tracts contain mucous membranes.

Serous membranes are a third type of epithelial membrane that are contained in body cavities and are composed of layers. A **parietal layer** lines the walls of a body cavity, and a **visceral layer** covers the organ within the body cavity. (Note that *viscer* is the word root for “organ.”) Between the parietal and visceral layers is a thin, fluid-filled serous space. Serous membranes provide protection to the organs they enclose by reducing friction that can lead to inflammation of the organs. There are three body cavities with serous membranes:

- **Pleura:** Serous membranes surround the lungs in the pleural cavity and reduce friction between the lungs and the body wall.
- **Pericardium:** Serous membranes surround the heart in the pericardial cavity and reduce friction between the heart and the wall of the pericardium. (Note the word components of *pericardial* are *peri-*

surrounding; *cardia*:- heart; and *-al*: pertaining to.)

- **Peritoneum:** Serous membranes surround several organs in the abdominopelvic cavity and reduce friction between the abdominal and pelvic organs and the body wall.

Consider the pericardium serous membranes around the heart as an example of a serous membrane. A visceral layer covers the heart, and a parietal layer lines the pericardial cavity. Between these two layers is a fluid-filled serous space that reduces friction for the beating heart. An analogy of this serous membrane is a fist surrounded by a thin, air-filled balloon to provide protection. See Figure 2.6² for an illustration of the visceral and parietal membranes of the pericardium compared to the analogy of a fist surrounded by a balloon.

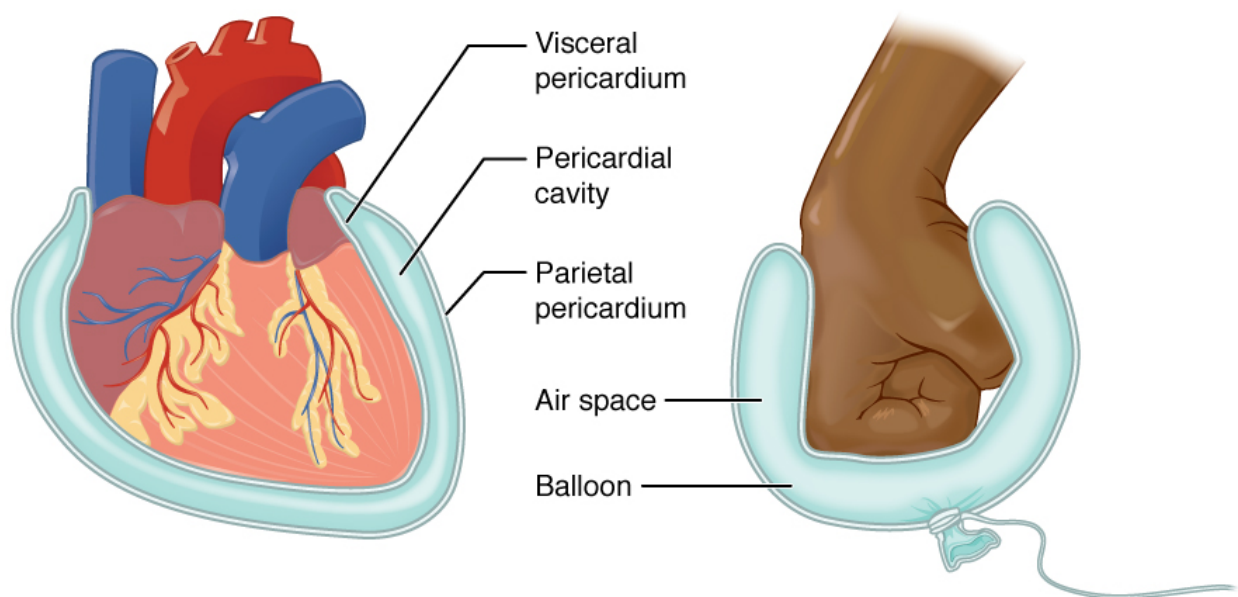


Figure 2.6 Serous Membranes of the Pericardium Compared to an Analogy of a Fist Surrounded by Two Membranes of an Air-Filled Balloon

2. “[Serous_Membrane.jpg](#)” by OpenStax is licensed under [CC BY 3.0](#). Access for free at <https://openstax.org/books/anatomy-and-physiology-2e/pages/1-introduction>

2.6 Anatomical View of the Body, Positions, Locations, and Directional Terms

ANATOMICAL VIEW OF THE BODY

Health care professionals use precise medical terminology when communicating detailed information about the body and its parts to reduce medical errors that can result from ambiguity. To further increase precision, a standardized **anatomical view of the body** is used. Just like paper maps are oriented with north at the top of the page, the standardized anatomical view of the body is its position standing upright with the feet at shoulder width and parallel and toes facing forward. The upper limbs are held out to each side of the body, and the palms of the hands face forward. The **anterior** view is the front of the body, and the **posterior** view is the back of the body. See an illustration of the standard anatomical position of a human body in both anterior and posterior views in Figure 2.7.¹

1. “Regions of the Body” by OpenStax is licensed under [CC BY 4.0](https://creativecommons.org/licenses/by/4.0/). Access for free at <https://openstax.org/books/anatomy-and-physiology-2e/pages/1-introduction>

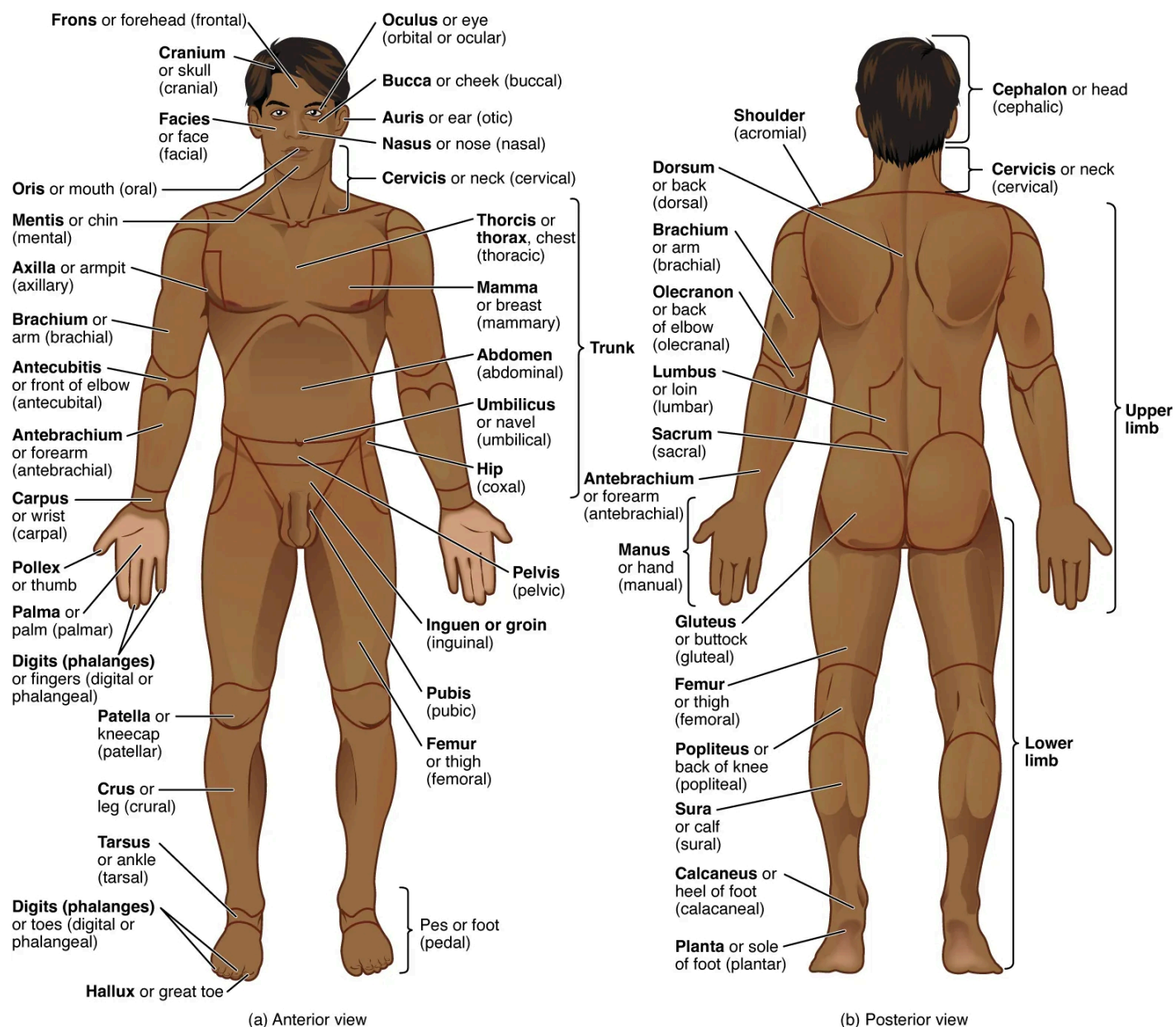


Figure 2.7 Standardized Anatomical View of the Human Body in (a) Anterior View and (b) Posterior View

Using this standardized anatomical view of the body reduces the potential for inaccuracy or error. It does not matter how a person who is being described is currently positioned when being examined; the terms for anatomical position are used as if the body is in this standard anatomical position. For example, if a patient is being examined while seated with their hand facing palm down

on a table and has a scar present on the palmar side of their wrist, the scar is described as being present on the “anterior wrist region.”

ANATOMICAL POSITIONS AND LOCATIONS

In addition to using a standardized anatomical view of the body, several medical terms are used to describe the positioning or location of the body or body parts, especially during specific procedures. For example, an individual lying down on their back is referred to as **supine**. If they are lying on the abdomen, their position is referred to as **prone**. If they are lying on their side, their position is referred to as **lateral** or side-lying.

If a condition occurs on one side of the body, it is referred to as **unilateral**, whereas if it occurs on both sides of the body, it is referred to as **bilateral**. For example, if an individual is having weakness in both legs, this condition may be documented as “bilateral leg weakness.”

Specific terms also refer to the location on an individual’s hand or foot. For example, **dorsum** refers to the top of one’s hand or foot. **Palmar** refers to the palm side of one’s hand, and **plantar** refers to the sole side of one’s foot.

- ▶ View additional information and images about positioning in the “Repositioning Patients” subsection of the “[Basic Concepts](#)” section in the “Mobility” chapter in *Open RN Nursing Fundamentals*.

DIRECTIONAL TERMS

Directional terms describe the locations of body structures related to each other. For example, a physician might document a tumor as “superficial to” a deeper body structure. See Figure 2.8² for an illustration of directional terms.

- **Anterior(or ventral):** The front or direction toward the front of the body. For example, the kneecap is on the anterior side of the leg.
- **Contralateral:** Positioned on the opposite side. For example, the left arm and right arm are contralateral to each other.
- **Deep:** A position farther from the surface of the body. For example, the brain is deep in the skull.
- **Distal:** A position in a limb that is farther from the point of attachment or the trunk of the body. For example, the hand is at the distal end of the forearm.
- **Inferior (or caudal):** A position below or lower than another part of the body; near the coccyx or lowest part of the spinal column. For example, the pelvis is inferior to the abdomen.
- **Ipsilateral:** Positioned on the same side. For example, the left arm and left leg are ipsilateral to each other.
- **Lateral:** The side or direction toward the side of the body. For example, the thumb is lateral to the digits.
- **Medial:** The middle or direction toward the middle of the body. For example, the hallux (commonly called the “big toe”) is the medial toe.
- **Posterior (or dorsal):** The back or direction toward the back of the body. For example, the shoulder blades are on the posterior side of the chest.
- **Proximal:** A position in a limb that is nearer to the point of attachment or the trunk of the body. For example, the proximal end of the femur joins

2. “Directions Terms” by OpenStax is licensed under [CC BY 4.0](https://creativecommons.org/licenses/by/4.0/). Access for free at <https://openstax.org/books/anatomy-and-physiology-2e/pages/1-introduction>

the pelvis.

- **Superficial:** A position closer to the surface of the body. For example, the skin is superficial to the bones.
- **Superior (or cranial or cephalic):** A position above or higher than another part of the body. For example, the head is superior to the neck.

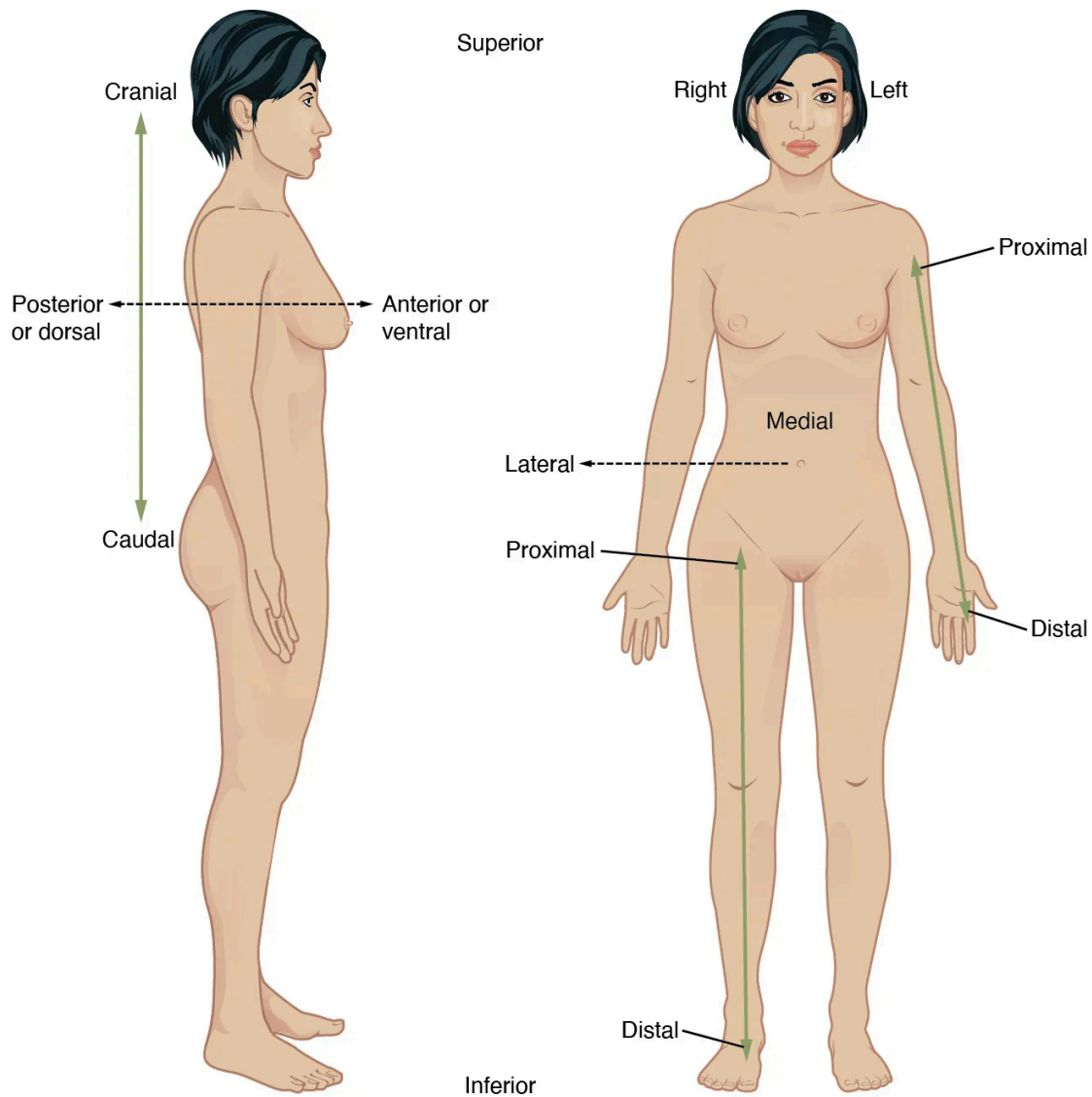


Figure 2.8 Directional Terms Applied to the Human Body

2.7 Body Planes

BODY PLANES

Medical imaging, such as CT scans, obtain images of an individual's body or an organ in sections. A section is a two-dimensional surface of a three-dimensional structure that has been virtually cut. In order for scans to be correctly interpreted, the viewer must understand the plane along which the section was made. A **plane** is an imaginary two-dimensional surface that passes through the body. Four planes commonly referred to the medical field are frontal (coronal), sagittal (lateral), transverse (axial), and oblique:

- **Frontal (coronal) plane:** A vertical plane running from side to side that divides the body or any of its parts into anterior and posterior portions.
- **Sagittal (lateral) plane:** A vertical plane running from front to back that divides the body or any of its parts into right and left sides. If this vertical plane runs directly down the middle of the body, it is called the **midsagittal** or **median** plane. If the plane divides the body into unequal right and left sides, it is called a **parasagittal** plane or **longitudinal** section.
- **Transverse (axial) plane:** A horizontal plane that divides the body or any of its parts into upper and lower parts. Transverse planes produce images often referred to as “cross-sections.”
- **Oblique plane:** Divides the body at an angle between the horizontal and vertical planes.

See Figure 2.9¹ for an illustration of body planes.

1. “[Planes_of_Body.jpg](#)” by OpenStax is licensed under [CC BY 4.0](#). Access for free

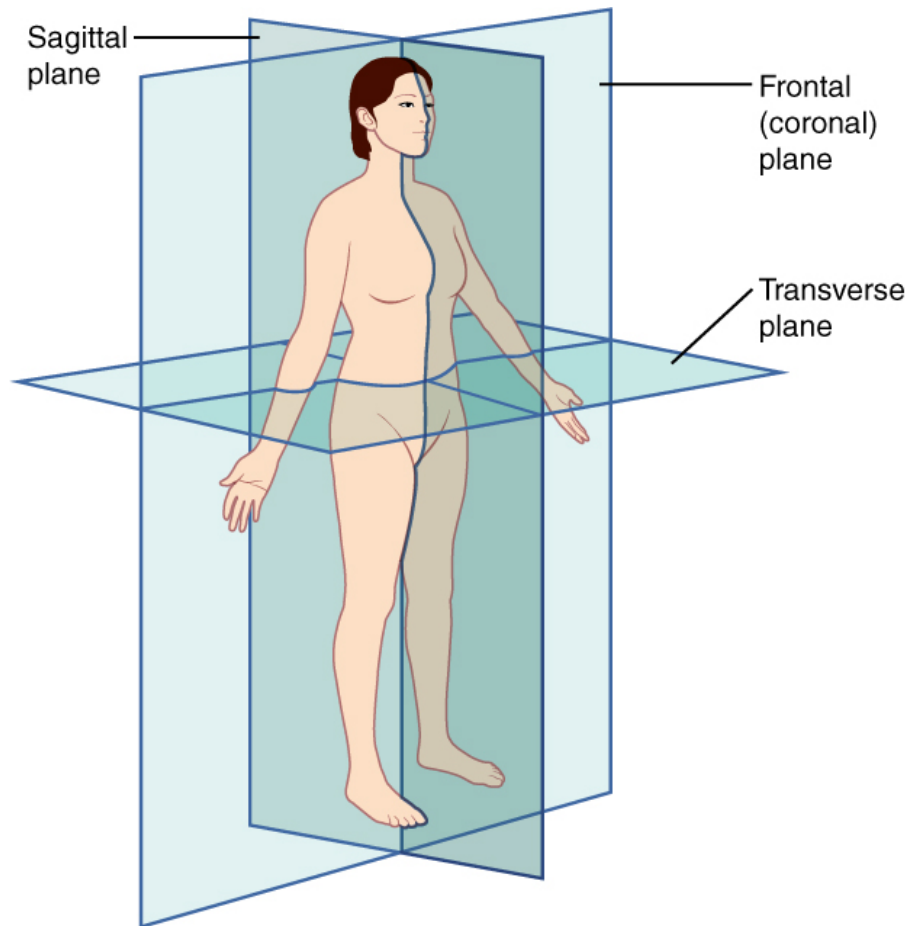


Figure 2.9 Body Planes



View a supplementary YouTube video² on body planes:

at <https://openstax.org/books/anatomy-and-physiology-2e/pages/1-introduction>

2. RegisteredNurseRN. (2019, May 17). *Body planes and sections: Frontal, sagittal, oblique, transverse* | *Anatomy and Physiology*. [Video].



One or more interactive elements has been excluded from this version of the text. You can view them online here: <https://wtcs.pressbooks.pub/medterm/?p=105#oembed-1>

YouTube. All rights reserved. Reused with permission.
<https://www.youtube.com/watch?v=0EjklfLrEW8>

2.8 Medical Language Related to the Whole Body Learning Activities

Interactive Learning Activity: Practice labelling body cavities with this drag and drop activity.



An interactive H5P element has been excluded from this version of the text. You can view it online here:

<https://wtcs.pressbooks.pub/medterm/?p=2767#h5p-5>

Interactive Learning Activity: Practice labelling quadrants with this drag and drop activity.



An interactive H5P element has been excluded from this version of the text. You can view it online here:

<https://wtcs.pressbooks.pub/medterm/?p=2767#h5p-7>

Interactive Learning Activity: Practice labelling planes by dragging the name of the plane to its corresponding position.



An interactive H5P element has been excluded from this version of the text. You can view it online here:

<https://wtcs.pressbooks.pub/medterm/?p=2767#h5p-3>

Interactive Learning Activity: Study terms discussed in this chapter using these flashcards.



An interactive H5P element has been excluded from this version of the text. You can view it online here:

<https://wtcs.pressbooks.pub/medterm/?p=2767#h5p-171>

Interactive Learning Activity: Quiz yourself on terms related to the human body.



An interactive H5P element has been excluded from this version of the text. You can view it online here:

<https://wtcs.pressbooks.pub/medterm/?p=2767#h5p-9>

Interactive Learning Activity: Quiz yourself on terms related to the human body.



An interactive H5P element has been excluded from this version of the text. You can view it online here:

<https://wtcs.pressbooks.pub/medterm/?p=2767#h5p-162>

Interactive Learning Activity: Drag and drop terms describing body planes.



An interactive H5P element has been excluded from this version of the text. You can view it online here:

<https://wtcs.pressbooks.pub/medterm/?p=2767#h5p-163>



Interactive Learning Activity: Match opposite directional terms.



An interactive H5P element has been excluded from this version of the text. You can view it online here:

<https://wtcs.pressbooks.pub/medterm/?p=2767#h5p-164>

- ▶ You can also print this as a [Chapter 2 Practice Worksheet](#) and check your answers with this [Answer Key PDF](#).

2.9 Glossary

Abdominopelvic cavity: Part of the ventral (anterior) cavity; the abdominopelvic cavity is the largest cavity in the body and houses the digestive organs, the pelvic cavity, and the reproductive organs. ([Chapter 2.3](#))

Anatomical view of the body: A standardized view of the human body used for precise documentation and communication, in the position of standing upright with the feet at shoulder width and parallel and toes facing forward. The upper limbs are held out to each side of the body, and the palms of the hands face forward. ([Chapter 2.6](#))

Anatomy: The structure of body systems. ([Chapter 2.2](#))

Anterior: The front or direction toward the front of the body. For example, the kneecap is on the anterior side of the leg. ([Chapter 2.6](#))

Bilateral: On both sides of the body. ([Chapter 2.6](#))

Contralateral: Positioned on the opposite side. For example, the left arm and right arm are contralateral to each other. ([Chapter 2.6](#))

Cranial cavity: Part of the dorsal (posterior) cavity that houses the brain. ([Chapter 2.3](#))

Deep: A position or direction farther from the surface of the body. For example, the brain is deep in the skull. ([Chapter 2.6](#))

Distal: A position in a limb that is farther from the point of attachment or the trunk of the body. For example, the hand is at the distal end of the forearm. ([Chapter 2.6](#))

Dorsal (posterior) cavity: The body cavity that includes the cranial and spinal (vertebral) cavities. ([Chapter 2.3](#))

Dorsum: The top of one's hand or foot. ([Chapter 2.6](#))

Frontal (coronal) plane: A vertical plane running from side to side that divides the body or any of its parts into anterior and posterior portions. ([Chapter 2.7](#))

Homeostasis (hō-mē-ō-STĀ-sīs): The body's biological processes that result in stable equilibrium. ([Chapter 2.2](#))

Inferior or caudal: A position below or lower than another part of the body;

near the coccyx or lowest part of the spinal column. For example, the pelvis is inferior to the abdomen. ([Chapter 2.6](#))

Ipsilateral: Positioned on the same side. For example, the left arm and left leg are ipsilateral to each other. ([Chapter 2.6](#))

Lateral: The position of lying on one's side or the direction toward the side of the body. For example, the thumb is lateral to the digits. ([Chapter 2.6](#))

Medial: The middle or the direction toward the middle of the body. For example, the hallux is the medial toe. ([Chapter 2.6](#))

Mucous membranes: A type of epithelial membrane that lines body cavities and their passageways that open to the external environment. Mucus, produced by epithelial exocrine glands, covers the epithelial membrane and provides protection. The digestive, respiratory, excretory, and reproductive tracts contain mucous membranes. ([Chapter 2.5](#))

Oblique plane: Divides the body at an angle between the horizontal and vertical planes. ([Chapter 2.7](#))

Organ systems: A group of organs that work together to perform major functions or meet the physiological needs of the body. There are eleven distinct organ systems in the human body, including the integumentary, skeletal, muscular, nervous, endocrine, cardiovascular, lymphatic, respiratory, digestive, urinary, and male and female reproductive systems. ([Chapter 2.2](#))

Palmar: The palm side of one's hand. ([Chapter 2.6](#))

Physiology: The function of body structures. ([Chapter 2.2](#))

Plantar: The sole side of one's foot. ([Chapter 2.6](#))

Posterior: The back or direction toward the back of the body. For example, the shoulder blades are on the posterior side of the chest. ([Chapter 2.6](#))

Prone: The position of lying on one's abdomen. ([Chapter 2.6](#))

Proximal: A position in a limb that is nearer to the point of attachment or the trunk of the body. For example, the proximal end of the femur joins the pelvis. ([Chapter 2.6](#))

Sagittal (lateral) plane: A vertical plane running from front to back that divides the body or any of its parts into right and left sides. If this vertical plane runs directly down the middle of the body, it is called the midsagittal or median plane. If the plane divides the body into unequal right and left sides, it is called a parasagittal plane or longitudinal section. ([Chapter 2.7](#))

Serous membranes: A type of epithelial membrane that is contained in body cavities and is composed of layers. A parietal layer lines the walls of a body cavity, and a visceral layer covers the organ within the body cavity. Between the parietal and visceral layers is a thin, fluid-filled serous space. Serous membranes provide protection to the organs they enclose by reducing friction that can lead to inflammation of the organs. There are three body cavities with serous membranes, including the pleura (lungs), pericardium (heart), and peritoneum (several organs in the abdominopelvic cavity). ([Chapter 2.5](#))

Spinal cavity: Part of the dorsal (posterior) cavity; the spinal cavity (vertebral cavity) encloses the spinal cord and is protected by the vertebral column and cerebrospinal fluid. ([Chapter 2.3](#))

Superficial: A position or direction closer to the surface of the body. For example, the skin is superficial to the bones. ([Chapter 2.6](#))

Superior or cranial: A position above or higher than another part of the body. For example, the head is superior to the neck. ([Chapter 2.6](#))

Supine: The position of lying down on one's back. ([Chapter 2.6](#))

Synovial membranes: A type of connective tissue membrane that lines the cavities of joints that hold synovial fluid. Synovial fluid lubricates joints for movement. For example, synovial membranes surround the joints of the shoulder, elbow, and knee. ([Chapter 2.5](#))

Thoracic cavity: Part of the ventral (anterior) cavity that is superior in position to the abdominopelvic cavity and enclosed by the rib cage. The thoracic cavity contains the lungs and the heart. ([Chapter 2.3](#))

Transverse (axial) plane: A horizontal plane that divides the body or any of its parts into upper and lower parts. Transverse planes produce images often referred to as “cross sections.” ([Chapter 2.7](#))

Unilateral: One side of the body. ([Chapter 2.6](#))

Ventral (anterior) cavity: The body cavity that includes the thoracic and abdominopelvic cavities. ([Chapter 2.3](#))

PART III

CHAPTER 3 INTEGUMENTARY SYSTEM TERMINOLOGY

3.1 Integumentary System Introduction

Learning Objectives

- Apply the rules of medical language to build, analyze, spell, pronounce, abbreviate, and define terms as they relate to the integumentary system
- Identify meanings of key word components of the integumentary system
- Categorize diagnostic, therapeutic, procedural, or anatomic terms related to the integumentary system
- Use terms related to the integumentary system
- Use terms related to the diseases and disorders of the integumentary system

Introduction to the Integumentary System

The integumentary system refers to the skin and accessory structures like hair, skin, and nails. This chapter will review common word components related to the integumentary system to assist students in learning how to analyze, build, and define terms. Other integumentary terms, whose definitions cannot be easily built from word components, will be described in context based on the anatomy and physiology of the integumentary system and common diseases and disorders. Medical specialists and procedures related to the integumentary system will also be discussed.



View the following YouTube video¹ for an introduction to the science of skin: The Science of Skin – Emma Bryce

1. TED-Ed. (2018, March 12). *The science of the skin – Emma Bryce* [Video]. YouTube. All rights reserved. <https://youtu.be/OxPICkTKhzY?si=oBrUcsTDLu2I3ivF>

3.2 Word Components Related to the Integumentary System

This section will describe common word components related to the integumentary system. These word components will help you build definitions for many medical terms related to the integumentary system. Other common prefixes are described in [Chapter 1.3](#), and common suffixes are described in [Chapter 1.5](#).

COMMON PREFIXES RELATED TO THE INTEGUMENTARY SYSTEM

- **a-, an-:** Absence of, without, not
- **bi-:** Two or both
- **dia-:** Through, complete
- **dys-:** Difficult, painful, abnormal, labored
- **epi-:** Upon, on, over
- **hyper-:** Above, excessive
- **hypo-:** Deficient, below, under, incomplete
- **intra-:** Within, in
- **meta-:** Change, beyond, after
- **neo-:** New
- **para-:** Beside, around, beyond, abnormal
- **per-:** Through
- **pro-:** Before

- **sub-**: Under, below
- **trans-**: Through, across, beyond
- **uni-**: One

COMMON WORD ROOTS WITH A VOWEL (CALLED COMBINING FORMS) RELATED TO THE INTEGUMENTARY SYSTEM

- **aden/o**: Gland
- **adip/o**: Fat
- **albin/o**: White
- **aut/o**: Self
- **bi/o**: Life
- **coni/o**: Dust
- **cry/o**: Cold
- **crypt/o**: Hidden
- **cutane/o**: Skin
- **cyan/o**: Blue
- **derm/o**: Skin
- **dermat/o**: Skin
- **erythr/o**: Red
- **erythemat/o**: Redness
- **fibr/o**: Fibrous tissues
- **heter/o**: Other, different
- **hidr/o**: Sweat
- **kerat/o**: Hard, horny tissue, keratin
- **lei/o**: Smooth
- **leuk/o**: White
- **lip/o, lipid/o**: Fat
- **melan/o**: Black
- **myc/o**: Fungus

- **necr/o**: Death
- **onych/o**: Nail
- **pachy/o**: Thick
- **pil/o**: Hair
- **py/o**: Pus
- **rhytid/o**: Wrinkles
- **scler/o**: Hardening
- **seb/o**: Sebum
- **staphyl/o**: Grapelike clusters
- **steat/o**: Fat, sebum
- **strept/o**: Twisted chains
- **trich/o**: Hair
- **ungu/o**: Nail
- **xanth/o**: Yellow
- **xer/o**: Dryness, dry

COMMON SUFFIXES RELATED TO THE INTEGUMENTARY SYSTEM

- **-a**: No meaning, noun ending
- **-ad**: Toward
- **-al**: Pertaining to
- **-coccus**: Berry-shaped
- **-cyte**: Cell
- **-ectomy**: Excision
- **-gen**: Substance that produces/causes, agent that produces/causes
- **-genic**: Producing, originating, causing
- **-ia**: Condition of, diseased state, abnormal state
- **-ic**: Pertaining to
- **-ior**: Pertaining to
- **-itis**: Inflammation

- **-logist**: Specialist who studies and treats
- **-logy**: Study of
- **-malacia**: Softening
- **-megaly**: Enlarged, enlargement
- **-oid**: Resembling
- **-oma**: Tumor, swelling
- **-opsy**: View of, process of viewing, viewing
- **-osis**: Abnormal condition, increased numbers pertaining to blood
- **-ous**: Pertaining to
- **-pathy**: Disease
- **-phagia**: Eating, swallowing
- **-plasia**: Development, growth, condition of formation
- **-plasm**: Growth, substance, formation
- **-plasty**: Surgical repair
- **-rrhea**: Flow
- **-rrhage, -rrhagia**: Excessive discharge
- **-sis**: State of
- **-stasis**: Stop, controlling, standing
- **-tome**: Instrument used to cut

3.3 Examples of Integumentary Terms Easily Defined By Their Word Components

Here are examples of integumentary medical terms that can be easily defined by breaking them into word components.

Dermatologist

1. Break down the medical term into word components:
Dermat/o/logist
2. Label the word parts: **Dermat** = WR; **o** = CV; **logist** = S
3. Define the word components: **Dermat** = skin; **logist** = specialist who studies and treats disorders
4. Create a final definition of the medical term: **A specialist who studies and treats disorders of the skin**

Epidermal

1. Break down the medical term into word components:
Epi/derm/al
2. Label the word parts: **Epi** = P; **derm** = WR; **al** = S

3. Define the word components: **Epi** = upon/on; **derm** = skin; **al** = pertaining to
4. Create a final definition of the medical term: **Pertaining to upon/on the skin**

Hypodermic

1. Break down the medical term into word components:
Hypo/derm/ic
2. Label the word parts: **Hypo** = P; **derm** = WR; **ic** = S
3. Define the word components: **Hypo** = below; **derm** = skin; **ic** = pertaining to
4. Create a final definition of the medical term: **Pertaining to below the skin**

Onychomycosis

1. Break down the medical term into word components:
Onych/o/myc/osis
2. Label the word parts: **Onych** = WR; **o** = CV; **myc** = WR; **osis** = S
3. Define the word components: **Onych** = nail; **myc** = fungus; **osis** = abnormal condition
4. Create a final definition of the medical term: **Abnormal condition of a fungus in the nails**



Interactive Learning Activity: Practice pronouncing and defining medical terms related to the integumentary system by breaking them into word components.



An interactive H5P element has been excluded from this version of the text. You can view it online here:

<https://wtcs.pressbooks.pub/medterm/?p=2955#h5p-21>

- ▶ You can also print this as a [Chapter 3 Student Companion Worksheet](#) and check your answers with this [Answer Key](#).

3.4 Anatomy and Physiology of the Integumentary System

This section will provide a general overview of the anatomy and physiology of the integumentary system.

ANATOMY OF THE INTEGUMENTARY SYSTEM

The skin and its accessory structures make up the integumentary system, which provides the body with overall protection. The skin is made of multiple layers of cells and tissues, which are held to underlying structures by connective tissue. The skin is composed of three main layers: the epidermis, dermis, and hypodermis.¹ See Figure 3.1² for an illustration of the three main layers of the skin and other anatomical structures.

1. This work is a derivative of [Anatomy and Physiology](#) by [OpenStax](#) licensed under [CC BY 4.0](#). Access for free at <https://openstax.org/books/anatomy-and-physiology/pages/1-introduction>
2. [“501_Structure_of_the_skin.jpg”](#) by J. Gordon Betts, et al., for OpenStax is licensed under [CC BY 4.0](#)

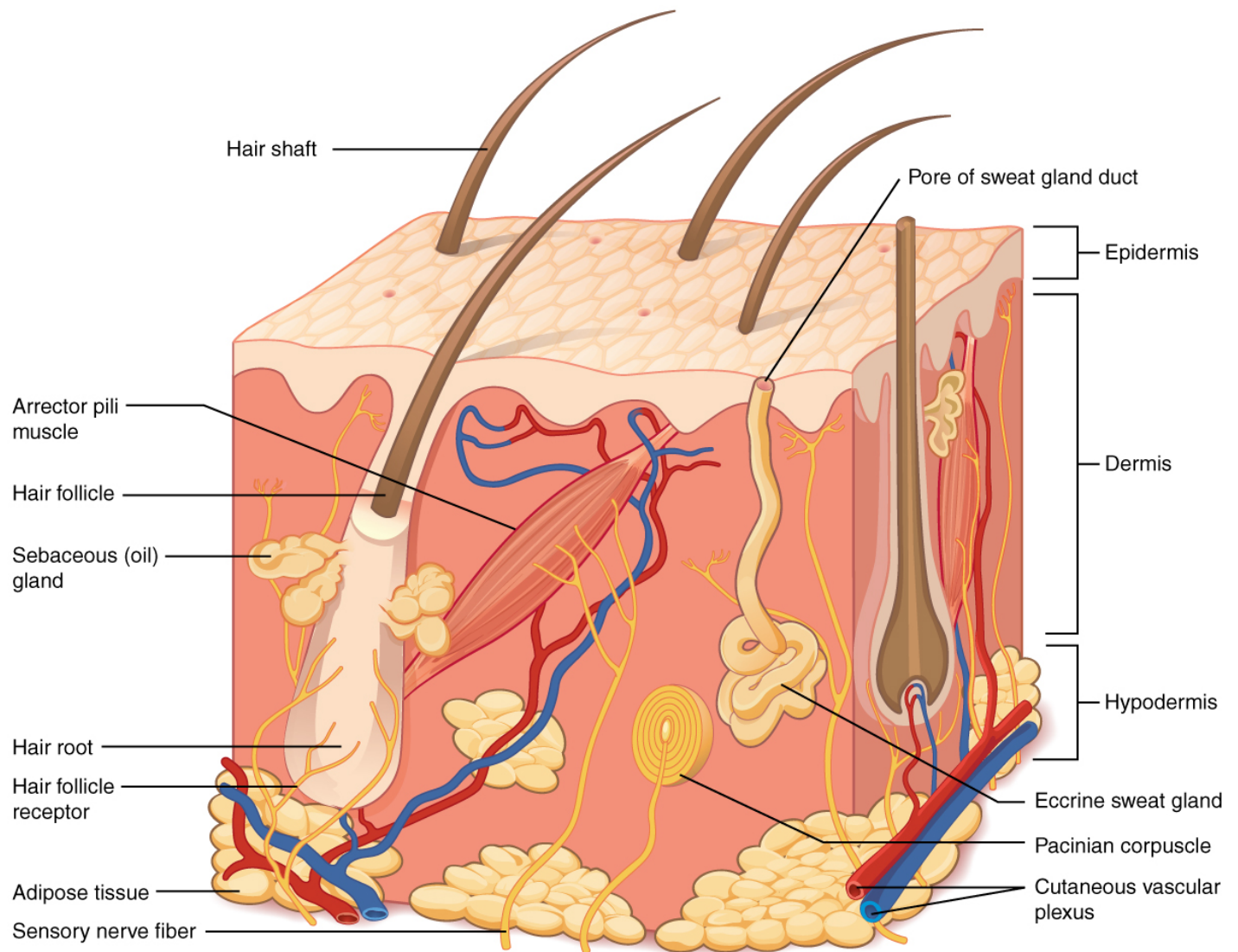


Figure 3.1 Layers of the Skin

The **epidermis** (ěp-ī-DUR-mīs) is the outermost layer of skin. It is composed of keratinized epithelium. **Keratin** (kěr-ă-TIN) is an intracellular fibrous protein that gives hair, nails, and skin their hardness and water-resistant properties. The keratinocytes in the epithelium are dead and regularly slough away, being replaced by cells from the deeper layers. **Melanocytes** (MĚL-ăn-ō-sīts) are melanin-producing cells located in the

bottom layer of epidermis. Melanin is a dark pigment primarily responsible for skin color.³

The **dermis** (DĚR-mĭs) lies under the epidermis. It contains blood and lymph vessels, nerves, and other structures, such as hair follicles and sweat glands.

The **hypodermis** (hĭ-pō-DUR-mĭs), also referred to as **subcutaneous** (sub-kū-TĀ-nē-us) tissue, is the layer underneath the dermis. It consists of connective tissue that is **vascularized** (VĀS-kū-lə-rīzd) (i.e., provided with blood vessels) and **adipose** (AD-ĭ-pōs) tissue. Adipose tissue serves as fat storage and provides insulation and cushioning. **Elastin** (ĭ-LĀS-tĭn) is a protein in this connective tissue that makes skin stretchy. The hypodermis connects the skin to the underlying bones and muscles, referred to as the **fascia** (FASH-ē-ă). The underlying hypodermis has important roles in storing fats, forming a “cushion” over underlying structures and providing insulation from cold temperatures.⁴

ACCESSORY STRUCTURES

Accessory structures of the skin include hair, nails, sweat glands, and sebaceous glands.

3. This work is a derivative of [Anatomy and Physiology](#) by [OpenStax](#) licensed under [CC BY 4.0](#). Access for free at <https://openstax.org/books/anatomy-and-physiology/pages/1-introduction>
4. This work is a derivative of [Anatomy and Physiology](#) by [OpenStax](#) licensed under [CC BY 4.0](#). Access for free at <https://openstax.org/books/anatomy-and-physiology/pages/1-introduction>

Hair

Hair is a keratinous filament growing out of the epidermis. It is primarily made of dead, keratinized cells. Strands of hair originate in the dermis in a structure called the hair follicle. The hair shaft is the part of the hair not anchored to the follicle, and much of this is exposed at the skin's surface. The rest of the hair, which is anchored in the follicle, lies below the surface of the skin and is referred to as the hair root.⁵

Each hair root is connected to a smooth muscle called the arrector pili that contracts in response to nerve signals from the **sympathetic nervous system** (sĭm-pă-THĚT-ĭk NĚR-vŭs SIS-tĕm). These signals make the external hair shaft “stand up,” commonly referred to as “goose bumps.” The primary purpose for this response is to trap a layer of air to add insulation and warmth.⁶ See Figure 3.2⁷ for an illustration of hair.

5. This work is a derivative of Anatomy and Physiology by OpenStax licensed under CC BY 4.0. Access for free at <https://openstax.org/books/anatomy-and-physiology/pages/1-introduction>
6. This work is a derivative of Anatomy and Physiology by OpenStax licensed under CC BY 4.0. Access for free at <https://openstax.org/books/anatomy-and-physiology/pages/1-introduction>
7. “506_Hair.jpg” by OpenStax is licensed under CC BY 4.0

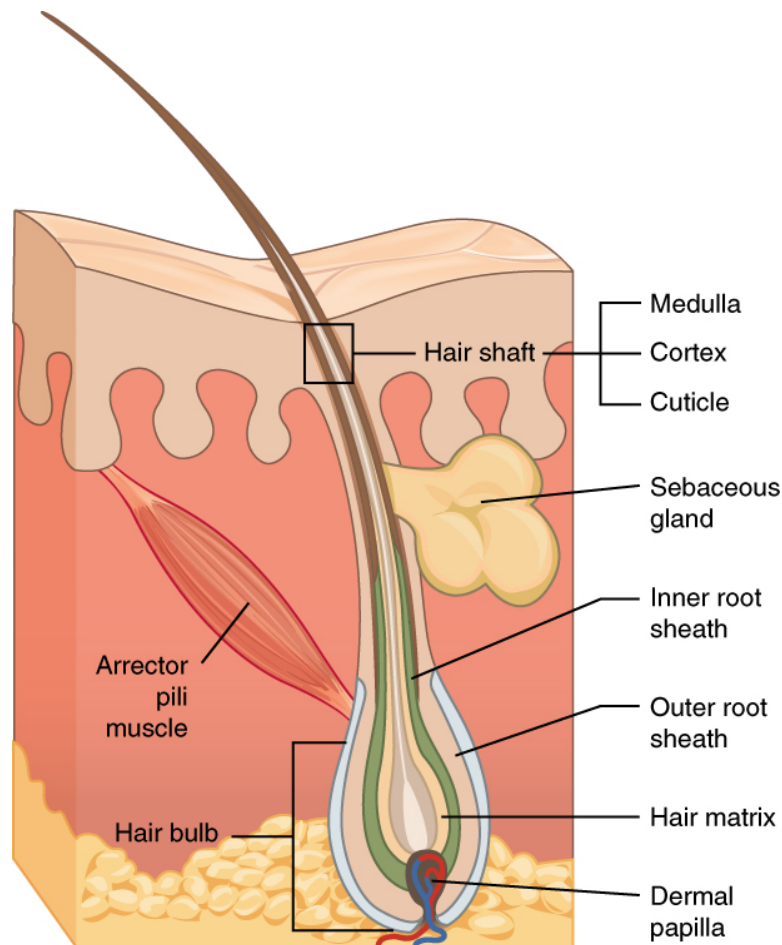


Figure 3.2 Hair

Hair serves a variety of functions, including protection, sensory input, thermoregulation, and communication. For example, hair in the nose and ears and around the eyes (eyelashes) defends the body by trapping and excluding dust particles that may contain allergens and microbes.⁸

Hair grows and is eventually shed and replaced by new hair. Hair loss occurs if there is more hair shed than what is replaced and can happen due to hormonal or dietary changes. Hair loss can also result from the aging process

8. This work is a derivative of [Anatomy and Physiology](https://openstax.org/books/anatomy-and-physiology/pages/1-introduction) by [OpenStax](https://openstax.org/books/anatomy-and-physiology/pages/1-introduction) licensed under [CC BY 4.0](https://creativecommons.org/licenses/by/4.0/). Access for free at <https://openstax.org/books/anatomy-and-physiology/pages/1-introduction>

or the influence of hormones. **Alopecia** (ăl-ō-PĒ-shē-ă) is the medical term for hair loss in areas where hair normally grows. Conversely, **hirsutism** (HUR-sū-tīz-əm) is the medical term for excessive hair growth in areas where hair is usually minimal or absent.

Similar to the skin, hair gets its color from the pigment melanin, and different hair color results from differences in the type of melanin. As a person ages, the melanin production decreases, and hair tends to lose its color and becomes gray and/or white.⁹

Dandruff (DĂN-drŭf) refers to flakes of dead skin from the scalp.

Nails

The nail bed is a specialized structure of the epidermis that is found at the tips of the fingers and toes. The nail body is formed on the nail bed and protects the tips of our fingers and toes as they are the farthest extremities and the parts of the body that experience the maximum mechanical stress. The term **cuticle** (KYŪ-tī-kĭl) refers to the protective layer of skin at the base of a nail.¹⁰ See Figure 3.3¹¹ for an illustration of nails.

The nail body is composed of densely packed dead keratinocytes. The nail body forms a back support for picking up small objects with the fingers. The nail bed is rich in blood vessels, making it appear pink, except at the base,

9. This work is a derivative of [Anatomy and Physiology](#) by [OpenStax](#) licensed under [CC BY 4.0](#). Access for free at <https://openstax.org/books/anatomy-and-physiology/pages/1-introduction>
10. This work is a derivative of [Anatomy and Physiology](#) by [OpenStax](#) licensed under [CC BY 4.0](#). Access for free at <https://openstax.org/books/anatomy-and-physiology/pages/1-introduction>
11. [“507_Nails.jpg”](#) by OpenStax is licensed under [CC BY 4.0](#)

where a thick layer of epithelium over the nail matrix forms a crescent-shaped region called the lunula.¹²

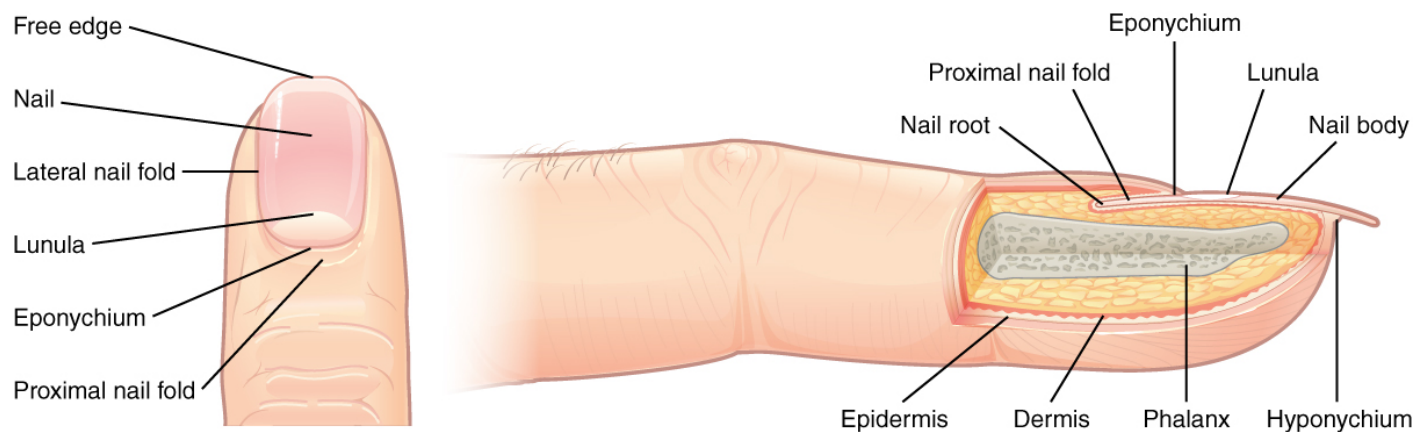


Figure 3.3 Nails

Onycholysis (ŏn-ĭ-KOL-ĭ-sĭs) refers to the separation of a fingernail or toenail from its nail bed. **Onychophagia** (ŏn-ĭ-KOF-ă-jĕ-ă) refers to the habit of biting one's nails.

Sweat Glands

When the body becomes warm, sweat glands produce sweat to cool the body. There are two types of sweat glands called eccrine sweat glands and apocrine sweat glands, each secreting slightly different products.

An **eccrine sweat gland** (ĔK-rĭn swĕt glănd) is type of gland that produces sweat for thermoregulation, as previously described in this section. These glands are found all over the skin's surface but are especially abundant on the palms of the hand, the soles of the feet, and the forehead. This type of sweat is

12. This work is a derivative of [Anatomy and Physiology](#) by [OpenStax](#) licensed under [CC BY 4.0](#). Access for free at <https://openstax.org/books/anatomy-and-physiology/pages/1-introduction>

composed mostly of water and some salt.¹³ See Figure 3.4¹⁴ for an illustration of an eccrine sweat gland.

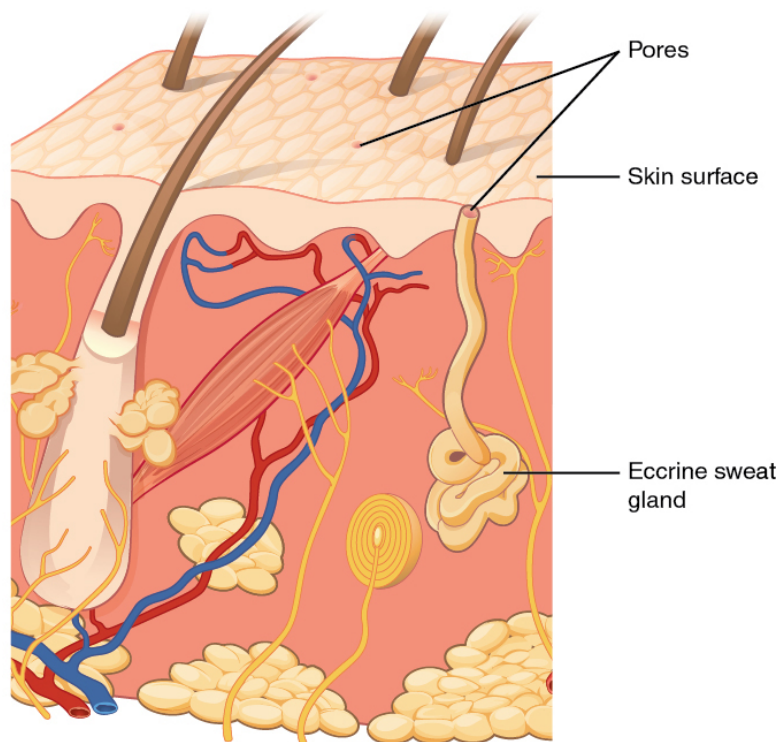


Figure 3.4 Eccrine Gland

Apocrine sweat glands (AP-ō-krĕn swĕt glānds) are found in hair follicles in densely hairy areas, such as the armpits and genital regions. In addition to water and salt, apocrine sweat glands release organic compounds that make the sweat thicker and subject to bacterial decomposition, resulting in odor. The release of apocrine sweat is controlled by hormones and the nervous system. Most commercial antiperspirants use an aluminum-based compound

¹³. This work is a derivative of [Anatomy and Physiology](#) by [OpenStax](#) licensed under [CC BY 4.0](#). Access for free at <https://openstax.org/books/anatomy-and-physiology/pages/1-introduction>

¹⁴. “[508_Eccrine_gland.jpg](#)” by OpenStax is licensed under [CC BY 4.0](#)

as their primary active ingredient to stop sweat. When the antiperspirant enters the sweat gland duct, the aluminum-based compounds physically block the duct and prevent sweat from coming out of the pore.¹⁵

Anhidrosis (ăn-hī-DRŌ-sīs) is the medical term used for the absence of sweat production. **Hyperhidrosis** (hī-pěr-hī-DRŌ-sīs) is the medical term used for excessive sweating.

Sebaceous Glands

A **sebaceous gland** (sē-BĀ-shŭs glănd) is a type of oil gland that lubricates and waterproofs the skin and hair. Most sebaceous glands are associated with hair follicles. They generate and excrete sebum, a mixture of lipids, onto the skin surface, thereby naturally lubricating the dry and dead layer of keratinized cells. The fatty acids of sebum also have antibacterial properties and prevent water loss from the skin in low humidity environments. The secretion of sebum is stimulated by hormones, many of which do not become active until puberty. Thus, sebaceous glands are relatively inactive during childhood.¹⁶

15. This work is a derivative of [Anatomy and Physiology](https://openstax.org/books/anatomy-and-physiology/pages/1-introduction) by [OpenStax](https://openstax.org/books/anatomy-and-physiology/pages/1-introduction) licensed under [CC BY 4.0](https://creativecommons.org/licenses/by/4.0/). Access for free at <https://openstax.org/books/anatomy-and-physiology/pages/1-introduction>

16. This work is a derivative of [Anatomy and Physiology](https://openstax.org/books/anatomy-and-physiology/pages/1-introduction) by [OpenStax](https://openstax.org/books/anatomy-and-physiology/pages/1-introduction) licensed under [CC BY 4.0](https://creativecommons.org/licenses/by/4.0/). Access for free at <https://openstax.org/books/anatomy-and-physiology/pages/1-introduction>

PHYSIOLOGY OF THE INTEGUMENTARY SYSTEM

The skin and accessory structures perform a variety of these essential functions¹⁷:

- Protecting the body from invasion by microorganisms, chemicals, and other environmental factors
- Acting as a sensory organ
- Modulating body temperature and electrolyte balance
- Synthesizing vitamin D

Protection

The skin protects the body from wind, water, and ultraviolet (UV) light. It acts as a protective barrier against excessive water loss referred to as **dehydration** (dē-hī-DRĀ-shŏn). It is also the first line of defense against abrasive activity such as grit, microbes, or harmful chemicals. Sweat excreted from sweat glands also deters microbes from overcolonizing the skin surface.¹⁸

Sensory Function

The epidermis, dermis, and the hypodermis contain specialized sensory nerve

17. This work is a derivative of [Anatomy and Physiology](#) by [OpenStax](#) licensed under [CC BY 4.0](#). Access for free at <https://openstax.org/books/anatomy-and-physiology/pages/1-introduction>

18. This work is a derivative of [Anatomy and Physiology](#) by [OpenStax](#) licensed under [CC BY 4.0](#). Access for free at <https://openstax.org/books/anatomy-and-physiology/pages/1-introduction>

structures that detect touch, surface temperature, and pain. These receptors are concentrated on the tips of the fingers, which are very sensitive to touch.¹⁹

Thermoregulation

The integumentary system helps regulate body temperature in association with the sympathetic nervous system. The sympathetic nervous system is continuously monitoring body temperature and initiating appropriate motor responses.²⁰

When the body becomes excessively warm, sweat glands secrete water, salt, and other substances to cool the body. Even when the body does not appear to be noticeably sweating, approximately 500 mL of sweat are secreted a day. This amount can greatly vary depending on the person's metabolic rate, physical activity, heat exposure, and medical condition. When the sweat evaporates from the skin surface, the body is cooled as body heat is dissipated. In addition to sweating, small blood vessels called arterioles in the dermis dilate so that excess heat carried by the blood can dissipate through the skin and into the surrounding environment.²¹

When body temperatures drop, the arterioles constrict to minimize heat loss, particularly in the ends of the fingers and toes and the tip of the nose. This constriction reduces blood flow to the skin to prevent the loss of heat and keep the internal organs warm. It can cause the skin to take on a whitish hue.

19. This work is a derivative of [Anatomy and Physiology](https://openstax.org/books/anatomy-and-physiology) by [OpenStax](https://openstax.org) licensed under [CC BY 4.0](https://creativecommons.org/licenses/by/4.0/). Access for free at <https://openstax.org/books/anatomy-and-physiology/pages/1-introduction>
20. This work is a derivative of [Anatomy and Physiology](https://openstax.org/books/anatomy-and-physiology) by [OpenStax](https://openstax.org) licensed under [CC BY 4.0](https://creativecommons.org/licenses/by/4.0/). Access for free at <https://openstax.org/books/anatomy-and-physiology/pages/1-introduction>
21. This work is a derivative of [Anatomy and Physiology](https://openstax.org/books/anatomy-and-physiology) by [OpenStax](https://openstax.org) licensed under [CC BY 4.0](https://creativecommons.org/licenses/by/4.0/). Access for free at <https://openstax.org/books/anatomy-and-physiology/pages/1-introduction>

If the temperature of the skin drops too much (such as in environmental temperatures below freezing), the conservation of body core heat can result in **frostbite** (FROST-bīt).²² See Figure 3.5²³ for illustrations demonstrating thermoregulation.

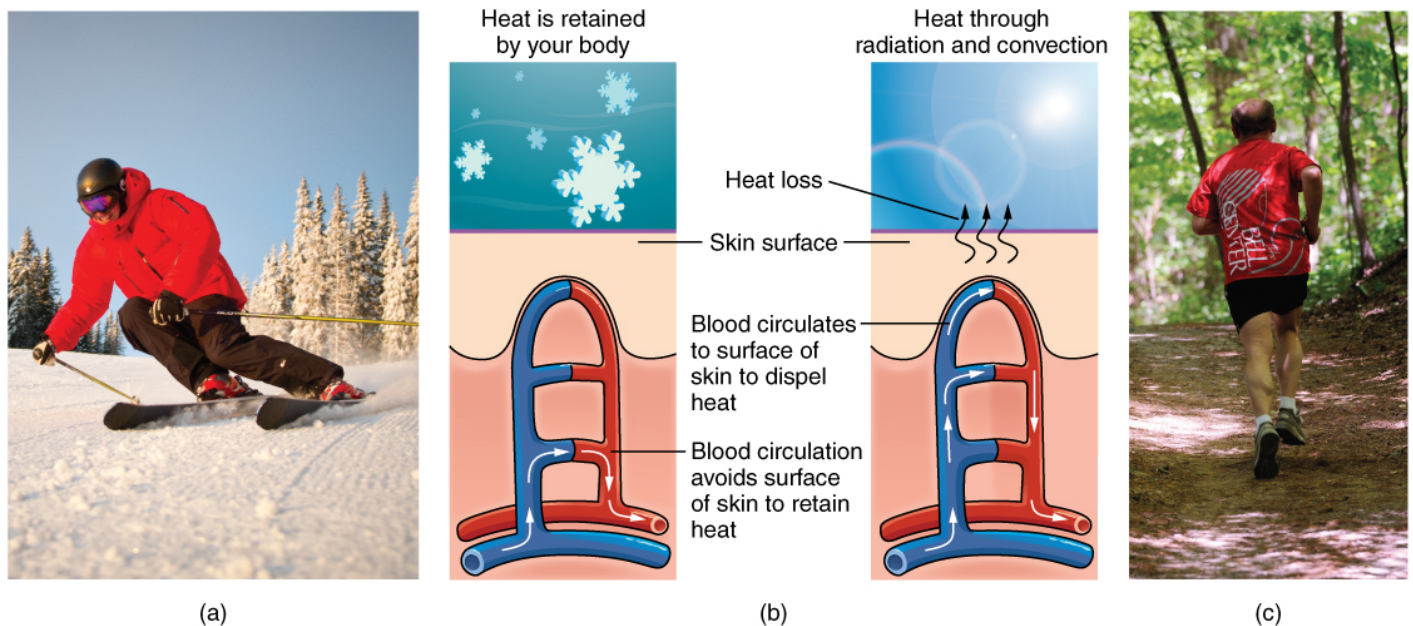


Figure 3.5 Thermoregulation

Medical conditions can cause excessive, profuse sweating referred to as **diaphoresis** (dī-ă-fō-RĒ-sīs). For example, a significant symptom of a heart attack, in addition to chest pain, is diaphoresis.

Vitamin D Synthesis

The epidermal layer synthesizes vitamin D when exposed to UV light. Vitamin

22. This work is a derivative of [Anatomy and Physiology](#) by [OpenStax](#) licensed under [CC BY 4.0](#). Access for free at <https://openstax.org/books/anatomy-and-physiology/pages/1-introduction>

23. "515_Thermoregulation.jpg" by OpenStax is licensed under [CC BY 4.0](#)

D is essential for normal absorption of calcium and phosphorous, which are required for healthy bones. In addition to its essential role in bone health, vitamin D is essential for general immunity against bacterial, viral, and fungal infections. Significant absence of sun exposure can lead to a lack of vitamin D in the body called **rickets** (RIK-ěts). For this reason, vitamin D is added as a supplement to many foods, including milk and orange juice.²⁴

CHANGES IN THE INTEGUMENTARY SYSTEM DUE TO AGING

All body systems change as a person ages. In the skin, older adults develop a thinner epidermis. Additionally, the dermis, responsible for the elasticity and resilience of the skin, exhibits a reduced ability to regenerate, which leads to slower wound healing. The hypodermis, with its fat stores, loses structure due to the reduction and redistribution of fat, which, in turn, contributes to the thinning and sagging of skin.²⁵ See Figure 3.6²⁶ for an illustration of these signs of aging skin.

24. This work is a derivative of [Anatomy and Physiology](#) by [OpenStax](#) licensed under [CC BY 4.0](#). Access for free at <https://openstax.org/books/anatomy-and-physiology/pages/1-introduction>

25. This work is a derivative of [Anatomy and Physiology](#) by [OpenStax](#) licensed under [CC BY 4.0](#). Access for free at <https://openstax.org/books/anatomy-and-physiology/pages/1-introduction>

26. “516_Aging.jpg” by OpenStax is licensed under [CC BY 4.0](#)



Figure 3.6 Signs of Aging Skin

The accessory structures also have lowered activity, generating thinner hair and nails and reduced amounts of sebum and sweat. A reduced sweating ability creates a risk for older adults in extreme heat. Other cells in the skin, such as melanocytes and dendritic cells, also become less active, leading to a paler skin tone and lowered immunity.²⁷



View the following supplementary YouTube video²⁸ to

27. This work is a derivative of [Anatomy and Physiology](#) by [OpenStax](#) licensed under [CC BY 4.0](#). Access for free at <https://openstax.org/books/anatomy-and-physiology/pages/1-introduction>

28. CrashCourse. (2015, February 16). *The integumentary system, Part 2* –

review the anatomy and physiology of the integumentary system: The Integumentary System, Part 2 – Skin Deeper: Crash Course A&P #7

Skin deeper: Crash Course Anatomy & Physiology #7 [Video]. YouTube. All rights reserved. <https://www.youtube.com/watch?v=EN-x-zXXVwQ>

3.5 Diseases, Disorders, and Injuries of the Integumentary System

This section will provide a general overview of diseases, disorders, and injuries of the integumentary system.¹

ACNE

Acne (AK-nē) is a skin condition characterized by inflamed or infected sebaceous glands in the skin, particularly on the face and back. Sebaceous glands (oil glands) produce sebum (an oily substance). An accumulation of sebum and keratin blocks hair follicles, resulting in acne. Acne is common

1. Unless otherwise indicated, this chapter contains material adapted from [Anatomy and Physiology](#) (on [OpenStax](#)), by Betts, et al. and is used under a [CC BY 4.0 international license](#). Download and access this book for free at <https://openstax.org/books/anatomy-and-physiology/pages/1-introduction>

during puberty due to associated hormonal changes. Severe acne can cause scarring.² See Figure 3.7³ for an image of acne.

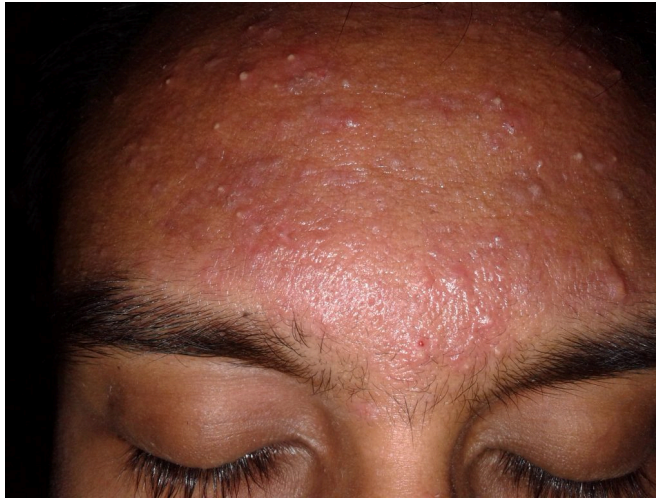

Figure 3.7 Acne

BENIGN GROWTHS

Benign (bē-NĪN) growths or tumors are not cancerous and do not spread to other parts of the body like cancer does, but they may require removal. Examples of benign tumors in the integumentary system are **dermatofibroma** (dĕr-mă-tō-fī-BRŌ-mă), a firm, nodular growth on the skin, and **lipoma** (lī-PŌ-mă), a fatty tissue tumor.

2. This work is a derivative of [Anatomy & Physiology](#) by [OpenStax](#) and is licensed under [CC BY 4.0](#). Access for free at <https://openstax.org/books/anatomy-and-physiology/pages/1-introduction>
3. [“Acne vulgaris on a very oily skin.jpg”](#) by [Roshu Bangal](#) is licensed under [CC BY-SA 4.0](#)

BURNS

A **burn** (bûrn) results when the skin is damaged by intense heat, radiation, electricity, or chemicals. Burns can lead to a massive fluid loss due to loss of protection against dehydration by the skin. Burned skin is also extremely susceptible to infection due to the loss of protection against pathogens by the skin.

Burns were traditionally classified by their degree of severity as first-degree, second-degree, third-degree, and fourth-degree burns. This historic classification of burns has been replaced by a system reflecting the need for surgical intervention. They are referred to as superficial, superficial partial-thickness, deep partial-thickness, and full-thickness burns:

- A **first-degree burn**, now referred to as a superficial burn, only affects the epidermis. Although the skin may be painful and swollen, these burns typically heal on their own within a few days. Mild sunburn fits into the category of a first-degree burn.
- A **second-degree burn**, now referred to as a partial thickness burn, affects both the epidermis and a portion of the dermis. These burns result in swelling and a painful blistering of the skin. It is important to keep the burn site clean to prevent infection. With good care, a second-degree burn will heal within several weeks.
- A **third-degree burn**, now referred to as a full-thickness burn, extends fully into the epidermis and dermis, destroying the tissue and affecting the nerve endings and sensory function. These are serious burns that require immediate medical attention.
- A **fourth-degree burn**, now referred to as a deep full-thickness burn, is even more severe, affecting the underlying muscle and bone.

Full-thickness burns require **debridement** (di-BRĒD-měnt), surgical removal of dead tissue, followed by grafting skin from an unaffected part of the body

or from skin grown in tissue culture.⁴ See Figure 3.8⁵ for an image of a patient recovering from a second-degree burn on the hand.

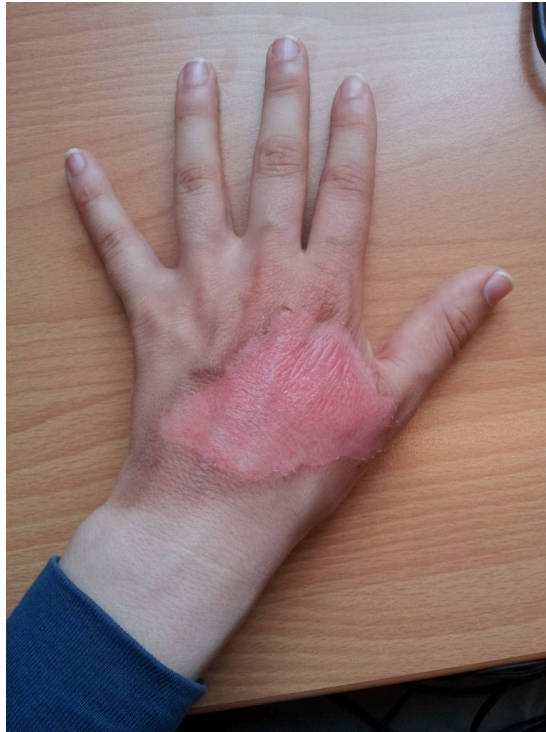

Figure 3.8 Recovering Second-Degree Burn

Severe burns are quickly measured in emergency departments using a tool called the “**Rule of Nines**,” which associates specific anatomical locations with a percentage of the body that is a factor of nine. Rapid estimate of the burned surface area is used to estimate the amount of intravenous fluids needed to

4. This work is a derivative of [Anatomy & Physiology](#) by [OpenStax](#) and is licensed under [CC BY 4.0](#). Access for free at <https://openstax.org/books/anatomy-and-physiology/pages/1-introduction>
5. “[1Veertje hand-burn-do8.jpg](#)” by [1Veertje](#) is licensed under [CC BY-SA 3.0](#)

replace fluid loss.⁶ See Figure 3.9⁷ for an illustration of the Rule of Nines. Using the Rule of Nines, the head is calculated as 9%, the upper limbs are 9% (4.5% on each side), the lower limbs are 18% (9% on each side), and the trunk is 36% (18% on each side), and the perineum/genitalia is 1%.

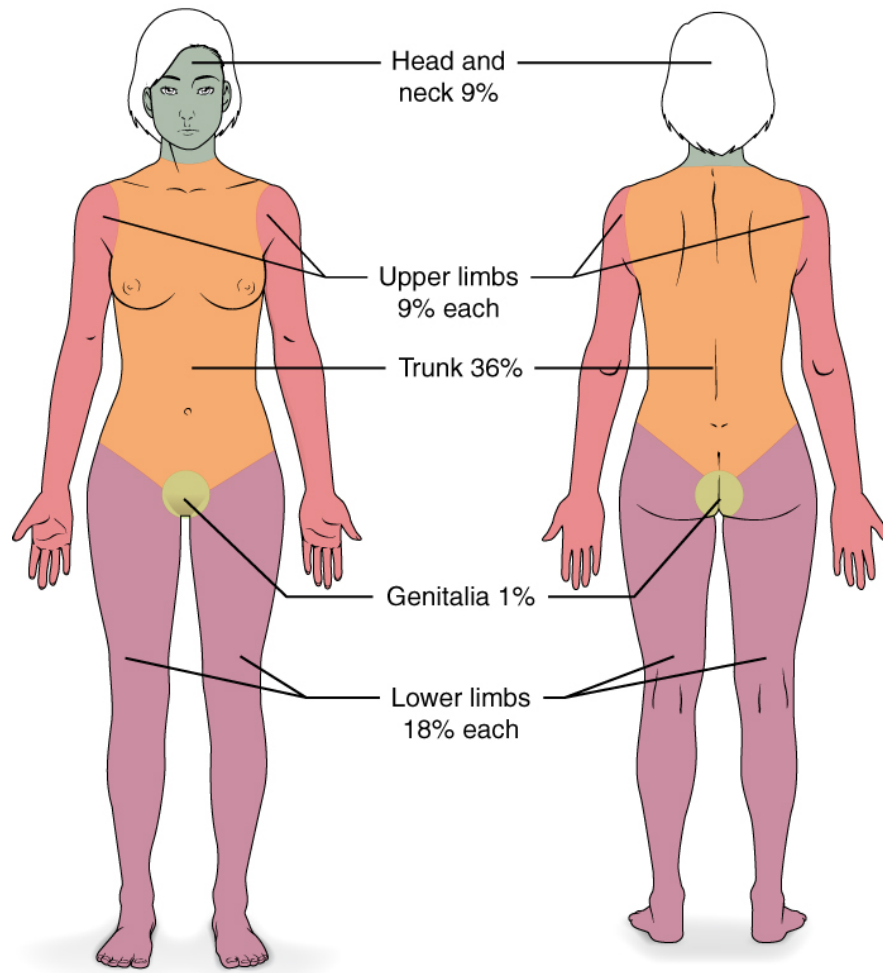


Figure 3.9 Rule of Nines

6. This work is a derivative of [StatPearls](#) by Moore, Waheed, and Burns and is licensed under [CC BY 4.0](#)

7. [“513 Degree of burns.jpg”](#) by [OpenStax](#) is licensed under [CC BY 3.0](#)

ECZEMA

Eczema (eg-ZĒ-mă) is an allergic, inflammatory condition that manifests as dry, itchy patches of skin that resemble a red, flaky rash. It can occur in individuals of all ages. See an image of eczema in Figure 3.10.⁸ Eczema may be accompanied by swelling of the skin, flaking, and, in severe cases, bleeding. Symptoms are usually managed with moisturizers, corticosteroid creams, and immunosuppressant medication.

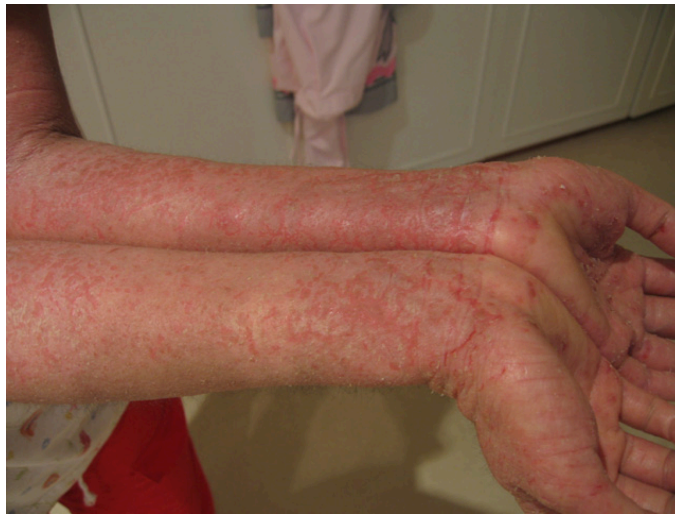

Figure 3.10 Eczema

EDEMA

Edema (ě-DĒ-mă) is caused by fluid accumulation within the tissues often caused by underlying cardiovascular or renal disease. **Lymphedema** (lim-fě-DĒ-mă) is the medical term for a type of swelling that occurs when lymphatic

8. “[Eczema-arms.jpg](#)” by [Jambula](#) at [English Wikipedia](#) is licensed in the [Public Domain](#).

fluid builds up in the body's soft tissues due to damage to the lymph system. It often occurs unilaterally in the arms or legs after surgery has been performed that injured the regional lymph nodes. See Figure 3.11⁹ for an image of lymphedema. Causes of lymphedema include infection, cancer, scar tissue from radiation therapy, surgical removal of lymph nodes, or inherited conditions. There is no cure for lymphedema, but elevation of the affected extremity is vital. Compression devices and massage can help to manage the symptoms.

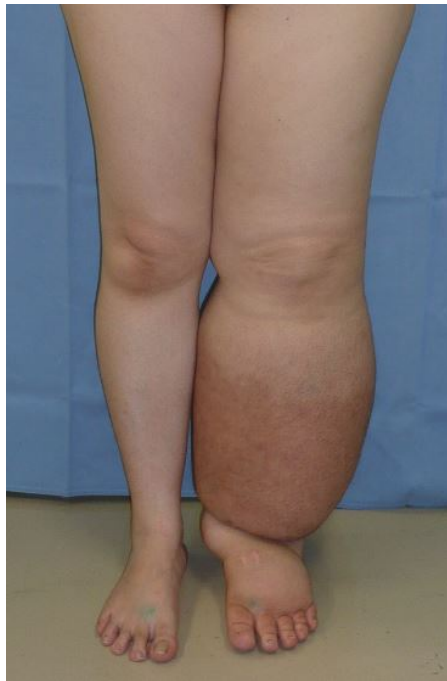

Figure 3.11 Lymphedema

INFECTIONS

An **infection** (in-FEK-shŏn) is caused by the invasion and multiplication of microorganisms in the body, such as **bacteria** (bak-TĒR-ē-a), viruses, fungi,

9. "[Lymphedema_limbs.JPG](#)" by medical doctors is licensed under [CC BY-SA 4.0](#)

and parasites. Microorganisms that cause infection are referred to as **pathogens** (path-Ŏ-jěns).

Bacterial Infections

Bacterial skin infections are commonly caused by **Staphylococcus** (staf-ĭ-lō-KOK-ŭs) or **Streptococcus** (strep-tō-KOK-ŭs) bacteria. **Methicillin-resistant Staphylococcus aureus** (mēth-ĭ-SĪL-ĭn rě-zĭs-tănt STĀF-ə-lō-KŌK-ŭs OWR-ē-ŭs) (**MRSA**) is a staph infection that is resistant to common antibiotics. There are two types of MRSA, referred to as community-acquired and hospital-acquired. **Hospital-acquired MRSA (HA-MRSA)** is diagnosed in people who acquired the infection while in the hospital or other health care setting and undergoing treatment for another medical condition. People in the hospital are at higher risk of becoming infected with MRSA because they often have breaks in their skin due to surgical wounds or intravenous lines (IVs) that allow bacteria to enter. **Community-acquired MRSA (CA-MRSA)** is a MRSA infection that is diagnosed in individuals outside of a hospital setting. It tends to occur in individuals who have had close skin-to-skin contact with another person with CA-MRSA. Different antibiotics are used to effectively treat HA-MRSA and CA-MRSA.

Bacterial infections often cause the development of pus. **Pus** (PŬS) is a thick, opaque yellow or green fluid produced in infected tissue, consisting of dead white blood cells, bacteria, and tissue debris. A **boil** (BOIL) is a painful, pus-filled bump that forms under the skin, often caused by an infected hair follicle. An **abscess** (ĀB-sěs) is a swollen area within body tissue, containing an accumulation of pus.

Impetigo (ĭm-pě-Tĭ-gō) is a contagious bacterial skin infection forming pustules and yellow, crusty sores, typically found in children between the ages of two and six. A **pustule** (PŬS-tŭl) is a small blister or pimple on the skin that contains pus. See Figure 3.12¹⁰ for an image of impetigo. Impetigo often starts when bacteria enter a break in the skin, such as a cut, scratch, or insect bite. Symptoms start with red or pimple-like sores surrounded by red skin. The

10. “[Impetigo2020.jpg](#)” by [James Heilman, MD](#) is licensed under [CC BY-SA 4.0](#)

sores fill with pus and then break open after a few days and form a thick crust. They are often itchy but scratching them can spread the sores. Impetigo can spread by contact with sores or nasal discharge from an infected person and is treated with antibiotics.

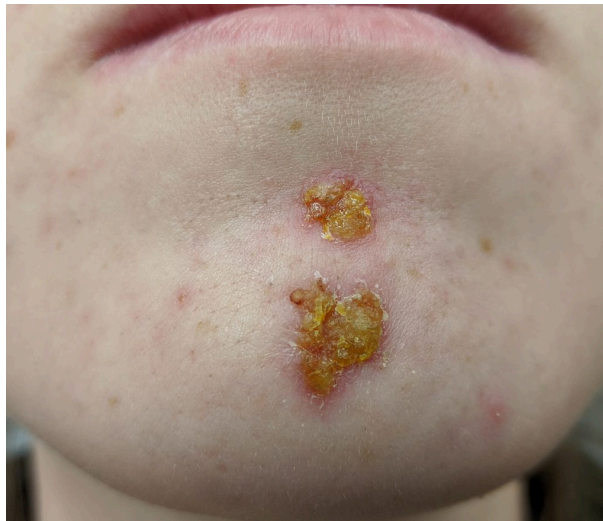

Figure 3.12 Impetigo

Cellulitis (sĕl-yū-Lĭ-tĭs) is a bacterial infection of the skin and subcutaneous tissue, characterized by redness, pain, heat, and swelling. Untreated cellulitis can become severe and spread throughout the body.

Viral Infections

Viruses are contagious and are easily spread among individuals. They can cause several different types of skin infections. A **virus** (Vĭ-rŭs) is a microorganism that spreads infection by invading the body's cells and replicating. For example, a **wart** (WART), also referred to as a **verruca** (vēr-ROO-kă), is a small benign growth on the skin caused by a virus.

Genital warts are caused by **human papillomavirus** (hyū-măn pap-ĭ-lō-mă-Vĭ-rŭs) (**HPV**), the most common sexually transmitted infection in the United States. Genital warts appear as a small bump or group of bumps in the genital or anal area. They can be small or large, raised or flat, or shaped like a cauliflower. In some individuals, HPV can progress to cancer. HPV can cause

cervical, throat, and other cancers. HPV vaccines help prevent some of the health effects HPV causes.¹¹

Shingles (SHING-gĭlz) is a viral disease that causes painful rashes on the skin. Shingles is caused by the varicella-zoster virus, the same virus responsible for chickenpox. A vaccine is available to prevent shingles and is recommended for adults over age 50 or for individuals with compromised immune systems.

Fungal and Yeast Infections

Tinea (TĪ-nē-ă) is the name of a group of skin infections caused by a fungus. These infections are usually not serious, but they can be uncomfortable because of the symptoms of itching and burning. They can be transmitted by touching other people's infected areas, damp surfaces such as shower floors, or even from pets.¹²

Tinea infections are commonly referred to as ringworm, athlete's foot, and jock itch. Ringworm or **tinea corporis** (TĪ-nē-ă KŌR-pŏ-rĭs) is a type of rash that forms on the body that typically looks like a red ring with a clear center, although a worm doesn't cause it. Scalp ringworm or **tinea capitis** (TĪ-nē-ă KĂP-ĭ-tĭs) causes itchy, red patches on the head that can leave bald spots. Athlete's foot or **tinea pedis** (TĪ-nē-ă PĔD-ĭs) causes itching, burning, and cracked skin between the toes. Jock itch or **tinea cruris** (TĪ-nē-ă KRŌŏ-rĭs) causes an itchy, burning rash in the groin area. Fungal infections are often

11. Centers for Disease Prevention and Control. (2022, April 14). *Genital HPV infection – Basic fact sheet*. [https://www.cdc.gov/std/hpv/stdfact-hpv.htm#:~:text=Human%20papillomavirus%20\(HPV\)%20is%20the,answers%20basic%20questions%20about%20HPV](https://www.cdc.gov/std/hpv/stdfact-hpv.htm#:~:text=Human%20papillomavirus%20(HPV)%20is%20the,answers%20basic%20questions%20about%20HPV)
12. MedlinePlus [Internet]. Bethesda (MD): National Library of Medicine (US); [updated 2020, Aug 17]. Tinea infections; [reviewed 2016, Apr 4; cited 2020, Sep 18]. <https://medlineplus.gov/tineainfections.html#:~:text=Tinea%20is%20the%20name%20of,or%20even%20from%20a%20pet>

treated successfully with over-the-counter creams and powders. See Figure 3.13¹³ for an image of a tinea in a patient's groin.¹⁴

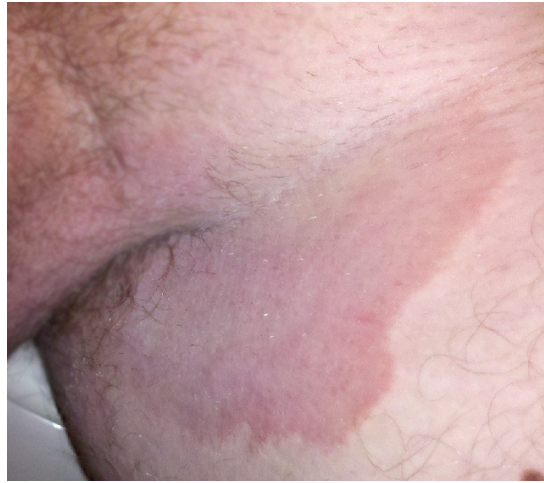

Figure 3.13 Fungal Infection in the Groin

Fungal infections of nails are referred to as **onychomycosis** (ŏn-ī-kō-mī-KŌ-sīs).

Yeast infections (YĒST ĭn-FĕK-shŭns) are commonly caused by *Candida*, a type of fungus. *Candida* normally lives on people's skin and inside their body without causing problems. However, *Candida* can cause yeast infections if it grows out of control. It can be caused by antibiotics that kill the normal flora on the skin or by diseases that reduce an individual's immune response.

13. "Tinea cruris.jpg" by [Robertgascoin](#) is licensed under [CC BY-SA 3.0](#)

14. MedlinePlus [Internet]. Bethesda (MD): National Library of Medicine (US); [updated 2020, Aug 17]. Tinea infections; [reviewed 2016, Apr 4; cited 2020, Sep 18]. <https://medlineplus.gov/tineainfections.html#:~:text=Tinea%20is%20the%20name%20of,or%20even%20from%20a%20pet>

- ▶ Read additional information about tinea at the [Centers for Disease Control and Prevention's web page on fungal infections](#).

Lice

Head lice are tiny insects that live on a person's head. **Pediculosis** (pěd-ĭ-kū-LŌ-sĭs) refers to a lice infection/infestation. Adult lice are about the size of a sesame seed, but the eggs, called nits, are smaller and can appear like a dandruff flake. See Figure 3.14¹⁵ for an image of very small white nits in a person's hair.

Children ages 3-11 often get head lice at school or daycare because they have head-to-head contact while playing together. Lice move by crawling and spread by close person-to-person contact. Rarely, they can spread by sharing personal belongings such as hats or hairbrushes. Contrary to popular belief, personal hygiene and cleanliness have nothing to do with getting head lice. Symptoms of head lice include the following:

- Tickling feeling in the hair
- **Pruritus** (prū-RĪ-tŭs) or severe itching caused by an allergic reaction to the bites
- Sores from scratching, which can become infected with bacteria
- Trouble sleeping due to head lice being most active in the dark

Head lice are diagnosed after the observation of one live louse on a person's head. Because they are very small and move quickly, a magnifying lens and a fine-toothed comb may be needed to find lice or nits. Treatments for head

15. "Fig.5. Louse nites.jpg" by [KostaMumcuoglu](#) at [English Wikipedia](#) is licensed under [CC BY-SA 3.0](#)

lice include over-the-counter and prescription shampoos, creams, and lotions such as permethrin lotion.¹⁶



Figure 3.14 Nits

Scabies

Scabies (SKĀ-bēz) is an infection caused by tiny mites that burrow into the skin, leading to intense pruritis (itching).

INJURIES

There are many types of injuries that can occur to the skin:

¹⁶. MedlinePlus [Internet]. Bethesda (MD): National Library of Medicine (US); [updated 2020, Aug 17]. Head lice; [reviewed 2016, Sep 9; cited 2020, Sep 18]. <https://medlineplus.gov/headlice.html>

- An **abrasion** (ă-BRĀ-zhŏn) is an area of skin damaged by scraping or wearing away. See Figure 3.15¹⁷ for an image of an abrasion.
- A **blister** (BLIS-tĕr) is a raised portion of the skin in which the epidermis becomes lifted up off the dermis and is filled with fluid. Blisters are typically caused by friction, burns, or other damage.
- A **bullā** (BOO-la) is a large blister.
- A **bruise** (BRŪZ), also referred to as a **contusion** (kŏn-TOO-zhŏn), is an injury appearing as an area of discolored skin on the body, caused by a blow or impact rupturing underlying blood vessels.
- A **laceration** (las-ĕ-RĀ-shŏn) is a deep cut or tear in skin and/or tissue.
- A skin **ulcer** (UL-sĕr) is an open sore on the body that is often slow to heal and prone to infection. There are many potential causes of ulcers, such as pressure injuries and lack of blood flow from diabetes.
- **Calluses** (KĀL-ŭ-ses) are thick, hardened layers of skin that develop when the skin tries to protect itself against friction or pressure. For example, calluses can often form on fingers if they are subjected to constant mechanical stress, such as long periods of writing with a pencil or playing string instruments. A **corn** is a specialized form of callus that develops on the tops and sides of toes and can be painful.

¹⁷. “[Abrasion wound on arm.jpg](#)” by [ProjectManhattan](#) is licensed under [CC BY-SA 3.0](#)

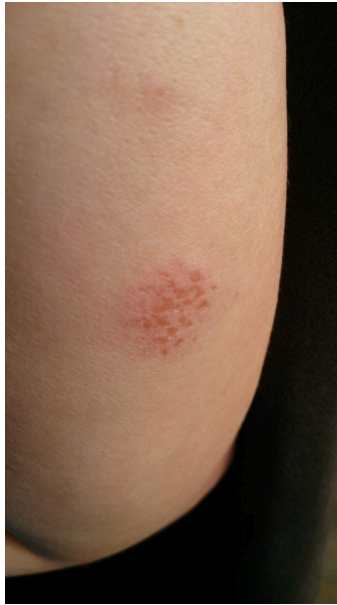

Figure 3.15 Abrasion

Pressure Injuries

Pressure injuries, formerly referred to as pressure ulcers or bedsores, form when a patient's skin and soft tissue press against a hard surface for a prolonged period of time. The pressure against a hard surface reduces blood supply to that area, causing damage to the skin tissue and possible ulcers. Patients are at high risk of developing a pressure injury if they spend a lot of time in one position without moving or have decreased sensation, poor nutrition, or bladder or bowel leakage.¹⁸ See Figure 3.16¹⁹ for an image of a pressure ulcer injury on the back of a patient who is bed-bound due to chronic illness. Pressure injuries are most common in patients who have debilitating conditions that cause them to be immobile. Nurses and other

¹⁸. A.D.A.M. Medical Encyclopedia [Internet]. Atlanta (GA): A.D.A.M., Inc.; c1997-2020. Preventing pressure ulcers; [updated 2020, Sep 16; cited 2020, Sep 18]. <https://medlineplus.gov/ency/patientinstructions/000147.htm>

¹⁹. “Decubitus 01.jpg” by AfroBrazilian is licensed under [CC BY-SA 3.0](https://creativecommons.org/licenses/by-sa/3.0/)

health care professionals reposition immobile patients every few hours to prevent the formation of pressure injuries.

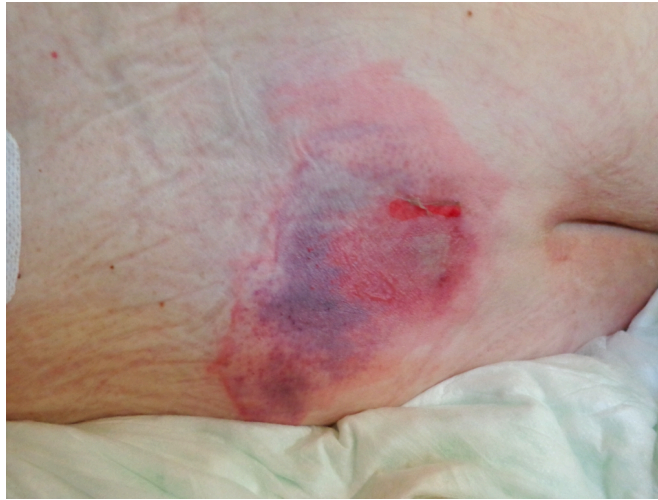


Figure 3.16 Pressure Ulcer Injury

- ▶ For additional information and images of pressure injuries, go to the “[Pressure Injuries](#)” section of the “Integumentary” chapter in *Open RN Nursing Fundamentals*.

PSORIASIS

Psoriasis (sō-Rĭ-ə-sĭs) is a skin condition marked by red, itchy, scaly patches found on the elbows, knees, scalp, low back, face, feet, fingernails, toenails,

and even the mouth. Treatments may include creams, ointments, ultraviolet light therapy, and medication.²⁰

RASHES

A **rash** is an area of redness and small spots appearing on the skin due to allergy or illness. There are different types of rashes that may occur, each with different appearances and causes. Terms used to describe rashes include the following:

- **Macule** (MAK-ūl): A flat, discolored spot on the skin.
- **Papule** (PAP-ūl): A small, raised, solid bump.
- **Vesicle** (VES-ĭ-kĭl): A small, fluid-filled sac or blister within or under the epidermis.
- **Urticaria** (ur-tĭ-KĀR-ē-ă): Raised, itchy welts on the skin, also known as hives. A **wheal** refers to an individual hive.

Dermatitis (dûr-mă-Tĭ-tĭs) is inflammation of the skin that can cause a rash. A common type of dermatitis is called contact dermatitis, caused by contact with a substance that causes an allergic reaction. For example, allergic skin reactions caused by latex allergy or poison ivy are examples of contact dermatitis. **Dermatoconiosis** (dûr-mă-tō-kō-nē-Ō-sĭs) is a type of dermatitis caused by dust contacting the skin.

Systemic lupus erythematosus (sis-TĔM-ik LOO-pŭs ěr-i-thē-mă-TO-sŭs) (**SLE**), commonly referred to as **lupus** (LOO-pŭs), is an autoimmune disease in which the immune system recognizes its own cell antigens as being “non-self” and mounts an immune response against them. As a result, skin, body

20. Centers for Disease Control and Prevention. (2018, October 25). *Psoriasis*. Centers for Disease Control and Prevention: Fungal Diseases. <https://www.cdc.gov/psoriasis/>

tissues, and vital organs become chronically inflamed and damaged. A common sign of lupus is a facial rash that resembles the wings of a butterfly unfolding across both cheeks. See Figure 3.17²¹ for an image of a butterfly rash associated with lupus.

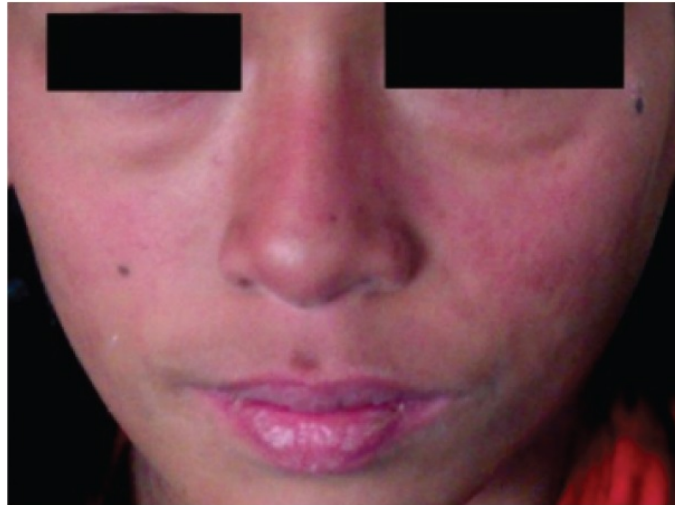


Figure 3.17 Butterfly Rash Associated With Lupus

Petechiae (pě-TĒK-ē-ī) are tiny red dots that can be mistaken as a rash but are actually caused by bleeding under the skin. Large petechiae are called **purpura** (PUR-pyöŏ-ră). An easy method used to assess for petechiae is to apply pressure to the rash with a gloved finger. A rash will blanch (i.e., whiten with pressure), but petechiae and purpura do not blanch. See Figure 3.18²² for an image of petechiae and purpura. New onset of petechiae should be

21. "[Butterfly_rash_of_lupus_erythematosus.jpg](#)" by CNX OpenStax is licensed under [CC BY 4.0](#)

22. "[Purpura.jpg](#)" by [User:Hektor](#) is licensed under [CC BY-SA 3.0](#)

immediately reported to a health care provider because it can indicate a serious underlying medical condition.²³

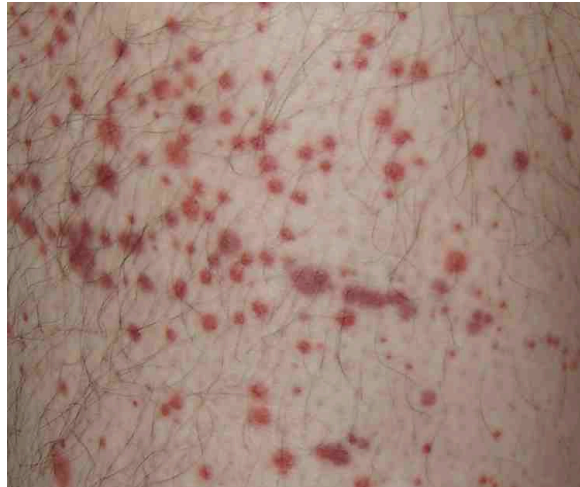

Figure 3.18 Petechiae and Purpura Can Be Mistaken For a Rash

SCARS AND KELOIDS

A **scar** (skär) is a mark left on the skin where an injury, wound, or burn did not completely heal, resulting in collagen-rich fibrous connective tissue formation. Modern cosmetic procedures, such as dermabrasion, laser treatments, and filler injections are used to treat severe scarring. These procedures reorganize the structure of the epidermis and the underlying collagen tissue to make it look more natural.

In some individuals, an overproduction of scar tissue occurs when the process of collagen formation does not stop after the wound is healed. This

23. A.D.A.M. Medical Encyclopedia [Internet]. Atlanta (GA): A.D.A.M., Inc.; c1997-2020. Bleeding into the skin; [updated 2020, Sep 16; cited 2020, Sep 18]. <https://medlineplus.gov/ency/article/003235.htm>

overproduction causes a raised scar called a **keloid** (KĒ-loyd).²⁴ Keloids are more common in patients with darker skin color. See Figure 3.19²⁵ for an image of a keloid that has developed from a scar on a patient's chest wall.

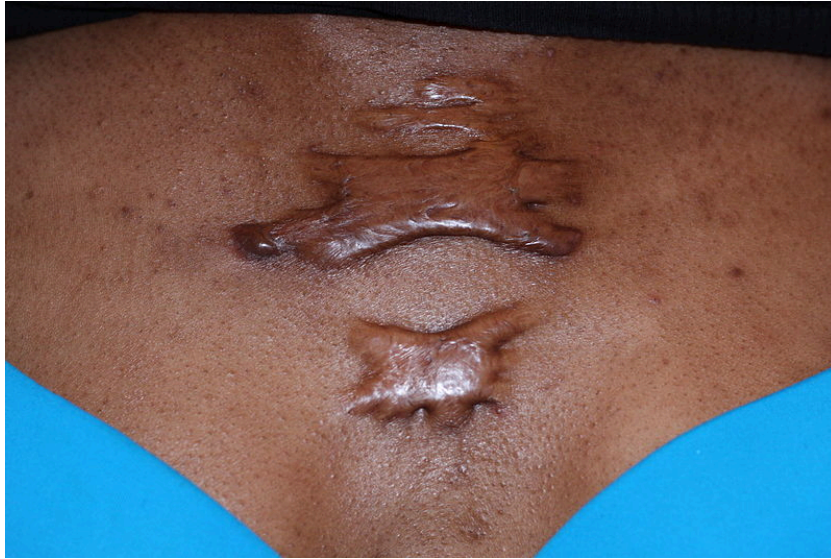

Figure 3.19 Keloid

SKIN CANCER

Skin cancer is common, with one in five Americans experiencing some type of skin cancer in their lifetime. **Basal cell carcinoma** (BĀ-sāl sel kar-sĭn-Ō-ma) is the most common of all cancers that occur in the United States and is frequently found on areas most susceptible to long-term sun exposure such as the head, neck, arms, and back. Basal cell carcinomas start in the

24. This work is a derivative of [Anatomy & Physiology](#) by [OpenStax](#) and is licensed under [CC BY 4.0](#). Access for free at <https://openstax.org/books/anatomy-and-physiology/pages/1-introduction>

25. "[Keloid-Butterfly, Chest Wall.JPG](#)" by [Htirgan](#) is licensed under [CC BY-SA 3.0](#)

epidermis and become an uneven patch, bump, growth, or scar on the skin surface. Treatment options include surgery, cryosurgery, and topical ointments.²⁶

Squamous cell carcinoma (SKWĀ-mŭs sel kar-sĭn-Ō-mă) presents as lesions commonly found on the scalp, ears, and hands. If not removed, squamous cell carcinomas can **metastasize** (mě-TĂS-tă-sĭz) to other parts of the body. Surgery and radiation are used to cure squamous cell carcinoma. See Figure 3.20²⁷ for an image of squamous cell carcinoma.²⁸

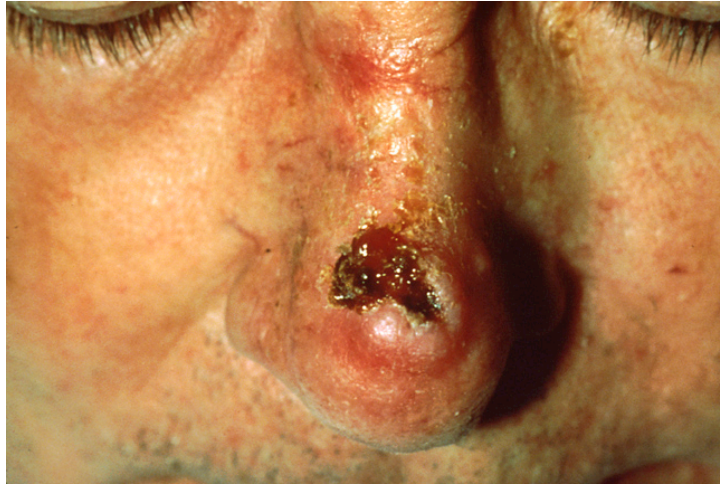

Figure 3.20 Squamous Cell Carcinoma

26. This work is a derivative of *Anatomy & Physiology* by OpenStax and is licensed under CC BY 4.0. Access for free at <https://openstax.org/books/anatomy-and-physiology/pages/1-introduction>
27. “Squamous cell carcinoma (3).jpg” by unknown photographer, provided by National Cancer Institute is licensed under CC0. Access for free at <https://openstax.org/books/anatomy-and-physiology/pages/5-4-diseases-disorders-and-injuries-of-the-integumentary-system>
28. This work is a derivative of *Anatomy & Physiology* by OpenStax and is licensed under CC BY 4.0. Access for free at <https://openstax.org/books/anatomy-and-physiology/pages/1-introduction>

Melanoma (mel-ă-NŌ-mă) is skin cancer caused by the uncontrolled growth of melanocytes, the pigment-producing cells in the epidermis. Melanoma commonly develops from an existing mole that becomes abnormal. A **mole** (MŌL) is a small, dark, benign skin growth. See Figure 3.21²⁹ for an image of a melanoma.

Individuals are encouraged to evaluate moles with an unusual appearance using the “ABCDE” rule that describes the features of early melanoma. These are the features:

- **Asymmetry:** The shape of one half does not match the other half.
- **Border:** The border is irregular, meaning the edges are ragged, notched, or blurred. The pigment may spread into the surrounding skin.
- **Color:** There is uneven color with different shades of black, brown, and tan. Areas of white, gray, red, pink, or blue may also be seen.
- **Diameter:** There is an increased change in the size of the mole. Most melanomas are larger than six millimeters wide (about 1/4 inch).
- **Evolving:** The mole has changed over the past few weeks or months.

Melanoma is the most fatal of all skin cancers because it is highly metastatic and can be difficult to detect before it has spread to other organs. Common treatments include Moh’s surgery and immunotherapy.³⁰ During **Mohs surgery** (MŌZ SŪR-jěr-ē), the surgeon removes thin layers of skin one layer at a time and examines each layer under a microscope to determine if any

29. “[Melanoma \(2\).jpg](#)” by unknown photographer, provided by [National Cancer Institute](#) is in the [Public Domain](#). Access for free at <https://openstax.org/books/anatomy-and-physiology/pages/5-4-diseases-disorders-and-injuries-of-the-integumentary-system>

30. This work is a derivative of [Anatomy & Physiology](#) by [OpenStax](#) and is licensed under [CC BY 4.0](#). Access for free at <https://openstax.org/books/anatomy-and-physiology/pages/1-introduction>

cancer remains. This procedure continues until only cancer-free tissue remains.³¹

- ▶ For additional information about Mohs surgery, visit the Skin Cancer Foundation's site on Mohs surgery.³²

31. John's Hopkins Medicine. (n.d.). *Moh's surgery*.

<https://www.hopkinsmedicine.org/health/conditions-and-diseases/mohs-surgery>

32. Mayo Clinic Staff. (2022, August 23). *Mohs surgery*. Mayo

Clinic. <https://www.mayoclinic.org/tests-procedures/mohs-surgery/about/>

[pac-20385222#:~:text=Mohs%20surgery%20is%20a%20precise,known%20as%20Mohs%20micrographic%20surgery](https://www.mayoclinic.org/tests-procedures/mohs-surgery/about/pac-20385222#:~:text=Mohs%20surgery%20is%20a%20precise,known%20as%20Mohs%20micrographic%20surgery)

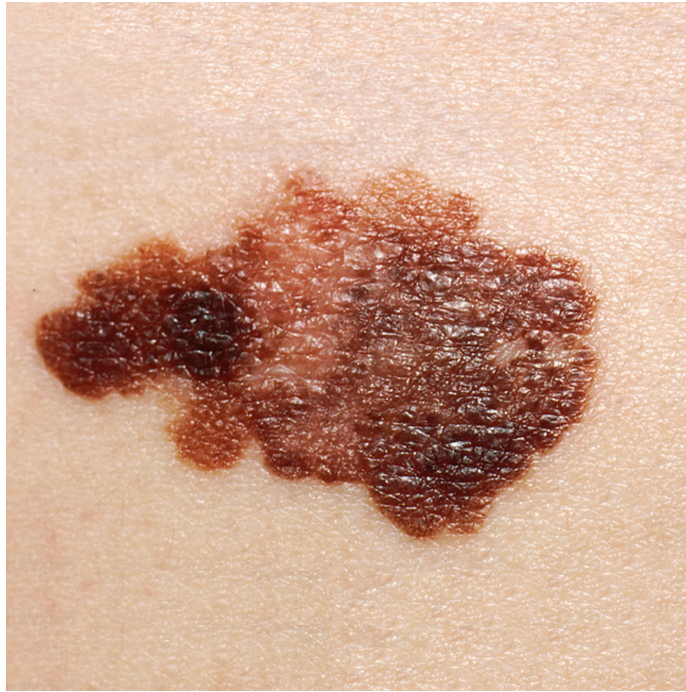


Figure 3.21 Melanoma

SKIN COLOR CHANGES

Changes in the appearance of the color of an individual's skin can be a symptom of many types of disorders:

- Redness in the skin caused by capillary dilation is referred to as **erythema** (ěr-ĭ-THĒ-mă).
- A drop in oxygenation can cause the skin to develop **pallor** (PĀL-or), the medical term for paleness. Severe or prolonged reduction in oxygen levels cause the skin to appear blue, referred to as **cyanosis** (sī-ă-NŌ-sīs). See Figure 3.22³³ for an image of cyanosis in fingertips.
- Death of cells causes them to appear black, referred to as **necrosis** (ně-KRŌ-sīs). See Figure 3.23³⁴ for an image of necrosis spreading after an

33. “[Blue finger tips 3.jpg](#)” by [WaltFletcher](#) is licensed under [CC BY-SA 4.0](#)

amputation.

- A yellow discoloration of the skin due to the accumulation of bilirubin is referred to as **jaundice** (JON-dīs). Jaundice is discussed in more detail below the images.

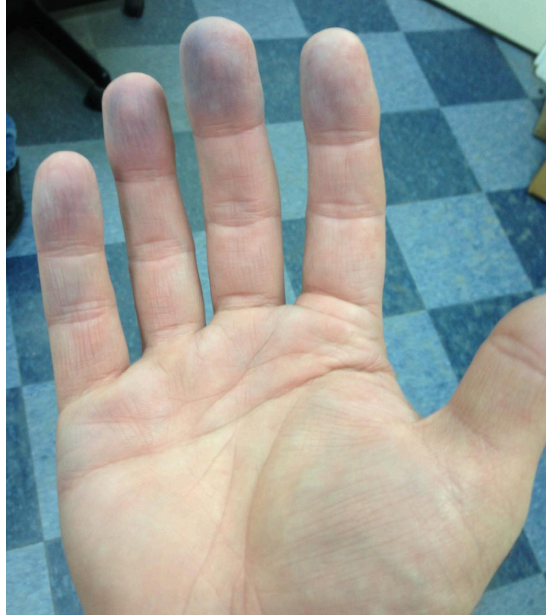

Figure 3.22 Cyanosis

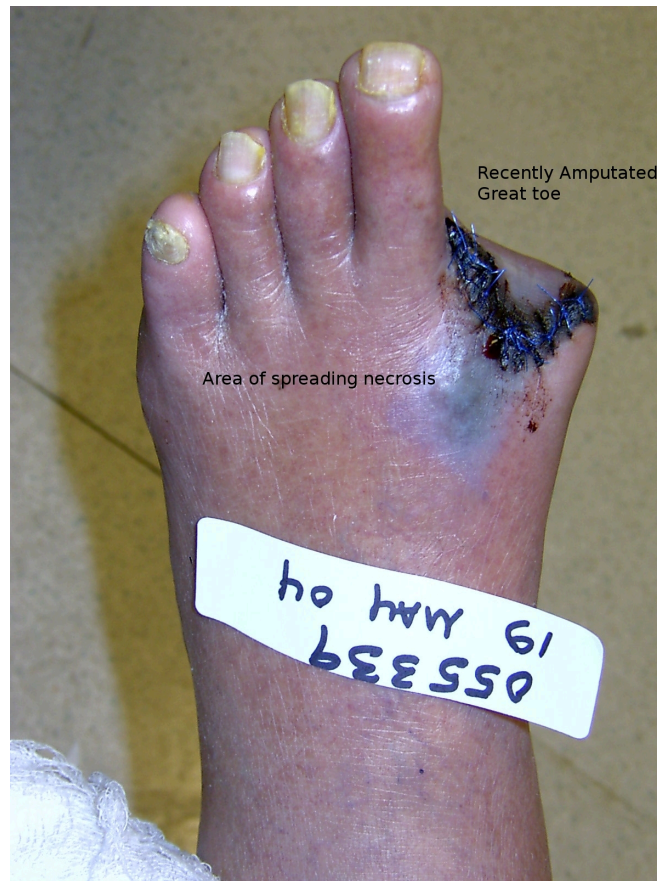

Figure 3.23 Necrosis

Jaundice causes skin and sclera (whites of the eyes) to turn yellow, also referred to as xanthoderma. See Figure 3.24³⁵ for an image of a patient with jaundice visible in the sclera and the skin. Jaundice is caused by too much bilirubin in the body. Bilirubin is a yellow chemical in hemoglobin, the substance that carries oxygen in red blood cells. As red blood cells break down, the old ones are processed by the liver. If the liver can't keep up due to large amounts of red blood cell breakdown or liver damage, bilirubin builds up and causes the skin and sclera to appear yellow. New onset of jaundice should always be reported to the health care provider. Jaundice can happen at any age for many reasons, such as liver disease, blood disease, infections, or side effects of some medications. Jaundice also occurs in newborns due to

35. "[Cholangitis Jaundice.jpg](#)" by [Bobjgalindo](#) is licensed under [CC BY-SA 4.0](#)

the immaturity of their livers, but it quickly resolves on its own or with phototherapy treatment.³⁶

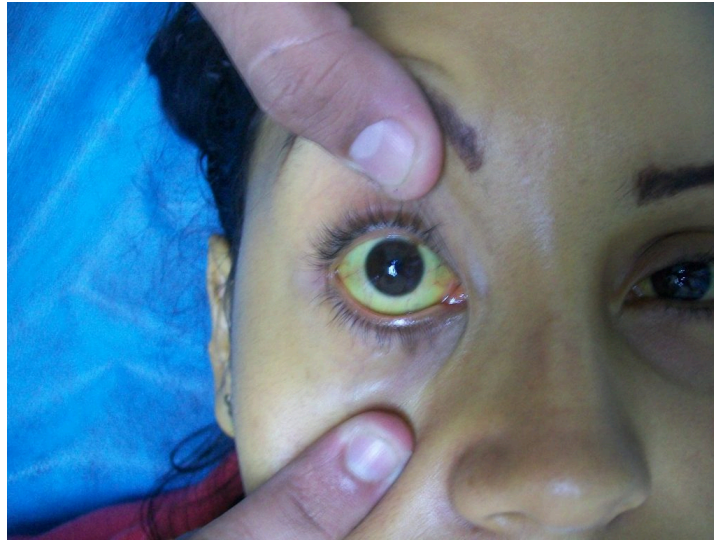

Figure 3.24 Jaundice

Albinism (AL-bĭ-nizm) is a genetic disorder that completely or partially affects the coloring of an individual's skin, hair, and eyes. This disorder is primarily due to the inability of melanocytes to produce melanin. Individuals with albinism tend to appear white or very pale due to the lack of melanin in their skin and hair. Recall that melanin helps protect the skin from the harmful effects of UV radiation. Individuals with albinism require additional protection from UV radiation because they are more prone to sunburns and skin cancer. They also tend to be more sensitive to light and have vision problems due to the lack of pigmentation on the retinal wall.

In **vitiligo** (vĭt-ĭ-Lĭ-gō), the melanocytes in certain areas of an individual's body lose their ability to produce melanin, possibly due to an autoimmune

36. MedlinePlus [Internet]. Bethesda (MD): National Library of Medicine (US); [updated 2019, Oct 22]. Jaundice; [reviewed 2016, Aug 31; cited 2020, Sep 18]. <https://medlineplus.gov/jaundice.html>

reaction. This causes a loss of color in patches, as shown in Figure 3.25.³⁷ The condition is especially noticeable in individuals with darker skin.

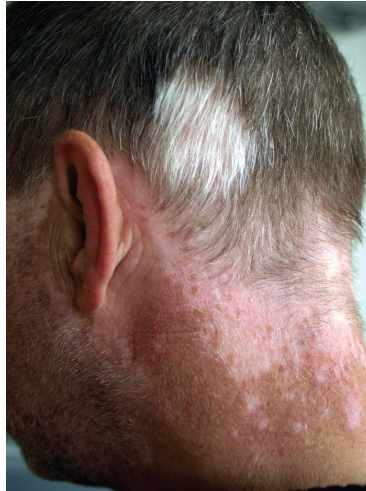

Figure 3.25 Vitiligo

Other Skin Conditions

Other skin conditions include the following:

- A **birthmark** (BURTH-mark) is a benign irregularity on the skin which is present at birth or appears shortly after birth.
- A **cyst** (sist) is a closed sac containing fluid, air, or other substances.
- **Gangrene** (GANG-grēn) is the death and decomposition of tissue, resulting from either infection or loss of blood supply.
- A **lesion** (lĒ-zhǒn) is an area of tissue that has suffered damage through injury or disease, such as a wound, ulcer, abscess, or tumor.
- **Leukoplakia** (loo-kō-PLĀ-kē-ă) refers to white, thickened patches on mucous membrane tissue of the tongue or cheek that cannot be scraped off. Leukoplakia is associated with chronic irritation, such as from tobacco

³⁷. “509_Vitiligo.jpg” by OpenStax College is licensed under [CC BY 3.0](https://creativecommons.org/licenses/by/3.0/)

use, including smoking and chewing.

- A **nevus** (NĒ-vŭs) is a pigmented skin blemish, commonly referred to as a “mole.”
- A **nodule** (NOJ-ool) is an abnormal growth of cells in the body that causes a lump and is distinct from its surroundings.
- **Pruritus** (proo-RĪT-ŭs) refers to severe itching. Pruritis can be caused by many types of disorders, such as contact dermatitis, insect bites, and viruses.
- **Rosacea** (rō-ZĀ-shē-ă) is a chronic skin disorder characterized by redness and pimples on the nose and cheeks.
- **Striae** (STRĪ-ē), commonly referred to as “stretch marks,” are caused by pressure associated with rapid growth, such as during puberty and pregnancy. They commonly occur over the hips and abdomen. A stretch mark results when the dermis is stretched beyond its limits of elasticity to accommodate the rapid growth. They initially have a reddish hue but lighten over time. Other than for cosmetic reasons, treatment of stretch marks is not required.
- **Telangiectasia** (těl-an-jē-ěk-TĀ-zē-ă), commonly referred to as “spider veins,” refers to small, dilated blood vessels near the surface of the skin.
- **Xeroderma** (zē-rō-DUR-mă) refers to abnormally dry skin.

3.6 Medical Specialists and Procedures Related to the Integumentary System

A **dermatologist** (dĕr-mă-TŎL-ō-jĭst) is a physician who specializes in treating diseases, disorders, and injuries related to the integumentary system. There are many dermatologic subspecialties such as cosmetic dermatology, dermatopathology, and pediatric dermatology.

- ▶ To learn more about the medical specialty of dermatology, visit the “[What is a Dermatologist?](#)” page of the American Academy of Dermatology Association website.

COMMON INTEGUMENTARY PROCEDURES

Common procedures performed on the integumentary system are as follows:

- **Biopsy** (Bĭ-op-sē) is the removal of living tissue to be viewed under a microscope for diagnostic purposes.
- **Cauterization** (KAW-tĕr-ĭz-a-shŏn) is a procedure that burns selected tissue by various means with the intent to destroy damaged tissues, prevent infections, or coagulate blood vessels.
- **Debridement** (Di-BRĒD-mĕnt) is the removal of damaged tissue or

foreign objects from a wound.

- **Dermabrasion** (Dur-mă-BRĀ-shŏn) is a procedure to refinish the top skin layer by mechanical scraping.
- **Dermatoheteroplasty** (Děr-mă-tō-HĚT-ěr-ō-plās-tē) is surgical repair of the skin using skin from another individual.
- **Excision** (Ek-SIZH-ŏn) is a surgical procedure to cut out something.
- **Incision & drainage** (In-SIZH-ŏn & DRĀN-ăj) (**I&D**) is a surgical cut to allow the release of fluids from a lesion, wound, or cavity.
- **Laser surgery** (LĀ-zěr SŮRJ-ě-rē) is a surgical procedure that uses a powerful beam of light to cut or burn tissue.
- **Rhytidectomy** (Rīt-ĭ-DEK-tŏ-mē) is the surgical removal of wrinkles, commonly known as a facelift.
- **Suturing** (SOO-chŭr-ing) is a procedure of inserting a row of stitches to hold together the edges of a wound or surgical incision.

3.7 Integumentary System Learning Activities

Interactive Learning Activity: Practice labeling the layers of the skin using this drag and drop activity.



An interactive H5P element has been excluded from this version of the text. You can view it online here:

<https://wtcs.pressbooks.pub/medterm/?p=2898#h5p-22>

Interactive Learning Activity: Study terms discussed in this chapter using these flashcards.



An interactive H5P element has been excluded from this version of the text. You can view it online here:

<https://wtcs.pressbooks.pub/medterm/?p=2898#h5p-172>

Interactive Learning Activity: Drag and drop matching definitions.



An interactive H5P element has been excluded from this version of the text. You can view it online here:

<https://wtcs.pressbooks.pub/medterm/?p=2898#h5p-165>

Interactive Learning Activity: Match prefixes and suffixes.



An interactive H5P element has been excluded from this version of the text. You can view it online here:

<https://wtcs.pressbooks.pub/medterm/?p=2898#h5p-166>

Interactive Learning Activity: Analyze spelling of integumentary-related words.



An interactive H5P element has been excluded from this version of the text. You can view it online here:

<https://wtcs.pressbooks.pub/medterm/?p=2898#h5p-167>

Interactive Learning Activity: Test your knowledge on terms related to the skin.



An interactive H5P element has been excluded from this version of the text. You can view it online here:

<https://wtcs.pressbooks.pub/medterm/?p=2898#h5p-27>

Interactive Learning Activity: Practice learning integumentary system terms by dragging the prefixes, suffixes, word roots, and combining vowels on the right to their appropriate spaces.



An interactive H5P element has been excluded from this version of the text. You can view it online here:

<https://wtcs.pressbooks.pub/medterm/?p=2898#h5p-26>

Interactive Learning Activity: Using the sample documentation provided, drag the terms on the right to their appropriate spaces within the documentation.



An interactive H5P element has been excluded from this version of the text. You can view it online here:

<https://wtcs.pressbooks.pub/medterm/?p=2898#h5p-25>



Interactive Learning Activity: Practice identifying and defining word parts for terms discussed in this chapter:



An interactive H5P element has been excluded from this version of the text. You can view it online here:

<https://wtcs.pressbooks.pub/medterm/?p=2898#h5p-194>

- ▶ You can also print this as a [Chapter 3 Practice Worksheet](#) and check your answers with this [Answer Key](#).

3.8 Glossary

Abrasion (ă-BRĀ-zhŏn): A wound caused by superficial damage to the skin by scraping or wearing away. ([Chapter 3.5](#))

Abscess (ĂB-sĕs): A swollen area within body tissue containing an accumulation of pus. ([Chapter 3.5](#))

Acne (AK-nē): A common skin condition characterized by the presence of pimples on the face, chest, and back due to inflammation or infection of the sebaceous glands and hair follicles. ([Chapter 3.5](#))

Adipose (ĂD-ĭ-pōs): Pertaining to fat or fatty tissue. ([Chapter 3.4](#))

Albinism (ĂL-bĭ-nĭz-əm): A group of inherited disorders characterized by little or no melanin production causing individuals to appear white or very pale. ([Chapter 3.5](#))

Alopecia (ăl-ō-PĒ-shē-ă): A condition in which hair is lost from some or all areas of the body, typically the scalp. ([Chapter 3.4](#))

Anhidrosis (ăn-hī-DRŌ-sĭs): Inability to sweat normally, which can lead to overheating. ([Chapter 3.4](#))

Apocrine sweat glands (ĂP-ō-krĭn swĕt glănds): Sweat glands that produce a more viscous sweat; found in the armpit and genital areas. ([Chapter 3.4](#))

Bacteria (bak-TĒR-ē-a): Members of a large group of microorganisms that have cell walls but lack organelles and an organized nucleus, including some that can cause disease. ([Chapter 3.5](#))

Basal cell carcinoma (BĀ-săl sel kar-sĭn-Ō-mă): A type of skin cancer that begins in the basal cells of the skin and is usually caused by long-term exposure to UV radiation from sunlight; most common of all skin cancers. ([Chapter 3.5](#))

Benign (bē-NĪN): A term used to describe tumors or growths that are not cancerous and do not spread to other parts of the body. ([Chapter 3.5](#))

Biopsy (BĪ-op-sē): The removal of tissue from the body for examination, usually to diagnose a disease. ([Chapter 3.6](#))

Birthmark (BURTH-mark): A benign irregularity on the skin present at birth or appearing shortly after birth. ([Chapter 3.5](#))

Blister (BLĪS-těr): A small bubble on the skin filled with serum and caused by friction, burning, or other damage. ([Chapter 3.5](#))

Boil (BOIL): A painful, pus-filled bump under the skin often caused by an infected hair follicle. ([Chapter 3.5](#))

Bruise (BRŪZ): Also referred to as a contusion; an injury appearing as an area of discolored skin on the body, caused by a blow or impact rupturing underlying blood vessels. ([Chapter 3.5](#))

Bulla (BŪL-lă): A large blister. ([Chapter 3.5](#))

Burn (bûrn): An injury caused by exposure to heat, flame, radiation, electricity, or chemicals. ([Chapter 3.5](#))

Calluses (KĀL-ŭ-ses): Thickened and hardened parts of the skin or soft tissue, especially in an area that has been subjected to friction. ([Chapter 3.5](#))

Cauterization (KAW-těr-īz-a-shŏn): A medical procedure used to burn tissue to stop bleeding or to remove a lesion. ([Chapter 3.6](#))

Cellulitis (sěl-yū-LĪ-tīs): A bacterial infection of the skin and subcutaneous tissue characterized by redness, pain, heat, and swelling. ([Chapter 3.5](#))

Community-acquired MRSA (CA-MRSA): MRSA infection occurring in people in the wider community. ([Chapter 3.5](#))

Contusion (kŏn-TOO-zhŏn): A region of injured tissue or skin in which blood capillaries have been ruptured; a bruise. ([Chapter 3.5](#))

Corn: A thickened area of skin with a central core, typically found on the toes. ([Chapter 3.5](#))

Cuticle (KYŪ-tĩ-kĭl): A protective thin layer of skin at the base of the fingernails and toenails. ([Chapter 3.4](#))

Cyanosis (sī-ă-NŌ-sīs): A bluish discoloration of the skin resulting from poor circulation or inadequate oxygenation of the blood. ([Chapter 3.5](#))

Cyst (sist): A closed sac in or under the skin that contains fluid, air, or other substances. ([Chapter 3.5](#))

Dandruff (DĀN-drŭf): The shedding of dead skin cells from the scalp. ([Chapter 3.4](#))

Debridement (di-BRĒD-měnt): The removal of damaged tissue or foreign objects from a wound. ([Chapter 3.5](#), [Chapter 3.6](#))

Dehydration (dē-hī-DRĀ-shōn): Excessive water loss. ([Chapter 3.4](#))

Dermabrasion (dûr-mă-BRĀ-shōn): A dermatological procedure that uses a rotating instrument to remove the outer layers of skin, typically on the face. ([Chapter 3.6](#))

Dermatitis (dûr-mă-TĪ-tīs): Inflammation of the skin that can cause a rash, including various types such as contact dermatitis and dermatitis caused by dust. ([Chapter 3.5](#))

Dermatoconiosis (dûr-mă-tō-kō-nē-Ō-sīs): A type of dermatitis caused by dust contacting the skin. ([Chapter 3.5](#))

Dermatofibroma (děr-mă-tō-fī-BRŌ-mă): A common benign skin growth, often a small, firm nodular lesion on the skin. ([Chapter 3.5](#))

Dermatoheteroplasty (dûr-mă-tō-HĚT-ěr-ō-plās-tē): Surgical repair of the skin using skin grafts from a donor. ([Chapter 3.6](#))

Dermatologist (dûr-mă-TŎL-ŏ-jĭst): A physician who specializes in the diagnosis and treatment of skin disorders and diseases. ([Chapter 3.6](#))

Dermis (DUR-mĭs): The middle layer of skin, containing tough connective tissue, hair follicles, and sweat glands. ([Chapter 3.4](#))

Diaphoresis (dī-ă-fə-RĒ-sīs): Excessive sweating, commonly associated with shock and other medical emergency conditions. ([Chapter 3.4](#))

Eccrine sweat gland (ĚK-rĭn swĕt glănd): A small sweat gland that produces a watery secretion without removing cytoplasm from the secreting cells; found all over the body but especially abundant on the palms of the hand, soles of the feet, and forehead. ([Chapter 3.4](#))

Eczema (eg-ZĚ-mă): An allergic inflammatory condition of the skin, manifesting as dry, itchy patches that resemble a red, flaky rash. ([Chapter 3.5](#))

Edema (ě-DĚ-mă): Swelling caused by excess fluid trapped in the body's tissues; commonly seen in the extremities. ([Chapter 3.5](#))

Elastin (ĭ-LĀS-tĭn): A protein in connective tissue that is elastic and allows many tissues in the body to resume their shape after stretching or contracting. ([Chapter 3.4](#))

Epidermis (ĕp-ĭ-DUR-mĭs): The outermost layer of skin, providing a waterproof barrier and creating skin tone. ([Chapter 3.4](#))

Erythema (ěr-ĭ-THĚ-mă): Redness of the skin caused by capillary dilation. ([Chapter 3.5](#))

Excision (ěk-SIZH-ŏn): The surgical removal of tissue, typically involving cutting out or off. ([Chapter 3.6](#))

Fascia (FĀSH-ē-ă): A band or sheet of connective tissue, primarily collagen, beneath the skin that attaches, stabilizes, encloses, and separates muscles, bones, and other internal organs. ([Chapter 3.4](#))

First-degree burn: A mild burn characterized by heat, pain, and reddening of the burned surface but not exhibiting blistering or charring of tissues. ([Chapter 3.5](#))

Fourth-degree burn: A burn which extends into deeper tissues, causing carbonization or charring of bones, muscles, and tendons underneath. ([Chapter 3.5](#))

Frostbite (FRŌST-bīt): Injury to body tissues caused by exposure to extreme cold, typically affecting the nose, fingers, or toes and sometimes resulting in gangrene. ([Chapter 3.4](#))

Gangrene (GANG-grēn): The death of body tissue due to a lack of blood flow or a bacterial infection. ([Chapter 3.5](#))

Hirsutism (HUR-sū-tīz-əm): Excessive hair growth on the face and body in areas where hair is usually minimal or absent, particularly in women. ([Chapter 3.4](#))

Hospital-acquired MRSA (HA-MRSA): MRSA infection occurring in people in hospitals or other health care facilities. ([Chapter 3.5](#))

Human papillomavirus (hyū-măn pap-ĭ-lō-mă-Vĭ-rŭs) (HPV): The most common sexually transmitted infection, causing genital warts and potentially leading to cervical, throat, and other cancers. ([Chapter 3.5](#))

Hyperhidrosis (hī-pěr-hī-DRŌ-sīs): Abnormally excessive sweating. ([Chapter 3.4](#))

Hypodermis (hī-pō-DUR-mīs): Also known as subcutaneous tissue; the deeper subcutaneous tissue composed of fat and connective tissue. ([Chapter 3.4](#))

Impetigo (ĭm-pě-Tĭ-gō): A contagious bacterial skin infection forming pustules and yellow crusty sores, typically in children. ([Chapter 3.5](#))

Incision & drainage (in-SIZH-ŏn and DRĀN-ij) (I&D): A minor surgical procedure to cut into a lesion or abscess to allow the escape of fluid. ([Chapter 3.6](#))

Infection (ĭn-FĚK-shŏn): The invasion and multiplication of microorganisms such as bacteria, viruses, and parasites that are not normally present within the body. ([Chapter 3.5](#))

Jaundice (JON-dĭs): A yellowing of the skin and eyes due to a buildup of bilirubin in the blood. ([Chapter 3.5](#))

Keloid (KĒ-loyd): An area of irregular fibrous tissue formed at the site of a scar or injury. ([Chapter 3.5](#))

Keratin (KĒR-ă-tĭn): A protein found in the skin, hair, and nails, providing strength and protection. ([Chapter 3.4](#))

Laceration (lăs-ě-RĀ-shŏn): A deep cut or tear in skin or flesh. ([Chapter 3.5](#))

Laser surgery (LĀ-zĕr SUR-jă-rĕ): A surgical technique that uses a laser to cut tissue instead of a scalpel. ([Chapter 3.6](#))

Lesion (lĒ-zhŏn): A region in an organ or tissue that has suffered damage through injury or disease. ([Chapter 3.5](#))

Leukoplakia (loo-kō-PLĀ-kē-ă): Thickened, white patches on the mucous membranes of the mouth, tongue, or cheek. ([Chapter 3.5](#))

Lipoma (lĭ-PŌ-mă): A benign tumor made of fat tissue. ([Chapter 3.5](#))

Lupus (LOO-pŭs): The common name for systemic lupus erythematosus; an autoimmune disease in which the immune system recognizes its own cell antigens as being “non-self” and mounts an immune response against them. ([Chapter 3.5](#))

Lymphedema (lim-fĕ-DE-mă): A type of swelling that occurs when lymph fluid builds up in the body’s soft tissues, often in the arms or legs, typically due to damage to the lymph system. ([Chapter 3.5](#))

Macule (MAK-ŭl): A flat, discolored spot on the skin. ([Chapter 3.5](#))

Melanocytes (mĕl-ĀN-ō-sĭtz): Cells located in the epidermis that produce melanin, the pigment responsible for skin color. ([Chapter 3.4](#))

Melanoma (mel-ă-NŌ-mă): A serious form of skin cancer that arises from the pigment-producing cells in the skin called melanocytes. ([Chapter 3.5](#))

Metastasize (mĕ-TĀS-tă-sĭz): The process by which cancer cells spread from the place where they first formed to another part of the body. ([Chapter 3.5](#))

Methicillin-resistant Staphylococcus aureus (mĕth-ĭ-SĪL-ĭn rĕ-zĭs-tănt STĀF-ə-lō-KŌK-ŭs OWR-ĕ-ŭs) (MRSA): A strain of staph bacteria that’s

resistant to the antibiotics commonly used to treat staph infections. ([Chapter 3.5](#))

Mohs surgery (MŌZ SŪR-jěr-ē): A precise surgical technique used to treat skin cancer, involving the progressive removal and examination of layers of cancer-containing skin until only cancer-free tissue remains. ([Chapter 3.5](#))

Mole (MŌL): A small skin growth that is usually brown or black; formed due to a cluster of pigmented cells. ([Chapter 3.5](#))

Necrosis (ně-KRŌ-sīs): The death of most or all of the cells in an organ or tissue due to disease, injury, or failure of the blood supply causing the skin to turn black. ([Chapter 3.5](#))

Nevus (NĒ-vūs): A benign skin lesion, commonly known as a mole, that is often pigmented. ([Chapter 3.5](#))

Nodule (NOJ-ool): A small lump or growth on or under the skin, often a sign of an underlying condition or disease. ([Chapter 3.5](#))

Onycholysis (ŏn-ĭ-KŌL-ĭ-sīs): The painless detachment of the nail from the nail bed. ([Chapter 3.4](#))

Onychomycosis (ŏn-ĭ-kō-mī-KŌ-sīs): Fungal infections of the nails. ([Chapter 3.5](#))

Onychophagia (ŏn-ĭ-kō-FĀ-jē-ă): The habit of biting the nails. ([Chapter 3.4](#))

Pallor (PĀL-or): An unhealthy pale appearance. ([Chapter 3.5](#))

Papule (PAP-ŭl): A small, raised, solid bump on the skin. ([Chapter 3.5](#))

Pathogens (PATH-ŏ-jěns): Microorganisms that cause disease. ([Chapter 3.5](#))

Pediculosis (pěd-ĭ-kū-LŌ-sīs): An infection with lice, typically affecting the head and resulting in itching and visible nits. ([Chapter 3.5](#))

Petechiae (pě-TĒK-ē-ĭ): Small, pinpoint, nonblanching red or purple spots on the skin, often caused by minor hemorrhages or bleeding under the skin. ([Chapter 3.5](#))

Pressure injuries: Damage to the skin and underlying soft tissue usually over a bony prominence or related to a medical or other device due to unrelieved pressure. ([Chapter 3.5](#))

Pruritus (proo-RĪT-ŭs): Severe itching; a common symptom in various skin conditions and diseases. ([Chapter 3.5](#))

Psoriasis (sō-RĪ-ə-sīs): A chronic autoimmune skin disease that speeds up

the growth cycle of skin cells, causing red, itchy, scaly patches on the body, most commonly on the elbows, knees, and scalp. ([Chapter 3.5](#))

Purpura (PUR-pyöŕ-ră): Larger areas of purple or red discolorations on the skin, often caused by bleeding underneath the skin. ([Chapter 3.5](#))

Pus (PŬS): A thick fluid composed of leukocytes, bacteria, and dead tissues, typically associated with infection. ([Chapter 3.5](#))

Pustule (PŬS-tŭl): A small blister or pimple on the skin containing pus. ([Chapter 3.5](#))

Rash: An area of redness and small spots on the skin due to allergy or illness. ([Chapter 3.5](#))

Rhytidectomy (řit-ř-DEK-tă-mē): A cosmetic surgical procedure, commonly known as a facelift, to remove wrinkles and sagging skin. ([Chapter 3.6](#))

Rickets (RIK-ěts): A disease of children caused by vitamin D deficiency, characterized by imperfect calcification, softening, and distortion of the bones typically resulting in bowed legs. ([Chapter 3.4](#))

Rosacea (rō-ZĀ-shē-ă): A chronic skin disorder characterized by facial redness, small, red, pus-filled bumps, and visible blood vessels, often on the nose and cheeks. ([Chapter 3.5](#))

Rule of Nines: A method used in calculating body surface area affected by burns. ([Chapter 3.5](#))

Scabies (SKĀ-bēz): An infection caused by tiny mites that burrow into the skin, leading to intense itching. ([Chapter 3.5](#))

Scar (skăř): A mark left on the skin or within body tissue where a wound, burn, or sore has not healed completely, and fibrous connective tissue has developed. ([Chapter 3.5](#))

Sebaceous gland (sě-BĀ-shŭs glănd): A small gland in the skin which secretes a lubricating oily matter (sebum) into the hair follicles to lubricate the skin and hair. ([Chapter 3.4](#))

Second-degree burn: A burn marked by pain, blistering, and superficial destruction of dermis with edema and hyperemia of the tissues beneath the burn. ([Chapter 3.5](#))

Shingles (SHING-gřlz): A viral disease that causes painful rashes on the skin, caused by the varicella-zoster virus. ([Chapter 3.5](#))

Skin ulcer ('skin ŬL-sěř): An open sore on an external or internal surface of

the body, caused by a break in the skin or mucous membrane that fails to heal. ([Chapter 3.5](#))

Squamous cell carcinoma (SKWĀ-mŭs sel kar-sĭn-Ō-mă): A common form of skin cancer that originates in the squamous cells of the skin; often due to UV exposure and can metastasize if not treated. ([Chapter 3.5](#))

Staphylococcus (stăf-ə-lō-KŌK-ŭs): A genus of gram-positive bacteria. ([Chapter 3.5](#))

Streptococcus (strĕp-tō-KŌK-ŭs): A genus of coccus (spherical) bacteria belonging to the phylum Firmicutes and the lactic acid bacteria group. ([Chapter 3.5](#))

Striae (STRĪ-ē): Commonly referred to as stretch marks; long, narrow streaks, stripes, or lines that develop on the skin, often due to rapid stretching of the skin. ([Chapter 3.5](#))

Subcutaneous (sŭb-kŭ-TĀ-nē-ŭs): Also known as hypodermis tissue; the deeper tissue composed of fat and connective tissue. ([Chapter 3.4](#))

Suturing (SOO-chər-ing): The act of sewing or stitching up a wound or incision. ([Chapter 3.6](#))

Sympathetic nervous system (sĭm-pă-THĚT-ĭk NUR-vŭs SIS-tĕm): Part of the autonomic nervous system that serves to accelerate the heart rate, constrict blood vessels, and raise blood pressure. ([Chapter 3.4](#))

Systemic lupus erythematosus (sis-TĚM-ik LOO-pŭs ěr-i-thĕ-mă-TO-sŭs) (SLE): A chronic autoimmune disease that can cause inflammation and damage to various body tissues and organs, including the skin, joints, kidneys, brain, and heart. ([Chapter 3.5](#))

Telangiectasia (tĕl-an-jĕ-ĕk-TĀ-zĕ-ă): Small, visible blood vessels near the surface of the skin; often appearing as red or purple lines. ([Chapter 3.5](#))

Third-degree burn: A severe burn characterized by destruction of the skin through the depth of the dermis and possibly into underlying tissues, loss of fluid, and sometimes shock. ([Chapter 3.5](#))

Tinea (TĪ-nē-ă): A group of skin infections caused by a fungus, including conditions like ringworm, athlete's foot, and jock itch. ([Chapter 3.5](#))

Tinea capitis (TĪ-nē-ă KĀP-ĭ-tĭs): Scalp ringworm causing itchy, red patches on the head that can leave bald spots. ([Chapter 3.5](#))

Tinea corporis (TĪ-nē-ă KŌR-pŏ-rĭs): Ringworm; a fungal rash on the body that typically looks like a red ring with a clear center. ([Chapter 3.5](#))

Tinea cruris (TĪ-nē-ă KRŌŏ-rĭs): Jock itch; causes an itchy, burning rash in the groin area. ([Chapter 3.5](#))

Tinea pedis (TĪ-nē-ă PĚD-ĭs): Athlete's foot, causing itching, burning, and cracked skin between the toes. ([Chapter 3.5](#))

Urticaria (ur-tĭ-KĀR-ē-ă): Raised, itchy rashes on the skin, also known as hives. ([Chapter 3.5](#))

Vascularized (VĀS-kū-lə-rĭzd): Richly supplied with blood vessels. ([Chapter 3.4](#))

Verruca (vĕr-ROO-kă): Another term for a wart; a benign growth on the skin caused by a virus. ([Chapter 3.5](#))

Vesicle (VES-ĭ-kĭl): A small, fluid-filled sac or blister within or under the epidermis. ([Chapter 3.5](#))

Virus (VĪ-rŭs): A microorganism that spreads infection by invading the body's cells and replicating. ([Chapter 3.5](#))

Vitiligo (vĭt-ĭ-LĪ-gŏ): A disease that causes loss of skin color in blotches. ([Chapter 3.5](#))

Wart (WART): A small, benign growth on the skin caused by a virus; also called verruca. ([Chapter 3.5](#))

Wheal: An individual hive. ([Chapter 3.4](#))

Xeroderma (zē-rō-DUR-mă): Excessively dry skin; often caused by environmental factors or certain skin conditions. ([Chapter 3.5](#))

Yeast infections (YĚST ĭn-FĕK-shŭns): Infections commonly caused by the Candida fungus, leading to overgrowth and symptoms like itching and discharge. ([Chapter 3.5](#))

PART IV

CHAPTER 4 RESPIRATORY SYSTEM TERMINOLOGY

4.1 Respiratory System

Introduction

Learning Objectives

- Apply the rules of medical language to build, analyze, spell, pronounce, abbreviate, and define terms as they relate to the respiratory system
- Identify meanings of key word components of the respiratory system
- Categorize diagnostic, therapeutic, procedural, or anatomic terms related to the respiratory system
- Use terms related to the respiratory system
- Use terms related to the diseases and disorders of the respiratory system

Introduction to the Respiratory System

The primary function of the respiratory system is to provide oxygen to body tissues and to remove carbon dioxide. This chapter will begin by reviewing common word components related to the respiratory system that can be used to build definitions of respiratory terminology. Other respiratory terms, whose definitions cannot be easily built from word components, will be described in context based on the anatomy and physiology of the respiratory system, as well as common respiratory diseases and disorders. Medical

specialists, diagnostic tests, procedures, and equipment related to the respiratory system will also be discussed.

View Figure 4.1¹ for an illustration of major anatomic structures of the respiratory system.

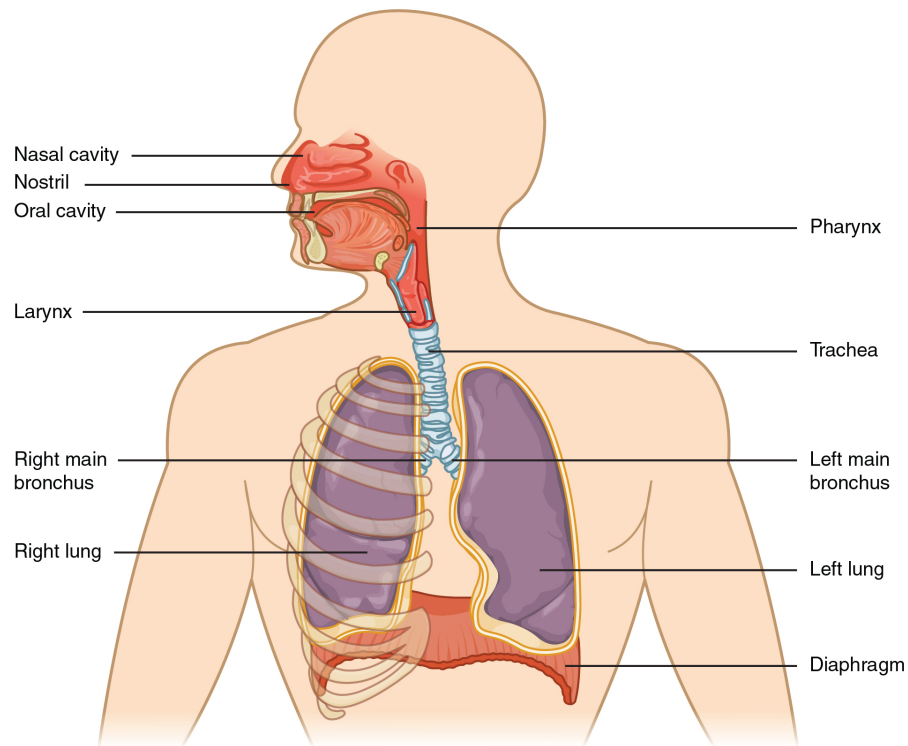


Figure 4.1 Major Respiratory Anatomic Structures

1. “[2301 Major Respiratory Organs.jpg](#)” by OpenStax College is licensed under [CC BY 3.0](#)

4.2 Word Components Related to the Respiratory System

This section will describe common word components related to the respiratory system. These word components can be used to build definitions for many medical terms related to the respiratory system. Other common prefixes are described in [Chapter 1.3](#), and common suffixes are described in [Chapter 1.5](#).

COMMON PREFIXES RELATED TO THE RESPIRATORY SYSTEM

- **a-**: Absence of, without
- **an-**: Absence of, without
- **brady-**: Slow
- **dys-**: Difficult, painful, abnormal, labored
- **endo-**: Within, in
- **eu-**: Normal, good
- **hyper-**: Above, excessive
- **hypo-**: Below, incomplete
- **intra-**: Within, in
- **poly-**: Many, much
- **tachy-**: Fast, rapid

COMMON WORD ROOTS WITH A COMBINING VOWEL RELATED TO THE RESPIRATORY SYSTEM

- **adenoid/o**: Adenoids
- **alveol/o**: Alveolus
- **atel/o**: Imperfect, incomplete
- **bronch/o**: Bronchus
- **bronchi/o**: Bronchus
- **capn/o**: Carbon dioxide
- **diaphragmat/o**: Diaphragm
- **epiglott/o**: Epiglottis
- **hem/o**: Blood
- **hemat/o**: Blood
- **laryng/o**: Larynx
- **lob/o**: Lobe
- **muc/o**: Mucus
- **nas/o**: Nose
- **orth/o**: Straight
- **ox/i**: Oxygen
- **pharyng/o**: Pharynx
- **phon/o**: Sound, voice
- **phren/o**: Diaphragm
- **pleur/o**: Pleura
- **pneum/o**: Lung, air
- **pneumat/o**: Lung
- **pneumon/o**: Lung, air
- **pulmon/o**: Lung
- **py/o**: Pus
- **radi/o**: X-rays, ionizing radiation
- **respir/o**: Breath, breathing
- **rhin/o**: Nose

- **sept/o**: Septum
- **sinus/o**: Sinus
- **somn/o**: Sleep
- **son/o**: Sound
- **spir/o**: Breathe, breathing
- **thorac/o**: Thorax, chest cavity
- **tom/o**: To cut, section, slice
- **tonsill/o**: Tonsil
- **trache/o**: Trachea

COMMON SUFFIXES RELATED TO THE RESPIRATORY SYSTEM

- **-algia**: Pain
- **-ar**: Pertaining to
- **-ary**: Pertaining to
- **-cele**: Hernia, protrusion
- **-centesis**: Surgical puncture to aspirate fluid
- **-eal**: Pertaining to
- **-ectasis**: Stretching out, dilation, expansion
- **-ectomy**: Excision, cut out
- **-emia**: In the blood
- **-genic**: Producing, originating, causing
- **-gram**: Record of, radiographic image
- **-graph**: Instrument used to record
- **-graphy**: Process of recording, radiographic imaging
- **-ia**: Condition, diseased state, abnormal state
- **-ic**: Pertaining to
- **-itis**: Inflammation
- **-logist**: Specialist who studies and treats
- **-logy**: Study of

- **-meter**: Instrument used to measure
- **-metry**: Measurement
- **-oid**: Resembling
- **-osis**: Abnormal condition
- **-pexy**: Surgical fixation, suspension
- **-plasty**: Surgical repair
- **-pnea**: Breathing
- **-ptysis**: Spitting, coughing
- **-rrhagia**: Rapid flow of blood, excessive bleeding
- **-scope**: Instrument used for visual examination
- **-scopic**: Pertaining to visual examination
- **-scopy**: Process of visually examining, visual examination
- **-spasm**: Sudden involuntary muscle contraction, spasmodic contraction
- **-stenosis**: Constriction, narrowing
- **-stomy**: Creation of an artificial opening
- **-thorax**: Chest, chest cavity
- **-tome**: Instrument used to cut
- **-tomy**: Cut into, incision

4.3 Examples of Respiratory Terms Easily Defined By Their Word Components

Here are examples of respiratory medical terms that can be easily defined by breaking them down into word components.

Pulmonologist

1. Break down the medical term into word components:
Pulmon/o/logist
2. Label the word parts: **Pulmon** = WR; **o** = CV; **logist** = S
3. Define the word components: **Pulmon** = lung; **logist** = specialist who studies and treats disorders
4. Create a final definition of the medical term: **Specialist who treats diseases and disorders of the lungs**

Adenoidectomy

1. Break down the medical term into word components:
Adenoid/ectomy
2. Label the word parts: **Adenoid** = WR; **ectomy** = suffix
3. Define the word components: **Adenoid** = adenoid; **ectomy** = excision (cut out)

4. Create a final definition of the medical term: **Excision of the adenoid**

Bronchoscopy

1. Break down the medical term into word components:
Bronch/o/scopy
2. Label the word parts: **Bronch** = WR; **o** = CV; **scopy** = suffix
3. Define the word components: **Bronch** = bronchus; **scopy** = visual examination
4. Create a final definition of the medical term: **Visual examination of the bronchi**



Interactive Learning Activity: Practice defining and pronouncing respiratory system medical terms by breaking them down into word parts.



An interactive H5P element has been excluded from this version of the text. You can view it online here:

<https://wtcs.pressbooks.pub/medterm/?p=3078#h5p-95>

- ▶ You can also print this as a [Chapter 4 Student Companion Worksheet](#) and check your answers with this [Answer Key](#).

4.4 Anatomy of the Respiratory System

This section will describe the major anatomic structures of the respiratory system, including the nose and adjacent structures, pharynx, larynx, trachea, bronchia, alveoli, and lungs. Common disorders affecting these structures will also be introduced.

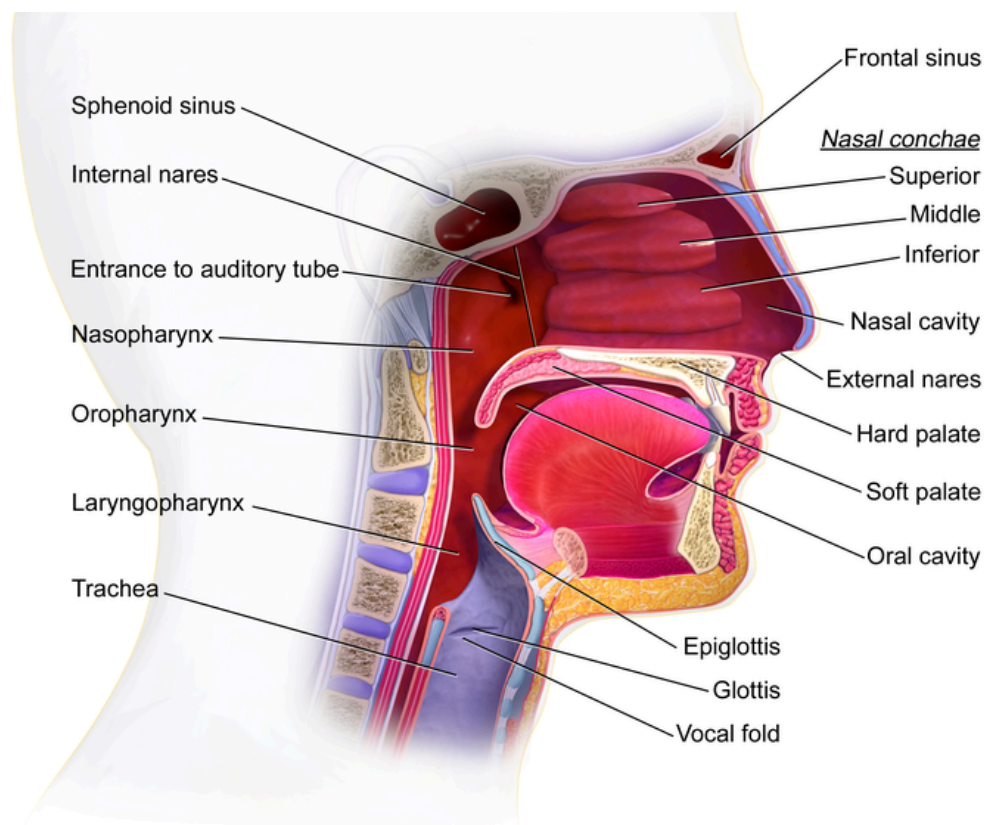
NOSE, NASAL CAVITY, AND SINUSES

See Figure 4.2¹ for an illustration of anatomic structures of the upper respiratory system. The upper respiratory system refers to the nose, nasal cavities, sinuses, pharynx, and larynx. An **upper respiratory infection** (ŬP-er RES-pĭr-ă-tō-rē ĩn-FEK-shun) (**URI**) refers to a viral infection of one or more of these structures.

The entrance and exit for the respiratory system are through the nose. The nostrils are the opening to the nose, also referred to as nares. The nares and nasal cavities are lined with mucous membranes, containing sebaceous glands and hair follicles that serve to prevent the passage of large debris, such as dirt, through the nasal cavity. The word root for “nose” is *rhin*. For example, **rhinorrhagia** (rĭ-nō-RĀ-jē-ă) refers to bleeding from the nose, also called **epistaxis** (ĕp-ĭ-STĀK-sĭs). **Rhinitis** (rye-NYE-tis) refers to inflammation of the nasal mucosa. The nares open into the nasal cavity, which is separated into left and right sections by the nasal **septum** (SĔP-tŭm). The floor of the nasal

1. “[Blausen_0872_UpperRespiratorySystem.png](#)” by [Blausen.com staff](#) (2014) is licensed under [CC BY 3.0](#)

cavity is composed of the hard palate and the soft palate. The nasal cavities are lined with mucous membranes that produce **mucus** (MŪ-kŭs), a substance created for lubrication and protection. **Rhinorrhea** (rye-noh-REE-uh), commonly referred to as a “runny nose,” is medical term for excess mucus production by the nasal cavity. Adjacent to the nasal cavity are the sinuses that serve to warm and humidify incoming air. There are four sinuses named for their adjacent bones: frontal sinus, maxillary sinus, sphenoidal sinus, and ethmoidal sinus. **Sinusitis** (sī-nŭ-SĪ-tĭs) refers to inflammation of the sinus cavities. Air moves from the nasal cavities and sinuses into the pharynx.²



The Upper Respiratory System

Figure 4.2 The Upper Respiratory System

2. This work is a derivative of [Anatomy and Physiology](https://openstax.org/books/anatomy-and-physiology/pages/1-introduction) by [OpenStax](https://openstax.org/books/anatomy-and-physiology/pages/1-introduction) licensed under [CC BY 4.0](https://creativecommons.org/licenses/by/4.0/). Access for free at <https://openstax.org/books/anatomy-and-physiology/pages/1-introduction>

The **pharynx** (FÄR-ĭngks), commonly known as the throat, is divided into three major regions: the nasopharynx, the oropharynx, and the laryngopharynx. See Figure 4.3³ for an illustration of the regions of the pharynx.

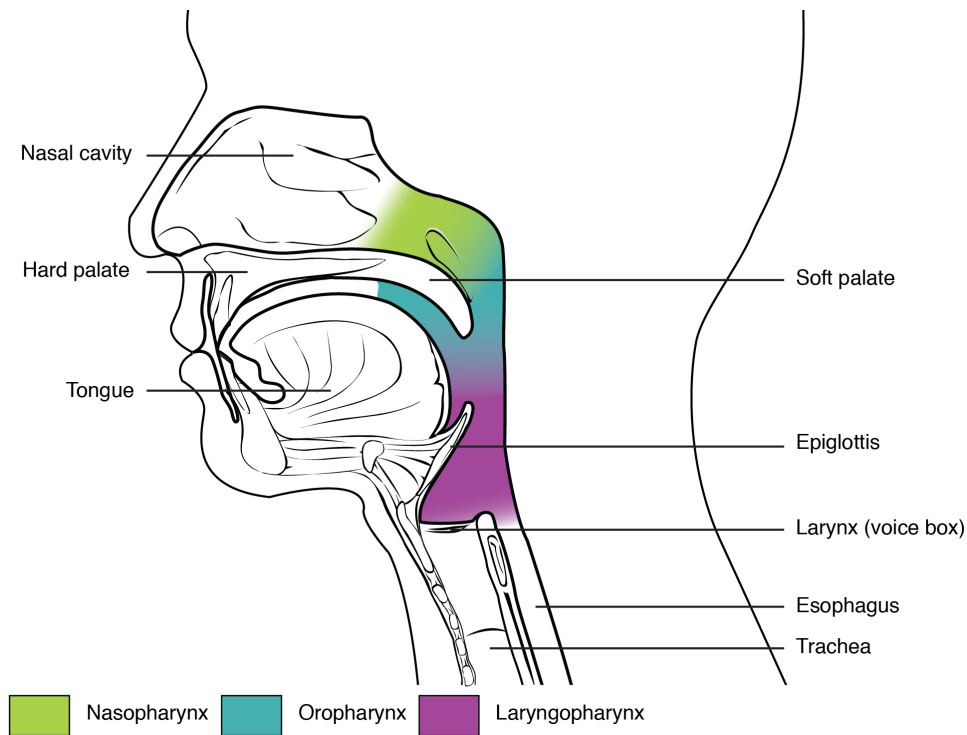


Figure 4.3 Regions of the Pharynx

At the top of the nasopharynx is the pharyngeal tonsil, also called adenoid, which is collection of lymphatic tissue found at the back of the nasal cavity in the nasopharynx. The function of the pharyngeal tonsil or **adenoid** (ÄD-ě-noyd) is to trap and destroy invading pathogens that enter the airway during inhalation. **Pharyngitis** (fä-RĭN-Jĭ-tĭs) is inflammation of the pharynx. **Tonsillitis** (tön-sĭl-ĭ-tĭs) refers to inflammation of the tonsils. **Adenoiditis** (ad-ě-

3. "[2305_Divisions_of_the_Pharynx.jpg](#)" by OpenStax College is licensed under CC BY 3.0

noiditis) refers to inflammation of the adenoids, a common medical condition in young children that can hinder speaking and breathing.⁴

The soft palate and a bulbous structure called the uvula swing upward during swallowing to close off the nasopharynx to prevent ingested materials from entering the nasal cavity. Eustachian tubes connect the middle ear cavities with the nasopharynx. This connection is why colds can sometimes cause ear infections in children.⁵

The oropharynx is bordered superiorly by the nasopharynx and anteriorly by the oral cavity. The oropharynx contains two distinct sets of tonsils called the palatine tonsils and lingual tonsils that also trap and destroy pathogens entering the body through the oral or nasal cavities.⁶

The laryngopharynx is located just below the oropharynx. It is the part of the pharynx (throat) located behind (posterior) the larynx. The laryngopharynx separates into the trachea (the tube going to the larynx) and the esophagus (the tube going into the stomach). The epiglottis prevents food and fluid from entering the trachea while swallowing.⁷

4. This work is a derivative of [Anatomy and Physiology](#) by [OpenStax](#) licensed under [CC BY 4.0](#). Access for free at <https://openstax.org/books/anatomy-and-physiology/pages/1-introduction>
5. This work is a derivative of [Anatomy and Physiology](#) by [OpenStax](#) licensed under [CC BY 4.0](#). Access for free at <https://openstax.org/books/anatomy-and-physiology/pages/1-introduction>
6. This work is a derivative of [Anatomy and Physiology](#) by [OpenStax](#) licensed under [CC BY 4.0](#). Access for free at <https://openstax.org/books/anatomy-and-physiology/pages/1-introduction>
7. This work is a derivative of [Anatomy and Physiology](#) by [OpenStax](#) licensed under [CC BY 4.0](#). Access for free at <https://openstax.org/books/anatomy-and-physiology/pages/1-introduction>

LARYNX

The structure of the **larynx** (LĀR-īngks) is formed by several pieces of cartilage, as shown in Figure 4.4.⁸ Three large cartilage pieces form the major structure of the larynx called thyroid cartilage (the larger piece of cartilage on the anterior side), epiglottis (at the top of the larynx), and cricoid cartilage (just inferior to the thyroid cartilage). **Laryngitis** (lă-rĭn-JĪ-tĭs) refers to inflammation of the larynx, specifically the vocal folds or cords, resulting in huskiness or loss of one's voice and a cough.⁹

8. "[2306_The_Larynx.jpg](#)" by OpenStax College is licensed under [CC BY 3.0](#)

9. This work is a derivative of [Anatomy and Physiology](#) by [OpenStax](#) licensed under [CC BY 4.0](#). Access for free at <https://openstax.org/books/anatomy-and-physiology/pages/1-introduction>

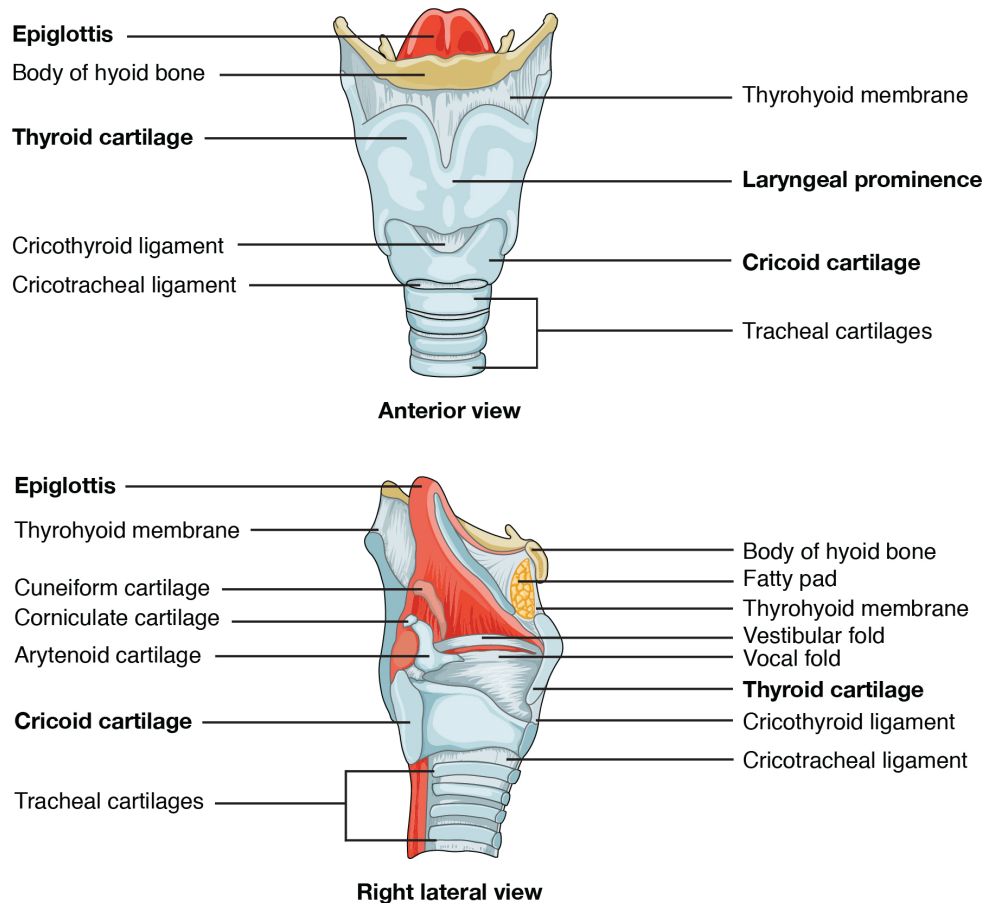


Figure 4.4 Larynx

The **epiglottis** (ě-pĭ-GLŎT-ĭs) is a flap of tissue that covers the trachea during swallowing to prevent **aspiration** (ăs-pĭ-RĀ-shŭn), the inhalation of food or fluids into the trachea and lower respiratory tract. The act of swallowing causes the pharynx and larynx to lift upward, allowing the pharynx to expand and the epiglottis of the larynx to swing downward, closing the opening to the trachea.¹⁰

Vocal cords are white, membranous folds attached by muscle to the cartilages of the larynx on their outer edges. The inner edges of the vocal

10. This work is a derivative of [Anatomy and Physiology](https://openstax.org/books/anatomy-and-physiology/pages/1-introduction) by [OpenStax](https://openstax.org/books/anatomy-and-physiology/pages/1-introduction) licensed under [CC BY 4.0](https://creativecommons.org/licenses/by/4.0/). Access for free at <https://openstax.org/books/anatomy-and-physiology/pages/1-introduction>

cords are free, allowing oscillation as air passes through to produce sound for speaking. See Figure 4.5¹¹ for an illustration of vocal cords. The word root *phon* refers to sound or voice, so the medical term **dysphonia** (dis-FŌ-nē-ă)¹² refers to the medical condition of difficulty speaking (i.e., voice).

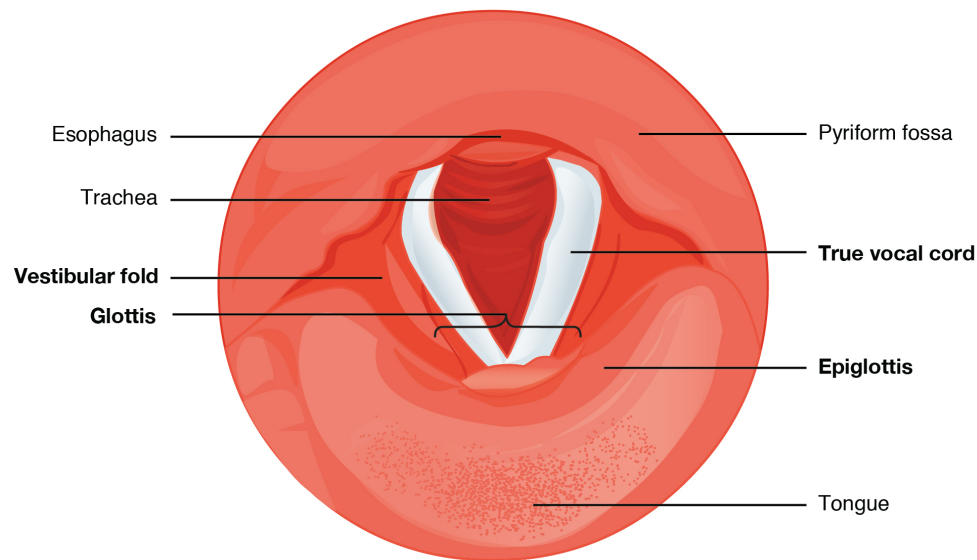


Figure 4.5 Vocal Cords

The lower respiratory tract consists of the trachea, bronchi, alveoli, and lungs.

The **trachea** (trā-KĒ-ă) is formed by stacked, C-shaped pieces of cartilage that are connected by dense connective tissue. See Figure 4.6¹³ for an

11. “2307_Cartilages_of_the_Larynx.jpg” by OpenStax College is licensed under [CC BY 3.0](#)

12. This work is a derivative of *Anatomy and Physiology* by OpenStax licensed under [CC BY 4.0](#). Access for free at <https://openstax.org/books/anatomy-and-physiology/pages/1-introduction>

13. “2308a_The_Trachea.jpg” by OpenStax *Anatomy and Physiology* is licensed under [CC BY 4.0](#)

illustration of the trachea. The trachea stretches and expands slightly during inhalation and exhalation, whereas the rings of cartilage provide structural support and prevent the trachea from collapsing. The trachea is lined with cilia and mucus-secreting cells to trap debris and move it towards the pharynx to be swallowed or spit out.¹⁴

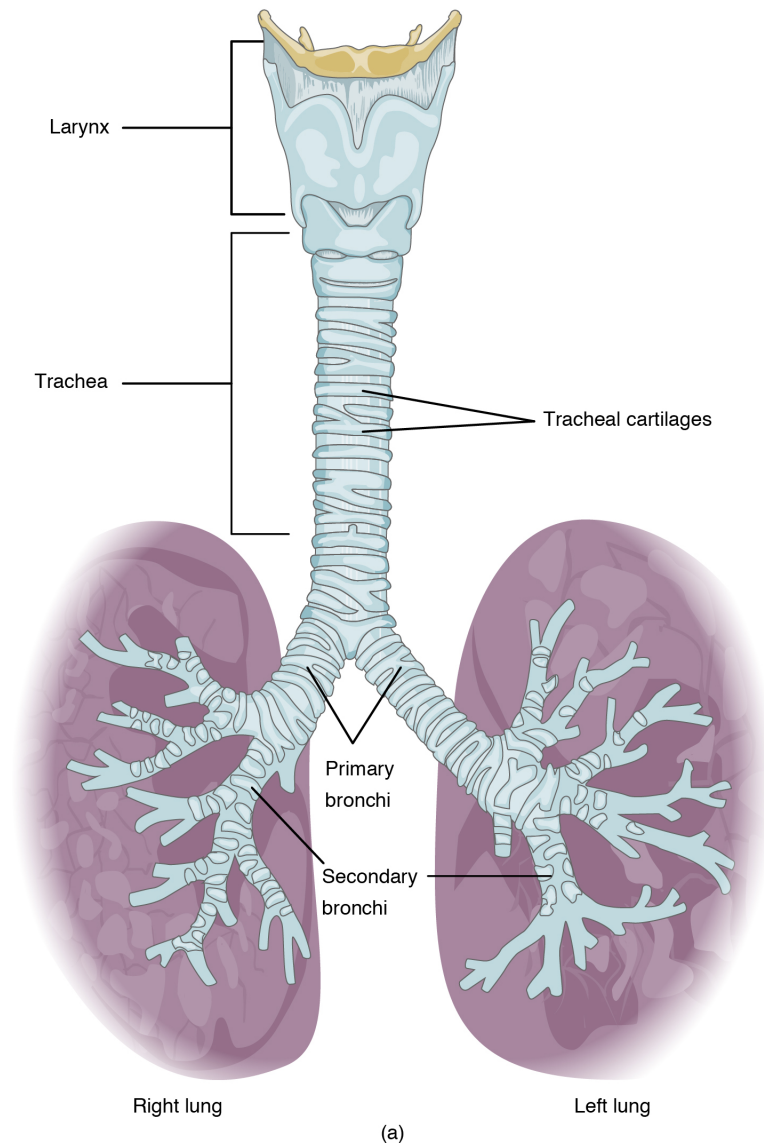


Figure 4.6 Trachea

14. This work is a derivative of [Anatomy and Physiology](https://openstax.org/books/anatomy-and-physiology/pages/1-introduction) by OpenStax licensed under CC BY 4.0. Access for free at <https://openstax.org/books/anatomy-and-physiology/pages/1-introduction>

If the upper respiratory tract becomes blocked with mucus, inflammation, or a foreign object, no air can pass to the lungs, causing a life-threatening emergency. A **tracheostomy** (trā-kē-ŌS-tō-mē) is an incision created in the trachea to create an artificial opening to allow breathing when an obstruction is present.

BRONCHI AND BRONCHIOLES

Bronchi (brōng-kī) are the main air passageways of the lungs. The trachea branches into the right and left primary bronchi at the carina. The carina is a raised structure that contains specialized nervous system tissue that induces violent coughing if a foreign body, such as food, is present. Rings of cartilage, similar to those of the trachea, support the structure of the bronchi and prevent their collapse. The bronchi of each lung continue to branch up to 26 times creating the bronchial tree, which looks similar to the branching of an actual tree.¹⁵

Bronchioles (brōng-kē-ōlz) are the smallest branches of the bronchi that lead to the alveolar sacs. See Figure 4.7¹⁶ for an illustration of the terminal (very last) bronchioles leading to the alveolar sacs. The muscular walls of these tiny bronchioles do not contain cartilage like those of the bronchi, so the muscular wall can change the size of the bronchia to increase or decrease airflow to the alveoli.¹⁷

15. This work is a derivative of [Anatomy and Physiology](#) by [OpenStax](#) licensed under [CC BY 4.0](#). Access for free at <https://openstax.org/books/anatomy-and-physiology/pages/1-introduction>

16. "[2309_The_Respiratory_Zone.jpg](#)" by OpenStax College is licensed under [CC BY 3.0](#)

17. This work is a derivative of [Anatomy and Physiology](#) by [OpenStax](#) licensed

The word root *bronch* refers to the bronchi. **Bronchospasm** (brōng-kō-spāz-ăm) is a symptom of many respiratory conditions that refers to a sudden constriction of the muscles in the walls of the bronchi. **Bronchitis** (brōng-KĪ-tĭs) refers to inflammation of the bronchi. **Bronchoscopy** (brōng-KŎS-kŏ-pē) is a procedure in which a tube is inserted by a medical specialist to visually examine the bronchi.¹⁸

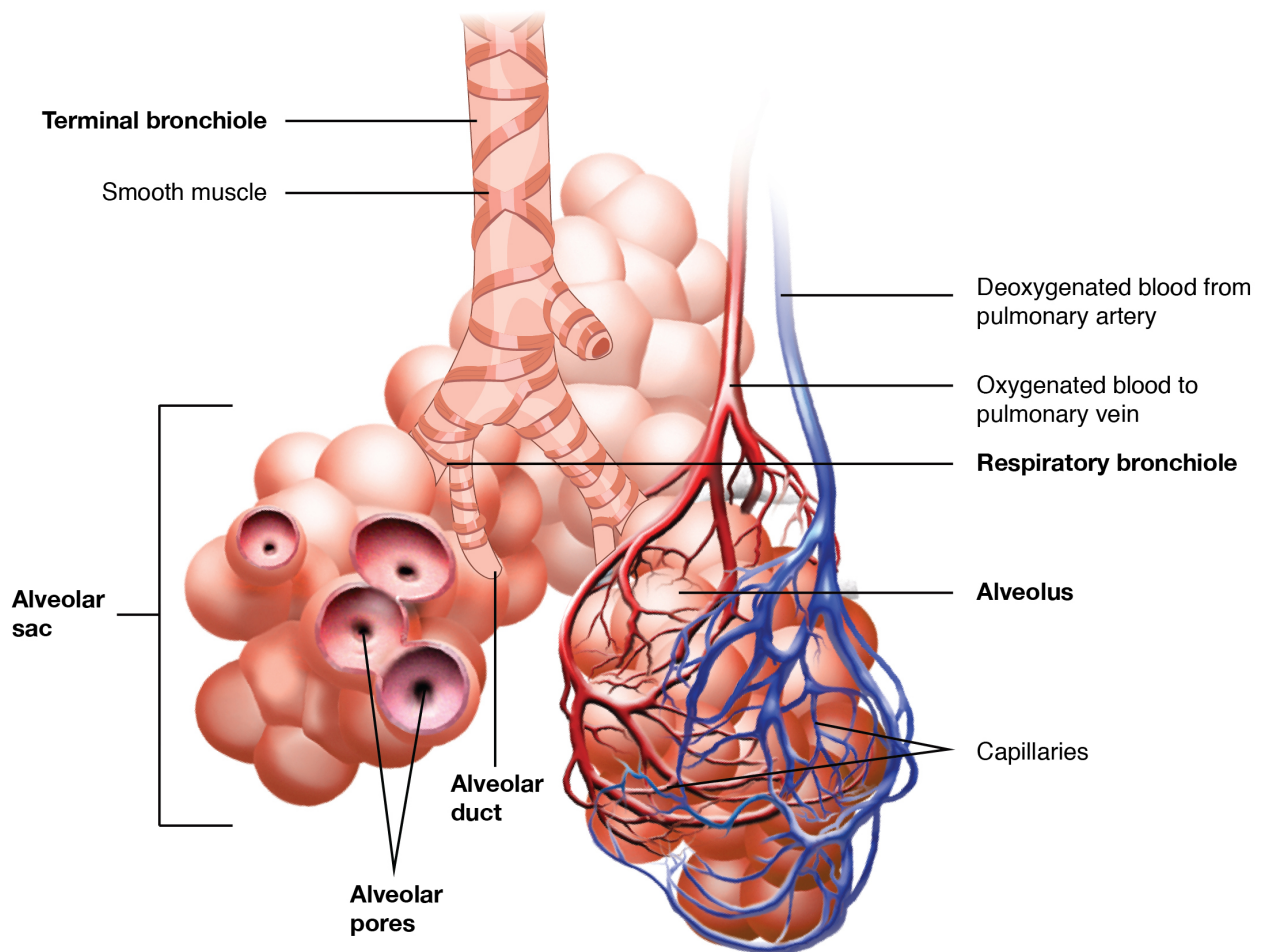


Figure 4.7 Alveoli

under [CC BY 4.0](https://openstax.org/books/anatomy-and-physiology/pages/1-introduction). Access for free at <https://openstax.org/books/anatomy-and-physiology/pages/1-introduction>

18. This work is a derivative of [Anatomy and Physiology](https://openstax.org/books/anatomy-and-physiology) by [OpenStax](https://openstax.org/books/anatomy-and-physiology) licensed under [CC BY 4.0](https://openstax.org/books/anatomy-and-physiology). Access for free at <https://openstax.org/books/anatomy-and-physiology/pages/1-introduction>

The trachea, bronchi, and bronchioles are lined with mucous membranes that create mucous secretions that can be expelled through the mouth, also referred to as **sputum** (SPŪT-ŭm).

ALVEOLI

Alveoli (ăl-VĒ-ŏ-lī) are small, grapelike sacs where gas exchange occurs. Alveoli have elastic walls that allow the alveolus to stretch during air intake, which greatly increases the surface area available for gas exchange. Alveoli secrete **surfactant** (SŬR-făk-tănt), a slippery substance that prevents the lungs from collapsing. **Atelectasis** (ă-tě-lĕk-TĀ-sĭs) is a medical term that refers to the collapse of alveoli and/or small passageways of the lungs that can result in a partially or completely collapsed lung.¹⁹

Alveol is the root word for alveolus, the singular form of alveoli. For example, the medical term **alveolar** (ăl-VĒ-ŏ-lăĕr) means pertaining to the alveolus.

[footnote]This work is a derivative of [Anatomy and Physiology](https://openstax.org/books/anatomy-and-physiology) by [OpenStax](https://openstax.org) licensed under [CC BY 4.0](https://creativecommons.org/licenses/by/4.0/). Access for free at <https://openstax.org/books/anatomy-and-physiology/pages/1-introduction>[/footnote]

LUNGS

The **lungs** (lŭngz) are connected to the trachea by the main (primary) bronchi

19. This work is a derivative of [Anatomy and Physiology](https://openstax.org/books/anatomy-and-physiology) by [OpenStax](https://openstax.org) licensed under [CC BY 4.0](https://creativecommons.org/licenses/by/4.0/). Access for free at <https://openstax.org/books/anatomy-and-physiology/pages/1-introduction>

that branches to the right and left bronchi. See Figure 4.8²⁰ for an illustration of the lungs. On the inferior surface, the lungs are bordered by the diaphragm. The cardiac notch, a medial indentation found only on the left lung, allows space for the heart. The apex of the lung is the superior region, whereas the base is the distal region near the diaphragm.²¹

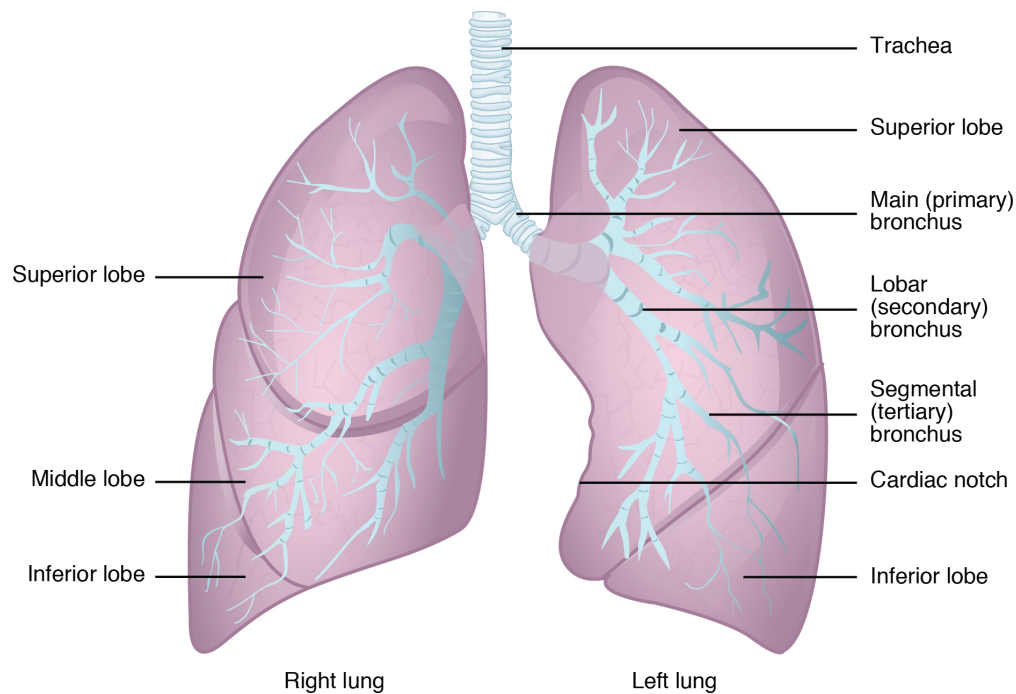


Figure 4.8 Lungs

Each lung is composed of smaller units called **lobes** (lōbz). The right lung consists of three lobes: the superior, middle, and inferior lobes. The left lung is smaller and only contains two lobes, superior and inferior, as it shares space

20. “2312_Gross_Anatomy_of_the_Lungs.jpg” by OpenStax College is licensed under [CC BY 3.0](#)

21. This work is a derivative of [Anatomy and Physiology](#) by [OpenStax](#) licensed under [CC BY 4.0](#). Access for free at <https://openstax.org/books/anatomy-and-physiology/pages/1-introduction>

with the heart. Each lobe receives its own large bronchus that has multiple branches. A **lobectomy** (lō-BĔK-tŭ-mē) refers to surgical removal of a lobe of the lung.²²

The word roots for lungs and/or air are *pneum* or *pneumon*. For example, the medical term **pneumonia** (noo-MŌN-yă) refers to a diseased state of the lung.²³

There are two pleural membranes in the lungs. The visceral pleura is a thin membrane on the surface of the lungs. The parietal pleura lines the inside of the thoracic cavity. Between these two membranes is the pleural cavity that contains pleural fluid to reduce friction and also sticks to the lungs to keep them inflated. See Figure 4.9²⁴ for an illustration of the pleural membranes and the pleural cavity. *Pleur* is the word root for pleural membranes. For example, **pleural effusion** (PLOOR-ăl ě-FŪ-zhŭn) is a medical term that refers to excessive fluid between the pleural membranes caused by disease or trauma.²⁵

22. This work is a derivative of *Anatomy and Physiology* by OpenStax licensed under CC BY 4.0. Access for free at <https://openstax.org/books/anatomy-and-physiology/pages/1-introduction>
23. This work is a derivative of *Anatomy and Physiology* by OpenStax licensed under CC BY 4.0. Access for free at <https://openstax.org/books/anatomy-and-physiology/pages/1-introduction>
24. “2313_The_Lung_Pleurea.jpg” by OpenStax College is licensed under CC BY 3.0
25. This work is a derivative of *Anatomy and Physiology* by OpenStax licensed under CC BY 4.0. Access for free at <https://openstax.org/books/anatomy-and-physiology/pages/1-introduction>

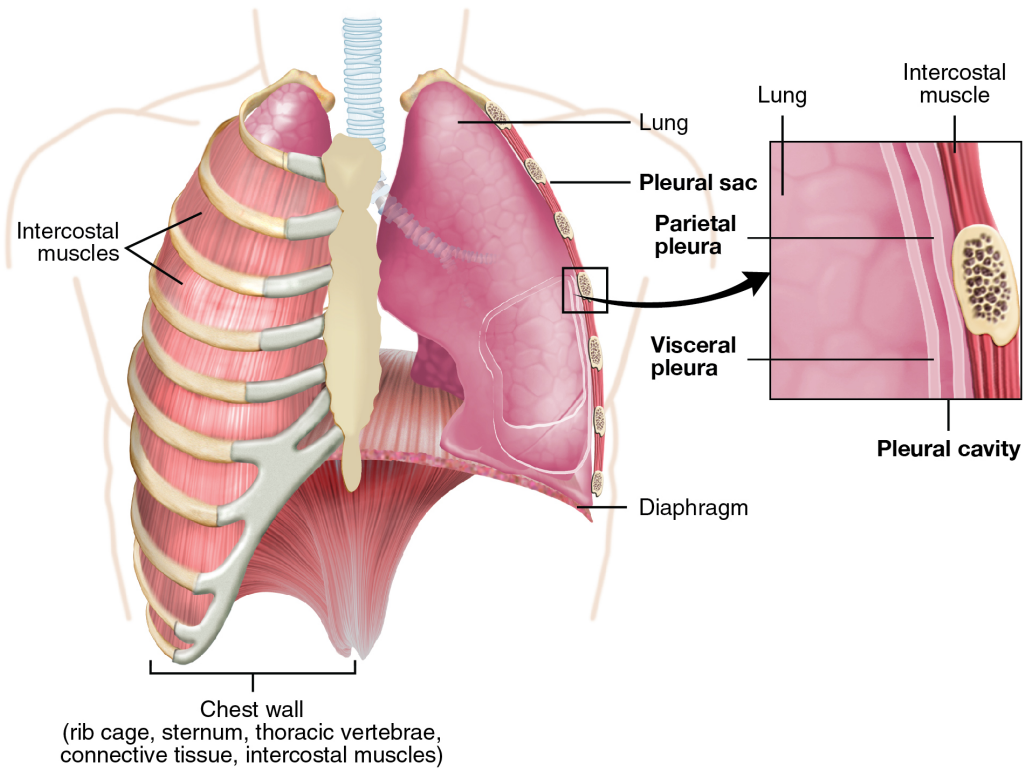


Figure 4.9 Pleural Cavity

View the following YouTube video²⁶ to visually review the anatomy of the respiratory system: [Respiratory System Anatomy \(v2.0\)](https://youtu.be/aqTwrdMS6CE)

26. Forciea, B. (2015, May 13). *Respiratory system anatomy (v2.0)* [Video]. YouTube. All rights reserved. Video used with permission.
<https://youtu.be/aqTwrdMS6CE>

4.5 Physiology of the Respiratory System

The main function of the respiratory system is **gas exchange** (gǎs ĭk-SCHĀNJ), meaning providing a constant supply of oxygen to the body and removing carbon dioxide. To achieve gas exchange, the structures of the respiratory system create the mechanical movement of air into and out of the lungs called **ventilation** (vēn-tĭ-LĀ-shŭn) (i.e., breathing).¹

VENTILATION AND THE MECHANICS OF BREATHING

The lungs bring oxygen to the cells of our body through inhalation. **Inhalation** (i-hā-LĀ-shŭn), also called inspiration, is the act of breathing in. During inhalation, the diaphragm contracts and flattens, creating a larger lung cavity, which decreases the pressure in the lungs. At the same, the intercostal muscles (the muscles between the ribs) pull downward, also causing the thoracic cavity to expand. The **thoracic cavity** (thuh-RAS-ik KA-vah-tee) is the space inside the chest that contains the heart, lungs, and other organs. As the thoracic cavity expands, a negative pressure (i.e., vacuum) is created inside the chest cavity, causing air to rush into the lungs (because air always moves from high pressure to low pressure).

¹. This work is a derivative of [Anatomy and Physiology](https://openstax.org/books/anatomy-and-physiology/pages/1-introduction) by [OpenStax](https://openstax.org/books/anatomy-and-physiology/pages/1-introduction) licensed under [CC BY 4.0](https://creativecommons.org/licenses/by/4.0/). Access for free at <https://openstax.org/books/anatomy-and-physiology/pages/1-introduction>

During **exhalation** (ěks-hā-LĀ-shŭn), also called expiration, the act of breathing out, the diaphragm relaxes and the thoracic cavity springs back to its original position. This causes the volume of the thoracic cavity to decrease and pressure to increase, causing air to leave the lungs.² See Figure 4.10³ for an illustration of inhalation and exhalation.

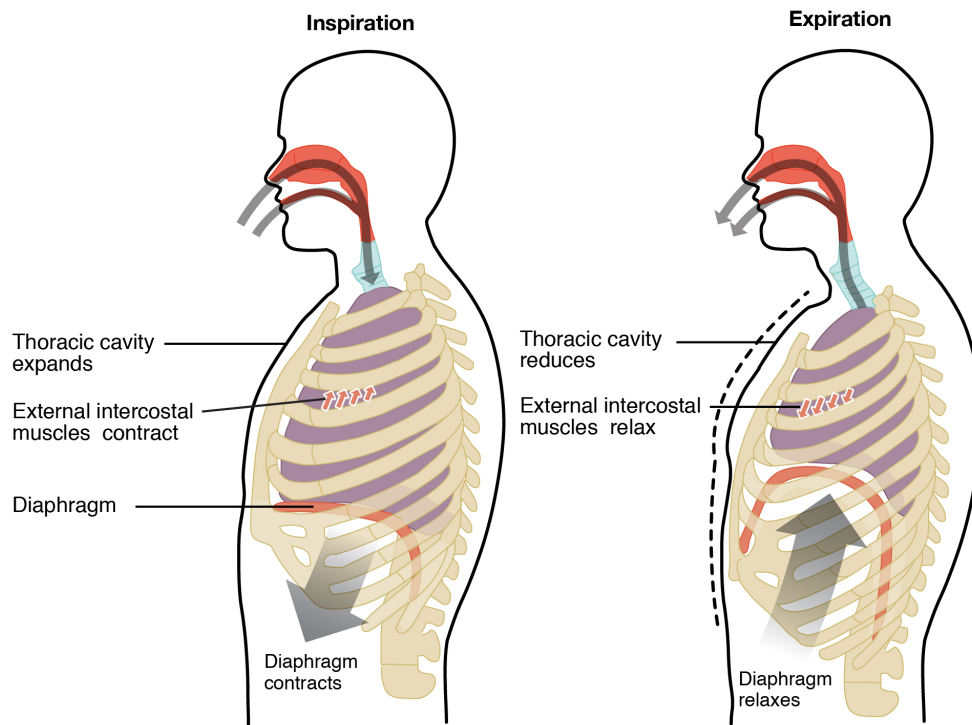


Figure 4.10 Inhalation and Exhalation

Health care professionals use an instrument called a **stethoscope** (STETH-ŏ-skōp) to listen to internal body sounds like lung sounds. Lung sounds are

2. This work is a derivative of [Anatomy and Physiology](#) by [OpenStax](#) licensed under [CC BY 4.0](#). Access for free at <https://openstax.org/books/anatomy-and-physiology/pages/1-introduction>
3. “[2316_Inspiration_and_Expiration.jpg](#)” by OpenStax College is licensed under [CC BY 3.0](#)

caused by the movement of air from the trachea to the bronchioles to the alveoli and can be impacted by the presence of sputum, bronchoconstriction, or fluid in the alveoli. These sounds are referred to as rhonchi (coarse crackles), rales (fine crackles), wheezes, stridor, and pleural rub⁴:

- **Rhonchi** (rǒng-kahy), also referred to as coarse crackles, are low-pitched, continuous sounds heard on expiration that are a sign of turbulent airflow through mucus in the large airways.
- **Rales** (rāylz), also called fine crackles, are popping or crackling sounds heard on inspiration. They are associated with medical conditions, such as heart failure or pneumonia, that cause fluid accumulation within the alveolar and interstitial spaces. The sound is similar to that produced by rubbing strands of hair together close to your ear.
- **Wheezes** (wēz-ěz) are whistling noises produced when air is forced through airways narrowed by bronchoconstriction or mucosal edema. For example, patients with asthma commonly have wheezing.
- **Stridor** (strī-door) is heard only on inspiration. It is associated with obstruction of the trachea/upper airway.
- **Pleural rub** (plur-uhl ruh) sounds like the rubbing together of leather and can be heard on inspiration and expiration. It is caused by inflammation of the pleura membranes that results in friction as the surfaces rub against each other.



View the following YouTube video⁵ to review the

4. This work is a derivative of Open RN [Nursing Skills 2e](#) by Chippewa Valley Technical College with [CC BY 4.0](#) licensing.

5. Chandra, S. (2017, November 1). *Mechanics of breathing AIDA*



mechanics of breathing: [Mechanics of Breathing AIDA Freediving](#)

Forced breathing, also known as **hyperpnea** (hī-pěrp-NĒ-ă), is a type of breathing that can occur during exercise or actions that require the active manipulation of breathing, such as singing. During forced breathing, muscle contractions of accessory muscles, in addition to the diaphragm, are used for inspiration and expiration. These additional muscle contractions during inspiration also occur during **labored breathing** (LĀ-börd BRĒ-thĭng), a symptom of many respiratory disorders.⁶

The word root *pnea* refers to breathe. Therefore, **tachypnea** (tak-ip-NĒ-ă) refers to rapid breathing, **bradypnea** (brăd-ĪP-nē-ă) refers to slow breathing, **hypopnea** (hī-POP-ne-ă) refers to deficient breathing, and **apnea** (AP-nē-ă) refers to the absence of breathing. **Dyspnea** (disp-NĒ-ă) is a common symptom of respiratory disorders and refers to difficulty breathing.

CONTROL OF BREATHING

Respiratory rate (RES-pĭr-ă-tō-rē rāt) is the number of breaths taken per minute. The normal respiratory rate for adults is 12-20 breaths per minute. A

freediving [Video]. YouTube. All rights reserved. https://youtu.be/baYZ_dgGIWw?si=_Vwrlr9J8vNSZuwA

6. This work is a derivative of [Anatomy and Physiology](#) by [OpenStax](#) licensed under [CC BY 4.0](#). Access for free at <https://openstax.org/books/anatomy-and-physiology/pages/1-introduction>

child under 1 year of age has a normal respiratory rate between 30 and 60 breaths per minute. By the time a child is about 10 years old, the normal rate is closer to 18 to 30. Respiratory rate can be an important indicator of a respiratory disorder because the rate may increase or decrease during illness or disease.⁷

The respiratory rate is controlled by the respiratory center located within the medulla oblongata and the pons in the brain stem, which responds primarily to changes in carbon dioxide, oxygen, and pH levels in the blood. These changes are sensed by central chemoreceptors, which are located in the brain, and peripheral chemoreceptors, which are located in the aortic arch and carotid arteries. The major factor that drives breathing is surprisingly not **hypoxemia** (hī-pők-SĒ-mē-ă), low levels of oxygen in the blood, rather the concentration of carbon dioxide. Carbon dioxide is a waste product of cellular respiration and is toxic at high levels in the blood, referred to as **hypercapnia** (hī-pěr-KAP-nē-ă). As carbon dioxide levels in the blood increase, the central chemoreceptors stimulate the contraction of the diaphragm and intercostal muscles (i.e., the muscles between the ribs), and the rate and depth of respiration increase to help rid the body of carbon dioxide. **Hyperventilation** (hī-pěr-vĕn-tĭ-LĀ-shŭn) refers to rapid and deep breathing. In contrast, low levels of carbon dioxide in the blood stimulate shallow, slow breathing to help the body retain carbon dioxide. **Hypoventilation** (hī-pō-vĕn-tĭ-LĀ-shŭn) refers to slow and shallow breathing.⁸

7. This work is a derivative of [Anatomy and Physiology](#) by [OpenStax](#) licensed under [CC BY 4.0](#). Access for free at <https://openstax.org/books/anatomy-and-physiology/pages/1-introduction>

8. This work is a derivative of [Anatomy and Physiology](#) by [OpenStax](#) licensed under [CC BY 4.0](#). Access for free at <https://openstax.org/books/anatomy-and-physiology/pages/1-introduction>

GAS EXCHANGE

Ventilation (i.e., the mechanics of breathing) provides air to the alveoli in the lungs for gas exchange. **Respiration** (rĕs-pĭ-RĀ-shŏn) refers to the exchange of gases in the lungs between the alveoli and the pulmonary capillaries or in the tissues between the systemic capillaries and cells/tissues.⁹

Gas exchange refers to the exchange of oxygen and carbon dioxide through capillary walls of the alveoli and the pulmonary capillaries, called external respiration. During external respiration, oxygen from the air we breathe diffuses into the blood. Carbon dioxide (waste) diffuses out of the blood and into the alveoli where it can be exhaled. Throughout the rest of the body, gas exchange also occurs between the systemic capillaries and body cells/tissues, called internal respiration. During internal respiration, oxygen diffuses out of the systemic capillaries and into the surrounding cells and tissues, and carbon dioxide diffuses from the cells/tissues into the systemic capillaries where it is carried to the lungs. It is through this process that cells in the body are oxygenated and carbon dioxide, the waste product of cellular respiration, is removed from the body.¹⁰

Asphyxia (ăs-FIK-sĕ-ă) refers to deprivation of oxygen to the tissues, commonly referred to as suffocation.

9. This work is a derivative of [Anatomy and Physiology](https://openstax.org/books/anatomy-and-physiology/pages/1-introduction) by [OpenStax](https://openstax.org/books/anatomy-and-physiology/pages/1-introduction) licensed under [CC BY 4.0](https://creativecommons.org/licenses/by/4.0/). Access for free at <https://openstax.org/books/anatomy-and-physiology/pages/1-introduction>

10. This work is a derivative of [Anatomy and Physiology](https://openstax.org/books/anatomy-and-physiology/pages/1-introduction) by [OpenStax](https://openstax.org/books/anatomy-and-physiology/pages/1-introduction) licensed under [CC BY 4.0](https://creativecommons.org/licenses/by/4.0/). Access for free at <https://openstax.org/books/anatomy-and-physiology/pages/1-introduction>

PERFUSION

In addition to adequate ventilation, the second important aspect of gas exchange is perfusion. **Perfusion** (pěr-FYŮ-zhŭn) refers to the flow of blood. In the lungs, perfusion occurs in the **pulmonary circulation** (PŮL-mŭ-năř-ē sěr-kyŏŏ-LĀ-shŭn), as it moves from the heart to the lungs and then back to the heart for distribution to the body. The **pulmonary arteries** (PŮL-mō-ně-rē ār-tě-rēs) carry deoxygenated blood from the heart into the lungs, where they branch and eventually become the capillary network composed of pulmonary capillaries. These pulmonary capillaries create the respiratory membrane with the alveoli. As the blood is pumped through this capillary network, gas exchange occurs.¹¹

Although a small amount of the oxygen is able to dissolve directly into the blood from the alveoli, most of the oxygen binds to **hemoglobin** (HĚ-mō-glō-bŭn) within red blood cells (erythrocytes). The more oxygen the hemoglobin in red blood cells carry, the brighter red the color of the blood. Oxygenated blood returns to the heart through the pulmonary veins to the left atrium and ventricle, where it is pumped out to the body via the aorta. The hemoglobin on the red blood cells transports the oxygen to the tissues throughout the body.¹²

11. This work is a derivative of [Anatomy and Physiology](https://openstax.org/books/anatomy-and-physiology/pages/1-introduction) by [OpenStax](https://openstax.org/books/anatomy-and-physiology/pages/1-introduction) licensed under [CC BY 4.0](https://creativecommons.org/licenses/by/4.0/). Access for free at <https://openstax.org/books/anatomy-and-physiology/pages/1-introduction>

12. This work is a derivative of [Anatomy and Physiology](https://openstax.org/books/anatomy-and-physiology/pages/1-introduction) by [OpenStax](https://openstax.org/books/anatomy-and-physiology/pages/1-introduction) licensed under [CC BY 4.0](https://creativecommons.org/licenses/by/4.0/). Access for free at <https://openstax.org/books/anatomy-and-physiology/pages/1-introduction>

HYPOXIA

Diseases and disorders affecting the respiratory system can cause **hypoxia** (hī-PŎK-sē-ă), low levels of oxygen in the tissues. A patient's oxygenation status is routinely assessed by health care professionals using pulse oximetry. **Pulse oximetry** (pŭls ōk-SĪM-ĭ-trē) is an estimated oxygenation level based on the saturation of hemoglobin measured by a pulse oximeter. Because the majority of oxygen carried in the blood is attached to hemoglobin within the red blood cells, pulse oximetry estimates how much hemoglobin is "saturated" with oxygen. The normal range for pulse oximetry is 94-100%.¹³

Hypoxia can occur due to inadequate ventilation or impaired perfusion. For example, a medical condition called **pulmonary edema** (PŪL-mō-ně-rē ě-DĒ-mă) refers to fluid accumulation in alveoli, often caused by heart failure or kidney failure. As a result of the fluid, oxygen cannot move across the alveolar membrane into the blood, and carbon dioxide cannot be removed from the blood. As a result, hypoxia and hypercapnia (high levels of carbon dioxide) may occur, requiring urgent medical interventions to sustain life by decreasing carbon dioxide levels and increasing oxygen levels.¹⁴



View supplementary YouTube videos for additional review of the respiratory system:

13. This work is a derivative of [Anatomy and Physiology](https://openstax.org/books/anatomy-and-physiology/pages/1-introduction) by [OpenStax](https://openstax.org/books/anatomy-and-physiology/pages/1-introduction) licensed under [CC BY 4.0](https://creativecommons.org/licenses/by/4.0/). Access for free at <https://openstax.org/books/anatomy-and-physiology/pages/1-introduction>
14. This work is a derivative of [Anatomy and Physiology](https://openstax.org/books/anatomy-and-physiology/pages/1-introduction) by [OpenStax](https://openstax.org/books/anatomy-and-physiology/pages/1-introduction) licensed under [CC BY 4.0](https://creativecommons.org/licenses/by/4.0/). Access for free at <https://openstax.org/books/anatomy-and-physiology/pages/1-introduction>

Respiratory System¹⁵

Overview of the Respiratory System, Animation¹⁶

Respiratory System, Part 1: Crash Course A&P #31¹⁷

15. Amoeba Sisters. (2022, February 28). *Respiratory system* [Video]. YouTube. All rights reserved. https://www.youtube.com/watch?v=v_j-LD2YEgg
16. Alila Medical Media. (2019, April 15). *Overview of the respiratory system, animation* [Video]. YouTube. All rights reserved. <https://youtu.be/03qvN5pjCTU?si=LJRgMq6RwLiUhcxF>
17. CrashCourse. (2015, August 24). *Respiratory system, Part 1: Crash Course Anatomy & Physiology #31* [Video]. YouTube. All rights reserved. <https://youtu.be/bHZsvBdUC2I>

4.6 Diseases and Disorders of the Respiratory System

This section provides an overview of common respiratory disorders and diseases.

ALLERGIES

Allergies (ÄL-ër-jēz) occur when a person's immune system reacts to a substance and makes antibodies that identify that substance as harmful. Substances identified as allergens can cause inflammation of the skin, sinuses, nasal passages, airways, or digestive system. The severity of allergies varies from person to person and can range from minor irritation to a potentially life-threatening emergency called **anaphylaxis** (ăn-ă-fī-LĂK-sīs). While most allergies can't be cured, allergy medications can help relieve symptoms.¹

There are many types of allergies. Allergic rhinitis, commonly referred to as "hay fever," can cause sneezing; **pruritus** (PRŪ-rī-tūs), itching of the skin, as well as itching of the nose, eyes, or roof of the mouth; rhinorrhea; and watery, red, or swollen eyes. A food allergy can cause tingling in the mouth; swelling of the lips, tongue, face, or throat; hives; and anaphylaxis. Read more information about anaphylaxis in the following subsection. An insect sting allergy can cause swelling at the sting site, itching or hives all over the body, cough, chest tightness, wheezing, shortness of breath, and anaphylaxis. A

1. Mayo Clinic Staff. (2022, August 5). *Allergies*. <https://www.mayoclinic.org/diseases-conditions/allergies/symptoms-causes/syc-20351497>

drug allergy can cause hives, pruritus, rash, swelling in the respiratory tract, and anaphylaxis.

ANAPHYLAXIS

Severe allergies, including allergies to foods, insect stings, medications, and blood transfusions, can trigger a severe reaction known as anaphylaxis. As a life-threatening medical emergency, anaphylaxis can cause a patient to go into anaphylactic shock, a potentially fatal condition. Signs and symptoms of anaphylaxis are as follows²:

- Loss of consciousness
- Drop in blood pressure
- Severe shortness of breath
- Skin rash
- Light-headedness
- Rapid, weak pulse
- Nausea and vomiting

Treatment of anaphylaxis often requires injection of a medication called epinephrine to rapidly reduce the body's allergic response and restore adequate respiratory status.

2. Mayo Clinic. (2021). *Anaphylaxis*. <https://www.mayoclinic.org/diseases-conditions/anaphylaxis/symptoms-causes/syc-20351468>

ASTHMA

Asthma (AZ-muh) is a common chronic respiratory condition that can affect all age groups. Asthma is characterized by episodes of inflammation and edema of the airways and bronchospasms that prevent air from entering the lungs. Excessive mucus secretion can also occur, which further contributes to blockage of the airway and shortness of breath. Bronchospasms can lead to **asthma attacks** (ĂZ-mă ă-TĂKS) that can range from mild to severe and can be life-threatening. An asthma attack may be triggered by environmental factors such as dust, pollen, pet hair, or dander; changes in the weather; mold; tobacco smoke; respiratory infections; or by exercise and stress.³ Between episodes of asthma attacks, many individuals with asthma are asymptomatic. See Figure 4.11⁴ for an illustration of how asthma affects the airways.

3. This work is a derivative of [Anatomy and Physiology](#) by [OpenStax](#) licensed under [CC BY 4.0](#). Access for free at <https://openstax.org/books/anatomy-and-physiology/pages/1-introduction>

4. "[Asthma attack-illustration_NIH.jpg](#)" by United States-National Institute of Health: National Heart, Lung, Blood Institute is in the [Public Domain](#)

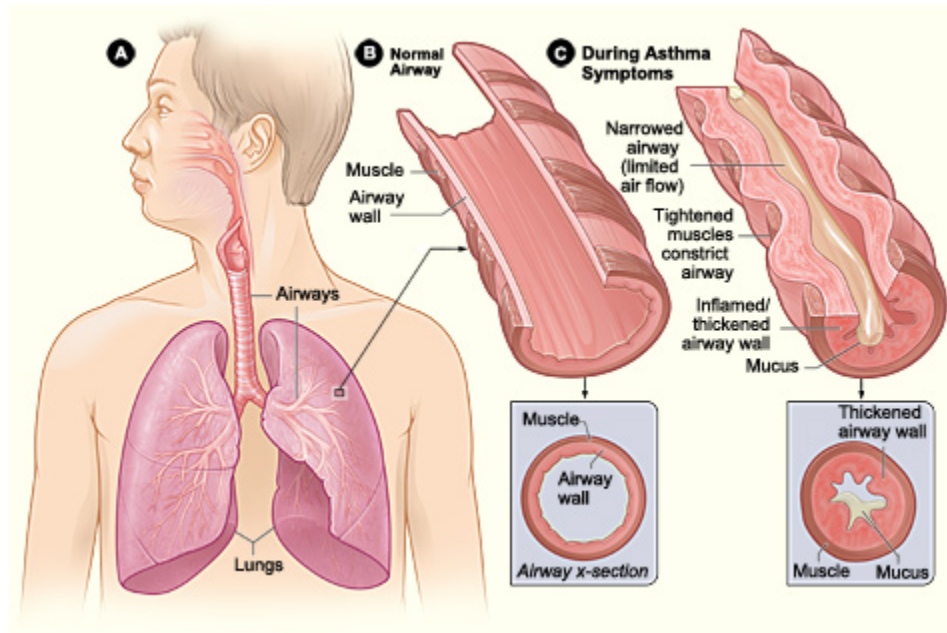


Figure 4.11 How Asthma Affects the Airways

Symptoms of an asthma attack involve coughing, dyspnea (shortness of breath), wheezing, and tightness of the chest. Severe asthma attacks can be fatal and require immediate medical attention. Symptoms of a severe asthma attack include worsening dyspnea that can cause **cyanotic** (sī-ă-NŌT-ĭk) or blue lips or fingertips, worsening wheezing, confusion, drowsiness, a rapid pulse, sweating, and severe anxiety.⁵

Chronic asthma is typically diagnosed by health care providers by using pulmonary function tests. Read more about pulmonary function tests in the “[Medical Specialists, Diagnostic Testing, and Procedures Related to the Respiratory System](#)” section of this chapter. Individuals with asthma are often prescribed a **peak flow meter** (pēk flō mē-tēr), a portable instrument used to measure air flow during forced exhalation, to help manage their symptoms.

Asthma is treated by respiratory medications given via an inhaler and/or

5. This work is a derivative of [Anatomy and Physiology](#) by [OpenStax](#) licensed under [CC BY 4.0](#). Access for free at <https://openstax.org/books/anatomy-and-physiology/pages/1-introduction>

nebulizer (NEB-yŭ-lī-zĕr). A nebulizer is a medical device that creates a mist for delivering respiratory medication. Inhalers may be referred to as dry powder inhalers (DPI) or metered dose inhalers (MDI). The severity of the condition, frequency of attacks, and identified triggers influence the type of medication that an individual may require. Long-term treatments for patients with severe asthma include oral and/or injectable medications.⁶ See Figures 4.12,⁷ 4.13,⁸ and 4.14⁹ for images of an albuterol inhaler, respiratory medication used in a nebulizer, and a nebulizer.

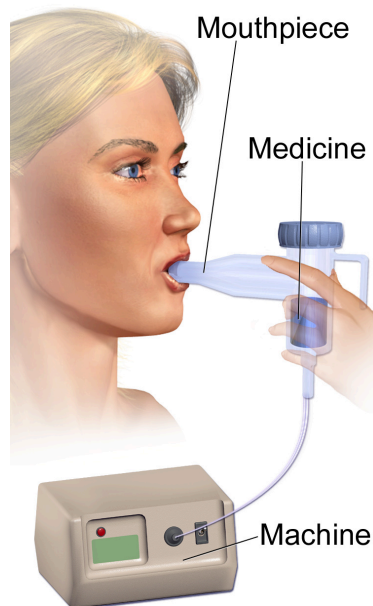


Figure 4.12 Albuterol Inhaler

6. This work is a derivative of [Anatomy and Physiology](#) by [OpenStax](#) licensed under [CC BY 4.0](#). Access for free at <https://openstax.org/books/anatomy-and-physiology/pages/1-introduction>
7. "[Ventolin® HFA \(Albuterol Sulfate\) Inhaler.jpg](#)" by [MisterNarwhal](#) is licensed under [CC BY SA 4.0](#)
8. "[Albuterol 2.jpg](#)" by [Mark Oniffrey](#) is licensed under [CC BY SA 4.0](#)
9. "[Nebulizer_Mouthpiece.png](#)" by [BruceBlaus](#) is licensed under [CC BY-SA 4.0](#)

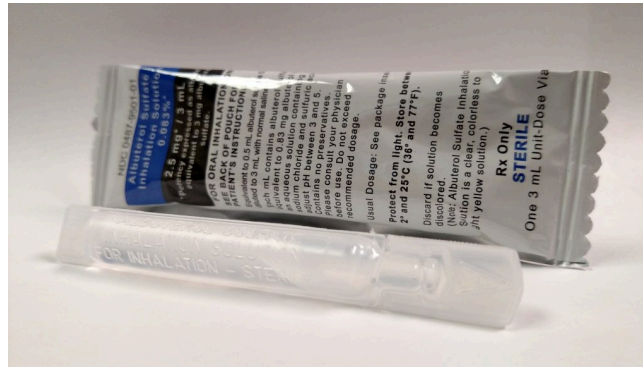


Figure 4.13 Medication Used in a Nebulizer



Using a Nebulizer with a Mouthpiece

Figure 4.14 Nebulizer

- ▶ To learn more about asthma, visit the [Centers for Disease Control and Prevention \(CDC\) web page on asthma](#).

View the following YouTube video¹⁰ for additional
 information about asthma: [How Does Asthma Work? – Christopher E. Gaw](#)

BRONCHITIS

Bronchitis is an inflammation of the lining of the bronchial tubes, which carry air to and from the lungs. People who have bronchitis often cough up thickened mucus, which can be discolored. Bronchitis may be either acute or chronic.

Often developing from a cold or other respiratory infection, acute bronchitis is very common. Acute bronchitis, also called a chest cold, usually improves within a week to ten days without lasting effects, although the cough may linger for weeks.

Chronic bronchitis (KRŎN-ĭk brŏng-KĪ-tĭs), a more serious condition, is a constant irritation or inflammation of the lining of the bronchial tubes, often due to smoking. Chronic bronchitis is one of the conditions included in

10. TED-Ed. (2017, May 11). *How does asthma work? – Christopher E. Gaw* [Video]. YouTube. <https://youtu.be/PzfLDi-sL3w>

chronic obstructive pulmonary disease (COPD).¹¹ Read more about COPD in the following subsection.

Symptoms for either acute bronchitis or chronic bronchitis may include the following:

- Cough
- Production of mucus (sputum), which can be clear, white, yellowish-gray, or green in color — rarely, it may be streaked with blood
- Fatigue
- Shortness of breath
- Slight fever and chills
- Chest discomfort

CHRONIC OBSTRUCTIVE PULMONARY DISEASE

Chronic obstructive pulmonary disease (KRŎN-ĭk ōb-STRŬK-tĭv PŬL-mō-nĕ-rĕ dĭ-ZĒZ) (**COPD**) is an inflammatory lung disease that causes obstructed airflow out of the lungs. COPD is a chronic condition with most symptoms appearing in people in their middle 50s. COPD is most often caused by smoking but can also be caused by long-term exposure to irritating gases or dust. People with COPD are at increased risk of developing heart disease, lung cancer, and a variety of other conditions.

Emphysema and chronic bronchitis are the two types of COPD that often occur together. **Emphysema** (ĕm-fŭ-SĒ-mă) is a disorder affecting the alveoli where they become abnormally inflated, damaging their walls and making it harder to breathe. Chronic bronchitis is inflammation of the lining of the

11. Mayo Clinic Staff. (2017, April 11). *Bronchitis*. <https://www.mayoclinic.org/diseases-conditions/bronchitis/symptoms-causes/syc-20355566>

bronchial tubes and characterized by chronic cough and mucus (sputum) production. See Figure 4.15 for an illustration of normal lungs compared to lungs with COPD.¹²

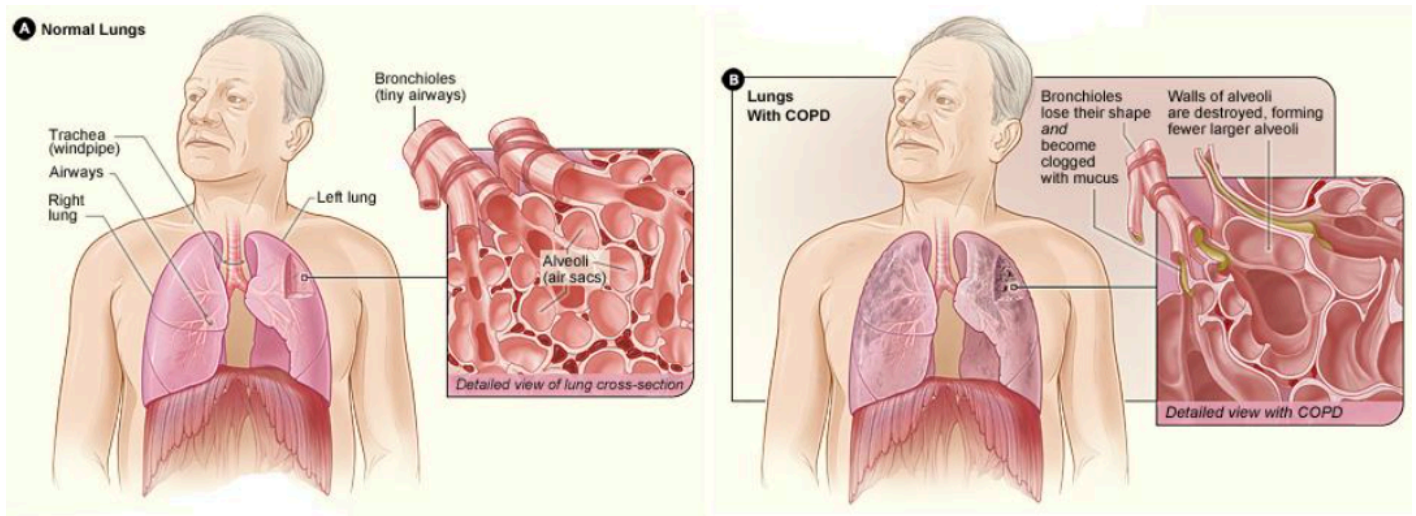


Figure 4.15 Normal Lungs Compared to Lungs in a Person With COPD

COPD symptoms often don't appear until significant lung damage has occurred, and they usually worsen over time, particularly if smoke exposure continues. Common signs and symptoms of COPD include the following:

- Dyspnea (shortness of breath), especially during physical activities
- **Wheezing** (HWĒ-zĭng) (breathing with a whistling or rattling sound in the chest)
- Chronic cough
- Excessive sputum (mucus from the respiratory tract) that may be clear, white, yellow, or greenish
- Frequent respiratory infections
- Lack of energy

12. “Copd 2010Side.JPG” by [National Heart, Lung, and Blood Institute](#) is licensed in the [Public Domain](#).

- Barrel chest (enlarged, rounded chest)
- Unintended weight loss (in later stages)

Signs and symptoms of COPD worsen during **exacerbations** (ěg-ză-sěr-BĀ-shŭns) or flare-ups and can result in hospitalization. Symptoms of COPD exacerbation may include worsening dyspnea, green or brown mucus, fever, **cyanosis** (sī-ă-NŌ-sīs) or blue lips or fingers caused by lack of oxygenation of tissues, and increased fatigue.

COPD is diagnosed by health care providers using spirometry. Spirometry is further described in pulmonary function tests in the “[Medical Specialists, Diagnostic Testing, and Procedures Related to the Respiratory System](#)” section of this chapter.

COPD is progressive disease that is treatable but not curable. Shortness of breath may be controlled with a medication called a **bronchodilator** (brŏng-kō-dī-LĀ-tŭr), a drug that relaxes and expands the bronchi. The best way to avoid exacerbations is to avoid triggers, avoid people who are sick, get the annual flu shot, and reduce exposure to cigarette smoke and pollution.¹³ The majority of cases of COPD are caused by cigarette smoking, and the best way to prevent COPD is to never smoke or stop smoking.¹⁴

► To learn more about COPD, visit the [Centers for Disease Control and Prevention’s web page on COPD](#).

13. Centers for Disease Control and Prevention. (2023, June 30). *What is COPD?* <https://www.cdc.gov/copd/index.html>

14. Mayo Clinic Staff. (2020, April 15). *COPD*. <https://www.mayoclinic.org/diseases-conditions/copd/symptoms-causes/syc-20353679>

The Effects of Second-Hand Tobacco Smoke

The burning of a tobacco cigarette creates multiple chemical compounds that are released through mainstream smoke, which is inhaled by the smoker, and through sidestream smoke, which is the smoke that is given off by the burning cigarette. Second-hand smoke, which is a combination of sidestream smoke and the mainstream smoke that is exhaled by the smoker, has been demonstrated by numerous scientific studies to cause disease. At least 40 chemicals in sidestream smoke have been identified that negatively impact human health, leading to the development of COPD, cancer, or other conditions, such as immune system dysfunction, liver toxicity, cardiac arrhythmias, pulmonary edema, and neurological dysfunction. Furthermore, second-hand smoke has been found to harbor at least 250 compounds that are known to be toxic, carcinogenic, or both. Some major classes of carcinogens in second-hand smoke are polyaromatic hydrocarbons (PAHs), N-nitrosamines, aromatic amines, formaldehyde, and acetaldehyde.

Tobacco and second-hand smoke are considered to be carcinogenic. Exposure to second-hand smoke can cause lung cancer in individuals who are not tobacco users themselves. It is estimated that the risk of developing lung cancer is increased by up to 30 percent in nonsmokers who live with an individual who smokes in the house, as compared to nonsmokers who are not regularly exposed to second-hand smoke. Children are especially affected by second-hand smoke. Children who live with an individual who smokes inside the home have a larger number of lower respiratory infections, which are associated with hospitalizations, and higher risk of sudden infant death syndrome (SIDS). Second-hand smoke in the home has also

been linked to a greater number of ear infections in children, as well as worsening symptoms of asthma.¹⁵

COMMON COLD

The common cold, also known as an upper respiratory infection (URI) is a viral infection of the upper respiratory tract. Many types of viruses can cause a common cold. Children younger than six are at greatest risk of colds, but healthy adults can also expect to have two or three colds annually. Most people recover from a common cold within a week to ten days. Symptoms might last longer in people who smoke.

Symptoms of a common cold usually appear one to three days after exposure to a cold-causing virus. Signs and symptoms, which can vary from person to person, are as follows¹⁶:

- Runny or stuffy nose
- Sore throat
- Cough
- Congestion
- Slight body aches or a mild headache
- Sneezing

15. This work is a derivative of [Anatomy and Physiology](https://openstax.org/books/anatomy-and-physiology/pages/1-introduction) by OpenStax licensed under [CC BY 4.0](https://creativecommons.org/licenses/by/4.0/). Access for free at <https://openstax.org/books/anatomy-and-physiology/pages/1-introduction>

16. Mayo Clinic Staff. (2023, May 24). *Common cold*. <https://www.mayoclinic.org/diseases-conditions/common-cold/symptoms-causes/syc-20351605>

- Low-grade fever
- Generally feeling unwell (malaise)

CORONAVIRUS (COVID-19)

Influenza and COVID-19 are both highly contagious respiratory illnesses, but they are caused by different viruses. COVID-19 is caused by infection with a coronavirus named SARS-CoV-2. You cannot tell the difference between the common cold, influenza, and COVID-19 by symptoms alone because all have similar symptoms. Individuals with symptoms should get tested for both influenza and COVID-19 and take appropriate precautions to prevent the spread of infection.¹⁷

- ▶ To read current information about COVID-19 symptoms and treatment, go to the [Centers for Disease Control and Prevention \(CDC\) website on COVID-19](https://www.cdc.gov/coronavirus/2019-ncov/).

CYSTIC FIBROSIS

Cystic fibrosis (SĪS-tĭk fĭ-BRŌ-sĭs) is a genetic disease that causes problems with breathing and digestion. People with cystic fibrosis have thick, sticky mucus that builds up in the lungs and digestive tract and other areas of the

¹⁷. Centers for Disease Control and Prevention. (n.d.). *COVID-19*.
<https://www.cdc.gov/coronavirus/2019-ncov/>

body. This excessive mucus blocks airways, traps germs, makes respiratory infections more likely, and leads to lung damage. It also affects the pancreas, with the increased secretions preventing digestive enzymes from reaching the intestines, which decreases the body's ability to absorb nutrients from food.¹⁸

INFLUENZA

Influenza (in-floo-EN-ză), commonly referred to as the “flu,” is a highly contagious viral infection affecting the respiratory tract. Symptoms of influenza include fever, cough, sore throat, rhinorrhea (runny nose), muscle aches, headache, and fatigue (severe tiredness). Most people who get influenza will recover in less than two weeks, but some people develop complications (such as pneumonia) that can be life-threatening. Anyone can get influenza, even healthy people, and serious problems related to the flu can happen to anyone at any age, but some people are at higher risk of developing serious flu-related complications if they get sick. This includes people 65 years and older, people of any age with certain chronic medical conditions (such as asthma, diabetes, or heart disease), pregnant women, and children younger than five years old. Everyone aged six months and older should get an annual flu vaccine, ideally by the end of October, to prevent influenza and its potential complications.¹⁹

18. Centers for Disease Control and Prevention. (2022, May 9). *Cystic fibrosis*. https://www.cdc.gov/genomics/disease/cystic_fibrosis.htm

19. Centers for Disease Control and Prevention. (2022, October 3). *Flu symptoms & complications*. <https://www.cdc.gov/flu/symptoms/symptoms.htm>

LUNG CANCER

Cancer (KĂN-sör) is a disease in which cells in the body grow out of control. When cancer begins in the lungs, it is called **lung cancer** (lŭng KĂN-sör), although it may spread to lymph nodes or other organs in the body, such as the brain. Cancer from other organs also may spread to the lungs. When cancer cells spread from one organ to another, they are called **metastases** (mě-TĂS-tă-sēz).²⁰

Cigarette smoking is the number one risk factor for lung cancer. In the United States, cigarette smoking is linked to about 80% to 90% of lung cancer deaths. People who quit smoking at any age have a lower risk of lung cancer than if they had continued to smoke, but their risk is higher than the risk for people who never smoked.²¹

After smoking, radon is the second leading cause of lung cancer in the United States. Radon is a naturally occurring gas that forms in rocks, soil, and water. It cannot be seen, tasted, or smelled. When radon gets into homes or buildings through cracks or holes, it can get trapped and build up in the air inside. People who live or work in these homes and buildings breathe in high radon levels. Over long periods of time, radon can cause lung cancer.²²

Most people with lung cancer don't have symptoms until the cancer is

20. Centers for Disease Control and Prevention. (2023, July 31). *What is lung cancer?* https://www.cdc.gov/cancer/lung/basic_info/what-is-lung-cancer.htm
21. Centers for Disease Control and Prevention. (2023, July 31). *What is lung cancer?* https://www.cdc.gov/cancer/lung/basic_info/what-is-lung-cancer.htm
22. Centers for Disease Control and Prevention. (2023, July 31). *What are the risk factors for lung cancer?* https://www.cdc.gov/cancer/lung/basic_info/risk_factors.htm

advanced and has metastasized. Lung cancer symptoms may include the following²³:

- Coughing that gets worse or doesn't go away
- Chest pain
- Shortness of breath
- Wheezing
- **Hemoptysis** (hē-MŎP-tĭ-sĭs) (coughing up blood)
- Fatigue (feeling very tired all the time)
- Weight loss with no known cause
- Repeated episodes of pneumonia
- Swollen or enlarged lymph nodes inside the chest in the area between the lungs

Lung cancer may initially be suspected after routine tests like **chest X-rays** (chĕst ěks-rās), also referred to as **radiographs** (RĀ-dē-ŏ-grāfs). Additional diagnostic testing is performed if lung cancer is suspected. Read more about diagnostic tests in the “[Medical Specialists, Diagnostic Testing, and Procedures Related to the Respiratory System](#)” section of this chapter.

Treatments for lung cancer may include surgery, chemotherapy, targeted therapy, immunotherapy, and radiation therapy.

23. Centers for Disease Control and Prevention. (2023, July 31). *What are the symptoms of lung cancer?* https://www.cdc.gov/cancer/lung/basic_info/symptoms.htm

OBSTRUCTIVE SLEEP APNEA

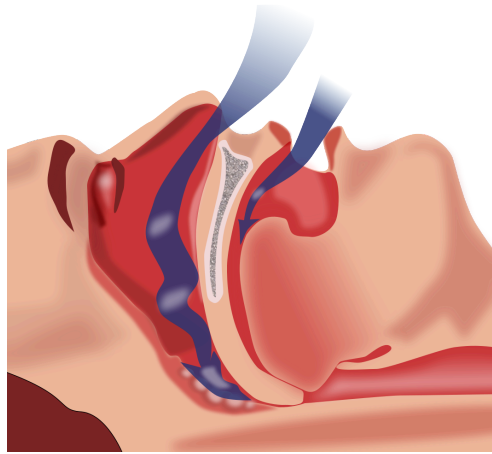


Figure 4.16 Obstructive Sleep Apnea

Obstructive sleep apnea (öb-STRÜK-tív slēp äp-NĒ-ä) is a chronic disorder that can occur in children and adults. It is characterized by periods of no breathing during sleep. These episodes may last for several seconds or several minutes and may differ in the frequency with which they are experienced. Sleep apnea leads to poor sleep. Symptoms of sleep apnea include fatigue, evening napping, irritability, memory problems, morning headaches, and excessive snoring. A diagnosis of sleep apnea is usually done during a sleep study, where the patient is monitored in a sleep laboratory or with home testing. Treatment of sleep apnea commonly includes the use of a device called a **continuous positive airway pressure device** (kõn-TĪN-yū-üs POZ-ĩ-tĭv AIR-wā PRESS-ür dĩ-VĪS) (**CPAP**) during sleep. The CPAP machine has a mask that covers the nose, or the nose and mouth, and forces air into the airway at regular intervals. This pressurized air can help to gently force the airway to remain open, allowing for more normal ventilation to occur.²⁴ Read more

24. Slowik, J. M., Sankari, A., & Collen, J. F. (2022). *Obstructive sleep apnea*.

about a CPAP device in the “[Medical Specialists, Diagnostic Testing, and Procedures Related to the Respiratory System](#)” section. See Figure 4.16²⁵ for an illustration of obstructive sleep apnea. As soft tissue falls to the back of the throat, it impedes the passage of air (blue arrows) through the trachea and is characterized by repeated episodes of complete or partial obstructions of the upper airway during sleep.

Figure 4.16 Obstructive Sleep Apnea

PNEUMONIA

Pneumonia is an infection of the alveoli of the lungs caused by microorganisms like bacteria, viruses, or fungi that can cause mild to severe illness in people of all ages.

Symptoms of pneumonia are as follows²⁶:

- Cough, which may produce greenish or yellow mucus (often called purulent sputum)
- Fever and shaking chills
- Dyspnea (shortness of breath)
- Rapid, shallow breathing

[Updated 2022 Dec 11]. In: StatPearls [Internet]. <https://www.ncbi.nlm.nih.gov/books/NBK459252/>

25. “[Obstruction ventilation apnée sommeil.svg](#)” by [Habib M'henni](#) is in the [Public Domain](#).

26. American Lung Association. (2023, August 3). *Pneumonia symptoms and diagnosis*. <https://www.lung.org/lung-health-diseases/lung-disease-lookup/pneumonia/symptoms-and-diagnosis>

- Sharp or stabbing chest pain that gets worse when breathing deeply or coughing
- Loss of appetite, low energy, and fatigue

See Figure 4.17²⁷ for an image of purulent sputum.

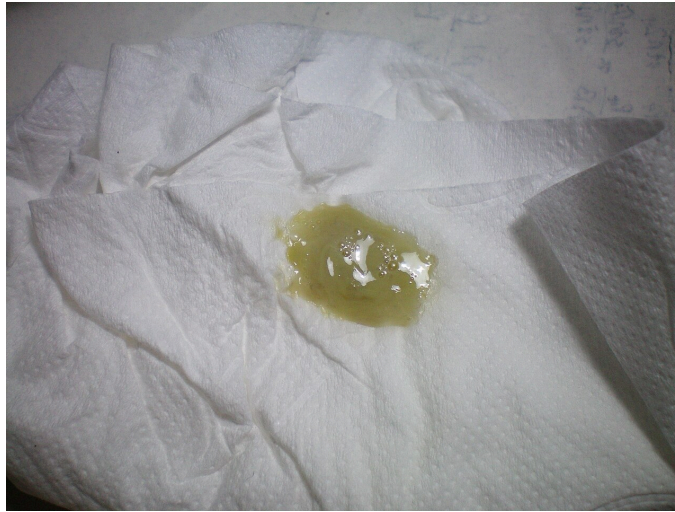

Figure 4.17 Purulent Sputum

Common diagnostic tests for pneumonia include sputum cultures and chest X-rays. Read more about these diagnostic tests in the “[Medical Specialists, Diagnostic Testing, and Procedures Related to the Respiratory System](#)” section of this chapter.

There are several categories of pneumonia that are treated with different types of antibiotics²⁸:

- **Aspiration pneumonia:** Pneumonia that occurs when food or liquid is

27. “[Sputum.JPG](#)” by [Zhangmoon618](#) is licensed under [CC0](#)

28. Centers for Disease Control and Prevention. (2022, September 30). *Causes of pneumonia*. <https://www.cdc.gov/pneumonia/causes.html>

breathed into the airways or lungs, instead of being swallowed.

- **Community-acquired pneumonia:** Pneumonia that is diagnosed in someone in the community (not in a hospital).
- **Healthcare-associated pneumonia:** Pneumonia that is diagnosed in someone during or following a stay in a health care setting.
- **Ventilator-associated pneumonia:** Pneumonia that is diagnosed in someone who has been on a ventilator.

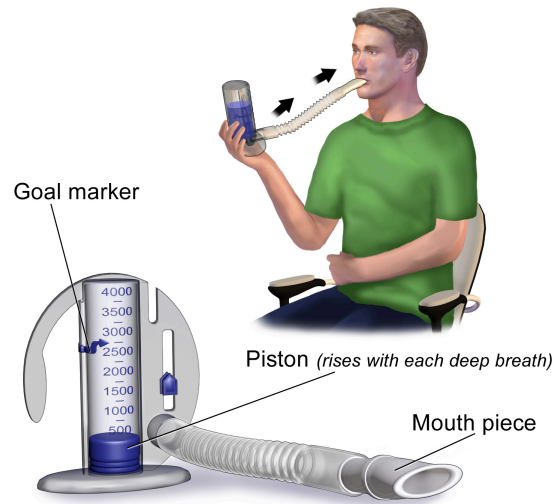Incentive Spirometry

Patients who have undergone surgery are at risk for developing atelectasis and pneumonia. Atelectasis means the alveoli have become deflated, which can cause a partial or complete collapsed lung and/or lead to pneumonia. An incentive spirometer is a medical device often prescribed as a preventative measure after surgery or for patients with atelectasis. While sitting upright, the patient should breathe in slowly and deeply through the tubing with the goal of raising the piston to a specified level. See Figure 4.18²⁹ for an image of a patient using an incentive spirometer. The patient should attempt to hold their breath for five seconds, or as long as tolerated, and then rest for a few seconds. This technique should be repeated by the patient ten times every hour while awake.³⁰

29. "[Incentive Spirometer.pngsommeil.svg](#)" by [BruceBlaus](#) is licensed under [CC BY-SA 4.0](#)

30.³¹

31. [16]



How to Use an Incentive Spirometer

Figure 4.18 Using an Incentive Spirometer

PULMONARY EDEMA

Pulmonary edema is the accumulation of fluid in the alveoli causing decreased gas exchange, resulting in increased levels of carbon dioxide and decreased levels of oxygen in the blood. Pulmonary edema can be caused by several medical conditions, such as pneumonia, heart failure, kidney failure, and liver failure. It is treated with medications that help eliminate excess fluid from the body, called diuretics.

PULMONARY EMBOLISM

A **pulmonary embolism** (PULL-muh-nair-ee EM-boh-liz-uhm) (**PE**) is a blood clot or other substance, such as fat or an air bubble, that has traveled through the bloodstream and lodged in a smaller vessel within the pulmonary circulation in the lungs and obstructed blood flow. This blockage causes lack

of oxygen delivery to the tissues supplied by that blood vessel. A PE is medical emergency that requires rapid treatment to prevent severe damage to the lungs or heart and death. Symptoms of a PE may include sudden, severe dyspnea; sharp pain in the chest or arm; and pale, clammy skin. Treatment includes medications to dissolve the clot or procedures to remove the clot in order to quickly restore adequate pulmonary circulation.³²

RESPIRATORY SYNCYTIAL VIRUS

Respiratory syncytial virus (rĕs-pĭ-RĀ-tōr-ē SĪN-sĭ-shē-ăl VĪ-rŭs) (**RSV**) is a very common respiratory virus that usually causes mild, cold-like symptoms. Most people recover in a week or two, but RSV can be very serious in infants and older adults. RSV is a common cause of pneumonia and bronchiolitis.

Bronchiolitis (brŏng-kē-ŌL-ĭ-tĭs) refers to inflammation of the small airways in the lung. Older adults and infants younger than six months of age with RSV may require hospitalization if they have problems breathing or become dehydrated. Severe cases may require endotracheal intubation and mechanical ventilation.³³


TUBERCULOSIS

Tuberculosis (tū-bĕr-kyŭ-LŌ-sĭs) (**TB**) is a serious infectious disease that

32. Cleveland Clinic. (2022). *Pulmonary embolism*. <https://my.clevelandclinic.org/health/diseases/17400-pulmonary-embolism>

33. Centers for Disease Control and Prevention. (2023). *Respiratory syncytial virus*. <https://www.cdc.gov/rsv/about/symptoms.html>

affects the lungs. It is caused by bacteria that can be spread through the air from person to person. Symptoms include a chronic cough, **hemoptysis** (hē-MŎP-tĭ-sĭs) or coughing up blood, weight loss, night sweats, and fever. Patients with TB require a long course of treatment involving multiple antibiotics.³⁴

View a supplementary YouTube video³⁵ on tuberculosis:
 [CDC Tuberculosis \(TB\) Transmission and Pathogenesis Video](#)

34. Centers for Disease Control and Prevention. (2023). Tuberculosis. <https://www.cdc.gov/tb/default.htm>

35. Centers for Disease Control and Prevention. (2020, May 6). *CDC tuberculosis (TB) transmission and pathogenesis video* [Video]. YouTube. All rights reserved. <https://youtube.com/watch?v=UKV8Zn7x0wM>

4.7 Medical Specialists, Diagnostic Testing, and Procedures Related to the Respiratory System

SPECIALISTS

Pulmonologist

Respiratory medicine is concerned with the diagnosis and treatment of diseases related to the respiratory system. Respiratory medicine requires in-depth knowledge of internal medicine. A physician who specializes in diagnosing and treating respiratory system disease is called a **pulmonologist** (pŭl-mŏn-ŎL-ŏ-jĭst).¹

► For more information, visit the [American Lung Association's page on pulmonologists](https://www.lung.org/blog/know-your-providers-pulmonologist).

1. American Lung Association. (2019, May 14). *Know your providers – What does a pulmonologist do?* <https://www.lung.org/blog/know-your-providers-pulmonologist>

Respiratory Therapist

Respiratory therapists (rě-spĭr-ă-tōr-ē THĚR-ă-pĭsts) (**RTs**) are health care professionals that monitor, assess, and treat people who are having problems breathing. RTs are licensed in the state in which they practice. RTs are trained in ventilation and airway management, cardiopulmonary resuscitation, and oxygen and aerosol therapy. They provide care for patients undergoing cardiac stress-testing, pulmonary function testing, smoking cessation, high-risk births, rehabilitation, and surgery. They also assist in treating patients with asthma, COPD, heart failure, and pneumonia.²

- ▶ For more information, visit the American Association for Respiratory Care's [What is an RT?](#) web page.

Thoracic Surgeon

A **thoracic surgeon** (thō-RĀS-ĭk SŪR-jŏn) refers to a surgeon who has specialized in either thoracic (chest) surgery or cardiothoracic (heart and chest) surgery. They perform surgery for patients with serious conditions of the heart, lungs, and other structures in the chest cavity.³

- ▶ To learn more about thoracic surgeons, visit [WebMD's What is a Thoracic Surgeon?](#) web page.

2. American Association for Respiratory Care. (n.d.). *What is an RT?* <https://www.aarc.org/careers/what-is-an-rt/>

3. WebMD. (2023, July 8). *What is a thoracic surgeon?* <https://www.webmd.com/a-to-z-guides/what-is-a-thoracic-surgeon>

DIAGNOSTIC TESTING AND PROCEDURES

Arterial Blood Gas

Arterial blood gas (ar-TĪR-ē-ăl blūd găs) (**ABG**) is a measurement of dissolved oxygen and carbon dioxide levels in blood taken from an artery. ABG is often obtained for patients who have deteriorating or unstable respiratory status requiring urgent and/or emergency treatment. An ABG is typically drawn in the forearm from the radial artery by a respiratory therapist, emergency or critical care nurse, or other health care provider.

Bronchoscopy

A **bronchoscopy** (bron-KOS-kǒ-pē) is a procedure used to visualize the bronchi with a **bronchoscope** (BRŎNG-kǒ-skōp), a thin, flexible tube with a light and a lens or small video camera on the end. The tube is inserted into the patient's nose or mouth, down the throat, into the trachea (windpipe), and into the airways (bronchi and bronchioles) of the lungs. It is typically performed by a physician. See Figure 4.19⁴ for an image of a bronchoscopy.

4. "[Bronchoskopie_Bronchoalveoläre_Lavage.jpg](#)" by [User:MrArifnajafo](#) is licensed under [CC BY-SA 3.0](#)

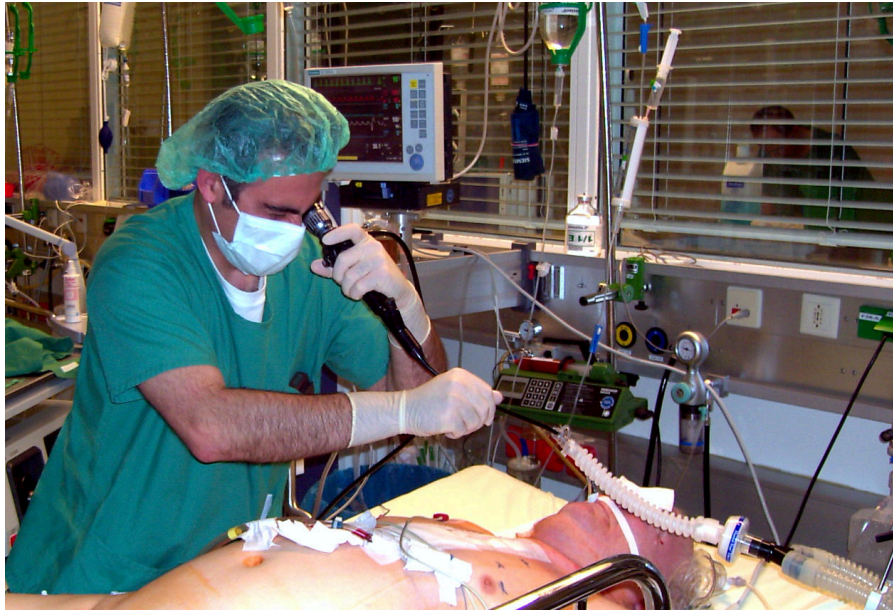

Figure 4.19 Bronchoscopy

A bronchoscopy is performed to look for the causes of problems in the airways of the lungs or to further examine an abnormal area seen on an imaging test (such as a chest X-ray or CT scan).⁵ Any abnormal areas in the airways that are seen with the bronchoscope can be biopsied to determine the cause of the abnormal finding. A biopsy is performed by passing long, thin instruments down the bronchoscope, such as small forceps (tweezers), needles, or brushes to collect the samples. Sterile salt water can also be flushed down the bronchoscope to rinse the airways and then suctioned up, which is referred to as a **bronchial washing** (BRŎNG-kē-ăl WŎSH-ing). The biopsy samples are visually examined under a microscope in a pathology lab.⁶

5. American Cancer Society. (2019, January 14). *Bronchoscopy*.
<https://www.cancer.org/cancer/diagnosis-staging/tests/endoscopy/bronchoscopy.html>

6. American Cancer Society. (2019, January 14). *Bronchoscopy*.
<https://www.cancer.org/cancer/diagnosis-staging/tests/endoscopy/bronchoscopy.html>

Chest X-Ray

As discussed earlier, a chest x-ray (CXR) is also referred to as a radiograph. Using a controlled beam of radiation, a CXR produces shadow-like images of organs and tissues like the bones, lungs, heart, and the diaphragm. After passing through the body, the beam hits a piece of film or a special detector. Tissues in the body absorb or block the radiation to varying degrees. Dense tissues, such as bones, block most radiation and appear white on the CXR. Soft tissues, like fat or muscle, block less radiation and show up in shades of gray. Organs that are mostly air (such as the lungs) appear black. Tumors are usually denser than the tissue around them, so they often show up as lighter shades of gray.⁷ See Figure 4.20⁸ for an image of a CXR. A CXR is used to diagnose a variety of respiratory conditions, such as pneumonia, pulmonary edema, and cancer.

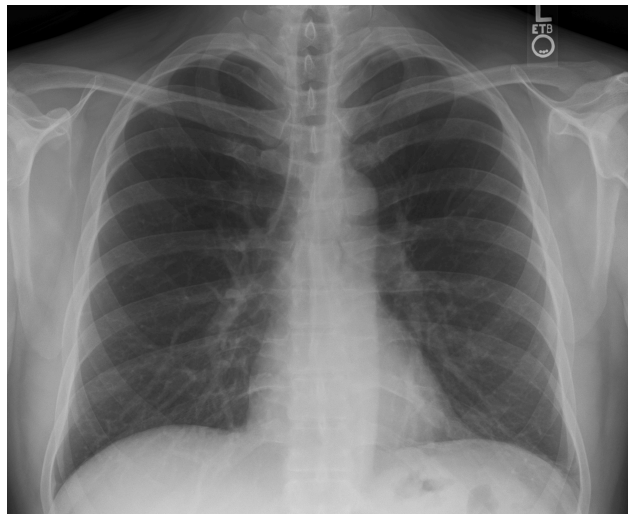


Figure 4.20 Chest X-ray

7. American Cancer Society. (2022, August 15). *Tests for lung cancer*.
<https://www.cancer.org/cancer/types/lung-cancer/detection-diagnosis-staging/how-diagnosed.html>
8. “Chest Xray PA 3-8-2010.png” by [Stillwaterising](#) is licensed under [CC0](#)

Computed Tomography (CT) Scan

A **computed tomography scan** (kǒm-PYŌŌ-těd tǒ-mŎG-ră-fē skăn) (**CT**) uses X-rays to make detailed cross-sectional images of a person's body. Instead of taking one or two pictures like a regular X-ray, a CT scanner takes many pictures and then a computer combines them to create detailed images in slices of the part of the body being studied. See Figure 4.21⁹ for an image of a CT scanner.

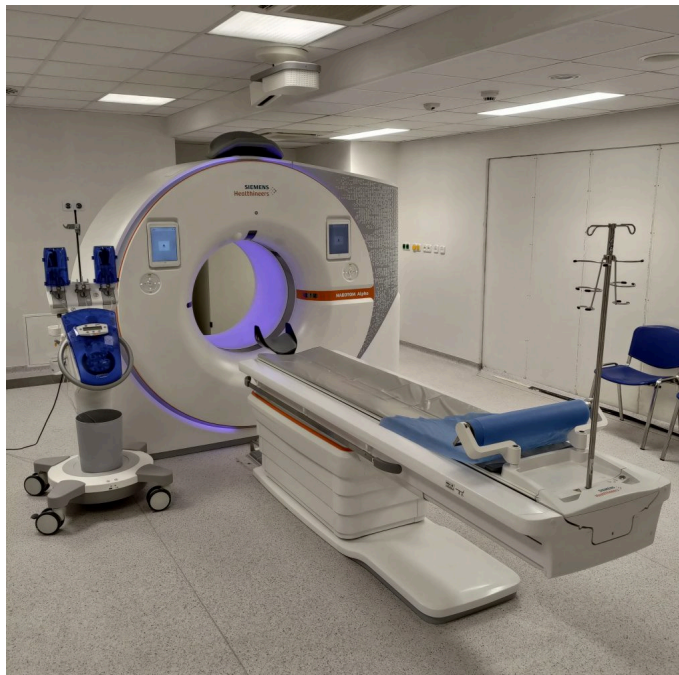

Figure 4.21 CT Scanner

A CT scan is more likely to show lung tumors than routine chest X-rays. It can also show the size, shape, and position of any lung tumor and can help visualize enlarged lymph nodes that might contain cancer that has spread. A

9. [“Moderní výpočetní tomografie s přímo digitální detekcí rentgenového záření.jpg”](#) by [Tomáš Vendiš](#) is licensed under [CC BY-SA 4.0](#)

CT scan can also be used to look for masses in the liver, brain, and other organs that can occur if the cancer has metastasized.¹⁰

If a suspected area of cancer is deep within the body, a CT scan can be used to guide a biopsy needle into this area to obtain a tissue sample to biopsy for cancer. This procedure is referred to as a **CT-guided needle biopsy** (sē-tē Gĭ-dĕd NĒ-dŭl BĪ-ŏp-sē).¹¹ See Figure 4.22¹² for an image of a CT-guided needle biopsy of the lung.

10. American Cancer Society. (2022, August 15). *Tests for lung cancer*.
<https://www.cancer.org/cancer/types/lung-cancer/detection-diagnosis-staging/how-diagnosed.html>

11. American Cancer Society. (2022, August 15). *Tests for lung cancer*.
<https://www.cancer.org/cancer/types/lung-cancer/detection-diagnosis-staging/how-diagnosed.html>

12. “Biopsie Lunge Computertomographie_BC.png” by Hellerhoff is licensed under [CC BY-SA 3.0](https://creativecommons.org/licenses/by-sa/3.0/)

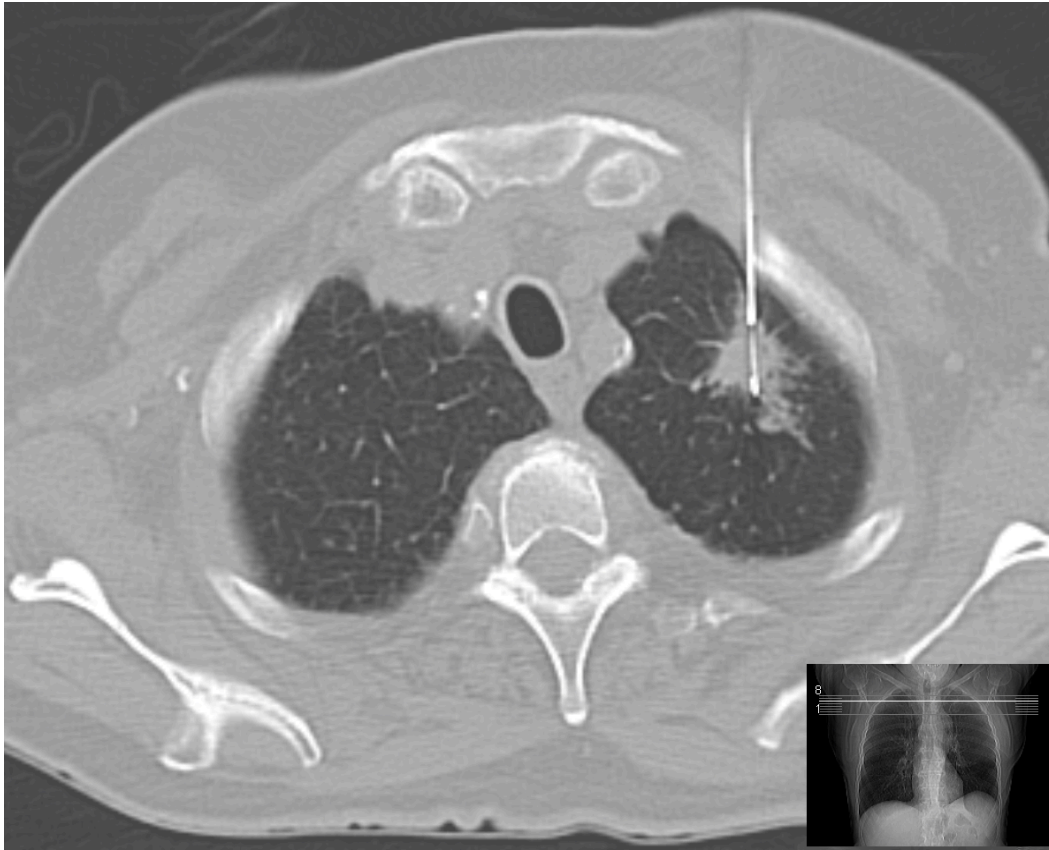


Figure 4.22 CT-Guided Needle Biopsy

Endotracheal Intubation

When a patient is experiencing respiratory failure or receiving general anesthesia during surgery, an **endotracheal tube** (ĕn-dō-TRĀ-kē-ăl tūb) (**ET tube**) is inserted to maintain a patent airway by health care professionals with advanced training, such as a respiratory therapist, paramedic, anesthesiologist, or physician. The ET tube is sealed within the trachea with an inflatable cuff, and oxygen is supplied via a bag valve mask or via mechanical ventilation. See Figure 4.23¹³ for an image of a cuffed endotracheal tube.

¹³. "[Sondeintubation.jpg](#)" by bigomar2 is licensed under [CC BY-SA 3.0](#)

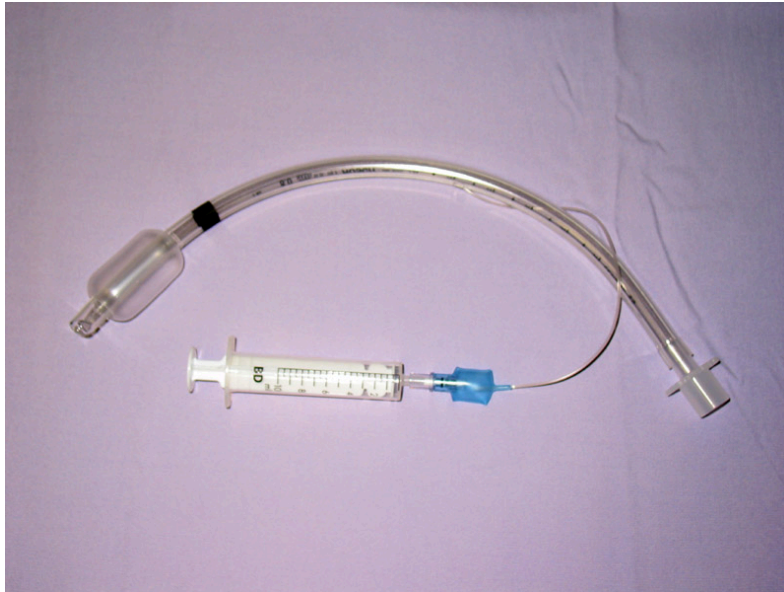


Figure 4.23 An Endotracheal Tube

Magnetic Resonance Imaging (MRI)

Similar to CT scans, **magnetic resonance imaging** (măg-NĚT-ĭk rĕz-ŏ-năns ĭM-ă-jing) (**MRI**) scans show detailed images of soft tissues in the body. However, MRI scans use radio waves and strong magnets instead of radiation. MRI scans are used to diagnose many medical conditions, such as soft tissue abnormalities, tears in ligaments, joint abnormalities, and tumors. They are also used to evaluate for metastasis of cancer to other areas of the body, such as the brain, liver, lungs, and bones.¹⁴

Mechanical Ventilation

A **mechanical ventilator** (mě-kăn-ĭ-kăl vĕn-tĭ-lă-tŏr) is a machine attached to an endotracheal tube to assist or replace spontaneous breathing. Mechanical ventilation is termed invasive because it requires placement of an

14. American Cancer Society. (2022, August 15). *Tests for lung cancer*.
<https://www.cancer.org/cancer/types/lung-cancer/detection-diagnosis-staging/how-diagnosed.html>

endotracheal tube in the trachea. Mechanical ventilators are typically managed by respiratory therapists. See Figure 4.24¹⁵ for an image of a simulated patient who is intubated with an endotracheal tube that is attached to a mechanical ventilator.

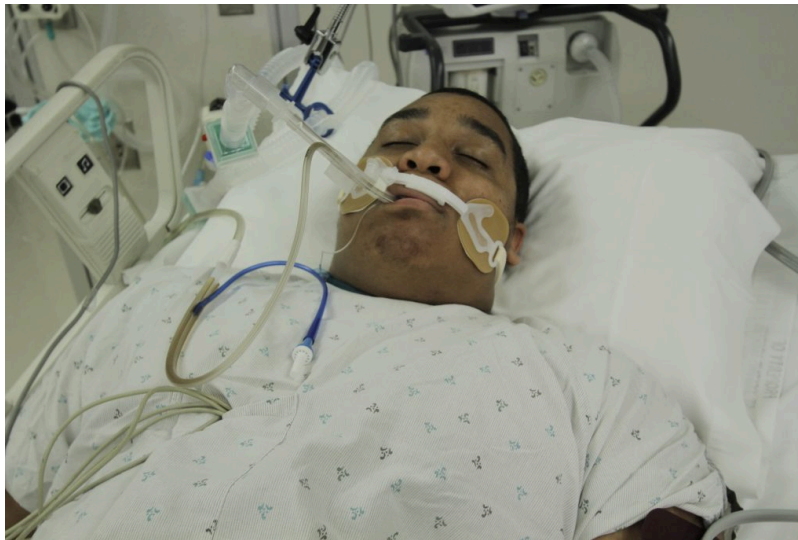

Figure 4.24 Simulated Intubated Patient on a Mechanical Ventilator

Needle Biopsy

During a **needle biopsy** (NĒ-dŭl BĪ-ŏp-sē), doctors use a needle to obtain a small sample of cells from a suspicious area (mass) to examine under a microscope. An advantage of needle biopsies is that they don't require a surgical incision. There are a variety of types of needle biopsies. One type of needle biopsy is a **fine needle aspiration biopsy** (fĭn NĒ-dŭl äs-pĭ-RĀ-shŭn BĪ-ŏp-sē) (**FNA**). During this procedure, a syringe with a very thin, needle is used

15. “Simulated intubated patient on a mechanical ventilator” by [Chippewa Valley Technical College](#) is licensed under [CC BY 4.0](#)

to **aspirate** (ĂS-pĩ-rāt) or withdraw cells and small fragments of tissue. An FNA biopsy is often used to check for cancer in lymph nodes.¹⁶

Positron Emission Tomography Scan

During a **positron emission tomography scan** (pۆz-İ-trۆn İ-MİSH-ən tۆ-mۆG-ră-fē skăn) (**PET**), a slightly radioactive substance is injected into the patient's blood. If cancer cells are present in the body, they have a higher uptake of this radioactive substance and appear as a highlighted area on the scan. Often a PET scan is combined with a CT scan so the highlighted areas on the PET scan can be easily visualized with the corresponding image on the CT scan. PET/CT scans are useful to determine if cancer has spread to other parts of the body.¹⁷ See Figure 4.25¹⁸ for an image of a PET/CT scan showing a red highlighted area of radioactive substance, indicating cancer cells have spread to this area of the body.

¹⁶. American Cancer Society. (2022, August 15). *Tests for lung cancer*.
<https://www.cancer.org/cancer/types/lung-cancer/detection-diagnosis-staging/how-diagnosed.html>

¹⁷. American Cancer Society. (2022, August 15). *Tests for lung cancer*.
<https://www.cancer.org/cancer/types/lung-cancer/detection-diagnosis-staging/how-diagnosed.html>

¹⁸. “[Anterior Pancoast tumor PET.jpg](#)” by Soichi Oka, Kenji Ono, Kenta Kajiyam, and Katsuma Yoshimatsu is licensed under [CC BY-SA 4.0](#)

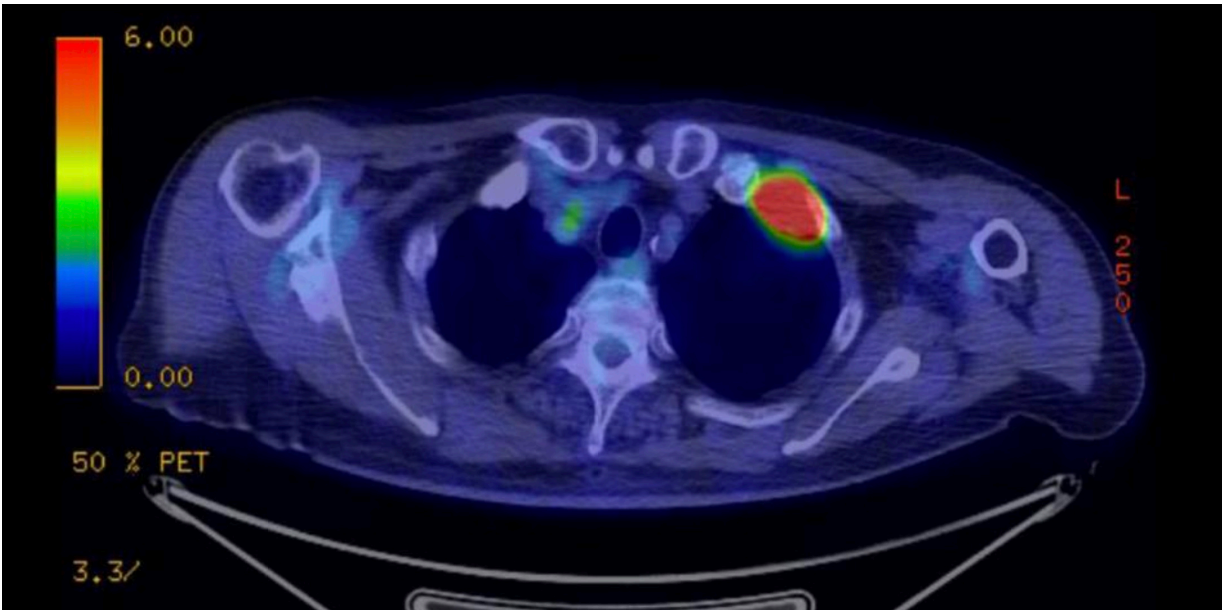


Figure 4.25 PET-CT Scan

Pulmonary Function Tests

Pulmonary function tests (PŬL-mŏ-nā-rē fŭnk-shŭn tĕsts) (**PFTs**) allow physicians and respiratory therapists to evaluate the respiratory function of patients with various types of lung disease. PFTs do not provide a specific diagnosis, but the results are combined with other assessment data to reach a diagnosis. PFTs also help determine the severity of pulmonary disease, assess the patient's response to treatment, and monitor for possible disease progression over time.¹⁹

Spirometry (spī-RŎM-ĕ-trĕ) is a common PFT that measures the patient's ability to inhale and exhale air relative to time using a device called a spirometer. Spirometry is used for diagnosis and therapeutic management of common respiratory disorders, such as asthma and chronic obstructive pulmonary disease (COPD). The primary measurements during spirometry testing are forced vital capacity (FVC), forced expiratory volume exhaled in the

¹⁹. This work is a derivative of [StatPearls](#) by Ponce, Sankari, & Sharma and is licensed under [CC BY 4.0](#)

first second (FEV1), and the FEV1/FVC ratio. The spirometry procedure has three phases that include maximal inspiration, a “blast” of exhalation, and a complete exhalation.²⁰ View an illustration of spirometry in Figure 4.26.²¹



Figure 4.26 Spirometry



View the following YouTube video²² for more information

20. This work is a derivative of [StatPearls](#) by Ponce, Sankari, & Sharma and is licensed under [CC BY 4.0](#)

21. “[Spirometry_Part_1.png](#)” by [BruceBlaus](#) is licensed under [CC BY-SA 4.0](#)

22. BMJ Learning. (2020, July 1). *How to do a spirometry test and interpret the results* [Video]. YouTube. All rights reserved. <https://youtu.be/jSkwBoed6Tw?si=AQxyjWNULZLAgC2t>



about spirometry: [How To Do a Spirometry Test and Interpret the Results](#)

Sputum Culture

A **sputum culture** (SPYŌŌ-tŭm KŬL-chŭr) is a diagnostic test that evaluates the type and number of bacteria present in mucus from the respiratory tract. The patient is asked to cough deeply and spit any mucus that comes up into a sterile specimen container. Care must be taken to ensure the specimen only contains mucus and not saliva. The sample is sent to a lab where it is placed in a special dish and examined for two to three days or longer to see if bacteria or other disease-causing pathogens grow. See Figure 4.27²³ for an image of a sputum culture.

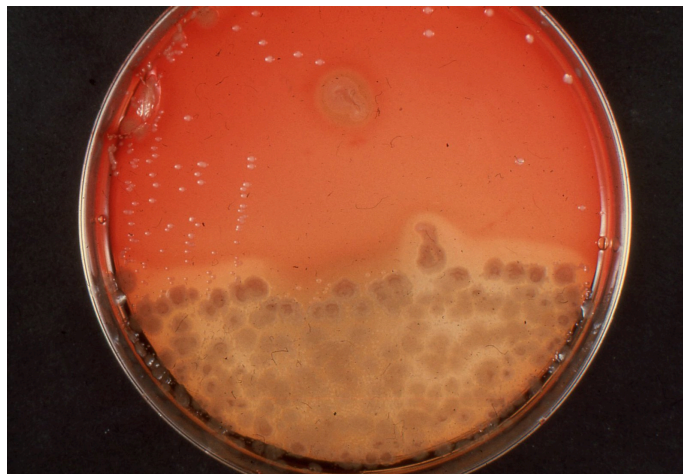


Figure 4.27 Sputum Culture

23. [“m241-8 Blood agar culture of sputum from patient with pneumonia. Comprised host. Colonies of Candida albicans and pseudomonas aeruginosa \(LeBeau\)”](#) by Microbe World is licensed under [CC BY-NC-SA 2.0](#)

Thoracentesis

If fluid has collected in the pleural space around the lungs (called a pleural effusion), health care providers perform a procedure called a **thoracentesis** (thor-uh-sen-TEE-sis) to remove the fluid. Pleural effusion is typically caused by a medical condition, such as pneumonia, heart failure, infection, or lung cancer.

During a thoracentesis, the patient's skin is numbed, and a needle is inserted between the ribs to aspirate (i.e., suction) the fluid for examination in the lab. If recurrent pleural effusions cause the patient to have trouble breathing, thoracentesis may be repeated to remove additional fluid to help the patient breathe better.²⁴ See Figure 4.28²⁵ for an illustration of removal of fluid during a thoracentesis.

24. American Cancer Society. (2022, August 15). *Tests for lung cancer*.
<https://www.cancer.org/cancer/types/lung-cancer/detection-diagnosis-staging/how-diagnosed.html>

25. "Thoracentesis.jpg" by [National Heart, Lung and Blood Institute](#) is licensed in the [Public Domain](#).

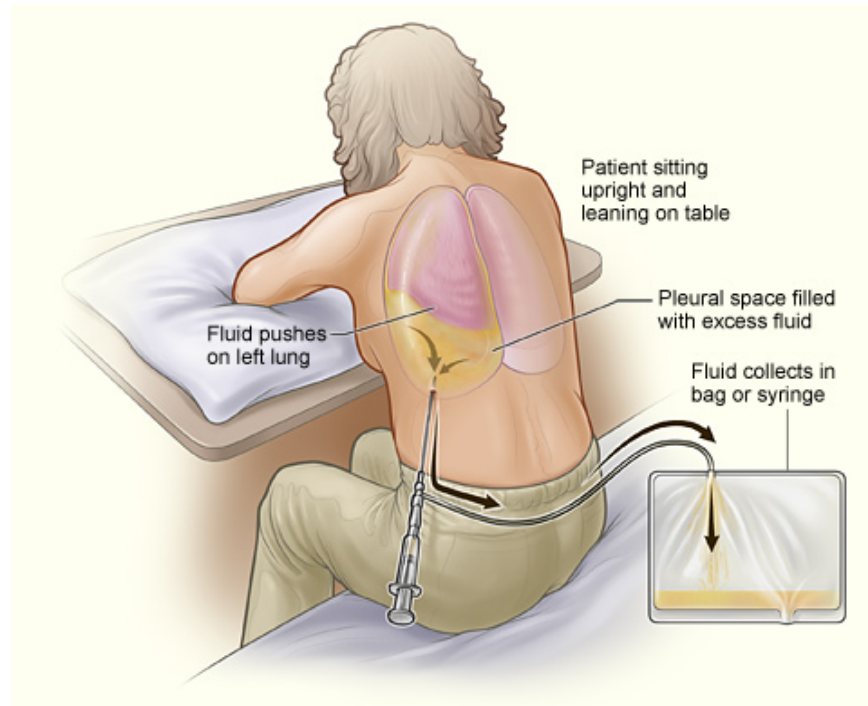


Figure 4.28 Thoracentesis

Tracheostomy

A **tracheostomy** (trā-kē-ŎS-tŏ-mē) is a surgically created opening, called a stoma, that goes from the front of the patient's neck into the trachea. A tracheostomy tube is placed through the stoma into the trachea to maintain a patent (open) airway and to administer oxygen. A tracheostomy may be an emergent procedure performed due to an airway obstruction or a planned procedure to manage a disease process. See Figure 4.29²⁶ for an illustration of a patient with a tracheostomy tube in place.

26. "Tracheostomy NIH.jpg" by [National Heart, Lung, and Blood Institute](#) is in the [Public Domain](#).

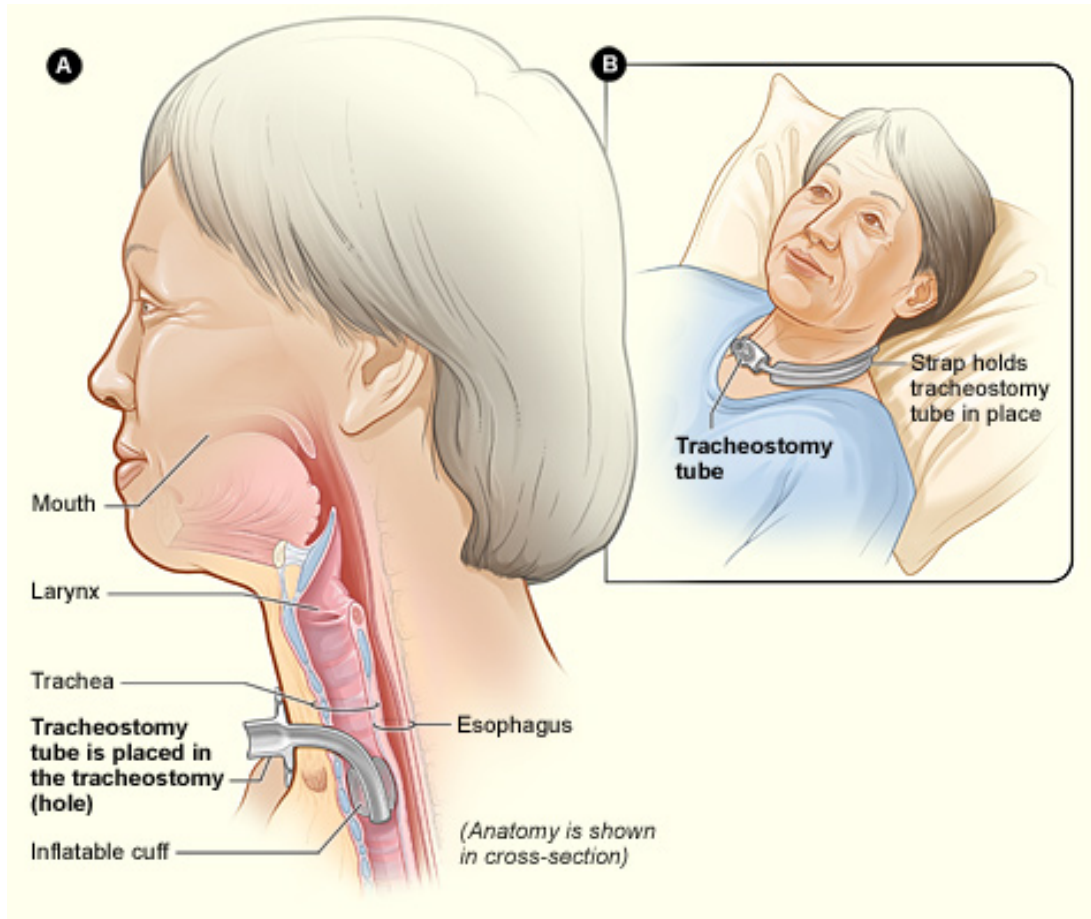


Figure 4.29 Patient With Tracheostomy Tube

RESPIRATORY EQUIPMENT

There are various types of medical devices related to the respiratory system.

Continuous Positive Airway Pressure (CPAP)

A **continuous positive airway pressure device** (kŏn-TĪN-yū-ŭs POZ-ĭ-tĭv AIR-wā PRESS-ŭr dĭ-VĪS) (**CPAP**) is used for people who are able to breathe spontaneously on their own but need help in keeping their airway unobstructed, such as those with obstructive sleep apnea. The CPAP device consists of a special mask that covers the patient's nose, or nose and mouth, and is attached to a machine that continuously applies mild air pressure to

keep the patient's airways from collapsing. See Figure 4.30²⁷ for an illustration of a patient wearing a CPAP device while sleeping.

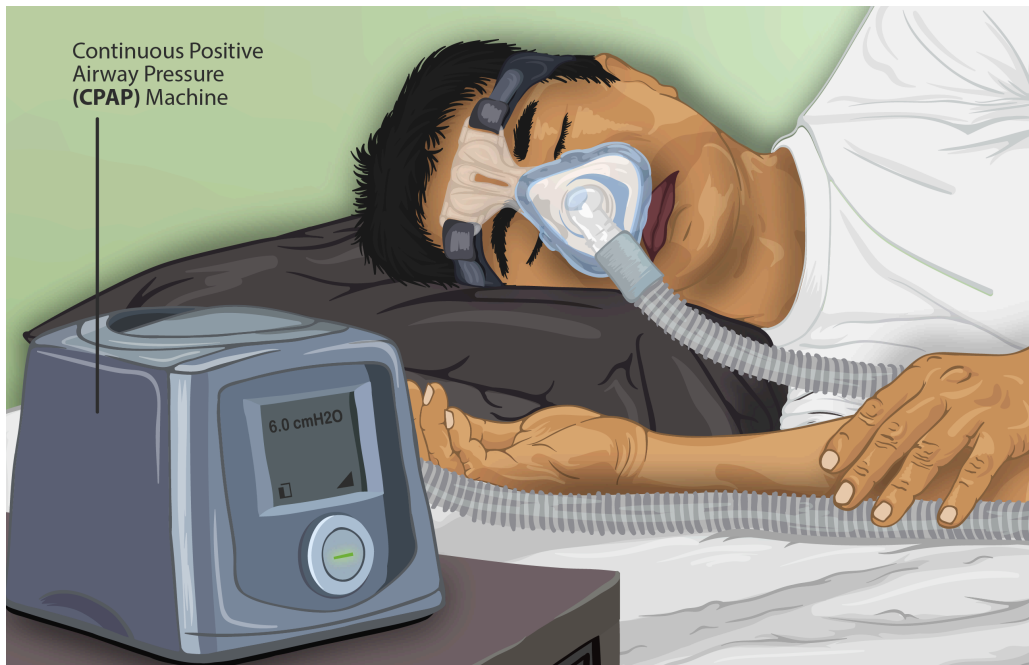


Figure 4.30 CPAP Machine

Bilevel Positive Airway Pressure (BiPAP)

A **bilevel positive airway pressure** (BĪ-lěv-ěĭ PŎZ-ĭ-tĭv ĀR-wā PRĚSH-ŭr) (**BiPAP**) device is similar to a CPAP device in that it is used to prevent airways from collapsing, but BiPAP devices have two pressure settings. One setting occurs during inhalation, and a lower pressure setting is used during exhalation. Patients using BiPAP devices in their home environment for obstructive sleep apnea often find these two pressures more tolerable because they don't have to exhale against continuous pressure. In acute care settings, BiPAP devices are also used for patients in acute respiratory distress

27. “[Depiction of a sleep apnea patient using a CPAP machine](https://www.myupchar.com/en)” by <https://www.myupchar.com/en> is licensed under [CC BY 4.0](https://creativecommons.org/licenses/by/4.0/)

as a noninvasive alternative to intubation and mechanical ventilation and are managed by respiratory therapists. See Figure 4.31²⁸ for an image of a simulated patient wearing a BiPAP mask in a hospital setting.

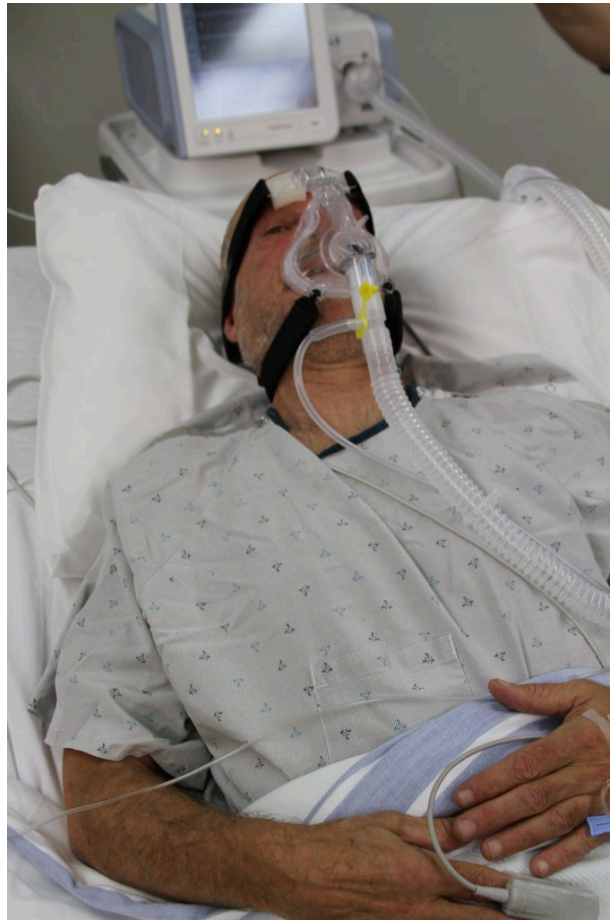

Figure 4.31 Simulated Patient Wearing a BiPAP Mask

Nasal Cannula

A **nasal cannula** (NĀ-zāl KĀN-yū-lă) is the simplest and most commonly used oxygenation device. It consists of oxygen tubing connected to two short

28. “[Simulated patient wearing a BiPAP mask](#)” by [Chippewa Valley Technical College](#) is licensed under [CC BY 4.0](#)

prongs that are inserted into the patient's nares (nostrils). See Figure 4.32²⁹ for an image of a nasal cannula. Nasal cannulas are used for short- and long-term therapy and are best used with stable patients who require low amounts of oxygen, such as patients with COPD.

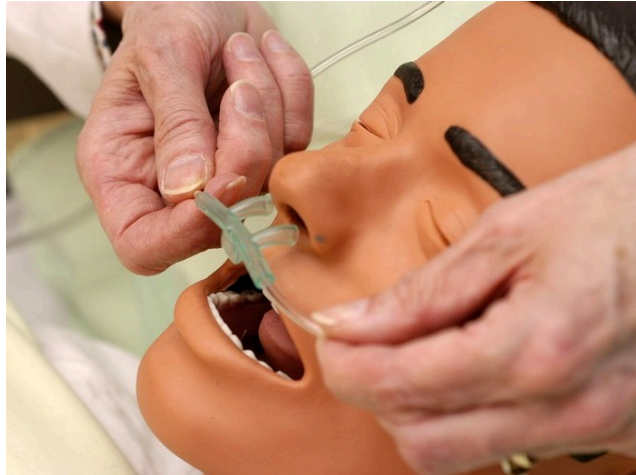

Figure 4.32 Nasal Cannula

- ▶ Read more information about additional oxygenation devices such as a high-flow nasal cannula, non-rebreather mask, partial rebreather mask, Venturi mask, oxymask, and oxymizer in the “[Oxygenation Equipment](#)” section of the “Oxygen Therapy” chapter of *Open RN Nursing Skills, 2e*.

29. “Image00011.jpg” by British Columbia Institute of Technology is licensed under [CC BY 4.0](#). Access for free at <https://opentextbc.ca/clinicalskills/chapter/5-5-oxygen-therapy-systems/>

Pulse Oximeter

A **pulse oximeter** (pŭls ōk-SĪM-ĭ-tŏr) is a commonly used portable device used to obtain a patient's oxygen saturation level, often referred to as a pulse oximetry reading. The pulse oximeter analyzes light produced by the probe as it passes through the finger to determine the saturation level of hemoglobin with oxygen while also analyzing the pulse rate. See Figure 4.33³⁰ for an image of a portable pulse oximeter. The normal range for a pulse oximetry reading for an adult without an underlying respiratory condition is 94-100%.

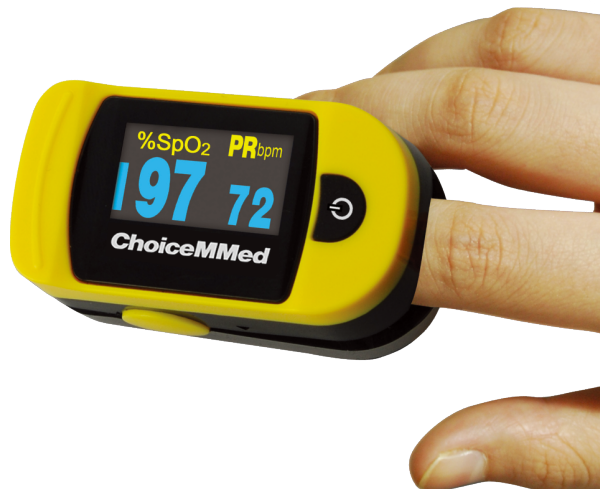

Figure 4.33 Portable Pulse Oximeter

30. "[OxyWatch_C20_Pulse_Oximeter.png](#)" by Thinkpaul is licensed under [CC BY-SA 3.0](#)

4.8 Respiratory System Learning Activities

Interactive Learning Activity: Label the anatomy of the respiratory system using this drag and drop activity.



An interactive H5P element has been excluded from this version of the text. You can view it online here:

<https://wtcs.pressbooks.pub/medterm/?p=3086#h5p-154>

Interactive Learning Activity: Study terms discussed in this chapter using these flashcards.



An interactive H5P element has been excluded from this version of the text. You can view it online here:

<https://wtcs.pressbooks.pub/medterm/?p=3086#h5p-173>

Interactive Learning Activity: Test your comprehension of respiratory system terms and concepts.



An interactive H5P element has been excluded from this version of the text. You can view it online here:

<https://wtcs.pressbooks.pub/medterm/?p=3086#h5p-104>

Interactive Learning Activity: Using the sample documentation provided, drag the terms on the right to their appropriate spaces within the documentation.



An interactive H5P element has been excluded from this version of the text. You can view it online here:

<https://wtcs.pressbooks.pub/medterm/?p=3086#h5p-99>

Interactive Learning Activity: Using the sample documentation provided, drag the terms on the right to their appropriate spaces within the documentation.



An interactive H5P element has been excluded from this version of the text. You can view it online here:

<https://wtcs.pressbooks.pub/medterm/?p=3086#h5p-101>

Interactive Learning Activity: Using the sample documentation provided, drag the terms on the right to their appropriate spaces within the documentation.



An interactive H5P element has been excluded from this version of the text. You can view it online here:

<https://wtcs.pressbooks.pub/medterm/?p=3086#h5p-102>



Interactive Learning Activity: Practice identifying and defining word parts for terms discussed in this chapter:



An interactive H5P element has been excluded from this version of the text. You can view it online here:

<https://wtcs.pressbooks.pub/medterm/?p=3086#h5p-195>

- ▶ You can also print this as a [Chapter 4 Practice Worksheet](#) and check your answers with this [Answer Key PDF](#).

4.9 Glossary

Adenoid (ĂD-ě-noyd): Lymphatic tissue between the back of the nasal cavity and the pharynx. ([Chapter 4.4](#))

Adenoiditis (ad-ě-noyd-ĪT-is): Inflammation of the adenoids. ([Chapter 4.4](#))

Allergies (ĂL-ěr-jěz): A condition in which the immune system reacts abnormally to a foreign substance. ([Chapter 4.6](#))

Alveolar (ăl-VĒ-ō-lăr): Pertaining to the alveoli, the small air sacs in the lungs responsible for gas exchange. ([Chapter 4.4](#))

Alveoli (ăl-VĒ-ō-lī): Tiny air sacs in the lungs where the exchange of oxygen and carbon dioxide takes place. ([Chapter 4.4](#))

Anaphylaxis (ăn-ă-fĭ-LĂK-sĭs): A severe, potentially life-threatening allergic reaction. ([Chapter 4.6](#))

Apnea (ĂP-nē-ă): Absence of breathing. ([Chapter 4.5](#))

Arterial blood gas (ar-TĪR-ē-ăl blŭd găs): A test that measures the amounts of oxygen and carbon dioxide in the blood from an artery. It is used to check how well the lungs are able to move oxygen into the blood and remove carbon dioxide from the blood. ([Chapter 4.7](#))

Asphyxia (ăs-FĪK-sē-ă): A condition arising when the body is deprived of oxygen, causing unconsciousness or death; suffocation. ([Chapter 4.5](#))

Aspirate (ĂS-pĭ-răt): To draw in or out using a sucking motion, typically refers to the process of drawing fluid or tissue samples from the body. ([Chapter 4.7](#))

Aspiration (ăs-pĭ-RĀ-shŭn): The inhalation of food, liquid, or other material into the respiratory tract. ([Chapter 4.4](#))

Asthma (ĂZ-mă): A condition in which a person's airways become inflamed, narrow, and swell, producing extra mucus, which makes it difficult to breathe. ([Chapter 4.6](#))

Asthma attacks (ĂZ-mă ă-TĂKS): Episodes of severe asthma symptoms, such as coughing, wheezing, and shortness of breath. ([Chapter 4.6](#))

Atelectasis (ăt-ě-lĚK-tă-sĭs): The collapse of part or all of a lung, often

caused by a blockage of the air passages or by pressure on the outside of the lung. ([Chapter 4.4](#))

Bilevel positive airway pressure (BĪ-lěv-ěl PŎZ-ĭ-tĭv ĀR-wā PRĚSH-ŭr) (BiPAP): A form of noninvasive ventilation that provides two levels of air pressure, one for inhalation and a lower one for exhalation, used in the treatment of sleep apnea and other respiratory problems. ([Chapter 4.7](#))

Bradypnea (brăd-ĬP-nē-ă): Abnormally slow breathing. ([Chapter 4.5](#))

Bronchi (BRŎNG-kĭ): The main passageways into the lungs. ([Chapter 4.4](#))

Bronchial washing (BRŎNG-kē-ăl WŎSH-ing): A procedure during bronchoscopy where saline is squirted into a part of the lung and then recollected for examination. It's used to collect cells from the bronchial tubes. ([Chapter 4.7](#))

Bronchioles (BRŎNG-kē-ŏlz): Small branches of the bronchi that lead to the alveoli in the lungs. ([Chapter 4.4](#))

Bronchiolitis (brŏng-kē-ŎL-ĭ-tĭs): An inflammation of the small airways in the lungs, known as bronchioles, usually due to a viral infection. It is most common in infants and young children, particularly during the winter months, and can cause symptoms like wheezing, coughing, and difficulty breathing. ([Chapter 4.6](#))

Bronchitis (brŏng-Kĭ-tĭs): Inflammation of the bronchial tubes, often resulting from infection or environmental factors like smoking. ([Chapter 4.4](#))

Bronchodilator (brŏng-kō-Dĭ-lā-tŏr): A drug that relaxes bronchial muscle resulting in expansion of the bronchial air passages, used in conditions like asthma. ([Chapter 4.6](#))

Bronchoscope (BRŎNG-kŏ-skŏp): A medical instrument with a light and camera used for examining the inside of the trachea, bronchi, and lungs. ([Chapter 4.7](#))

Bronchoscopy (brŏng-KŎS-kŏ-pē): A procedure that allows a doctor to look at the airway through a thin viewing instrument called a bronchoscope. ([Chapter 4.4](#))

Bronchospasm (BRŎNG-kō-spăz-ŭm): The sudden constriction of the muscles in the bronchial walls. ([Chapter 4.4](#))

Cancer (KĀN-sŏr): A disease in which abnormal cells divide uncontrollably and destroy body tissue. ([Chapter 4.6](#))

Chest X-rays (chěst ěks-rāz) (CXR): An imaging test that uses small amounts of radiation to produce pictures of the organs, bones, and tissues in the chest area; also called radiographs. ([Chapter 4.6](#))

Chronic bronchitis (KRŎN-ĭk brŏng-Kĭ-tĭs): A form of bronchitis characterized by chronic cough and mucus production for at least three months in two consecutive years. ([Chapter 4.6](#))

Chronic obstructive pulmonary disease (KRŎN-ĭk ōb-STRŮK-tĭv PŮL-mō-ně-rē dĭ-ZĚZ) (COPD): A group of lung diseases that block airflow and make it difficult to breathe. ([Chapter 4.6](#))

Computed tomography scan (kŏm-PYŎŎ-těd tŏ-mŎG-ră-fē skăn) (CT): A medical imaging technique used to create detailed images of internal body structures, particularly useful for diagnosing diseases or conditions in the lungs and other thoracic structures. ([Chapter 4.7](#))

Continuous positive airway pressure device (kŏn-TĪN-yŭ-ŭs POZ-ĭ-tĭv AIR-wā PRESS-ŭr dĭ-VĪS) (CPAP): A type of therapy used in sleep apnea, in which air is supplied through a mask to keep airways open during sleep. ([Chapter 4.6](#))

CT-guided needle biopsy (sē-tē Gĭ-děd NĒ-dŭl Bĭ-ŏp-sē): A procedure where a needle biopsy is performed with the guidance of computed tomography (CT) imaging to obtain a tissue sample from the lung or other internal organs. ([Chapter 4.7](#))

Cyanosis (sĭ-ă-NŎ-sĭs): A bluish discoloration of the skin and mucous membranes resulting from poor circulation or inadequate oxygenation of the blood. ([Chapter 4.6](#))

Cyanotic (sĭ-ă-NŎT-ĭk): Pertaining to cyanosis; a bluish or purplish discoloration of the skin due to deficient oxygenation of the blood. ([Chapter 4.6](#))

Cystic fibrosis (SĪS-tĭk fĭ-BRŎ-sĭs): A genetic disorder affecting the lungs and digestive system, characterized by thick, sticky mucus that can clog airways and lead to respiratory and digestive problems. ([Chapter 4.6](#))

Dysphonia (dis-FŎ-nē-ă): Difficulty in speaking due to a problem with the voice. ([Chapter 4.4](#))

Dyspnea (dĭs-PNĒ-ă): Difficulty or discomfort in breathing; shortness of breath. ([Chapter 4.5](#))

Emphysema (ěm-fĩ-ZĚ-mă): A chronic respiratory disease where there is overinflation of the air sacs (alveoli) in the lungs, leading to a decrease in lung function and breathlessness. ([Chapter 4.6](#))

Endotracheal tube (ěn-dō-TRĀ-kē-ăl tūb) (ET tube): A flexible plastic tube that is put in the mouth and then down into the trachea to help a patient breathe. ([Chapter 4.7](#))

Epiglottis (ě-pĩ-GLÖT-īs): A flap of tissue that covers the trachea during swallowing to prevent aspiration. ([Chapter 4.4](#))

Epistaxis (ěp-ĩ-STĀK-sīs): Bleeding from the nose; also called rhinorrhagia. ([Chapter 4.4](#))

Exacerbations (ěg-ză-sěr-BĀ-shŭns): Episodes where symptoms of a disease become worse or more severe. ([Chapter 4.6](#))

Exhalation (ěks-hă-LĀ-shŭn): The process of breathing out air. ([Chapter 4.5](#))

Fine needle aspiration biopsy (fĩn NĚ-dŭl ăs-pĩ-RĀ-shŭn Bĩ-öp-sē) (FNA): A diagnostic procedure used to investigate lumps or masses. In this technique, a thin needle is used to extract sample cells from the body. ([Chapter 4.7](#))

Gas exchange (găs ĩk-SCHĀNJ): The process in the lungs where oxygen is taken up by the blood and carbon dioxide is released from the blood. ([Chapter 4.5](#))

Hemoglobin (HĚ-mō-glō-bĩn): A protein in red blood cells that carries oxygen from the lungs to the rest of the body and returns carbon dioxide from the body to the lungs. ([Chapter 4.5](#))

Hemoptysis (hē-MÖP-tĩ-sīs): Coughing up blood from the respiratory tract. ([Chapter 4.6](#))

Hypercapnia (hĩ-pěr-KĀP-nē-ă): Excess carbon dioxide in the bloodstream, typically caused by inadequate respiration. ([Chapter 4.5](#))

Hyperpnea (hĩ-PŮR-pnē-ă): Excessively deep or rapid breathing; forced breathing. ([Chapter 4.5](#))

Hyperventilation (hĩ-pěr-věn-tĩ-LĀ-shŭn): Breathing that is deeper and more rapid than normal. ([Chapter 4.5](#))

Hypopnea (hĩ-pÖP-nē-ă): Deficient shallow or slow breathing. ([Chapter 4.5](#))

Hypoventilation (hĩ-pō-věn-tĩ-LĀ-shŭn): Reduced rate and/or depth of air movement into the lungs, leading to increased carbon dioxide levels in the blood. ([Chapter 4.5](#))

Hypoxemia (hī-pők-SĒ-mē-ă): Low levels of oxygen in the blood. ([Chapter 4.5](#))

Hypoxia (hī-PÖK-sē-ă): A condition in which the body or a region of the body is deprived of adequate oxygen supply at the tissue level. ([Chapter 4.5](#))

Influenza (ĩn-flōō-ěň-ză): A highly contagious viral infection affecting the respiratory tract, commonly referred to as the flu, with symptoms like fever, cough, sore throat, and muscle aches. ([Chapter 4.6](#))

Inhalation (ĩn-hă-lĀ-shŭň): The process of breathing in air. ([Chapter 4.5](#))

Labored breathing (LĀ-börd BRĒ-thĩng): Breathing that requires more effort than normal; often a sign of distress or illness. ([Chapter 4.5](#))

Laryngitis (lă-rĩn-JĪ-tĩs): Inflammation of the larynx, typically resulting in huskiness or loss of voice. ([Chapter 4.4](#))

Larynx (LĀR-ĩngks): The organ forming an air passage to the lungs and holding the vocal cords; the voice box. ([Chapter 4.4](#))

Lobectomy (lō-BĚK-tō-mē): Surgical removal of a lobe of an organ, such as a lobe of the lung. ([Chapter 4.4](#))

Lobes (lōbz): Divisions of the lungs; the right lung has three lobes, and the left lung has two. ([Chapter 4.4](#))

Lung cancer (lŭng KĀN-sŏr): A type of cancer that begins in the lungs and may spread to lymph nodes or other organs in the body. ([Chapter 4.6](#))

Lungs (lŭngz): The main organs of the respiratory system, responsible for the exchange of oxygen and carbon dioxide. ([Chapter 4.4](#))

Magnetic resonance imaging (măg-NĚT-ĩk řěz-ŏ-năňs ĨM-ă-jĩng) (MRI): A medical imaging technique used in radiology to form pictures of the anatomy and the physiological processes of the body. ([Chapter 4.7](#))

Mechanical ventilator (mě-kăn-ĩ-kăl vĕň-tĩ-lă-tŏr): A machine that provides respiratory support for patients who are unable to breathe effectively on their own. ([Chapter 4.7](#))

Metastases (mě-TĀS-tă-sēz): The spread of cancer from one part of the body to another. ([Chapter 4.6](#))

Mucus (MŪ-kŭs): A slippery secretion produced by, and covering, mucous membranes for lubrication and protection. ([Chapter 4.4](#))

Nasal cannula (NĀ-zăl KĀN-yŭ-lă): A device used to deliver supplemental

oxygen or increased airflow to a patient in need of respiratory help. ([Chapter 4.7](#))

Nebulizer (NĒB-yū-lī-zēr): A device for converting a drug into mist and delivering it to the lungs, often used in treating asthma and other respiratory conditions. ([Chapter 4.6](#))

Needle biopsy (NĒ-dŭl BĪ-ōp-sē): A procedure to obtain a sample of cells from the body for laboratory testing, often used to diagnose diseases such as cancer. ([Chapter 4.7](#))

Obstructive sleep apnea (ōb-STRŬK-tĭv slēp āp-NĒ-ă) (OSA): A sleep disorder characterized by pauses in breathing or periods of shallow breathing during sleep. ([Chapter 4.6](#))

Peak flow meter (pēk flō mē-tēr): A small, hand-held device used to measure the ability to push air out of the lungs. ([Chapter 4.6](#))

Perfusion (pěr-FYŪ-zhŭn): The passage of fluid through the circulatory system or lymphatic system to an organ or a tissue. ([Chapter 4.5](#))

Pharyngitis (fă-RĪN-JĪ-tĭs): Inflammation of the pharynx, often resulting in a sore throat. ([Chapter 4.4](#))

Pharynx (FĀR-ĭngks): Commonly known as the throat; a part of the neck and throat that is situated posteriorly to the mouth and nasal cavity and cranially to the esophagus and larynx. ([Chapter 4.4](#))

Pleural effusion (PLŪR-ăl ě-FYŪ-zhŭn): A condition where fluid accumulates in the pleural space, the area between the layers of tissue that line the lungs and chest cavity. ([Chapter 4.4](#))

Pleural rub (plur-uhl ruhb): An abnormal lung sound that is caused by inflammation of the pleura membranes that results in friction as the surfaces rub against each other. ([Chapter 4.5](#))

Pneumonia (nŭ-MŌ-nē-ă): An infection that inflames the air sacs in one or both lungs, which may fill with fluid or pus. ([Chapter 4.4](#))

Positron emission tomography scan (pōz-Ī-trŏn ĭ-MĪSH-ən tŏ-mŏG-ră-fē skăn) (PET): A diagnostic imaging test using a radioactive substance to look for disease in the body, often used for detecting cancer. ([Chapter 4.7](#))

Pruritus (PRŪ-rĭ-tŭs): Itching or an uncomfortable irritation of the skin. ([Chapter 4.6](#))

Pulmonary arteries (PŬL-mŏ-ně-rē ār-tě-rēs): The arteries carrying blood

from the right ventricle of the heart to the lungs for oxygenation. ([Chapter 4.5](#))

Pulmonary circulation (PŮL-mō-ně-rē sř-kyū-LĀ-shŭn): The part of the circulatory system which carries blood from the heart to the lungs and back to the heart. ([Chapter 4.5](#))

Pulmonary edema (PŮL-mŏn-ăr-ē ě-DĚ-mă): Fluid accumulation in the alveoli of the lungs, often caused by heart or kidney failure. ([Chapter 4.5](#))

Pulmonary embolism (PŮL-mŏ-nā-rē ěm-BŌ-lř-zŭm) (PE): A blockage in one of the pulmonary arteries in the lungs, usually caused by blood clots that travel to the lungs from the legs or other parts of the body. ([Chapter 4.6](#))

Pulmonary function tests (PŮL-mŏ-nā-rē fŭnk-shŭn tĕsts) (PFTs): A group of tests that measure how well the lungs take in and release air and how well they move gases such as oxygen from the atmosphere into the body's circulation. ([Chapter 4.7](#))

Pulmonologist (pŭl-mŏn-ŎL-ŏ-jřst): A physician who specializes in the diagnosis and treatment of diseases and disorders related to the respiratory system. ([Chapter 4.7](#))

Pulse oximeter (pŭls ōk-SĪM-ř-tŏr): A small, clip-like device that attaches to a body part, like toes or an earlobe, but most commonly to a finger, to measure the oxygen saturation of arterial blood. ([Chapter 4.5](#))

Radiographs (RĀ-dē-ŏ-grăf): Images produced on a sensitive plate or film by X-rays, gamma rays, or similar radiation, and used in medical examinations. ([Chapter 4.6](#))

Rales (rāylz): An abnormal lung sound, also called fine crackles, that sound like popping or crackling sounds on inspiration. Rales are associated with medical conditions that cause fluid accumulation within the alveolar and interstitial spaces, such as heart failure or pneumonia. ([Chapter 4.5](#))

Respiration (rĕs-př-RĀ-shŏn): The process of inhaling oxygen from the air and exhaling carbon dioxide out of the body. It is a vital function for the survival of humans and many other organisms, facilitating the exchange of gases in the lungs and tissues. ([Chapter 4.5](#))

Respiratory rate (RES-př-ă-tŏ-rē rāt): The number of breaths a person takes per minute. ([Chapter 4.5](#))

Respiratory syncytial virus (rĕs-př-RĀ-tŏr-ē SĪN-sř-shē-ăl VĪ-rŭs) (RSV): A

common and highly contagious virus that causes infections of the respiratory tract. It can lead to mild, cold-like symptoms in adults and older children but can be severe in infants, young children, and older adults, especially those with underlying health conditions. ([Chapter 4.6](#))

Respiratory therapists (rě-spīr-ă-tōr-ē THĚR-ă-pīsts): Health care professionals who specialize in providing care for patients with breathing or other cardiopulmonary disorders. ([Chapter 4.7](#))

Rhinitis (rye-NYE-tis): Inflammation of the nasal mucosa. ([Chapter 4.4](#))

Rhinorrhagia (rī-nō-RĀ-jē-ă): Bleeding from the nose, also known as epistaxis. ([Chapter 4.4](#))

Rhinorrhea (rye-noh-REE-uh): Excess mucous production by the nasal cavities, commonly referred to as a “runny nose.” ([Chapter 4.4](#))

Rhonchi (rǒng-kahy): An abnormal lung sounds, also referred to as coarse crackles, that are low-pitched, continuous sounds heard on expiration that are a sign of turbulent airflow through mucus in the large airways. ([Chapter 4.5](#))

Septum (SĚP-tŭm): The structure separating the left and right airways in the nose, dividing the two nostrils. ([Chapter 4.4](#))

Sinusitis (sī-nŭ-SĪ-tīs): Inflammation of the sinus cavities. ([Chapter 4.4](#))

Spirometry (spī-RŌM-ě-trē): A common office test used to assess how well the lungs work by measuring how much air is inhaled, how much is exhaled, and how quickly it is exhaled. ([Chapter 4.7](#))

Sputum (SPŪT-ŭm): Mucous secretions from the respiratory tract that can be expelled through the mouth. ([Chapter 4.4](#))

Sputum culture (SPYŌŌ-tŭm KŮL-chŭr): A test to detect and identify bacteria or fungi that are infecting the lungs or breathing passages. ([Chapter 4.7](#))

Stethoscope (STĚTH-ō-skōp): A medical instrument used for listening to the internal sounds of an organism, typically used for heart and lung sounds. ([Chapter 4.5](#))

Stridor (strī-door): An abnormal lungs sound heard during inspiration that is associated with obstruction of the trachea/upper airway. ([Chapter 4.5](#))

Surfactant (SŮR-făk-tănt): A substance that reduces the surface tension of fluid in the lungs and helps make the alveoli more stable. ([Chapter 4.4](#))

Tachypnea (tăk-ĪP-nē-ă): Rapid breathing. ([Chapter 4.5](#))

Thoracentesis (thōr-ă-sĕn-TĒ-sĭs): A procedure to remove fluid from the space between the lining of the outside of the lungs (pleura) and the wall of the chest. ([Chapter 4.7](#))

Thoracic cavity (thō-RĀS-ĭk KĀV-ĭ-tē): The area of the body located between the neck and the diaphragm, housing the lungs and heart. ([Chapter 4.5](#))

Thoracic surgeon (thō-RĀS-ĭk SŪR-jŏn): A surgeon who specializes in surgical procedures of the chest, including the heart, lungs, esophagus, and other organs in the chest. ([Chapter 4.7](#))

Tonsillitis (tŏn-sĭl-Ī-tĭs): Inflammation of the tonsils. ([Chapter 4.4](#))

Trachea (TRĀ-kē-ă): The windpipe; a tube that connects the larynx to the bronchi, providing a pathway for air to enter the lungs. ([Chapter 4.4](#))

Tracheostomy (trā-kē-ŌS-tŏ-mē): A surgical procedure to create an opening through the neck into the trachea (windpipe) to allow direct access to the breathing tube. ([Chapter 4.4](#))

Tuberculosis (tū-bĕr-kyū-lŏ-sĭs) (TB): A serious infectious disease that mainly affects the lungs, caused by the bacterium *Mycobacterium tuberculosis*. ([Chapter 4.6](#))

Upper respiratory infection (ŪP-er RES-pĭr-ă-tŏ-rē ĭn-FEK-shun) (URI): A viral infection of one or more structures of the upper respiratory system, including the nose, nasal cavities, sinuses, pharynx, and larynx. ([Chapter 4.4](#))

Ventilation (vēn-tĭ-LĀ-shŭn): The movement of air in and out of the lungs. ([Chapter 4.5](#))

Wheezing (HWĒ-zĭng): A high-pitched whistling sound made while breathing, typically heard when exhaling, often associated with asthma or lung diseases. ([Chapter 4.6](#))

PART V

CHAPTER 5 URINARY SYSTEM TERMINOLOGY

5.1 Urinary System

Introduction

Learning Objectives

- Apply the rules of medical language to build, analyze, spell, pronounce, abbreviate, and define terms as they relate to the urinary system
- Identify meanings of key word components of the urinary system
- Categorize diagnostic, therapeutic, procedural, or anatomic terms related to the urinary system
- Use terms related to the urinary system
- Use terms related to the diseases and disorders of the urinary system

Introduction to the Urinary System

The urinary system filters waste products from the blood and produces urine. It also performs several additional physiological processes, such as regulating fluid volume and electrolyte levels, releasing hormones to control blood pressure and red blood cell production, and helping with bone health by controlling calcium and phosphorus levels.

This chapter will review common word components related to the urinary system to assist students in learning how to analyze, build, and define terms. Other urinary terms, whose definitions cannot be easily built from word

components, will be described in context based on the anatomy and physiology of the urinary system and common diseases and disorders. Medical specialists, diagnostic tests, and procedures related to the urinary system will also be discussed.

View the following YouTube video¹ on the urinary system:

▶ [Urinary System, Part 1: Crash Course Anatomy & Physiology #38](https://youtu.be/l128tW1H5a8?si=qJRaF8EPQrVMMkqQ)

1. CrashCourse. (2015, October 12). *Urinary system, Part 1: Crash Course Anatomy & Physiology #38* [Video]. YouTube. All rights reserved.
<https://youtu.be/l128tW1H5a8?si=qJRaF8EPQrVMMkqQ>

5.2 Word Components Related to the Urinary System

This section will describe common word components related to the urinary system. These word components can be used to build definitions for many medical terms related to the urinary system. Other common prefixes are described in [Chapter 1.3](#), and common suffixes are described in [Chapter 1.5](#).

COMMON PREFIXES RELATED TO THE URINARY SYSTEM

- **a-**: Absence of, without
- **an-**: Absence of, without
- **dia-**: Through, complete
- **dys-**: Painful, abnormal, difficult, labored
- **poly-**: Many, much

COMMON WORD ROOTS WITH A COMBINING VOWEL RELATED TO THE URINARY SYSTEM

- **albumin/o**: Albumin
- **azot/o**: Urea, nitrogen
- **blast/o**: Developing cell, germ cell
- **cyst/o**: Bladder, sac
- **glomerul/o**: Glomerulus
- **glyc/o**: Sugar
- **glycos/o**: Sugar
- **hydr/o**: Water
- **lith/o**: Stone, calculus
- **meat/o**: Meatus
- **nephr/o**: Kidney
- **noct/i**: Night
- **olig/o**: Few, scanty
- **py/o**: Pus
- **pyel/o**: Renal pelvis
- **ren/o**: Kidney
- **ur/o**: Urine, urinary tract
- **ureter/o**: Ureter
- **urethr/o**: Urethra
- **urin/o**: Urine, urinary tract
- **vesic/o**: Bladder, sac

COMMON SUFFIXES RELATED TO THE URINARY SYSTEM

- **-al**: Pertaining to
- **-ary**: Pertaining to
- **-cele**: Hernia, protrusion
- **-emia**: In the blood
- **-esis**: Condition
- **-gram**: The recorded radiographic image
- **-graph**: Instrument used to record
- **-graphy**: Process of recording, radiographic imaging
- **-iasis**: Condition
- **-itis**: Inflammation
- **-lith**: Stone
- **-lysis**: Loosening, dissolution, separating
- **-megaly**: Enlarged, enlargement
- **-oma**: Tumor, swelling
- **-osis**: Abnormal condition
- **-pexy**: Surgical fixation, suspension
- **-ptosis**: Drooping, sagging, prolapse
- **-rrhaphy**: Suturing, repairing
- **-scope**: Instrument used for visual examination
- **-scopic**: Pertaining to visual examination
- **-scopy**: Visual examination
- **-stomy**: Creation of an artificial opening
- **-tomy**: Cut into, incision
- **-tripsy**: Surgical crushing
- **-uria**: Urine, urination

5.3 Examples of Urinary Terms Easily Defined By Their Word Components

Here are examples of urinary medical terms that can be easily defined by breaking them into word components.

Cystoscopy

1. Break down the medical term into word components:
Cyst/o/scopy
2. Label the word parts: **Cyst** = WR; **o** = CV; **scopy** = S
3. Define the word components: **Cyst** = bladder; **scopy** = visual examination
4. Create a final definition of the medical term: **Visual examination of the bladder**

Dysuria

1. Break down the medical term into word components:
Dys/ur/ia
2. Label the word components: **Dys** = P; **ur** = WR; **ia** = S
3. Define the word components: **Dys** = painful or difficult; **ur** = urine; **ia** = condition of

4. Create a final definition of the medical term: **Condition of difficult or painful urination**

Nephritis

1. Break down the medical term into word components:
Nephr/itis
2. Label the word components: **Nephr** = WR; **itis** = S
3. Define the word components: **Nephr** = kidney; **itis** = inflammation
4. Create a final definition of the medical term:
Inflammation of the kidney



Interactive Learning Activity: Practice defining and pronouncing additional urinary system medical terms by breaking them down into word parts.



An interactive H5P element has been excluded from this version of the text. You can view it online here:

<https://wtcs.pressbooks.pub/medterm/?p=3446#h5p-136>

- ▶ You can also print this as a [Chapter 5 Student Companion Worksheet](#) and check your answers with this [Answer Key](#).

5.4 Anatomy of the Urinary System

The **urinary** (YŪR-ĭ-nĕr-ē) system, also referred to as the **renal** (RĒ-nāl) system or **urinary tract** (YŪR-ĭ-nĕr-ē trăkt), consists of the kidneys, ureters, bladder, and urethra. The kidneys form urine and perform other functions attributed to the urinary system. The ureters carry the urine away from kidneys to the urinary bladder, where it is stored until it is expelled during urination. The urethra carries the urine from the urinary bladder to the outside the body during urination.¹ See Figure 5.1² for an illustration of the male urinary system.

1. National Institute of Diabetes and Digestive and Kidney Diseases. (2020, June). *The urinary tract & how it works*. National Institutes of Health. <https://www.niddk.nih.gov/health-information/urologic-diseases/urinary-tract-how-it-works>
2. “Urinary_System_(Male).png” by BruceBlaus is licensed under [CC BY-SA 4.0](#)

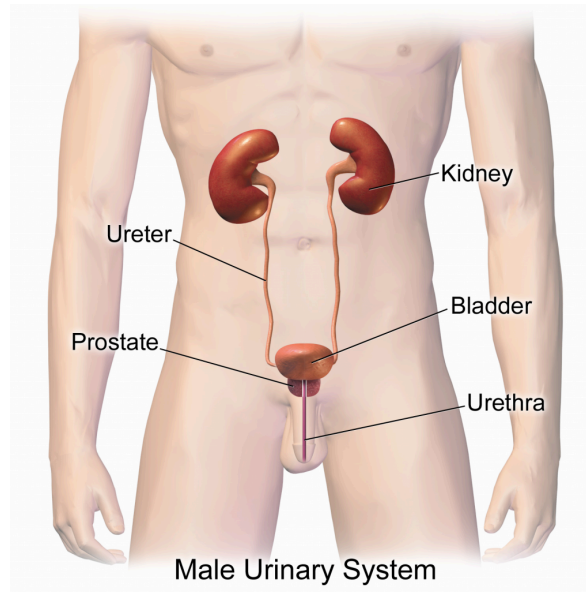


Figure 5.1 Male Urinary System

KIDNEYS

The **kidneys** (KĪD-nēz) are a pair of organs that filters waste from the blood and produces urine. Kidneys lie on either side of the spine behind the abdominal cavity, well protected by muscle, fat, and ribs. They are roughly the size of your fist. The male kidneys are typically a bit larger than the female kidneys. The kidneys are well-vascularized, receiving about 25 percent of the blood pumped out of the heart with each heartbeat.³ Figure 5.2⁴ shows the location of the kidneys.

3. This work is a derivative of *Anatomy and Physiology* by OpenStax licensed under CC BY 4.0. Access for free at <https://openstax.org/books/anatomy-and-physiology/pages/1-introduction>

4. “2608_Kidney_Position_in_Abdomen.jpg” by OpenStax College is licensed under CC BY 3.0

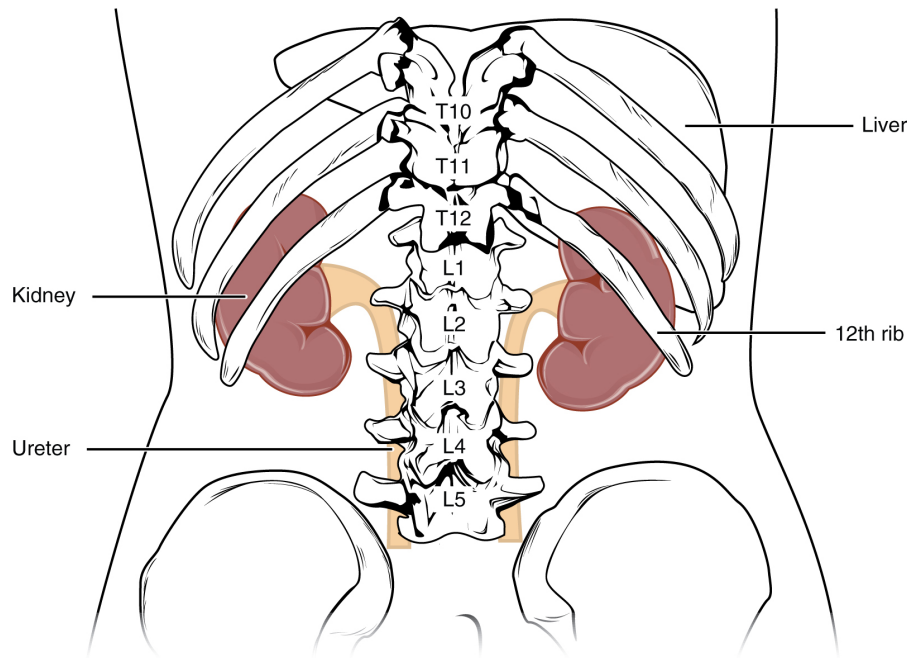


Figure 5.2 Kidneys

The outer region of the kidney is called the renal cortex, and the inner region is called the renal medulla. See Figure 5.3⁵ for an illustration of the internal structures of the kidney. The renal hilum is the entry and exit site for vessels, nerves, and ureters. The renal arteries (colored red) come directly from the descending aorta, and the renal veins (colored blue) return cleansed blood to the inferior vena cava.⁶

5. “[2610_The_Kidney.jpg](#)” by OpenStax College is licensed under [CC BY 3.0](#)

6. This work is a derivative of [Anatomy and Physiology](#) by [OpenStax](#) licensed under [CC BY 4.0](#). Access for free at <https://openstax.org/books/anatomy-and-physiology/pages/1-introduction>

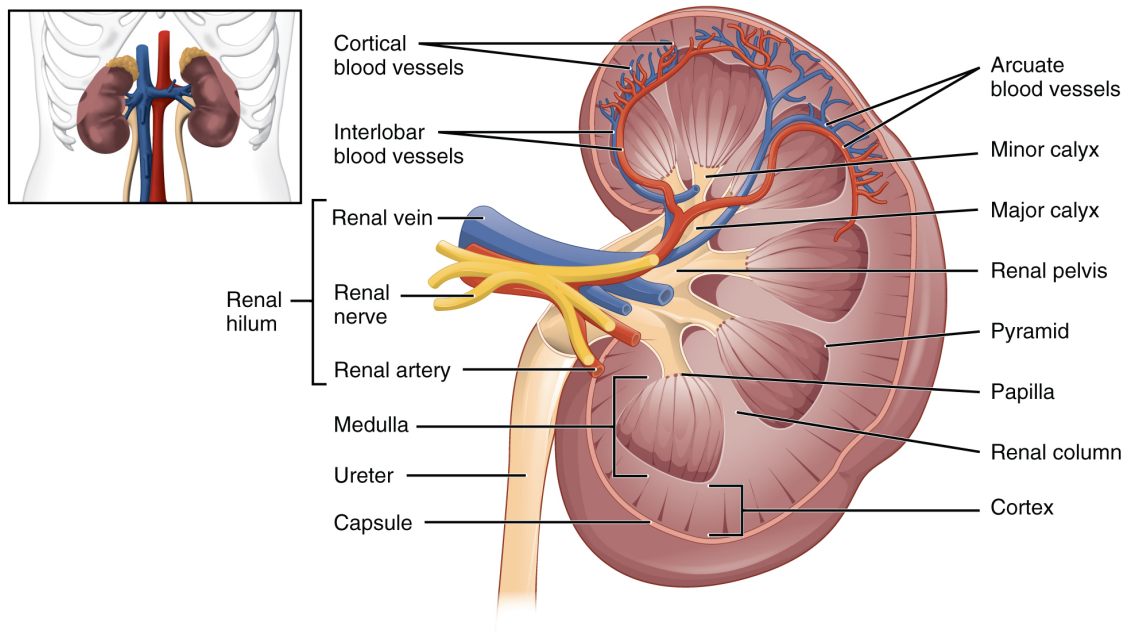


Figure 5.3 Internal Structures of the Kidney

Arterioles and Nephrons

The renal artery branches into small arteries called afferent arterioles that bring blood to the nephron. See Figure 5.4⁷ for an illustration of blood flow from the renal artery to the afferent arterioles to a nephron. The **nephron** (NĚF-rŏn) is the functional unit of the kidney and filters the blood, removes wastes, and balances fluid and electrolyte levels. Afferent arterioles service about 1.3 million nephrons in each kidney.⁸

7. “2612_Blood_Flow_in_the_Kidneys.jpg” by OpenStax College is licensed under [CC BY 3.0](#)

8. This work is a derivative of [Anatomy and Physiology](#) by [OpenStax](#) licensed under [CC BY 4.0](#). Access for free at <https://openstax.org/books/anatomy-and-physiology/pages/1-introduction>

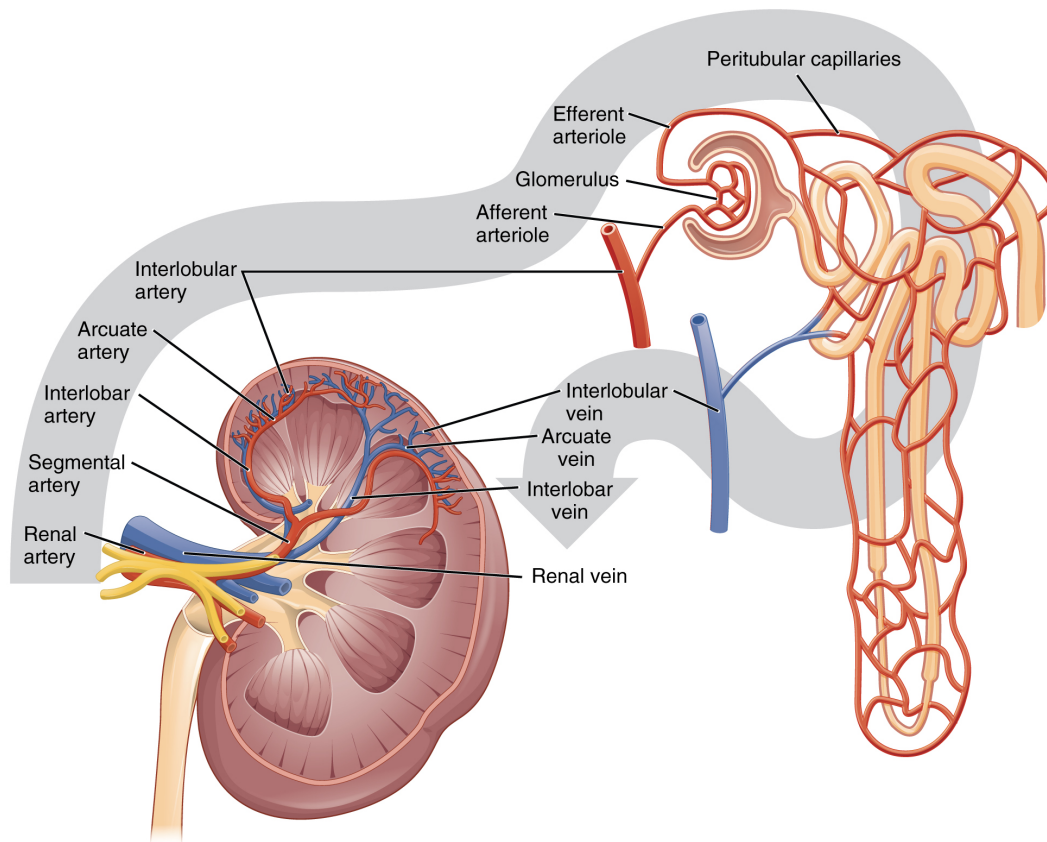


Figure 5.4 Blood Flow in the Kidneys

A nephron has two main sections called a renal corpuscle and a renal tubule. The renal corpuscle consists of a cluster of high-pressure capillaries, called the **glomerulus** (glō-MĚR-ū-lŭs), surrounded by a glomerular capsule. See Figure 5.5⁹ for an illustration of blood flow through the nephron. The capillaries in the glomerulus initially filter the blood to create a filtrate, which is mostly water, amino acids, glucose, and ions. The filtrate then flows through the renal tubule beginning with the proximal tubule, a long loop-like structure called the nephron loop (or loop of Henle), and the distal convoluted tubule. Different portions of the renal tubule have different permeabilities for solutes and water, and efferent arterioles recover most of the water and electrolytes

9. “[2611_Blood_Flow_in_the_Nephron.jpg](#)” by OpenStax College is licensed under [CC BY 3.0](#)

and return them back into the circulation. The remaining wastes pass as urine from the nephrons into collecting ducts and eventually into the ureters for elimination from the body.¹⁰

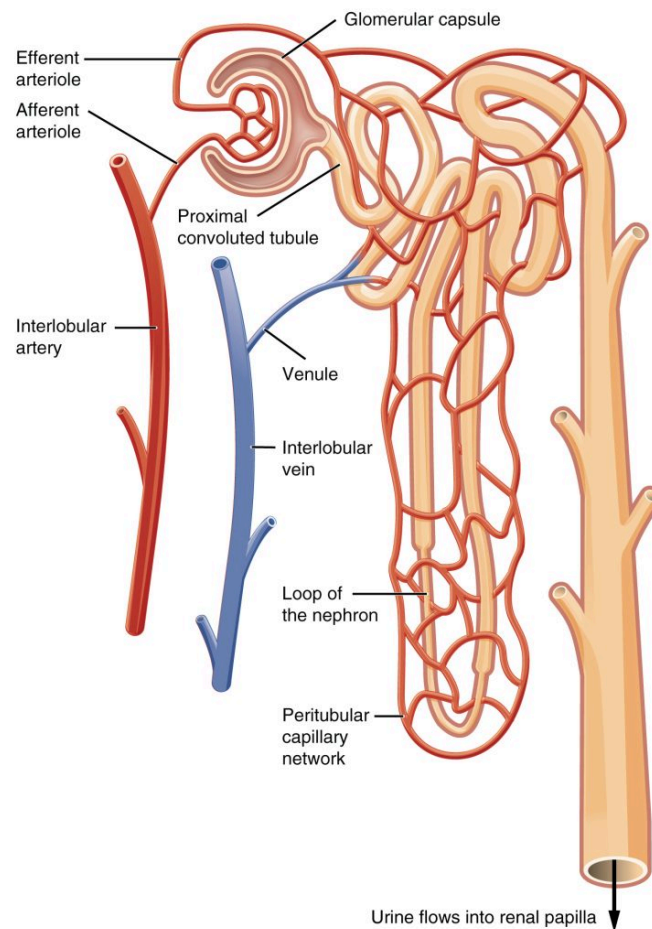


Figure 5.5 Blood Flow in the Nephron

¹⁰. This work is a derivative of [Anatomy and Physiology](https://openstax.org/books/anatomy-and-physiology/pages/1-introduction) by [OpenStax](https://openstax.org/books/anatomy-and-physiology/pages/1-introduction) licensed under [CC BY 4.0](https://creativecommons.org/licenses/by/4.0/). Access for free at <https://openstax.org/books/anatomy-and-physiology/pages/1-introduction>

URETERS

As urine is formed, it drains into the calyces of the kidney, which merge to form the funnel-shaped renal pelvis in the hilum of each kidney. The hilum narrows to become the **ureter** (YŪR-ě-těr). As urine passes through the ureter, it does not passively drain into the bladder but rather is propelled by wave-like contractions called peristalsis. The ureters are approximately 30 cm long.¹¹

BLADDER

The **bladder** (blăd-ěr) collects urine from both ureters. View Figure 5.6¹² to see a cross-section of the bladder. The bladder lies anterior to the uterus in females, posterior to the pubic bone, and anterior to the rectum. During late pregnancy, bladder capacity is reduced due to compression by the enlarging uterus, resulting in increased frequency of urination. In males, the anatomy is similar, minus the uterus, with the addition of the prostate inferior to the bladder. The bladder can project into the abdomen when it becomes **distended** (dis-TEN-ded) or stretched out with urine.¹³

11. This work is a derivative of [Anatomy and Physiology](#) by [OpenStax](#) licensed under [CC BY 4.0](#). Access for free at <https://openstax.org/books/anatomy-and-physiology/pages/1-introduction>
12. "[2605_The_Bladder.jpg](#)" by OpenStax College is licensed under [CC BY 3.0](#)
13. This work is a derivative of [Anatomy and Physiology](#) by [OpenStax](#) licensed under [CC BY 4.0](#). Access for free at <https://openstax.org/books/anatomy-and-physiology/pages/1-introduction>

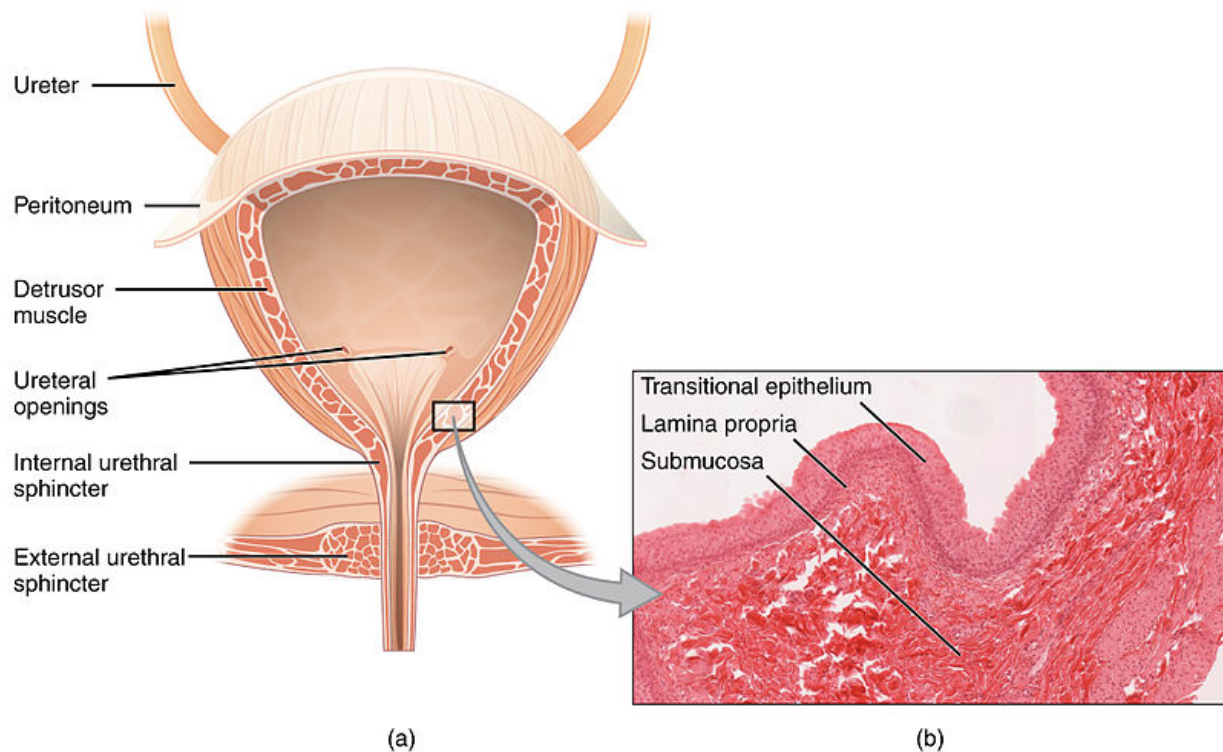


Figure 5.6 Bladder

URETHRA

The **urethra** (yū-RĒ-thră) transports urine from the bladder to the outside of the body during urination. The urethra is the only urologic organ that is significantly different between males and females; all other urine transport structures are identical. In females, the urethra is shorter, which causes an

increased risk for urinary tract infections.¹⁴ See Figure 5.7¹⁵ for a comparison of the female and male urinary systems.

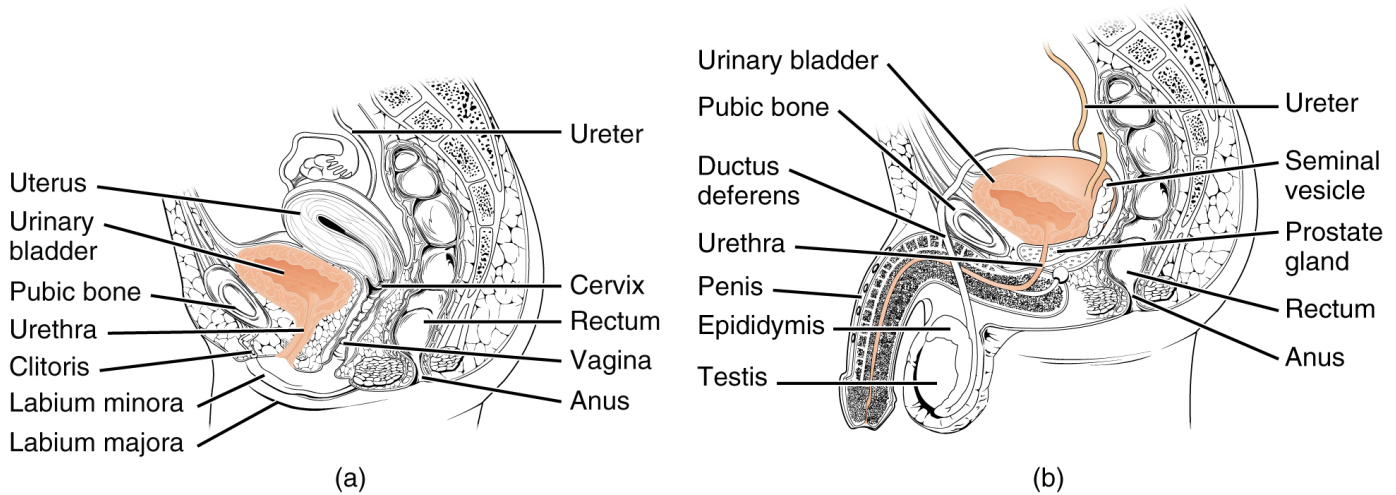


Figure 5.7 Female and Male Urinary Systems

URINATION

Urinate (YŪR-ĭ-nāt) means to pass urine, also referred to as **void** (voyd) or **micturate** (MĪK-tū-rāt). A healthy adult with normal functioning kidneys produces an average of 800-2,000 mL of urine per day, depending on their

14. This work is a derivative of [Anatomy and Physiology](#) by [OpenStax](#) licensed under [CC BY 4.0](#). Access for free at <https://openstax.org/books/anatomy-and-physiology/pages/1-introduction>
15. “Female_and_Male_Urethra.jpg” by OpexStax College is licensed under [CC BY 4.0](#) Access for free at <https://openstax.org/books/anatomy-and-physiology-2e/pages/1-introduction>

fluid intake and other physiological processes. The adult bladder typically holds about 360-480 mL of urine.¹⁶

Urination is regulated by the internal and external urinary **sphincters** (SFĬNK-těrz), circular muscles constricting an orifice (opening). As the bladder fills to about 150 mL (5 ounces), it sends signals to the brain to create an urge to urinate. The internal and external urinary sphincters work together to close off the urethra to keep urine in the bladder until the brain sends signals it is time to urinate. As the bladder continues to fill, subsequent urges become harder to ignore. If voluntary voiding does not occur and the bladder overfills, voluntary control fails, resulting in urinary **incontinence** (ĭn-KŎN-tĭ-něns).¹⁷

Frequency of urination depends on how quickly the kidneys produce urine and how much urine a person's bladder can comfortably hold. Normal urine is typically clear or pale to light yellow in color with little to no odor. However, some foods (like asparagus) or medications (such as antibiotics) may change the smell or color of urine.¹⁸

In infants, the reflex to urinate is active, but as toddlers mature, they learn how to override the reflex and control the external sphincter, thus delaying voiding until it is appropriate to do so (commonly referred to as “potty training”).¹⁹

16. This work is a derivative of [Anatomy and Physiology](#) by [OpenStax](#) licensed under [CC BY 4.0](#). Access for free at <https://openstax.org/books/anatomy-and-physiology/pages/1-introduction>

17. This work is a derivative of [Anatomy and Physiology](#) by [OpenStax](#) licensed under [CC BY 4.0](#). Access for free at <https://openstax.org/books/anatomy-and-physiology/pages/1-introduction>

18. National Institute of Diabetes and Digestive and Kidney Diseases. (2020, June). *The urinary tract & how it works*. National Institutes of Health. <https://www.niddk.nih.gov/health-information/urologic-diseases/urinary-tract-how-it-works>

19. This work is a derivative of [Anatomy and Physiology](#) by [OpenStax](#) licensed

under [CC BY 4.0](https://openstax.org/books/anatomy-and-physiology/pages/1-introduction). Access for free at <https://openstax.org/books/anatomy-and-physiology/pages/1-introduction>

5.5 Physiology of the Urinary System

The kidneys filter all the blood in your body every 30 minutes and create urine. They remove waste products and excess fluid and also regulate electrolytes and hormones that control blood pressure, stimulate production of red blood cells, and keep bones healthy.¹

FILTRATION, REABSORPTION, AND SECRETION

As previously discussed in “[Anatomy of the Urinary System](#),” blood enters the kidneys via the renal arteries and is filtered by nephrons, where many functions take place. Three principal functions of the nephron are filtration, reabsorption, and secretion. Secondary functions of the nephron include controlling blood pressure (via the production of renin), producing red blood cells (via the hormone erythropoietin), and absorbing calcium.²

The initial filtering of the blood takes place in the glomerulus, a cluster of capillaries surrounded by the glomerular capsule within the nephron. The

1. Centers for Disease Control and Prevention. (2022, February 28). *Chronic kidney disease basics*. <https://www.cdc.gov/kidneydisease/basics.html>
2. National Institute of Diabetes and Digestive and Kidney Diseases. (2020, June). *The urinary tract & how it works*. National Institutes of Health. <https://www.niddk.nih.gov/health-information/urologic-diseases/urinary-tract-how-it-works>

renal tubule receives this filtered fluid, called glomerular filtrate, and electrolytes and water are reabsorbed in different parts of the renal tubule and returned to circulation. The final end product of the filtered fluid is urine.³

Glomerular Filtration

The first step in urine production is **glomerular filtration** (glō-MER-yū-lăř fĭl-TRĀ-shŭn). In this process, water and most of the solutes in the blood pass through the wall of glomerular capillaries into the glomerular capsule and then into the renal tubule. This process filters the blood and creates a filtrate that does not contain blood cells or large proteins, referred to as glomerular filtrate.⁴

The volume of filtrate formed by both kidneys per minute is called the **glomerular filtration rate** (glō-MER-yū-lăř fĭl-TRĀ-shŭn rāt) (**GFR**). GFR is used to assess how well the kidneys are functioning. The heart pumps about five liters of blood per minute when a person is resting, and approximately 20 percent of this (i.e., one liter) enters the kidneys to be filtered per minute. On average, this results in the production of about 115 mL/min of filtrate produced by the nephrons. However, 99 percent of this filtrate is returned to the circulation by reabsorption so that only about 1–2 liters of urine are produced per day.⁵

GFR is influenced by hydrostatic pressure, osmotic pressure, and oncotic pressures. **Hydrostatic** (hĭ-drō-STAT-ik) pressure refers to the pressure produced by a fluid against a surface. Glomerular filtration occurs as

3. [Anatomy & Physiology](#) by CCCOnline is licensed under [CC BY-SA](#)

4. This work is a derivative of [Anatomy and Physiology](#) by [OpenStax](#) licensed under [CC BY 4.0](#). Access for free at <https://openstax.org/books/anatomy-and-physiology/pages/1-introduction>

5. This work is a derivative of [Anatomy and Physiology](#) by [OpenStax](#) licensed under [CC BY 4.0](#). Access for free at <https://openstax.org/books/anatomy-and-physiology/pages/1-introduction>

hydrostatic pressure forces fluid and solutes through the semipermeable barrier of the glomerular capillary membrane. The movement of solutes out of the blood is limited by their size. Glomerular filtration occurs when glomerular capillary hydrostatic pressure exceeds the luminal hydrostatic pressure of glomerular capsule.⁶ See Figure 5.8⁷ for an illustration of hydrostatic pressure in a capillary.

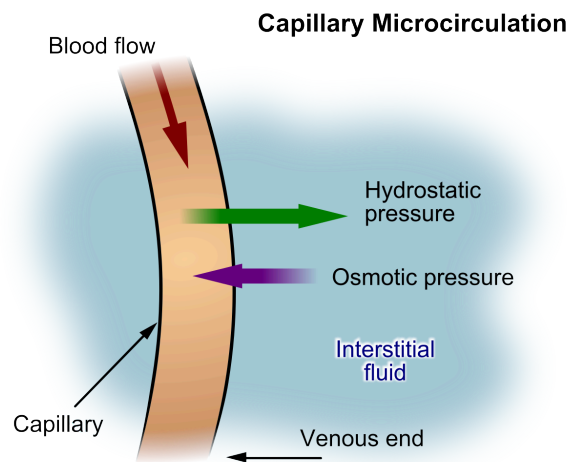


Figure 5.8 Hydrostatic and Osmotic Pressures in Capillaries

Another force, called osmotic pressure, also controls the movement of water. **Osmosis** (ōz-MŌ-sīs) refers to the movement of water across a semipermeable membrane that is impermeable to a solute. As long as the concentration of water differs on both sides, water will move in the direction of lower pressure until the osmotic pressure on both sides of the membrane is equal. For this reason, a proper concentration of solutes in the blood is

6. This work is a derivative of [Anatomy and Physiology](#) by [OpenStax](#) licensed under [CC BY 4.0](#). Access for free at <https://openstax.org/books/anatomy-and-physiology/pages/1-introduction>

7. "[Capillary_microcirculation.jpg](#)" by [Kes47](#) is in the [Public Domain](#)

important in maintaining osmotic pressure in the glomerulus, as well as systemically throughout the body.⁸

A third force, called **oncotic pressure** (ŏn-KŎT-ĭk PRĚSH-ŭr), is created by the protein content of the blood that helps hold water inside of capillaries. There are urinary system disorders in which too much protein passes through during filtration into the glomerular filtrate. This excess protein in the filtrate leads to a deficiency of circulating proteins in the blood. In turn, the presence of excess protein in the urine allows it to retain more water in the filtrate and results in an increase in urine volume. Because there is less circulating protein in the blood (principally albumin), the osmotic pressure of the blood also falls. Less osmotic pressure tips the balance towards hydrostatic pressure, which causes water to be pushed out of the capillaries. The net effect is that water is lost from the circulation into interstitial tissues and cells. This “plumps up” the tissues and cells, a condition called **edema** (ĭ-DE-mă) or puffy, swollen tissue due to accumulation of fluid.⁹

Tubular Reabsorption and Secretion

After glomerular filtration, the filtrate continues to undergo modification through secretion and reabsorption in the renal tubules before urine is produced and collected in the collecting ducts. During this process, some substances are reabsorbed, whereas others are secreted. In fact, 99 percent of the water and most of the solutes that were filtered out during glomerular filtration are reabsorbed in the tubules. A blood vessel runs alongside the tubule. As the filtered fluid moves along the tubule, a blood vessel reabsorbs almost all of the water, along with minerals and nutrients the body needs,

8. This work is a derivative of [Anatomy and Physiology](https://openstax.org/books/anatomy-and-physiology/pages/1-introduction) by [OpenStax](https://openstax.org/books/anatomy-and-physiology/pages/1-introduction) licensed under [CC BY 4.0](https://creativecommons.org/licenses/by/4.0/). Access for free at <https://openstax.org/books/anatomy-and-physiology/pages/1-introduction>
9. This work is a derivative of [Anatomy and Physiology](https://openstax.org/books/anatomy-and-physiology/pages/1-introduction) by [OpenStax](https://openstax.org/books/anatomy-and-physiology/pages/1-introduction) licensed under [CC BY 4.0](https://creativecommons.org/licenses/by/4.0/). Access for free at <https://openstax.org/books/anatomy-and-physiology/pages/1-introduction>

and returns them to the body via the renal vein. The remaining fluid and wastes in the tubule become urine.¹⁰

See Figure 5.9¹¹ for an illustration of nephron structure. The glomerulus (1) filters small solutes from the blood. The proximal tubule (2) reabsorbs 60-70% of the sodium and water back into the bloodstream. From the proximal tubule, the filtrate flows into the descending loop of Henle (3) and then into the ascending loop of Henle (4). Another 20-25% of sodium is reabsorbed in the ascending loop of Henle. Filtrate then enters the distal tubule (5), where sodium is actively filtered in exchange for potassium or hydrogen ions to maintain blood pH and electrolyte balance, a process regulated by the hormone aldosterone. The collecting duct (6) is the final pathway where antidiuretic hormone (ADH) acts to further reabsorb water and solutes back into the bloodstream, thereby preventing it from being eliminated in urine.¹²

10. This work is a derivative of [Anatomy and Physiology](#) by [OpenStax](#) licensed under [CC BY 4.0](#). Access for free at <https://openstax.org/books/anatomy-and-physiology/pages/1-introduction>

11. "[Figure 41 03 04.jpg](#)" by [CNX OpenStax](#) is licensed under [CC BY 4.0](#)

12. McCuistion, L., Vuljoin-DiMaggio, K., Winton, M., & Yeager, J. (2018). *Pharmacology: A patient-centered nursing process approach*. pp. 443-454. Elsevier.

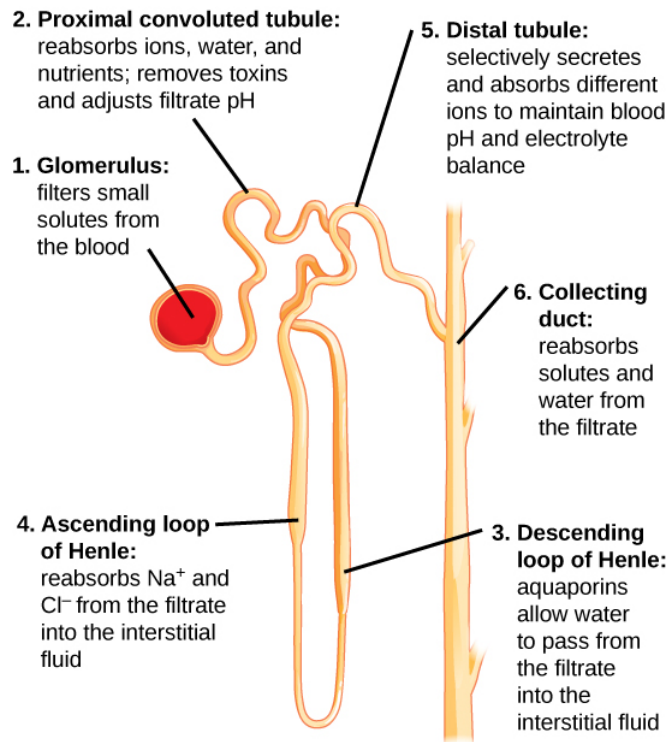


Figure 5.9 Nephron Structure

Imbalances Resulting From Nephron Damage

Several diseases and disorders can damage the kidneys and the nephrons. When nephrons are damaged, their ability to filter, reabsorb, and secrete substances is affected. Two common symptoms of kidney disease include fluid retention (causing edema) and **hyperkalemia** (hī-pĕr-kă-LĒM-ē-ă) or increased levels of potassium in the blood due to a reduced inability to reabsorb these substances.

URINE

Urine volume varies considerably by individual, based on several factors such as fluid intake, perspiration, and disorders affecting the urinary system. The normal range of urine output for adults is one to two liters per day. The

kidneys must produce a minimum urine volume of about 500 mL/day to adequately rid the body of wastes. Urine output below this level can be caused by severe dehydration or kidney disease.¹³

Urine color and odor are affected by many conditions and even the food the person has eaten. For example, a urinary tract infection or kidney stone may cause bleeding, resulting in pink or even bright red urine. Dehydration produces darker, concentrated urine. See Figure 5.10¹⁴ for an illustration of the color of urine based on the patient's hydration status. Additionally, about one in five people detect a distinctive odor in their urine after consuming asparagus; other foods such as onions, garlic, and fish can impart their own aromas. These food-caused odors are harmless.¹⁵

13. This work is a derivative of [Anatomy and Physiology](#) by [OpenStax](#) licensed under [CC BY 4.0](#). Access for free at <https://openstax.org/books/anatomy-and-physiology/pages/1-introduction>
14. "[2601_Urine_Color_Chart.jpg](#)" by OpenStax College is licensed under [CC BY 3.0](#)
15. This work is a derivative of [Anatomy and Physiology](#) by [OpenStax](#) licensed under [CC BY 4.0](#). Access for free at <https://openstax.org/books/anatomy-and-physiology/pages/1-introduction>

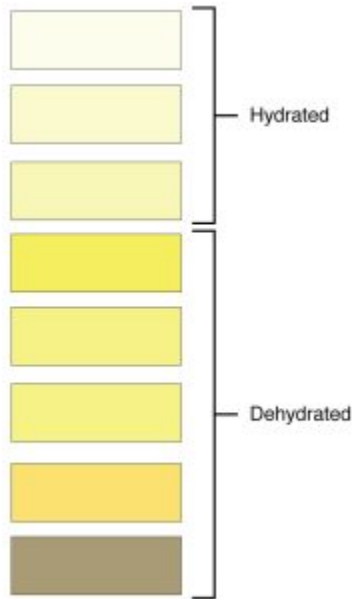


Figure 5.10 Urine Color Based on Hydration Status

Urea

Urea (yū-RĒ-ă) nitrogen is a waste product made when the liver breaks down protein into amino acids, and then **deamination** (dē-am-ĭ-NĀ-shŏn) converts the amino acids into ammonia, urea, or uric acid. Urea is transported in the blood, filtered out by the kidneys, and eliminated from the body in urine. Urine primarily contains urea with small amounts of ammonia and uric acid. When damage occurs to the nephrons, urea is filtered out less efficiently, and a buildup of urea in the blood can occur.¹⁶ For this reason, a diagnostic test called blood urea nitrogen (BUN) provides important information about kidney function and is further discussed in the “[Medical Specialists, Diagnostic Testing, and Procedures Related to the Urinary System](#)” section.

Most of the ammonia produced from the breakdown of protein in the body

¹⁶. This work is a derivative of [Anatomy and Physiology](#) by [OpenStax](#) licensed under [CC BY 4.0](#). Access for free at <https://openstax.org/books/anatomy-and-physiology/pages/1-introduction>

is converted into urea by the liver, so the odor of ammonia is rarely detected in fresh urine. The strong ammonia odor that can sometimes be detected in bathrooms is due to the breakdown of urea into ammonia by bacteria in the environment.¹⁷

Diuretics

A **diuretic** (dī-ū-RĒT-ĭk) is a substance that increases urine production. Three common beverages contain diuretic compounds: coffee, tea, and alcohol. The caffeine in coffee and tea works by promoting vasodilation in the nephron, which increases GFR. Alcohol increases GFR by inhibiting ADH release from the posterior pituitary, resulting in less water recovery by the collecting duct. Medications called diuretics are prescribed to individuals with high blood pressure to reduce blood volume and, thereby, reduce blood pressure.¹⁸

Other Terms Related to Urine and Urination

Terms commonly used to document urine and urination are as follows:

- **Anuria** (ă-NOOR-ē-ă): Absence of urine output, typically found during kidney failure, defined as less than 50 mL of urine over a 24-hour period.
- **Diuresis** (dī-ū-RĒ-sĭs): Increased production of urine.
- **Dysuria** (dĭs-ŪR-ē-ă): Painful or difficult urination.
- **Enuresis** (en-ū-RĒ-sĭs): Involuntary urination, especially by children at night.
- **Frequency** (FRĒ-kwĕn-sē): The need to urinate several times during the

17. This work is a derivative of [Anatomy and Physiology](https://openstax.org/books/anatomy-and-physiology/pages/1-introduction) by [OpenStax](https://openstax.org/books/anatomy-and-physiology/pages/1-introduction) licensed under [CC BY 4.0](https://creativecommons.org/licenses/by/4.0/). Access for free at <https://openstax.org/books/anatomy-and-physiology/pages/1-introduction>

18. This work is a derivative of [Anatomy and Physiology](https://openstax.org/books/anatomy-and-physiology/pages/1-introduction) by [OpenStax](https://openstax.org/books/anatomy-and-physiology/pages/1-introduction) licensed under [CC BY 4.0](https://creativecommons.org/licenses/by/4.0/). Access for free at <https://openstax.org/books/anatomy-and-physiology/pages/1-introduction>

day or at night (nocturia) in normal or less-than-normal volumes. It may be accompanied by a feeling of urgency.¹⁹

- **Hematuria** (hē-mă-TŪR-ē-ă): Blood in the urine, either visualized or found during microscopic analysis.
- **Oliguria** (ō-lī-GŪR-ē-ă): Decreased urine output, defined as less than 500 mL of urine in adults in a 24-hour period.
- **Nocturia** (nōk-TŪR-ē-ă): The need to get up at night on a regular basis to urinate. Nocturia often causes sleep deprivation that affects a person's quality of life.²⁰
- **Polyuria** (pōl-ē-ŪR-ē-ă): Greater than 2.5 liters of urine output over 24 hours, also referred to as diuresis.²¹ New polyuria should be reported to the health care provider because it can be a sign of many medical conditions.
- **Pyuria** (pī-ŪR-ē-ă): White blood cells in a urine sample indicating infection. In severe infections, pus may be visible in the urine.²² See Figure 5.11²³ for an image of pyuria.
- **Urgency** (ŪR-jěn-sē): A sensation of an urgent need to void.²⁴ Urgency can

19. Maddukuri, G. (2021, January). *Urinary frequency*. Merck Manual Professional Version. <https://www.merckmanuals.com/professional/genitourinary-disorders/symptoms-of-genitourinary-disorders/urinary-frequency>

20. This work is a derivative of [StatPearls](#) by Leslie, Sajjad, & Singh and is licensed under [CC BY 4.0](#)

21. A.D.A.M. Medical Encyclopedia [Internet]. Atlanta (GA): A.D.A.M., Inc.; c1997-2021. Urination – excessive amount; [updated 2021, Feb 8; cited 2021, Feb 16]. <https://medlineplus.gov/ency/article/003146.htm>

22. Cherney, K. (2018, August 30). *Everything you should know about pyuria*. Healthline. <https://www.healthline.com/health/pyuria>

23. “Pyuria2011.JPG” by [James Heilman, MD](#) is licensed under [CC BY-SA 3.0](#)

24. Maddukuri, G. (2021, January). *Urinary frequency*. Merck Manual Professional

cause urge incontinence if the patient is not able to reach the bathroom quickly.

- **Urinal** (Ū-rĭn-ăl): A receptacle used for urine collection in health care facilities.



Figure 5.11 Pyuria

View the following YouTube video about the urinary
system: [Urinary System, Part 2: Crash Course Anatomy & Physiology #39](https://www.youtube.com/watch?v=DlqyyyvTI3k)²⁵

Version. <https://www.merckmanuals.com/professional/genitourinary-disorders/symptoms-of-genitourinary-disorders/urinary-frequency>

- ²⁵ CrashCourse. (2015, October 19). Urinary system, Part 2: Crash Course Anatomy & Physiology #39 [Video]. YouTube. All rights reserved. <https://youtu.be/DlqyyyvTI3k?si=Pf8-IEPgHQJTLHAa>

5.6 Diseases and Disorders of the Urinary System

ACUTE KIDNEY FAILURE

Acute kidney failure (ā-kūt kīd-nē fāl-yŭr) is the rapid (less than two days) loss of kidney function. There are many possible causes of acute kidney failure. They include the following¹:

- Acute tubular necrosis (damage to the renal tubules)
- Autoimmune kidney disease
- Decreased blood flow to the kidneys due to very low blood pressure, which can result from dehydration, hemorrhage, serious illness or injury, or surgery
- Disorders that cause clotting within the kidney's blood vessels
- Infections that directly injure the kidney, such as acute pyelonephritis (severe infection of the kidneys)
- Pregnancy complications, including placental abruption (separation of the placenta from the uterine wall) or placenta previa (placenta blocking the cervix)
- Urinary tract blockage
- Illicit drugs such as cocaine and heroin
- Medicines including nonsteroidal anti-inflammatory drugs (NSAIDs), certain antibiotics and blood pressure medicines, intravenous contrast

1. A.D.A.M. Medical Encyclopedia [Internet]. Atlanta (GA): A.D.A.M., Inc.; c1997-2023. Acute Kidney Failure; [reviewed 2022, April 11]. <https://medlineplus.gov/ency/article/000501.htm>

(dye), HIV medications, and some types of cancer

Acute kidney failure is diagnosed through blood and urine tests that measure creatinine, urea nitrogen, and protein levels in the blood and urine. Read more information about these diagnostic tests in the “[Medical Specialists, Diagnostic Testing, and Procedures Related to the Urinary System](#)” section.

Acute kidney failure is typically treated with dialysis and medications. Read more information about dialysis in the “[Medical Specialists, Diagnostic Testing, and Procedures Related to the Urinary System](#)” section.

CHRONIC KIDNEY DISEASE

Kidney disease is a leading cause of death in the United States. More than one in seven American adults have **chronic kidney disease** (KRŎN-ĭk kĭd-nē dĩ-ZĒZ) (**CKD**) where the kidneys are damaged and cannot filter blood as well as they should. Because of the decreased kidney function, excess fluid and waste products remain in the body and cause other health problems. CKD has varying levels of seriousness and usually gets worse over time, although treatment has been shown to slow its progression. If left untreated, CKD can progress to kidney failure. Kidney failure is also called **end-stage renal disease** (ĕnd-stāj rē-nāl dĩ-ZĒZ).²

Risk factors for developing CKD include diabetes mellitus type 1 and type 2, high blood pressure, heart disease, family history of CKD, and obesity. People with CKD may not feel ill or notice any symptoms. The only way to diagnose CKD is through blood and urine tests that measure creatinine, urea nitrogen, and protein levels. Read more information about these diagnostic tests in the

2. Centers for Disease Control and Prevention. (2022, February 28). *Chronic kidney disease basics*. <https://www.cdc.gov/kidneydisease/basics.html>

“Medical Specialists, Diagnostic Testing, and Procedures Related to the Urinary System” section.

CKD is treated by carefully managing blood pressure and diabetes to prevent further damage to the nephrons. If the kidneys stop working, dialysis or a kidney transplant is needed for survival.³ Read more information about dialysis and kidney transplantation in the “Medical Specialists, Diagnostic Testing, and Procedures Related to the Urinary System” section.

GLOMERULONEPHRITIS

Glomerulonephritis (glō-mĕr-ŭ-lō-nĕ-FRĭ-tĭs) involves inflammation of the glomerular capillaries. Glomerulonephritis can be caused by immune system problems, cancer, or infections such as strep infections, viruses, heart infections, or abscesses. It can develop quickly and lead to kidney failure, or it can become a chronic disease. Damage to the glomeruli affects their ability to filter correctly, and blood and protein can be lost in the urine. Common symptoms of glomerulonephritis include blood in the urine (hematuria), foamy urine (due to excess protein in the urine), and swelling (edema) of the face, eyes, ankles, feet, legs, or abdomen due to decreased protein (and osmotic pressure) in the bloodstream. Many diagnostic tests may be performed, but the diagnosis is typically confirmed by a kidney biopsy. Treatment depends upon the cause, but controlling high blood pressure with medications is usually the most important part of treatment. Drugs that suppress the immune system may also be prescribed.⁴

3. Centers for Disease Control and Prevention. (2022, February 28). *Chronic kidney disease basics*. <https://www.cdc.gov/kidneydisease/basics.html>

4. A.D.A.M. Medical Encyclopedia [Internet]. Atlanta (GA): A.D.A.M., Inc.; c1997-2023. Glomerulonephritis; [reviewed 2021, July 27]. <https://medlineplus.gov/ency/article/000484.htm>

HYDRONEPHROSIS

Hydronephrosis (hī-drō-ně-FRŌ-sīs) is the swelling of one or both kidneys because of urine backflow into the kidney. Several conditions can cause hydronephrosis, such as a kidney stone or other blockage in the ureters or back flow of urine from the bladder to the kidney, which is called **vesicoureteral reflux** (vēs-ĭ-kō-yū-RĒT-ěr-ăl rē-FLŮKS). Symptoms include back/side pain, an abdominal mass, nausea and vomiting, urinary tract infection (UTI), fever, dysuria (painful urination), and increased urinary frequency or urgency. Many diagnostic tests may be performed, such as an intravenous pyelogram. An intravenous pyelogram (IVP) is discussed in the [“Medical Specialists, Diagnostic Testing, and Procedures Related to the Urinary System”](#) section. Treatment is performed to treat the cause and may include placing a stent (tube) through the bladder and ureter to allow urine to flow from the kidney into the bladder, placing a tube into the kidney through the skin to allow the blocked urine to drain out of the body into a drainage bag, removing a stone causing the blockage, or performing surgery to correct the blockage or reflux.⁵

NEPHROLITHIASIS

Nephrolithiasis (něf-rō-lĭ-THĪ-ă-sīs), commonly referred to as kidney stones, is solid pieces of material that form in the kidney from substances in the urine, such as calcium or uric acid. A kidney stone, also called **renal calculus** (RĒ-năl KĀL-kŭ-lŭs), may be as small as a grain of sand or as large as a pearl. See

5. A.D.A.M. Medical Encyclopedia [Internet]. Atlanta (GA): A.D.A.M., Inc.; c1997-2023. Hydronephrosis of One Kidney; [reviewed 2021, July 1]. <https://medlineplus.gov/ency/article/000506.htm>

Figure 5.12⁶ for an image of various sizes of kidney stones. Most kidney stones pass out of the body without medical intervention, but some get stuck in the urinary tract, block the flow of urine, and cause severe pain. Pain is typically located in the back or side. People with kidney stones may have hematuria (blood in the urine), fever and chills, vomiting, foul-smelling urine that may appear cloudy, or dysuria (painful urination).⁷



Figure 5.12 Kidney Stones

Extracorporeal shock wave **lithotripsy** (LĪTH-ō-trīp-sē) or commonly called ESWL is a procedure for treating stones in the kidney and ureter that does not require surgery. Instead, high-energy shock waves are passed through the

6. “Kidney stones %28 renal calculi %29, Бубрежни камења_15.jpg” by Jakupica is licensed under [CC BY-SA 4.0](#)

7. MedlinePlus [Internet]. Bethesda (MD): National Library of Medicine (US); [updated 2016, Dec 8]. Kidney Stones; [cited 2023, Oct 12]. <https://medlineplus.gov/kidneystones.html>

body and used to break stones into pieces as small as grains of sand. Because of their small size, these pieces can then pass out the body with the urine.⁸

Nephrolithotomy (něf-rō-lī-THŎT-ŏ-mē) may be performed for patients who have large (two centimeters) or irregularly shaped kidney stones, stones that have not been broken up successfully by extracorporeal shock wave lithotripsy, or those who are not candidates for ureteroscopy. During this procedure, the surgeon enters the kidney through a small incision in the back and then threads a **nephroscope** (NĚF-rŏ-skōp), a miniature fiberoptic camera and then other small instruments, through the incision to remove the stone.⁹

POLYCYSTIC KIDNEY DISEASE

Polycystic kidney disease (pŏl-ē-SĪS-tĭk KĪD-nē dĭ-ZĒZ) (**PKD**) is an inherited genetic mutation that affects the kidneys and other organs. It is an inherited disorder that is passed down through families genetically. Clusters of fluid-filled sacs, called cysts, develop in the kidneys and interfere with their ability to filter waste products from the blood. See Figure 5.13¹⁰ for an illustration of PKD. The growth of cysts causes the kidneys to become enlarged and can lead to chronic kidney disease (CKD). As CKD worsens, treatments for end-stage kidney disease may include dialysis or a kidney transplant. Cysts may also develop in other organs, particularly the liver. Cysts that are painful,

8. National Kidney Foundation. (n.d.). *Lithotripsy*. <https://www.kidney.org/atoz/content/lithotripsy>
9. National Kidney Foundation. (n.d.). *Percutaneous nephrolithotomy/nephrolithrotripsy*. https://www.kidney.org/atoz/content/kidneystones_PNN
10. “[Polycystic kidneys, gross pathology CDC PHIL.png](#)” by CDC/ Dr. Edwin P. Ewing, Jr. is licensed in the [Public Domain](#).

infected, bleeding, or causing a blockage may need to be drained. There are usually too many cysts to make it practical to remove each cyst, so surgery to remove one or both kidneys may be needed.¹¹

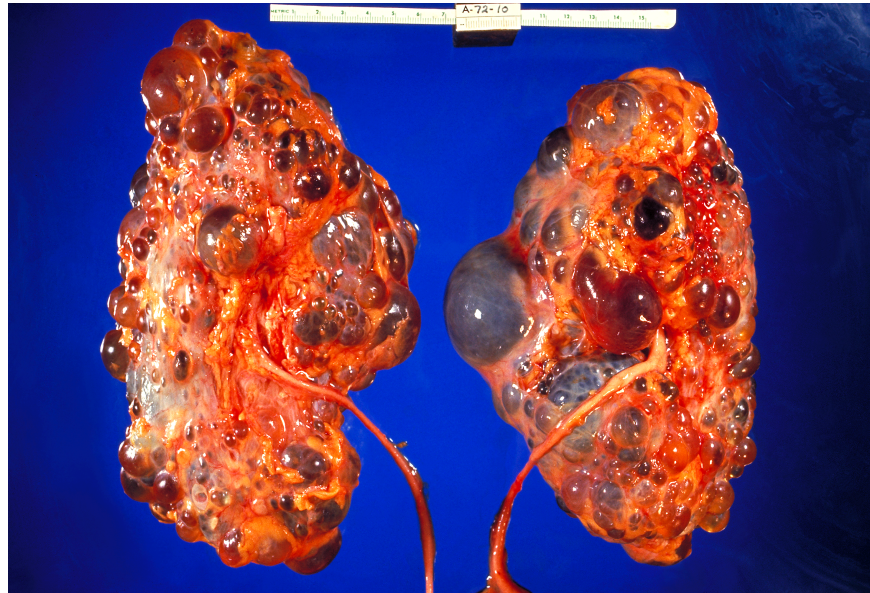


Figure 5.13 Polycystic Kidney Disease

RENAL CELL CANCER

Renal cell cancer (also called renal cell carcinoma) is the most common type of kidney cancer. Cancer occurs in tubules in the kidneys where urine is produced and collected. There are many types of treatments for renal cell cancer, including surgery, radiation therapy, chemotherapy, immunotherapy, and targeted therapy. The types of surgery that may be used are as follows¹²:

11. A.D.A.M. Medical Encyclopedia [Internet]. Atlanta (GA): A.D.A.M., Inc.; c1997-2023. Polycystic Kidney Disease; [reviewed 2021, July 27]. <https://medlineplus.gov/ency/article/000502.htm>

12. National Cancer Institute. (2023, July 21). *Renal cell cancer – PDQ patient*

- **Partial nephrectomy** (něf-RĚK-tǔ-mē): A surgical procedure to remove the cancer within the kidney and some of the tissue around it.
- **Simple nephrectomy** (sĭm-pĭl něf-RĚK-tǔ-mē): A surgical procedure to remove the kidney.
- **Radical nephrectomy** (rǎd-ĭ-kǎl něf-RĚK-tǔ-mē): A surgical procedure to remove the kidney, the adrenal gland, surrounding tissue, and, usually, nearby lymph nodes.

URINARY INCONTINENCE

Urinary incontinence (YŪR-ĭ-nĕr-ē ĭn-KŎN-tĭ-nĕns) is the involuntary loss of urine. It is a common symptom that can seriously affect the physical, psychological, and social well-being of affected individuals.

There are many types and causes of urinary incontinence. A common type of incontinence is **stress urinary incontinence** (strĕs YŪR-ĭ-nĕr-ē ĭn-KŎN-tĭ-nĕns), a leakage of urine during moments of physical activity that increases abdominal pressure, such as coughing, sneezing, laughing, or exercise.¹³

Overactive bladder is another type of incontinence where there is a frequent and sudden urge to urinate that can result in the individual not being able to make it to the restroom in time.

Diagnostic testing may be performed, such as a urinalysis to check for a urinary tract infection or urodynamic flow testing to evaluate bladder

version. National Institutes of Health. https://www.cancer.gov/types/kidney/patient/kidney-treatment-pdq#_1

13. McClurg, D., Pollock, A., Campbell, P., Hazelton, C., Elders, A., Hagen, S., & Hill, D. C. (2016). Conservative interventions for urinary incontinence in women: An overview of Cochrane systematic reviews. *The Cochrane Database of Systematic Reviews*, 2016(9). <https://doi.org/10.1002/14651858.CD012337>

function, including filling, urine storage, and emptying.¹⁴ Treatment of incontinence is based on the cause of incontinence and may include pelvic floor exercises, medications, or surgery.

URINARY RETENTION

Urinary retention (YŪR-ĭ-nĕr-ē rĭ-TĚN-shŭn) is a condition that occurs when the patient cannot empty all of the urine from the bladder. Urinary retention can be acute (i.e., the sudden inability to urinate after receiving anesthesia during surgery) or chronic (i.e., a gradual inability to completely empty the bladder due to enlargement of the prostate gland in males). Urinary retention is caused by a blockage that prevents the flow of urine or the bladder not being able to create a strong enough force to expel all the urine. In addition to causing discomfort, urinary retention increases the patient's risk for developing a urinary tract infection (UTI) or other complications. See Figure 5.14¹⁵ for an image of an enlarged prostate gland blocking the flow of urine from the bladder into the urethra.

14. Tso, C. (2018, January 10). Postmenopausal women and urinary incontinence. *American Nurse*. <https://www.myamericannurse.com/postmenopausal-women-urinary-incontinence/>

15. “Normal-vs-enlarged-prostate.jpg” by Akcmdu9 is licensed under [CC BY-SA 3.0](#)

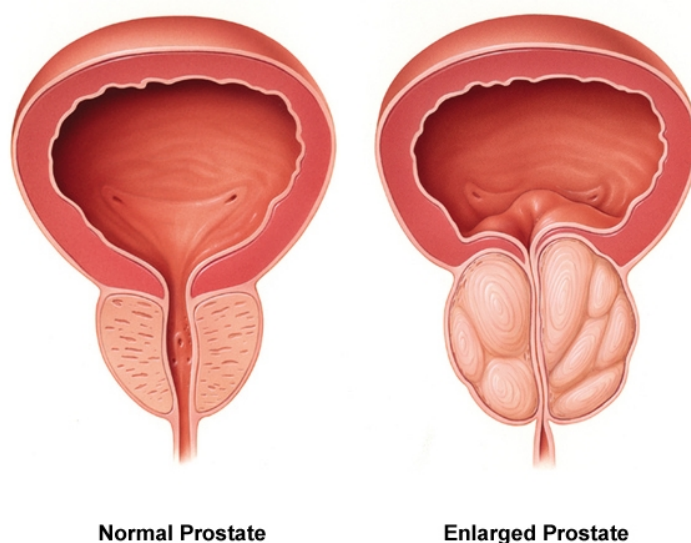


Figure 5.14 Enlarged Prostate Gland

Symptoms of urinary retention can range from no symptoms to severe abdominal pain.¹⁶ Health care providers use a patient's medical history, physical exam findings, and diagnostic tests to determine the cause of urinary retention. **Post-void residual** (pōst voyd rī-ZĪD-ū-ăl) measurements can be taken when urinary retention is suspected by using a bladder scanner or inserting a catheter to determine how much urine is left in the bladder.¹⁷

Treatment for urinary retention depends on the cause. It may include urinary catheterization to drain the bladder, bladder training therapy,

16. National Institute of Diabetes and Digestive and Kidney Diseases. (n.d.). *Urinary retention*. National Institutes of Health. <https://www.niddk.nih.gov/health-information/urologic-diseases/urinary-retention>

17. National Institute of Diabetes and Digestive and Kidney Diseases. (n.d.). *Urinary retention*. National Institutes of Health. <https://www.niddk.nih.gov/health-information/urologic-diseases/urinary-retention>

medications, or surgery.¹⁸ A surgery called **transurethral resection of the prostate** (trăns-yū-RĒ-thrāl rĭ-SĚK-shŭn ăv thĕ PRŌS-tāt) (**TURP**) may be performed in males to treat urinary retention caused by an enlarged prostate that is not responsive to medication.

URINARY TRACT INFECTION

A **urinary tract infection** (YŪR-ĭ-nĕr-ĕ trăkt ĭn-FĚK-shŭn) (**UTI**) is a common infection that occurs when bacteria, typically from the rectum, enter the urethra and infect the urinary tract. Infections can affect several parts of the urinary tract, but the most common type is a bladder infection, referred to as **cystitis** (sĭs-TĪ-tĭs). Kidney infections, referred to as **pyelonephritis** (pĭ-ĕl-ō-nĕ-FRĪ-tĭs), are more serious infections because they can have long-lasting effects on the kidneys.¹⁹

Some people are at higher risk of getting a UTI. UTIs are more common in females because their urethras are shorter and closer to the rectum, which makes it easier for bacteria to enter the urinary tract. Other factors that can increase the risk of UTIs include the following²⁰:

18. National Institute of Diabetes and Digestive and Kidney Diseases. (n.d.). *Urinary retention*. National Institutes of Health. <https://www.niddk.nih.gov/health-information/urologic-diseases/urinary-retention>
19. Centers for Disease Control and Prevention. (2021, October 6). *Urinary tract infection*. <https://www.cdc.gov/antibiotic-use/community/for-patients/common-illnesses/uti.html>
20. Centers for Disease Control and Prevention. (2021, October 6). *Urinary tract infection*. <https://www.cdc.gov/antibiotic-use/community/for-patients/common-illnesses/uti.html>

- A previous UTI
- Sexual activity, especially with a new sexual partner
- Pregnancy
- Age (Older adults and young children are at higher risk.)
- Structural problems in the urinary tract, such as prostate enlargement
- Dehydration
- Uncontrolled diabetes

Symptoms of a UTI include the following²¹:

- Pain or burning while urinating (dysuria)
- Frequent urination (frequency)
- Urgency with small amounts of urine (oliguria)
- Bloody urine (hematuria)
- Pressure or cramping in the groin or lower abdomen
- Confusion or altered mental status in older adults

Symptoms of pyelonephritis include fever above 101 degrees F (38.3 degrees C), shaking chills, lower back pain or flank pain (i.e., on the sides of the back), and nausea or vomiting.²² Older adults with a UTI may not exhibit these symptoms but often demonstrate an increased level of confusion. In some cases, UTIs can spread to the blood, leading to life-threatening infection called sepsis. **Sepsis** (SĔP-sīs) occurs when the body's infection-fighting processes work improperly and damage the organs. Sepsis may progress to septic shock, a dramatic drop in blood pressure that can damage the lungs, kidneys,

21. Centers for Disease Control and Prevention. (2021, October 6). *Urinary tract infection*. <https://www.cdc.gov/antibiotic-use/community/for-patients/common-illnesses/uti.html>

22. Centers for Disease Control and Prevention. (2021, October 6). *Urinary tract infection*. <https://www.cdc.gov/antibiotic-use/community/for-patients/common-illnesses/uti.html>

liver, and other organs. When the damage is severe, it can lead to death. Early treatment of sepsis improves chances for survival.²³

When a patient presents with symptoms of a UTI, the health care provider orders diagnostic tests that may include a urine dip, urinalysis, or urine culture & sensitivity. Read more about diagnostic tests in the “[Medical Specialists, Diagnostic Testing, and Procedures Related to the Urinary System](#)” section. Antibiotics are prescribed for urinary tract infections, and health teaching is provided to prevent future UTIs. Patients are also encouraged to drink extra fluids to help flush bacteria from the urinary tract.

23. Mayo Clinic. (2023). *Sepsis*. <https://www.mayoclinic.org/diseases-conditions/sepsis/symptoms-causes/syc-20351214>

5.7 Medical Specialists, Diagnostic Testing, and Procedures Related to the Urinary System

MEDICAL SPECIALISTS

Nephrology (něf-RŎL-ŏ-jē) is the study of kidney diseases. A **nephrologist** (něf-RŎL-ŏ-jĭst) is a physician who specializes in diagnosing and treating kidney conditions. **Urology** (yū-RŎL-ŏ-jē) is the study of male and female urinary systems as well as the male reproductive system. A **urologist** (yū-RŎL-ŏ-jĭst) is a specialist who diagnoses and treats urinary system conditions, disorders, and diseases.

▶ To learn more about urology, visit the [Why Urology?](#) by the American Urological Association.

DIAGNOSTIC TESTS

Common diagnostic tests related to the urinary system are described in this

section. Diagnostic tests performed for specific medical conditions are discussed in the “[Diseases and Disorders of the Urinary System](#)” section.

Blood Tests

Blood Urea Nitrogen (BUN)

Urea nitrogen is a waste product made when the liver breaks down protein. Urea is carried in the blood, filtered out by the kidneys, and removed from the body in urine. A diagnostic test called **blood urea nitrogen** (blŭd yŭ-rē-ă nī-trŏ-jĕn) (**BUN**) provides important information about kidney and liver function. If the liver is unhealthy, it may not break down proteins the way it should, and if the kidneys aren't healthy, they may not correctly filter urea. Either of these problems can lead to an increased amount of urea nitrogen in the blood. Additionally, dehydration (not enough fluid in the body) can cause higher levels of urea in the blood because not much urine is being created.

Creatinine

A **creatinine** (krē-ĀT-ĭ-nĕn) test is used to determine if the kidneys are working normally. Creatinine is a waste product made by muscles as part of regular, everyday activity. Healthy kidneys filter creatinine from the blood and eliminate it in the urine. However, if there is a problem with kidney functioning, creatinine can build up in the blood and less will be released in urine. If creatinine levels in the blood and/or urine are not in normal range, it can be a sign of kidney disease.

Glomerular Filtration Rate

Glomerular filtration rate (GFR) is one of the most common blood tests to check for kidney disease and to determine how well the nephrons are filtering creatinine. People make different amounts of creatinine, depending on their age, gender, height, weight, diet, and activity levels, so a formula is

used to calculate their estimated GFR (eGFR). Lower than normal eGFR levels indicate kidney disease, and very low levels indicate kidney failure.¹

Urine Tests

Urine Dip

A **urine dip** (yū-rēn dīp) test refers to a treated chemical strip (dipstick) being placed in a person's urine sample. Patches on the dipstick change color to indicate the presence of substances such as white blood cells, red blood cells, protein, or glucose. See Figure 5.15² for an image of a urine dipstick test. Urine is collected for a urine dip test in a clean specimen container. Using the “clean catch” technique, the skin surrounding the urethra is cleaned with a special towelette before the urine is collected.

1. MedlinePlus [Internet]. Bethesda (MD): National Library of Medicine (US); [updated 2023, July 6]. Glomerular Filtration Rate (GFR) Test; [cited 2023, Oct 12]. <https://medlineplus.gov/lab-tests/glomerular-filtration-rate-gfr-test/>

2. “Chemstrip2.jpg” by J3D3 is licensed under [CC BY-SA 3.0](#)

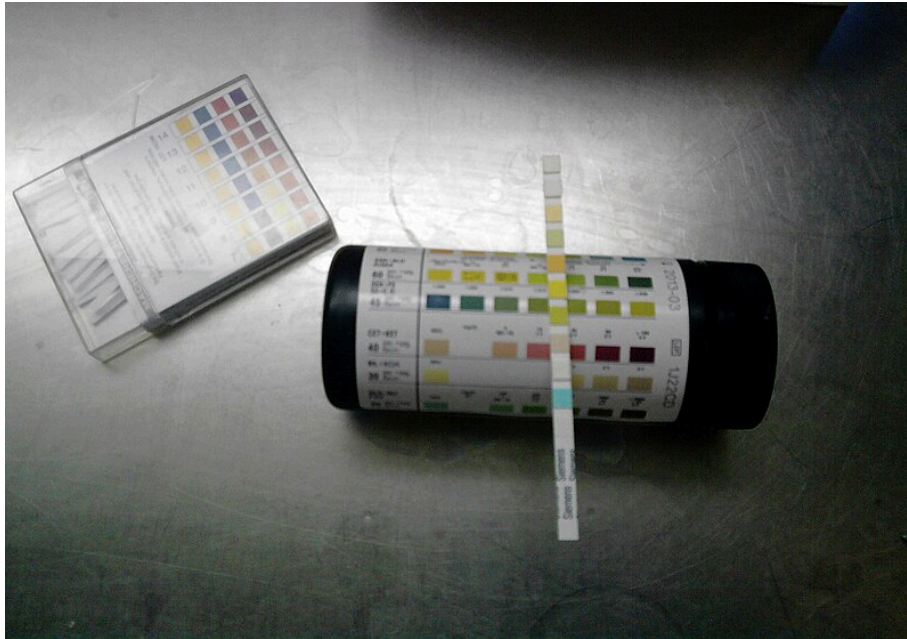

Figure 5.15 Urine Dipstick Test

Urinalysis

A **urinalysis** (yūr-ĭ-NĀL-ĭ-sĭs) (**UA**) includes a physical, chemical, and microscopic examination of urine by a lab technician. It requires collection of a “clean catch” urine sample in a sterile container. It involves analyzing the urine with a microscope for the following³:

- Color
- Appearance (i.e., clear or cloudy)
- Odor
- pH level (acidity)
- Specific gravity (concentration of all particles in the urine)
- Substances not usually found in significant amounts in the urine, such as

3. MedlinePlus [Internet]. Bethesda (MD): National Library of Medicine (US); [updated 2016, May 5]. Urinalysis; [cited 2023, Oct 12]. <https://medlineplus.gov/urinalysis.html>

red blood cells, white blood cells, leukocyte esterase, bacteria, protein, glucose, ketones, and bilirubin

- Cells, crystals, and casts

Urine Culture and Sensitivity

Urine culture and sensitivity (yū-rēn KŮL-chŭr ānd sēn-sĭ-TĪV-ĭ-tē) **(C&S)**

detects and identifies the number and type of bacteria growing in urine that can indicate a urinary tract infection (UTI). If pathogenic bacteria are found, a sensitivity report is generated that lists antibiotics to which the bacteria are sensitive to for treatment. A culture that is reported as “no growth in 24 or 48 hours” usually indicates that there is no infection. If a culture shows growth of several different types of bacteria, then it is likely due to contamination of the urine sample during collection, and a new collection of urine may be required.⁴

24-Hour Urine Collection

During a **24-hour urine collection test** (twehn-tee fôr hour yŭ-rēn kŏ-lĕk-shŭn tĕst), all urinary output from an individual is collected over a 24-hour period of time and analyzed for protein, creatinine, and other substances to evaluate kidney function.

Other Diagnostic Tests

Bladder Scan

A **bladder scan** (blăd-ēr skăn) uses a portable, noninvasive medical device that uses sound waves to calculate the amount of urine in a patient’s bladder.

4. LabTestsOnline.org. (2022, September 29). *Urine culture test*.

<https://labtestsonline.org/tests/urine-culture>

Nurses use bladder scanners at patients' bedsides to determine post-void residual urine amounts without the need to perform urinary catheterization.

CT Scan of Kidney

A **computed tomography scan of the kidney** (kŏm-PYŌŌ-těd tŏ-mŏg-ră-fē skăn ăv thē kĭd-nē) (**CT**) is a diagnostic imaging procedure that uses a combination of X-rays and computer technology to produce a variety of images. It provides detailed images of the kidney looking for disease, cancer, obstructions, and other kidney conditions.⁵

Intravenous Pyelogram (IVP)

An **intravenous pyelogram** (ĭn-tră-vē-nŭs Pĭ-ě-lŏ-gram) (**IVP**) is a special X-ray exam of the kidneys, bladder, and ureters. An iodine-based contrast (dye) is administered intravenously (into a vein). A series of X-ray images are taken at different times to see how the kidneys remove the dye and collect the urine. Before the final image is taken, the patient is asked to urinate again to see how well the bladder has emptied.⁶

Kidney, Ureter, and Bladder X-ray

A kidney, ureter, and bladder X-ray, often abbreviated KUB, is used to visualize these structures in the urinary system.

5. Johns Hopkins Medicine. (n.d.). *Computed tomography (CT or CT scan) of the kidney*. <https://www.hopkinsmedicine.org/health/treatment-tests-and-therapies/ct-scan-of-the-kidney>

6. A.D.A.M. Medical Encyclopedia [Internet]. Atlanta (GA): A.D.A.M., Inc.; c1997-2023. Intravenous pyelogram; [reviewed 2023, Jan 1; cited 2023, Oct 12]. <https://medlineplus.gov/ency/article/003782.htm>

Urodynamic Flow Test

Urodynamic flow testing (yū-rō-dī-NĀM-ĭk flō tēs-tĭng) is a procedure that looks at how well the bladder, sphincters, and urethra are storing and releasing urine. Most urodynamic tests focus on the bladder's ability to hold urine and empty steadily and completely. Urodynamic tests can also show whether the bladder is having involuntary contractions that cause urine leakage.⁷

Voiding Cystourethrogram

A **voiding cystourethrogram** (VOY-dĭng SĭS-tō-ūr-ĒTH-rō-gram) (**VCUG**) uses X-ray technology called fluoroscopy to visualize the urinary tract and bladder to examine the size, shape, and direction of urine flow. A thin, flexible tube called a catheter is inserted into the urethra and passed into the bladder. Contrast dye flows through the catheter into the bladder. X-rays are taken from various angles while the bladder is full of contrast dye, and then the catheter is removed, and X-rays are taken as the patient empties their bladder.⁸

7. National Institute of Diabetes and Digestive and Kidney Diseases. (2021, September). *Urodynamic testing*. National Institutes of Health.
<https://www.niddk.nih.gov/health-information/diagnostic-tests/urodynamic-testing>

8. A.D.A.M. Medical Encyclopedia [Internet]. Atlanta (GA): A.D.A.M., Inc.; c1997-2021. Voiding cystourethrogram; [updated 2023, Jan 1 cited 2023, Oct 12].
<https://medlineplus.gov/ency/article/003784.htm>

Procedures and Surgeries

Cystoscopy

Cystoscopy (sĭs-TŌS-kŏ-pē) is a procedure performed by a urologist who uses a cystoscope to look inside the urethra and bladder. A cystoscope is a long, thin optical instrument with an eyepiece at one end, a rigid or flexible tube in the middle, and a tiny lens and light at the other end of the tube. The urologist fills the bladder with fluid and looks at detailed images of the urethra and bladder on a computer monitor. During a cystoscopy, the urologist can see kidney stones, tumors, **stricture** (STRIK-chŭr) or a narrowing of the urethra, and other signs of blockage, such as an enlarged prostate gland.⁹ See Figure 5.16¹⁰ for an illustration of cystoscopy.

During a cystoscopy, a urologist may also perform treatments, such as removing a stone, taking a sample of the urethra or bladder tissue for a biopsy, injecting medicines into the bladder to treat urinary leakage, or remove abnormal tissue. The urologist may also perform **retrograde pyelography** (rě-trō-grād pī-ě-lō-gră-fē), an X-ray procedure where a special dye is injected into the urinary tract to create images of urinary flow to show obstructions such as kidney stones and tumors.¹¹

9. National Institute of Diabetes and Digestive and Kidney Disorders. (2021, July). *Cystoscopy & ureteroscopy*. National Institutes of Health.
<https://www.niddk.nih.gov/health-information/diagnostic-tests/cystoscopy-ureteroscopy>
10. “[Diagram showing a cystoscopy for a man and a woman CRUK_064.svg](#)” by Cancer Research UK is licensed under [CC BY-SA 4.0](#)
11. National Institute of Diabetes and Digestive and Kidney Disorders. (2021, July). *Cystoscopy & ureteroscopy*. National Institutes of Health.
<https://www.niddk.nih.gov/health-information/diagnostic-tests/cystoscopy-ureteroscopy>

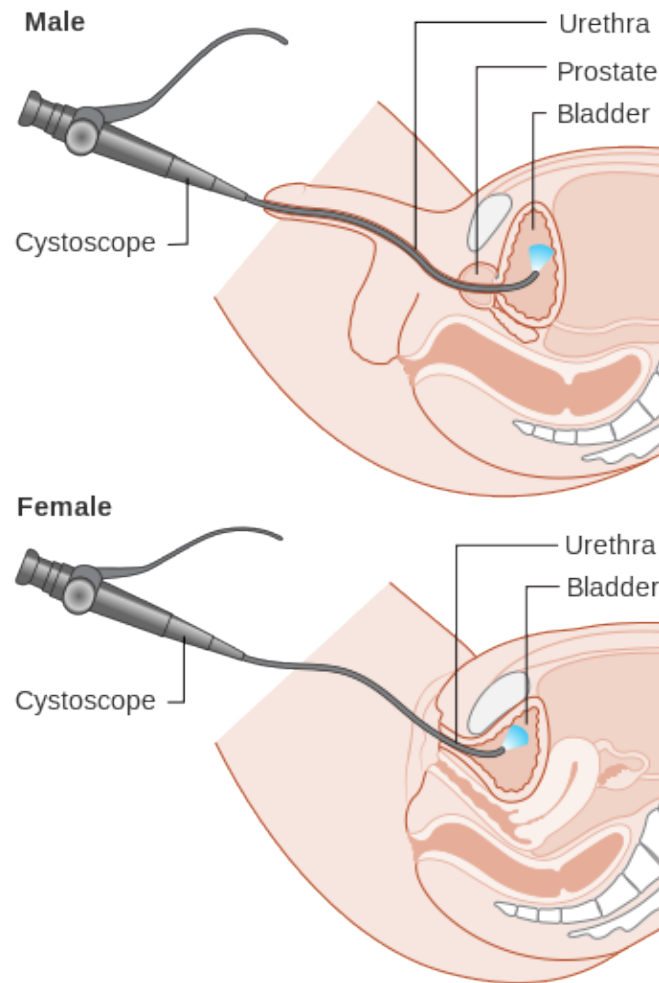


Figure 5.16 Cystoscopy

Dialysis

When kidney failure occurs, treatment is required to eliminate excess wastes, potassium, salt, and water. There are two types of dialysis: hemodialysis and peritoneal dialysis. **Hemodialysis** (hē-mō-dī-ĀL-ĭ-sĭs) uses a special machine that filters the blood. People who are not hospitalized go to a special dialysis clinic for hemodialysis treatments several times a week. **Peritoneal dialysis** (pěr-ĭ-tō-NĒ-ăl dī-ĀL-ĭ-sĭs) uses the lining of the abdomen, called the peritoneal membrane, to filter the blood. Peritoneal dialysis can be performed

in a person's home. See Figure 5.17¹² for an image of a patient undergoing hemodialysis.

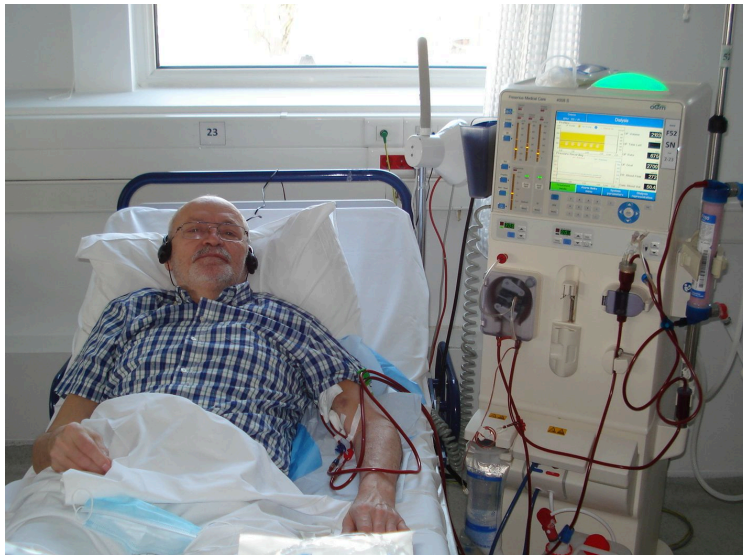

Figure 5.17 Hemodialysis

Kidney Transplantation

A **kidney transplant** (KĪD-nē TRĀNS-plānt), also referred to as **renal transplant** (RĒ-nāl TRĀNS-plānt), is a surgical procedure used for some patients in end-stage renal disease. During a transplant, the surgeon places the donated kidney in the lower abdomen and connects a renal artery and renal vein. The healthy donated kidney takes over the work of the two kidneys that failed, so dialysis is no longer needed. Often, the new kidney will start making urine as soon as blood starts flowing through it, but sometimes it takes a few weeks for it to start working. People who have received a kidney transplant must take immunosuppressive medications for the rest of their lives to keep their bodies from rejecting the new kidney.¹³

¹². “Dializa-02-2021.jpg” by [Mishu57](#) is licensed under [CC BY-SA 4.0](#)

¹³. MedlinePlus [Internet]. Bethesda (MD): National Library of Medicine (US);

Ureteroscopy

Ureteroscopy (yū-rě-těr-ŎS-kŏ-pē) is a procedure that uses a ureteroscope to look inside the ureters and kidneys. Like a cystoscope, a ureteroscope has an eyepiece at one end, a rigid or flexible tube in the middle, and a tiny lens and light at the other end of the tube. However, a ureteroscope is longer and thinner than a cystoscope so the urologist can see detailed images of the lining of the ureters and kidneys.¹⁴

Urinary Catheterization

Urinary catheterization (YŪR-ĭ-něr-ē kăth-ĭ-těr-ĭ-ZĀ-shŭn) is the insertion of a catheter tube into a person's urethra and then into their bladder to drain urine. This procedure is commonly performed by nurses. Catheterization may include an indwelling catheter or intermittent catheterization.

An **indwelling catheter** (ĭn-DWĔL-ĭng KĀTH-ĭ-těr), often referred to as a "Foley catheter," refers to a urinary catheter that remains in place after insertion into the bladder for the continual collection of urine. It has a balloon on the insertion tip to maintain placement in the neck of the bladder. The other end of the catheter is attached to a drainage bag for the collection of urine. See Figure 5.18¹⁵ for an illustration of a urine collection bag connected to an indwelling catheter as the patient is lying in bed.

[updated 2016, Apr 13]. Kidney Transplantation; [cited 2023, Oct 12]. <https://medlineplus.gov/kidneytransplantation.html>

14. National Institute of Diabetes and Digestive and Kidney Disorders. (2021, July). *Cystoscopy & ureteroscopy*. National Institutes of Health. <https://www.niddk.nih.gov/health-information/diagnostic-tests/cystoscopy-ureteroscopy>

15. "Closed Urinary Drainage.png" by BruceBlaus is licensed under [CC BY-SA 4.0](https://creativecommons.org/licenses/by-sa/4.0/)

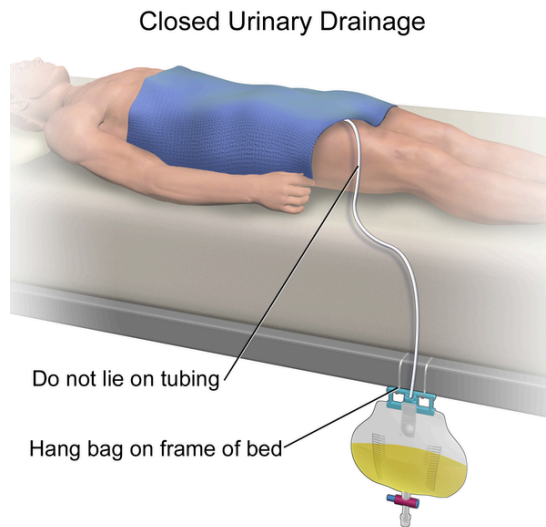


Figure 5.18 Placement of Urine Collection Bag

Intermittent catheterization (in-tĕr-MĪT-ĕnt KĀTH-ĕ-tĕr-ĭ-ZĀ-shŭn) is used for the relief of urinary retention. It may be performed once, such as after surgery when a patient is experiencing urinary retention due to the effects of anesthesia or performed several times a day to manage chronic urinary retention. A straight catheter is used for intermittent urinary catheterization. The catheter is inserted into the urethra and bladder to allow for the flow of urine and then immediately removed, so a balloon is not required at the insertion tip.¹⁶ See Figure 5.19¹⁷ for an image of a straight catheter.

¹⁶. Centers for Disease Control and Prevention. (2015, November 15). *Catheter-associated urinary tract infections (CAUTI)*. <https://www.cdc.gov/infectioncontrol/guidelines/cauti/>

¹⁷. “[Urinary catheter.JPG](#)” by [Bengt Oberger](#) is licensed under [CC BY-SA 3.0](#)




Figure 5.19 Straight Catheter

5.8 Urinary System Learning Activities

Interactive Learning Activity: Label the anatomy of the urinary system using this drag and drop activity.



An interactive H5P element has been excluded from this version of the text. You can view it online here:

<https://wtcs.pressbooks.pub/medterm/?p=3453#h5p-137>

Interactive Learning Activity: Study urinary system medical terms discussed in this chapter using these flashcards.



An interactive H5P element has been excluded from this version of the text. You can view it online here:

<https://wtcs.pressbooks.pub/medterm/?p=3453#h5p-174>

Interactive Learning Activity: Test your knowledge of the urinary system by completing this activity.



An interactive H5P element has been excluded from this version of the text. You can view it online here:

<https://wtcs.pressbooks.pub/medterm/?p=3453#h5p-142>

Interactive Learning Activity: Using the sample documentation provided, drag the terms on the right to their appropriate spaces within the documentation.



An interactive H5P element has been excluded from this version of the text. You can view it online here:

<https://wtcs.pressbooks.pub/medterm/?p=3453#h5p-140>

Interactive Learning Activity: Using the sample documentation provided, drag the terms on the right to their appropriate spaces within the documentation.



An interactive H5P element has been excluded from this version of the text. You can view it online here:

<https://wtcs.pressbooks.pub/medterm/?p=3453#h5p-141>



Interactive Learning Activity: Practice identifying and defining word parts for terms discussed in this chapter:



An interactive H5P element has been excluded from this version of the text. You can view it online here:

<https://wtcs.pressbooks.pub/medterm/?p=3453#h5p-197>

- ▶ You can also print this as a [Chapter 5 Practice Worksheet](#) and check your answers with this [Answer Key PDF](#).

5.9 Glossary

24-hour urine collection test (twehn-tee fôr hour yŭ-rĕn kŏ-lĕk-shŭn tĕst): A diagnostic procedure where all urine output is collected over a 24-hour period to analyze components such as protein, creatinine, and other substances for evaluating kidney function. ([Chapter 5.7](#))

Acute kidney failure (ā-kŭt kĭd-nĕ fāl-yŭr) (ARF): A rapid loss of kidney function, often within 2 days, due to various causes such as decreased blood flow to the kidneys, infections, and blockages. ([Chapter 5.6](#))

Anuria (ă-NOOR-ĕ-ă): The absence of urine output, often seen in severe kidney failure, defined as less than 50 mL of urine over a 24-hour period. ([Chapter 5.5](#))

Bladder (blăd-ĕr): A muscular sac in the pelvis that stores urine from the kidneys before it is expelled from the body. ([Chapter 5.4](#))

Bladder scan (blăd-ĕr skăn): A non-invasive, portable medical device using ultrasound technology to estimate the volume of urine in the bladder. ([Chapter 5.7](#))

Blood urea nitrogen (blŭd yŭ-rĕ-ă nĭ-trŏ-jĕn) (BUN): A laboratory test measuring the amount of urea nitrogen in the blood, providing information about kidney and liver function. ([Chapter 5.7](#))

Chronic kidney disease (KRŎN-ĭk kĭd-nĕ dĭ-ZĒZ) (CKD): A long-term condition where the kidneys progressively lose their ability to filter and eliminate waste products and excess fluids from the body. ([Chapter 5.6](#))

Computed tomography scan of the kidney (kŏm-PYŎŎ-tĕd tŏ-mŏg-ră-fĕ skăn ăv thĕ kĭd-nĕ) (CT): An imaging procedure using X-rays and computer technology to create detailed images of the kidneys. ([Chapter 5.7](#))

Creatinine (krĕ-ĂT-ĭ-nĕn): A waste product from muscle metabolism, normally filtered by the kidneys and excreted in urine, used to measure kidney function. ([Chapter 5.7](#))

Cystitis (sĭs-Tĭ-tĭs): Inflammation of the bladder, usually due to a urinary tract infection, causing symptoms like pain and increased urge to urinate. ([Chapter 5.6](#))

Cystoscopy (sīs-TŌS-kŏ-pē): A diagnostic procedure where a cystoscope is used to visually examine the interior of the bladder and urethra. ([Chapter 5.7](#))

Deamination (dē-am-ĭ-NĀ-shŏn): The removal of an amino group from an amino acid or other compound, which occurs in the liver and forms ammonia and urea. ([Chapter 5.5](#))

Distended (dīs-TĒN-dĕd): Stretched out or enlarged, often used to describe the bladder or abdomen when filled with fluid or gas. ([Chapter 5.4](#))

Diuresis (dī-ū-RĒ-sīs): Increased or excessive production of urine, which can occur in various medical conditions. ([Chapter 5.5](#))

Diuretic (dī-ū-RĒT-ĭk): A substance or medication that increases the production and excretion of urine, used to treat conditions like high blood pressure. ([Chapter 5.5](#))

Dysuria (dīs-ŪR-ē-ă): Painful or difficult urination, often a symptom of urinary tract infections or other urological conditions. ([Chapter 5.5](#))

Edema (ĭ-DE-mă): Swelling caused by excess fluid trapped in the body's tissues, often seen in kidney or heart disease. ([Chapter 5.5](#))

End-stage renal disease (ĕnd-stāj rē-nāl dī-ZĒZ) (ESRD): The final phase of chronic kidney disease where the kidneys can no longer meet the body's needs, requiring dialysis or transplantation. ([Chapter 5.6](#))

Enuresis (ĕn-ū-RĒ-sīs): Involuntary urination, especially common among children during the night (nocturnal enuresis). ([Chapter 5.5](#))

Frequency (FRĒ-kwĕn-sē): The need to urinate more often than usual, a symptom often associated with urinary tract infections or bladder conditions. ([Chapter 5.5](#))

Glomerular filtration (glō-MER-yū-lăr fĭl-TRĀ-shŭn): The process in the kidneys where blood plasma is filtered through the glomeruli, allowing waste products and excess substances to be excreted while retaining necessary components. ([Chapter 5.5](#))

Glomerular filtration rate (glō-MER-yū-lăr fĭl-TRĀ-shŭn rāt) (GFR): A measure of how well the kidneys filter waste from the blood, used as an indicator of kidney function. ([Chapter 5.5](#))

Glomerulonephritis (glō-mĕr-ū-lŏ-nĕ-FRĭ-tīs): An inflammation of the glomeruli in the kidneys, affecting their ability to filter blood properly, often leading to kidney damage. ([Chapter 5.6](#))

Glomerulus (glō-MER-yū-lŭs): A network of tiny blood vessels in the kidneys that are involved in the filtration process to form urine. ([Chapter 5.4](#))

Hematuria (hē-mă-TŪR-ē-ă): The presence of blood in the urine, which can be a sign of various urinary tract or kidney conditions. ([Chapter 5.5](#))

Hemodialysis (hē-mō-dī-ĀL-ī-sīs): A medical procedure where a machine filters waste and excess fluids from the blood, used in cases of kidney failure. ([Chapter 5.7](#))

Hydronephrosis (hī-drō-ně-FRŌ-sīs): Swelling of a kidney due to a build-up of urine, often caused by obstruction in the urinary tract. ([Chapter 5.6](#))

Hydrostatic (hī-drō-STAT-ik): Pertaining to the pressure exerted by a fluid at rest. ([Chapter 5.5](#))

Hyperkalemia (hī-pěr-kă-LĒM-ē-ă): An abnormally high level of potassium in the blood, which can occur in kidney disease or from other causes. ([Chapter 5.5](#))

Incontinence (ĭn-KŌN-tĭ-něns): The inability to control urination or defecation, leading to involuntary loss of urine or feces. ([Chapter 5.4](#))

Indwelling catheter (ĭn-DWĒL-ĭng KĀTH-ĭ-těr): A type of urinary catheter that remains inside the bladder for continuous urine drainage. ([Chapter 5.7](#))

Intermittent catheterization (ĭn-těr-MĪT-ěnt KĀTH-ě-těr-ĭ-ZĀ-shŭn): A method of urinary catheterization where a catheter is temporarily inserted into the bladder to drain urine and then removed. ([Chapter 5.7](#))

Intravenous pyelogram (ĭn-tră-vē-nŭs PĪ-ě-lŏ-gram) (IVP): An imaging test where a contrast dye is injected into a vein and X-rays are taken to visualize the kidneys, ureters, and bladder. ([Chapter 5.7](#))

Kidneys (KĪD-nēz): A pair of organs in the urinary system responsible for filtering waste products and excess substances from the blood to form urine. ([Chapter 5.4](#))

Kidney transplant (KĪD-nē TRĀNS-plănt): A surgical procedure to replace a diseased kidney with a healthy one from a donor. ([Chapter 5.7](#))

Lithotripsy (LĪTH-ŏ-trĭp-sē): A medical procedure that uses shock waves or other means to break up stones in the kidney, bladder, or ureters. ([Chapter 5.6](#))

Micturate (MĪK-tū-răt): To urinate or pass urine. ([Chapter 5.4](#))

Nephrolithiasis (něf-rō-lī-THĪ-ă-sīs): The presence of stones (calculi) in the kidney. ([Chapter 5.6](#))

Nephrolithotomy (něf-rō-lī-THŎT-ŏ-mē): A surgical procedure to remove stones from the kidney. ([Chapter 5.6](#))

Nephrologist (ně-FRŎL-ŏ-jĭst): A physician who specializes in the diagnosis and treatment of kidney diseases. Nephrologists manage various conditions related to kidney function, including chronic kidney disease, kidney infections, kidney stones, and hypertension related to kidney problems. ([Chapter 5.7](#))

Nephrology (něf-RŎL-ŏ-jē): Study of the physiology and diseases of the kidneys. ([Chapter 5.7](#))

Nephron (NĚF-rŏn): The functional unit of the kidney, responsible for filtering and excreting waste products from the blood. ([Chapter 5.4](#))

Nephroscope (NĚF-rŏ-skōp): An instrument used in surgery to visualize the interior of the kidney, particularly in procedures involving kidney stones. ([Chapter 5.6](#))

Nocturia (nŏk-TŪR-ē-ă): The need to wake up and urinate frequently during the night. ([Chapter 5.5](#))

Oliguria (ŏ-lī-GŪR-ē-ă): The production of abnormally small amounts of urine, often indicative of kidney dysfunction or dehydration. ([Chapter 5.5](#))

Oncotic pressure (ŏn-KŎT-ĭk PRĚSH-ŭr): The form of osmotic pressure exerted by proteins, particularly albumin, in the blood plasma or other solutions. ([Chapter 5.5](#))

Osmosis (ŏz-MŎ-sīs): The movement of water molecules through a semipermeable membrane from a region of lower solute concentration to a region of higher solute concentration. ([Chapter 5.5](#))

Partial nephrectomy (pär-shŭl něf-RĚK-tŏ-mē): A surgical procedure to remove a portion of the kidney, typically done to treat kidney cancer while preserving kidney function. ([Chapter 5.6](#))

Peritoneal dialysis (pěr-ĭ-tŏ-NĚ-ăl dĭ-ĀL-ĭ-sīs): A form of dialysis where the lining of the abdomen (peritoneum) acts as a filter to remove waste from the blood when the kidneys are not functioning properly. ([Chapter 5.7](#))

Polycystic kidney disease (pŏl-ē-SĪS-tĭk KĪD-nē dĭ-ZĚZ) (PKD): A genetic disorder characterized by the growth of numerous cysts in the kidneys, often leading to kidney failure. ([Chapter 5.6](#))

Polyuria (pöl-ē-ŪR-ē-ă): The production of abnormally large volumes of dilute urine, often a symptom of conditions like diabetes. ([Chapter 5.5](#))

Post-void residual (pōst voyd ři-ZĪD-ŭ-ăl): The amount of urine remaining in the bladder after urination, as measured for diagnostic purposes. ([Chapter 5.6](#))

Pyelonephritis (pī-ěl-ō-ně-FRĪ-tīs): A type of urinary tract infection where one or both kidneys become infected and inflamed. ([Chapter 5.6](#))

Pyuria (pī-ŪR-ē-ă): The presence of white blood cells in the urine, indicating an infection in the urinary tract. ([Chapter 5.5](#))

Radical nephrectomy (răd-ĭ-kăl něf-RĚK-tŏ-mē): A surgical procedure to remove the entire kidney, along with the adrenal gland, surrounding tissue, and often nearby lymph nodes, usually for cancer treatment. ([Chapter 5.6](#))

Renal (RĚ-năl): Pertaining to the kidneys. ([Chapter 5.4](#))

Renal calculus (RĚ-năl KĀL-kŭ-lŭs): Another term for a kidney stone. ([Chapter 5.6](#))

Renal transplant (RĚ-năl TRĀNS-plănt): Surgical procedure to place a functioning kidney from a donor into a person with end-stage renal disease. ([Chapter 5.7](#))

Retrograde pyelography (rě-trō-grād pī-ě-lŏ-gră-fē): A type of X-ray examination of the upper urinary tract, including the kidneys and ureters, typically performed during a cystoscopy. ([Chapter 5.7](#))

Sepsis (SĚP-sīs): A life-threatening condition that arises when the body's response to an infection causes injury to its own tissues and organs. Sepsis can lead to significant health complications or death, especially if not recognized early and treated promptly. It often presents with fever, increased heart rate, increased breathing rate, and confusion. ([Chapter 5.6](#))

Simple nephrectomy (sĭm-pĭl něf-RĚK-tŏ-mē): A surgical procedure to remove a kidney, typically for conditions like severe damage or cancer. ([Chapter 5.6](#))

Sphincters (SFĪNK-těrz): Circular muscles that constrict and close a natural body passage; in the urinary system, they control the release of urine from the bladder. ([Chapter 5.4](#))

Stress urinary incontinence (strēs YŪR-ĭ-něr-ē ĭn-KŌN-tĭ-něns): Involuntary

leakage of urine during activities that increase abdominal pressure, such as coughing, sneezing, or exercising. ([Chapter 5.6](#))

Stricture (STRIK-chŭr): A narrowing of a tube or passage in the body, such as the urethra, often leading to restricted flow of fluids like urine. ([Chapter 5.7](#))

Transurethral resection of the prostate (trăns-yŭ-RĒ-thrăl rĭ-SĚK-shŭn ăv thĕ PRŌS-tăt) (TURP): A surgical procedure to remove part of the prostate gland to treat urinary problems. ([Chapter 5.6](#))

Urea (yŭ-RĒ-ă): A nitrogenous compound produced in the liver as a waste product from the breakdown of proteins, excreted in the urine. ([Chapter 5.5](#))

Ureter (YŪR-ĕ-tĕr): A tube that carries urine from the kidney to the urinary bladder. ([Chapter 5.4](#))

Ureteroscopy (yŭ-rĕ-tĕr-ŎS-kŏ-pĕ): A procedure using a ureteroscope to examine or treat disorders of the urinary tract, especially the ureters and kidneys. ([Chapter 5.7](#))

Urethra (yŭ-RĒ-thră): The tube that carries urine from the bladder to the outside of the body. ([Chapter 5.4](#))

Urgency (ŬR-jĕn-sĕ): A sudden, compelling need to urinate, often a symptom of urinary tract infections or overactive bladder. ([Chapter 5.5](#))

Urinal (ŬR-ĭn-ăl): A receptacle or device for collecting urine, especially in healthcare settings. ([Chapter 5.5](#))

Urinalysis (yŭr-ĭ-NĂL-ĭ-sĭs) (UA): A test of the urine involving physical, chemical, and microscopic examination to detect disorders or diseases. ([Chapter 5.7](#))

Urinary (YŪR-ĭ-nĕr-ĕ): Relating to urine or the organs of the urinary system. ([Chapter 5.4](#))

Urinary catheterization (YŪR-ĭ-nĕr-ĕ kăth-ĭ-tĕr-ĭ-ZĂ-shŭn): The process of inserting a catheter into the bladder through the urethra for the purpose of draining urine. ([Chapter 5.7](#))

Urinary incontinence (YŪR-ĭ-nĕr-ĕ ĭn-KŎN-tĭ-nĕns): The inability to control urination, resulting in involuntary leakage of urine. ([Chapter 5.6](#))

Urinary retention (YŪR-ĭ-nĕr-ĕ rĭ-TĚN-shŭn): The inability to empty the bladder completely, resulting in accumulation of urine. ([Chapter 5.6](#))

Urinary tract (YŪR-ĭ-nĕr-ĕ trăkt): The system of organs that produce, store,

and eliminate urine, including the kidneys, ureters, bladder, and urethra. ([Chapter 5.4](#))

Urinary tract infection (YŪR-ĭ-nĕr-ē trăkt ĭn-FĚK-shŭn) (UTI): An infection in any part of the urinary system, most commonly the bladder and urethra. ([Chapter 5.6](#))

Urinate (YŪR-ĭ-nāt): The act of passing urine from the bladder to the outside of the body. ([Chapter 5.4](#))

Urine culture and sensitivity (yŭ-rĕn KŬL-chŭr ānd sĕn-sĭ-TĭV-ĭ-tĕ) (C&S): A laboratory test to identify the bacteria causing a urinary tract infection and determine the most effective antibiotics for treatment. ([Chapter 5.7](#))

Urine dip (yŭ-rĕn dĭp): A quick, initial screening test using a dipstick to detect abnormalities in urine, such as the presence of blood, protein, or signs of infection. ([Chapter 5.7](#))

Urodynamic flow testing (yŭ-rō-dĭ-NĀM-ĭk flō tĕs-tĭng): A series of diagnostic tests that assess the function of the bladder and urethra, specifically focusing on urine storage and release. ([Chapter 5.7](#))

Urologist (yŭ-RŎL-ŏ-jĭst): A physician who specializes in diagnosing and treating diseases and disorders of the urinary system and male reproductive organs. ([Chapter 5.7](#))

Urology (yŭ-RŎL-ŏ-jĕ): Study of the male and female urinary systems as well as the male reproductive system. ([Chapter 5.7](#))

Vesicoureteral reflux (vĕs-ĭ-kō-yŭ-RĚT-ĕr-āl rĕ-FLŬKS) (VUR): A condition where urine flows backward from the bladder into the ureters and sometimes the kidneys, potentially leading to kidney damage. ([Chapter 5.6](#))

Void (voyd): To empty the bladder; to urinate. ([Chapter 5.4](#))

Voiding cystourethrogram (VOY-dĭng SĭS-tō-ŭr-ĒTH-rō-gram) (VCUG): A medical imaging test used to examine the bladder and urethra while the bladder fills and empties. The test involves the insertion of a catheter into the bladder, through which a contrast dye is introduced, followed by X-ray imaging. VCUG is often used to diagnose issues like bladder and urethral dysfunction, vesicoureteral reflux, and urinary tract obstructions, especially in children. ([Chapter 5.7](#))

PART VI

CHAPTER 6 MALE REPRODUCTIVE SYSTEM TERMINOLOGY

6.1 Male Reproductive System Introduction

Learning Objectives

- Apply the rules of medical language to build, analyze, spell, pronounce, abbreviate, and define terms as they relate to the male reproductive system
- Identify meanings of key word components of the male reproductive system
- Categorize diagnostic, therapeutic, procedural, or anatomic terms related to the male reproductive system
- Use terms related to the male reproductive system
- Use terms related to the diseases and disorders of the male reproductive system


Introduction to the Male Reproductive System

The male reproductive system produces testosterone to maintain male reproductive function, create sperm, and promote transport of sperm into the female reproductive system for fertilization.¹

This chapter will review common word components related to the male

1. This work is a derivative of [StatPearls](#) by Gurung, Yetiskul, & Jialal and is licensed under [CC BY 4.0](#)

reproductive system to assist learning how to analyze, build, and define medical terms. Other male reproductive terms, whose definitions cannot be easily built from word components, will be described in context based on the anatomy and physiology of the male reproductive system and common diseases and disorders. Medical specialists, diagnostic tests, and procedures related to the male reproductive system will also be discussed.

View the following YouTube video² on the male
 reproductive system: [Reproductive System, Part 2 – Male Reproductive System: Crash Course A&P #41](https://youtu.be/-XQcnO4iX_U?si=CAHbdwnaGxQOMKP5)

2. CrashCourse. (2015, November 9). *Reproductive system, Part 2 – Male reproductive system: Crash Course Anatomy & Physiology #41* [Video]. YouTube. All rights reserved. https://youtu.be/-XQcnO4iX_U?si=CAHbdwnaGxQOMKP5

6.2 Word Components Related to the Male Reproductive System

This section will describe common word components related to the male reproductive system. These word components help build definitions for many medical terms. Other common prefixes are described in [Chapter 1.3](#), and common suffixes are described in [Chapter 1.5](#).

COMMON PREFIXES RELATED TO THE MALE REPRODUCTIVE SYSTEM

- **a-**: Absence of, without
- **an-**: Absence of, without
- **crypt-**: Hidden
- **dys-**: Painful, difficult
- **epi-**: Above
- **hyper-**: Above, excessive
- **hypo-**: Below
- **par-**: Near
- **trans-**: Through, across, beyond

COMMON WORD ROOTS WITH A COMBINING VOWEL RELATED TO THE

MALE REPRODUCTIVE SYSTEM

- **andr/o**: Male
- **balan/o**: Glans penis
- **epididym/o**: Epididymis
- **gonad/o**: Gonad
- **orch/o**: Testis, testicle
- **orchi/o**: Testis, testicle
- **orchid/o**: Testis, testicle
- **pen/i**: Penis
- **phall/o**: Penis
- **posth/o**: Prepuce, foreskin
- **preputi/o**: Prepuce, foreskin
- **prostat/o**: Prostate gland
- **scrot/o**: Scrotum
- **semin/i**: Semen
- **sperm/o**: Sperm, spermatozoon
- **spermat/o**: Sperm, spermatozoon
- **test/o**: Testis, testicle
- **testicular/o**: Testis, testicle
- **urethr/o**: Urethra
- **vas/o**: Vas deferens, vessel, duct
- **vesicul/o**: Seminal vesicle

COMMON SUFFIXES RELATED TO THE MALE REPRODUCTIVE SYSTEM

- **-al**: Pertaining to
- **-algia**: Pain
- **-ar**: Pertaining to

- **-cision:** Processing of cutting
- **-ectomy:** Excision or surgical removal
- **-genesis:** Beginning, development, or production
- **-gram:** Record
- **-graphy:** Process of recording
- **-ia:** Diseased state, abnormal state, condition of, condition
- **-ic:** Pertaining to
- **-ism:** State of, condition
- **-itis:** Inflammation
- **-logy:** Study of
- **-lysis:** Loosening, dissolution, separating
- **-oma:** Tumor, mass
- **-ous:** Pertaining to
- **-pathy:** Disease
- **-pexy:** Surgical fixation, suspension
- **-plasia:** Development, growth
- **-plasty:** Surgical repair
- **-rrhea:** Flow, discharge
- **-sis:** Condition
- **-stomy:** Creation of new opening, process of new opening
- **-tomy:** Cut into, incision

6.3 Examples of Male Reproductive Terms Easily Defined By Their Word Components

Here are examples of common medical terms related to the male reproductive system that can be easily defined by breaking the terms into their word components.

Prostatitis

1. Break down the medical term into word components:
Prostat/itis
2. Label the word components: **Prostat** = WR; **itis** = S
3. Define the word components: **Prostat** = prostate; **itis** = inflammation
4. Create a final definition of the medical term:
Inflammation of the prostate gland

Transurethral

1. Break down the medical term into word components:
Trans/urethr/al

2. Label the word components: **Trans** = P; **urethr** = WR; **al** = S
3. Define the word components: **Trans** = through; **urethr** = urethra; **al** = pertaining to
4. Create a final definition of the medical term: **Pertaining to through the urethra**

Vasectomy

1. Break down the medical term into word components:
Vas/ectomy
2. Label the word components: **Vas** = WR; **ectomy** = S
3. Define the word components: **Vas** = vas deferens duct; **ectomy** = excision or removal of
4. Create a final definition of the medical term: **Excision or removal of the vas deferens duct**



Interactive Learning Activity: Practice defining and pronouncing male reproductive system medical terms by breaking them down into word parts.



An interactive H5P element has been excluded from this version of the text. You can view it online here:

<https://wtcs.pressbooks.pub/medterm/?p=4118#h5p-46>

- ▶ You can also print this as a [Chapter 6 Student Companion Worksheet](#) and check your answers with this [Answer Key](#).

6.4 Anatomy of the Male Reproductive System

The structures of the male reproductive system include the testes and epididymis in the scrotum; the vas deferens, seminal vesicles, and bulbourethral glands; the prostate gland; and the penis. These structures are well-vascularized with many glands and ducts to promote the formation, storage, and ejaculation of sperm for fertilization and to also produce testosterone.¹

See Figure 6.1² for an illustration of these structures of the male reproductive system.

1. This work is a derivative of [StatPearls](#) by Gurung, Yetiskul, & Jialal and is licensed under [CC BY 4.0](#)

2. "[Figure_28_01_01.jpg](#)" by OpenStax College is licensed under [CC BY 3.0](#)

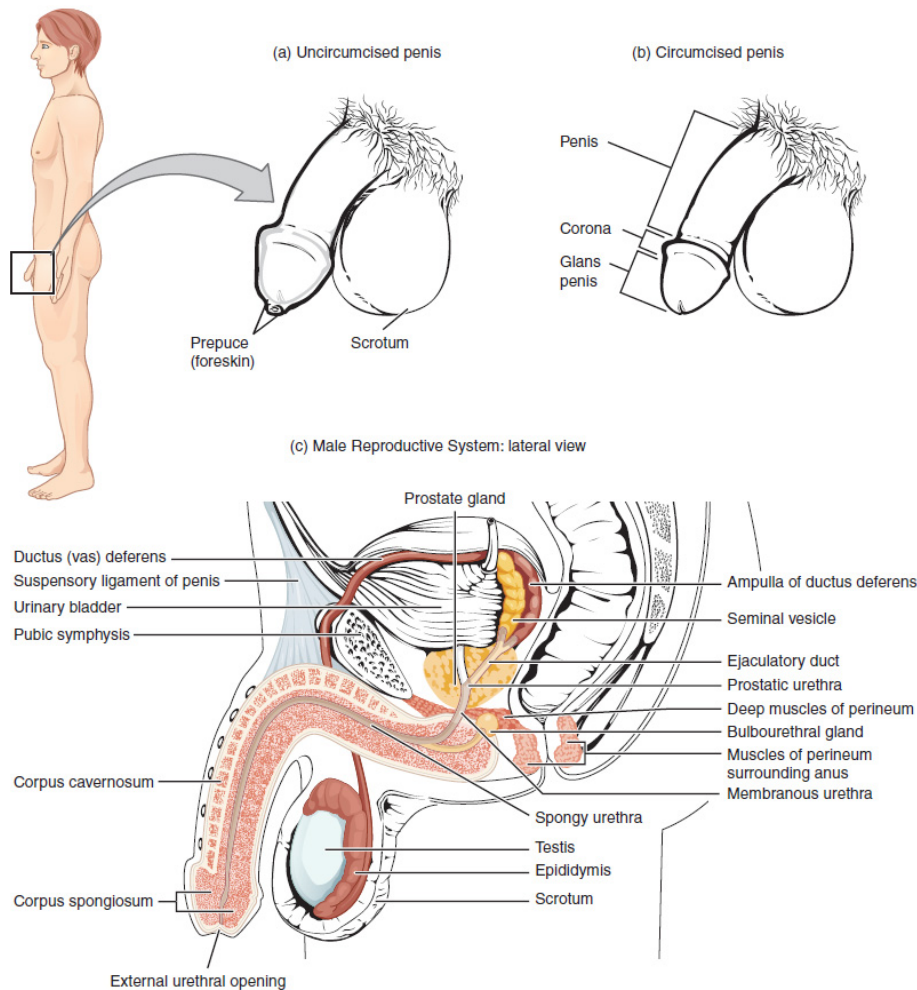


Figure 6.1 Male Reproductive System

TESTES

The **testes** (TĒS-tēz) are the male reproductive organs. They produce both sperm and **androgen** (AN-drō-jĕn), (i.e., the male sex hormone testosterone), and are active throughout the reproductive life span of the male. There are two testes, each approximately four to five cm in length, that are housed within the **scrotum** (SKRŌ-tŭm), an external pouch.³

During the seventh month of the developmental period of a male fetus, the testes move through the abdominal musculature to descend into the scrotal cavity. This is called the “descent of the testes.” **Cryptorchidism** (krip-TOR-kid-izm) is the clinical term used when one or both of the testes fail to descend into the scrotum prior to birth.⁴ **Anorchism** (ă-NOR-kizm) refers to the absence of one of the testes. See Figure 6.2⁵ for an illustration of a testicle.

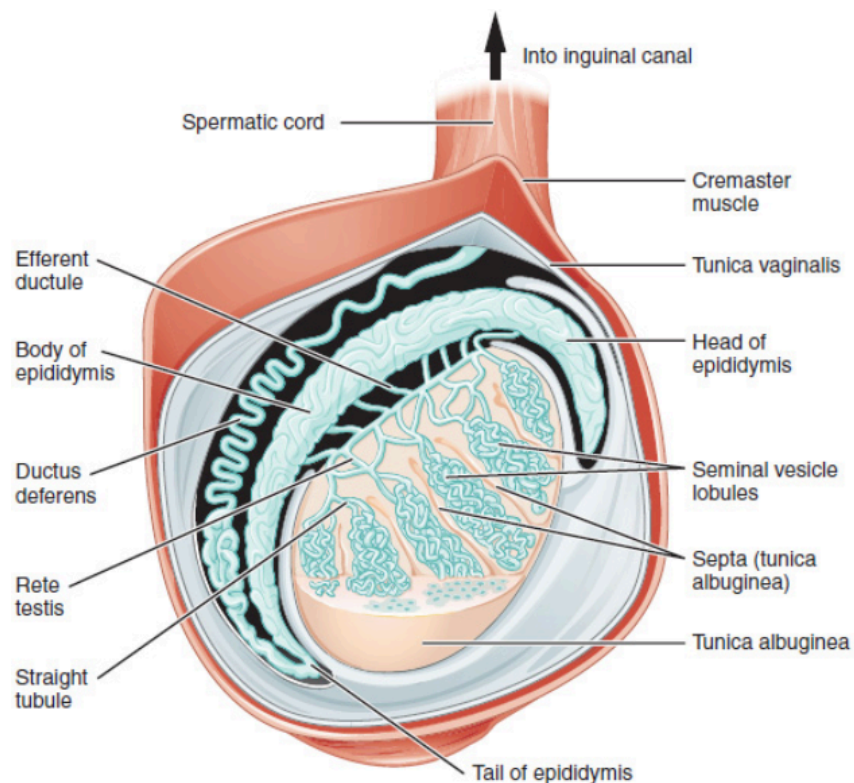


Figure 6.2 Testicle

under [CC BY 4.0](https://openstax.org/books/anatomy-and-physiology/pages/1-introduction). Access for free at <https://openstax.org/books/anatomy-and-physiology/pages/1-introduction>

4. This work is a derivative of [Anatomy & Physiology](https://openstax.org/books/anatomy-and-physiology) by [OpenStax](https://openstax.org/books/anatomy-and-physiology) and is licensed under [CC BY 4.0](https://openstax.org/books/anatomy-and-physiology/pages/1-introduction). Access for free at <https://openstax.org/books/anatomy-and-physiology/pages/1-introduction>

5. “[Figure_28_01_03.JPG](#)” by OpenStax College is licensed under [CC BY 3.0](https://openstax.org/books/anatomy-and-physiology)

The **spermatic cord** (spur-MAT-ĭk KORD) is a bundle of blood vessels, nerves, and ducts that connect the testicles to the abdominal cavity through the inguinal canal. There are several disorders related to the spermatic cord. The spermatic cord is sensitive to **torsion** (TOR-shŏn), in which the testicle rotates within its sac and blocks its own blood supply. An **inguinal hernia** (IN-gwĭ-năl HUR-nĕ-ă) can occur, referring to protrusion of abdominal contents through the inguinal canal into the scrotum. Varicose veins can occur in the spermatic cord, referred to as **varicocele** (VAR-ĭ-kō-sĕl). Though often asymptomatic, about one in four men with varicocele may experience infertility.⁶

Each testis is divided by septa into 300 to 400 structures called lobules. Within the lobules, sperm develop in structures called **seminiferous tubules** (sem-ĭ-NIF-ĕr-ŭs TŪ-bŭls). Newly produced sperm leave the seminiferous tubules and travel to the **epididymis** (ep-ĭ-DID-ĭ-mĭs), a coiled tube on top of the testes where the newly formed sperm continue to mature for an average of 12 days. As they are moved along the length of the epididymis, the sperm further mature and acquire the ability to move under their own power. Once inside the female reproductive tract, they will use this ability to move independently toward the unfertilized egg. Mature sperm are stored in the tail of the epididymis until ejaculation occurs.⁷

During ejaculation, sperm exit the tail of the epididymis and are pushed by smooth muscle contraction to the **vas deferens** (VĀS DEF-ĕr-ĕnz). Sperm make up only 5 percent of the final volume of **semen** (SĒ-mĕn), the thick, milky fluid that a male ejaculates. This fluid is produced by accessory glands

6. This work is a derivative of [Anatomy and Physiology](https://openstax.org/books/anatomy-and-physiology/pages/1-introduction) by [OpenStax](https://openstax.org/books/anatomy-and-physiology/pages/1-introduction) licensed under [CC BY 4.0](https://creativecommons.org/licenses/by/4.0/). Access for free at <https://openstax.org/books/anatomy-and-physiology/pages/1-introduction>
7. This work is a derivative of [Anatomy & Physiology](https://openstax.org/books/anatomy-and-physiology/pages/1-introduction) by [OpenStax](https://openstax.org/books/anatomy-and-physiology/pages/1-introduction) and is licensed under [CC BY 4.0](https://creativecommons.org/licenses/by/4.0/). Access for free at <https://openstax.org/books/anatomy-and-physiology/pages/1-introduction>

of the male reproductive system, the **seminal vesicles** (SEM-ĭ-năl VES-ĭ-kĕlz), the prostate, and the bulbourethral glands. From here, the semen travels through the urethra to the outside of the body during ejaculation.⁸

Because the vas deferens is easily accessible within the scrotum, surgical sterilization to interrupt sperm delivery can be performed by cutting and sealing a small section of the vas deferens, referred to as a **vasectomy** (vă-SEK-tō-mē). Read more about vasectomy in the “[Medical Specialists, Diagnostic Testing, and Procedures Related to the Male Reproductive System](#)” section.

PROSTATE AND BULBOURETHRAL GLANDS

As sperm pass through the vas deferens at ejaculation, they mix with fluid produced by the associated seminal vesicle. Seminal vesicle fluid contains large amounts of fructose, which is used by the sperm mitochondria to generate energy to allow movement through the female reproductive tract. The seminal fluid, now containing both sperm and seminal vesicle secretions, moves into the associated ejaculatory duct. The paired ejaculatory ducts transport the seminal fluid into the prostate gland.⁹

The **prostate** (PRŌS-tāt) is a gland that is anterior to the rectum at the base of the bladder and surrounds the urethra. A normal prostate gland is the size

8. This work is a derivative of [Anatomy and Physiology](#) by [OpenStax](#) licensed under [CC BY 4.0](#). Access for free at <https://openstax.org/books/anatomy-and-physiology/pages/1-introduction>
9. This work is a derivative of [Anatomy & Physiology](#) by [OpenStax](#) and is licensed under [CC BY 4.0](#). Access for free at <https://openstax.org/books/anatomy-and-physiology/pages/1-introduction>

of a walnut. It excretes an alkaline, milky fluid in semen to coagulate (thicken) and then decoagulate the semen following ejaculation. The temporary thickening of semen helps retain it within the female reproductive tract, providing time for sperm to utilize the fructose provided by seminal vesicle secretions. When semen regains its fluid state, the sperm can pass farther into the female reproductive tract.¹⁰

The final addition to semen is made by two **bulbourethral glands** (bul-bō-ŭ-RĒ-thrāl glandz) that release a thick, salty fluid to lubricate the end of the urethra and the vagina, as well as cleanse urine residue from the urethra. The fluid from these accessory glands is released after the male becomes sexually aroused and shortly before the release of the semen, so it is often referred to as pre-ejaculate. It is possible for bulbourethral fluid to pick up sperm already present in the urethra and cause pregnancy. Semen moves into the penis via the urethra, a multifunction anatomical structure that also transports urine from the bladder.¹¹

PENIS

The **penis** (PĒ-nīs) is a male reproductive organ that is flaccid during nonsexual actions, such as urination, and becomes stiff and rod-like during sexual arousal. When erect, the stiffness of the penis allows it to penetrate into the vagina and deposit semen into the female reproductive tract, referred to sexual intercourse or **coitus** (KŌ-ĭ-tūs).

10. This work is a derivative of [Anatomy & Physiology](#) by [OpenStax](#) and is licensed under [CC BY 4.0](#). Access for free at <https://openstax.org/books/anatomy-and-physiology/pages/1-introduction>

11. This work is a derivative of [Anatomy & Physiology](#) by [OpenStax](#) and is licensed under [CC BY 4.0](#). Access for free at <https://openstax.org/books/anatomy-and-physiology/pages/1-introduction>

The **glans penis** (glānz PĒ-nīs) refers to the tip of the penis. **Circumcision** (sĭr-kŭm-SIZH-ŏn) is the surgical removal of the **foreskin** (FŌR-skin), also called **prepuce** (PRĒ-pyūs), a fold of skin that covers the tip of the penis. Read more about circumcision in the “[Medical Specialists, Diagnostic Testing, and Procedures Related to the Male Reproductive System](#)” section.

6.5 Physiology of the Male Reproductive System

TESTOSTERONE

Testosterone (tes-TOS-tě-rōn) is an **androgen** (AN-drō-jěn) (i.e., male sex hormone) produced in the testes. In a male fetus, testosterone is secreted by the testes by the seventh week of development, with peak concentrations reached in the second trimester. This early release of testosterone results in the anatomical differentiation of the male sexual organs. In childhood, testosterone concentrations are low and then increase during **puberty** (PŪ-běrt-ē), the period during which adolescents develop secondary sex characteristics and become capable of reproduction. During puberty, the production of sperm begins.¹

Testosterone is released into the systemic circulation and plays an important role in muscle development, bone growth, development of secondary sex characteristics, and maintenance of **libido** (lĭ-BĒ-dō) (i.e., sex drive) in both males and females. In females, the ovaries secrete small amounts of testosterone, although most is converted to estradiol (a form of estrogen). A small amount of testosterone is also secreted by the adrenal glands in both sexes.²

1. This work is a derivative of [Anatomy & Physiology](#) by [OpenStax](#) and is licensed under [CC BY 4.0](#). Access for free at <https://openstax.org/books/anatomy-and-physiology/pages/1-introduction>
2. This work is a derivative of [Anatomy & Physiology](#) by [OpenStax](#) and is licensed

SPERMATOGENESIS

Spermatogenesis (spur-mă-tō-JĚN-ě-sīs), the production of sperm, occurs in the testes. Spermatogenesis requires a two- to three-degree lower temperature than body temperature, which is why it occurs outside of the body. It begins at puberty, after which time sperm are produced constantly throughout a man's life.³

One production cycle, from spermatogonia through formed sperm, takes approximately 64 days. Sperm counts, the total number of sperm a man produces, slowly decline after age 35. **Azoospermia** (ā-zō-ō-SPĚR-mē-ă) refers to the absence of viable sperm in the semen.

Sperm (SPURM), the male reproductive cell, are smaller than most cells in the body. In fact, the volume of a sperm cell is 85,000 times less than that of the egg (female reproductive cell). Approximately 100 to 300 million sperm are produced each day, whereas women typically ovulate only one oocyte (egg) per month. As is true for most cells in the body, the structure of sperm cells speaks to their function. Sperm have a distinctive head, midpiece, and tail region.⁴ See Figure 6.3⁵ for an illustration of a sperm.

under [CC BY 4.0](https://openstax.org/books/anatomy-and-physiology/pages/1-introduction). Access for free at <https://openstax.org/books/anatomy-and-physiology/pages/1-introduction>

3. This work is a derivative of [Anatomy and Physiology](https://openstax.org/books/anatomy-and-physiology/pages/1-introduction) by [OpenStax](https://openstax.org/books/anatomy-and-physiology/pages/1-introduction) licensed under [CC BY 4.0](https://openstax.org/books/anatomy-and-physiology/pages/1-introduction). Access for free at <https://openstax.org/books/anatomy-and-physiology/pages/1-introduction>
4. This work is a derivative of [Anatomy and Physiology](https://openstax.org/books/anatomy-and-physiology/pages/1-introduction) by [OpenStax](https://openstax.org/books/anatomy-and-physiology/pages/1-introduction) licensed under [CC BY 4.0](https://openstax.org/books/anatomy-and-physiology/pages/1-introduction). Access for free at <https://openstax.org/books/anatomy-and-physiology/pages/1-introduction>
5. "Structure of Sperm" by OpenStax College is licensed under [CC BY 4.0](https://openstax.org/books/anatomy-and-physiology/pages/1-introduction). Access for free at <https://openstax.org/books/anatomy-and-physiology/pages/1-introduction>

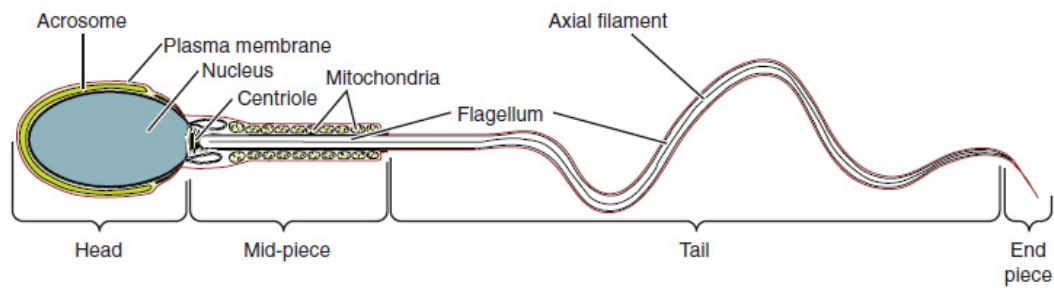


Figure 6.3 Sperm

Ejaculation (i-jak-yŭ-LĀ-shŏn) refers to the ejection of sperm-containing semen from the penis during **orgasm** (OR-gazm), the climax of sexual stimulation.⁶ A **condom** (KON-dŏm) is a sheath that may be worn during coitus to prevent pregnancy by collecting ejaculate. Condoms also help prevent the spread of sexually transmitted infections.

Penile erection is caused by vasocongestion of the penile tissues as more arterial blood flows into the penis than is leaving in the veins.⁷ **Priapism** (PRĪ-ă-pizm) is a disorder in which the penis maintains a prolonged, rigid erection for four hours or longer, in the absence of stimulation. Priapism that is caused by blood not being able to leave the penis is a medical emergency requiring prompt surgery to prevent damage to the penis. If not treated promptly, priapism can progress to permanent erectile dysfunction.⁸ **Erectile**

6. This work is a derivative of [Anatomy & Physiology](https://openstax.org/books/anatomy-and-physiology/pages/1-introduction) by OpenStax and is licensed under [CC BY 4.0](https://creativecommons.org/licenses/by/4.0/). Access for free at <https://openstax.org/books/anatomy-and-physiology/pages/1-introduction>

7. This work is a derivative of [Anatomy & Physiology](https://openstax.org/books/anatomy-and-physiology/pages/1-introduction) by OpenStax and is licensed under [CC BY 4.0](https://creativecommons.org/licenses/by/4.0/). Access for free at <https://openstax.org/books/anatomy-and-physiology/pages/1-introduction>

8. This work is a derivative of [StatPearls](https://www.statpearls.com/entry/view?id=3854) by Silberman, Stormont, Leslie, & Hu and is licensed under [CC BY 4.0](https://creativecommons.org/licenses/by/4.0/)

dysfunction (ě-RĚK-tīl dis-FŮNGK-shŏn) (**ED**) refers to the inability to attain or maintain an erection sufficient to perform sexual intercourse.

6.6 Diseases and Disorders of the Male Reproductive System

BENIGN PROSTATIC HYPERTROPHY

Benign prostatic hyperplasia (bē-NĪN prōs-TĀT-ĭk hī-pěr-PLĀ-zhē-ă) (**BPH**) refers to enlargement of the prostate that is not cancerous. See Figure 6.4¹ for an illustration of BPH. BPH is a common condition in males aged 50 and older. The prostate presses against the urethra, causing it to narrow. Eventually, the bladder becomes weak from trying to pass urine through the narrowed urethra. It loses its ability to completely empty, leaving some urine in the bladder called urinary retention. The inability to completely empty the bladder causes many of the symptoms associated with BPH, such as a frequent and intense urge to urinate, urinating frequently at night, difficulty starting a urine stream or a weak stream, and a sensation that the bladder has not emptied completely. If urinary retention is not addressed, it can cause complications such as urinary tract infections, bladder damage, and kidney damage.²

1. [“Benign_Prostatic_Hyperplasia_nci-vol-7137-300.jpg”](#) by unknown author for [National Cancer Institute](#) is licensed in the [Public Domain](#).

2. MedlinePlus [Internet]. Bethesda (MD): National Library of Medicine (US); [updated 2022, Aug. 17]. Enlarged prostate (BPH); [cited 2023, Oct. 10]. <https://medlineplus.gov/enlargedprostatebph.html>

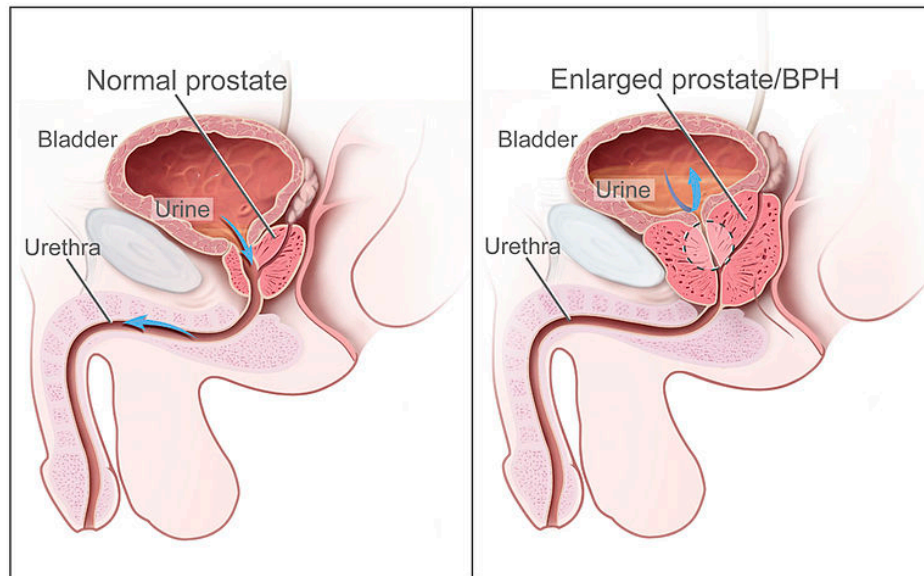


Figure 6.4 Benign Prostatic Hypertrophy

A health care provider may order several types of medical tests to diagnose BPH, such as urodynamic testing or a cystoscopy.³ Review information about these tests in the “[Medical Specialists, Diagnostic Testing, and Procedures Related to the Urinary System](#)” section in the “Urinary System Terminology” chapter.

BPH may be treated with medications or **transurethral** (trans-ū-RĒ-thrăl) procedures where an instrument is inserted through the urethra to widen the urethra or destroy part of the prostate with heat. **Transurethral microwave thermotherapy** (trans-ū-RĒ-thrăl MĪ-krō-wāv THUR-mō-THĚR-ă-pē) (**TUMT**) eliminates excess tissue present in benign prostatic hyperplasia by using heat generated by microwave.

Surgery may be performed when symptoms are severe, other treatments haven’t helped, or a complication has developed such as bladder damage. Surgeries remove part or all of the prostate or make cuts in the prostate to

3. MedlinePlus [Internet]. Bethesda (MD): National Library of Medicine (US); [updated 2022, Aug. 17]. Enlarged prostate (BPH); [cited 2023, Oct. 10]. <https://medlineplus.gov/enlargedprostatebph.html>

take pressure off the urethra.⁴ For example, **transurethral incision of the prostate** (trans-ū-RĒ-thrāl in-SIZH-ŭn öv thě PRŌS-tāt) (**TUIP**) is a procedure that widens the urethra by making a few small incisions in the bladder neck and the prostate gland. **Transurethral resection of the prostate** (trans-ū-RĒ-thrāl rĭ-SĚK-shŭn öv thě PRŌS-tāt) (**TURP**) is the surgical removal of pieces of the prostate gland by using an instrument inserted through the urethra.

CANCER

Prostate Cancer

Prostate cancer (PROS-tāt KAN-sěr), cancer of the prostate gland, is the second most common cancer occurring in men. Prostate cancer is most common in older men. In the U.S., about 1 out of 8 men will be diagnosed with prostate cancer. Prostate cancer usually grows very slowly, so treating it before symptoms occur may not improve men's health or help them live longer.⁵

Symptoms of prostate cancer are similar to benign prostatic hypertrophy (BPH), such as trouble starting a urine stream and frequent urination, especially at night, and trouble emptying the bladder. Symptoms of advanced prostate cancer that have metastasized to other areas of the body

4. MedlinePlus [Internet]. Bethesda (MD): National Library of Medicine (US); [updated 2022, Aug. 17]. Enlarged prostate (BPH); [cited 2023, Oct. 10]. <https://medlineplus.gov/enlargedprostatebph.html>

5. National Cancer Institute. (2023, February 16). *Prostate cancer treatment (PDQ) – patient version*. National Institutes of Health. <https://www.cancer.gov/types/prostate/patient/prostate-treatment-pdq>

include pain in the back, hips, or pelvis that doesn't go away, shortness of breath, fatigue, fast heartbeat, dizziness, or pale skin caused by anemia.⁶

Diagnostic testing for prostate cancer may include the following⁷:

- **Digital rectal exam** (dĭj-ĭ-tăl RĚK-tăl ěgz-ăm): An exam where the health care provider inserts a lubricated, gloved finger into the rectum and feels the prostate through the rectal wall to assess size, lumps, or other abnormal areas.
- **Pelvic lymphadenectomy** (PĚL-vĭk lim-fad-ě-NEK-tō-mē): A surgical procedure to remove the lymph nodes in the pelvis. A pathologist views the tissue under a microscope to look for cancer cells.⁸
- **Prostate-specific antigen** (PRŌS-tăt spě-SIF-ĭk AN-tĭ-jĕn) (**PSA**): A test that measures the level of PSA in the blood, a substance made by the prostate that may be found in higher-than-normal amounts in the blood of men who have prostate cancer. PSA levels may also be elevated in men who have BPH or prostatitis, so it is not a very reliable test.
- **PSMA PET scan** (PSMA PĚ-Ě-TĚ skăn): An imaging procedure that is used to help find prostate cancer cells that have spread outside of the prostate, into bone, lymph nodes, or other organs. For this procedure, a cell-targeting molecule linked to a radioactive substance is injected into the body and travels through the blood. It attaches to a protein called prostate-specific membrane antigen (PSMA) that is found on the surface

6. National Cancer Institute. (2023, February 16). *Prostate cancer treatment (PDQ) – patient version*. National Institutes of Health. <https://www.cancer.gov/types/prostate/patient/prostate-treatment-pdq>

7. National Cancer Institute. (2023, February 16). *Prostate cancer treatment (PDQ) – patient version*. National Institutes of Health. <https://www.cancer.gov/types/prostate/patient/prostate-treatment-pdq>

8. National Cancer Institute. (2023, February 16). *Prostate cancer treatment (PDQ) – patient version*. National Institutes of Health. <https://www.cancer.gov/types/prostate/patient/prostate-treatment-pdq>

of prostate cancer cells. A PET scanner detects high concentrations of the radioactive molecule and shows where the prostate cancer cells are in the body.

- **Seminal vesicle biopsy** (SEM-ĭ-năl VES-ĭ-kĕl BĪ-ŏp-sĕ): The removal of fluid from the seminal vesicles using a needle that is then viewed under a microscope by a pathologist to look for cancer cells.⁹
- **Transrectal ultrasound** (trans-RĚK-tăl ŮL-tră-sound): A procedure in which a probe that is about the size of a finger is inserted into the rectum to check the prostate. The probe is used to bounce high-energy sound waves (ultrasound) off internal tissues or organs and make echoes. The echoes form a picture of body tissues called a sonogram. Transrectal ultrasound may also be used during a biopsy procedure called **transrectal ultrasound guided biopsy** (trăns-RĚK-tăl ŮL-tră-sound GĪ-ded BĪ-ŏp-sĕ).
- **Transrectal MRI** (trans-RĚK-tăl ěm-ĀR-ĀĪ): A procedure that uses a strong magnet, radio waves, and a computer to make a series of detailed pictures of areas inside the body. A probe that gives off radio waves is inserted into the rectum near the prostate. This helps the MRI machine make clearer pictures of the prostate and nearby tissue. A transrectal MRI is done to find out if the cancer has spread outside the prostate into nearby tissues. Transrectal MRI may also be used during a biopsy procedure. This is called **transrectal MRI guided biopsy** (trăns-RĚK-tăl MRĪ GĪ-ded BĪ-ŏp-sĕ).
- **Transrectal biopsy** (trans-RĚK-tăl BĪ-ŏp-sĕ): The removal of tissue from the prostate by inserting a thin needle through the rectum and into the prostate. This procedure may be done using transrectal ultrasound or transrectal MRI to help guide where samples of tissue are taken from. A pathologist views the tissue under a microscope to look for cancer cells.

If prostate cancer is diagnosed, additional testing to check for metastasis may

9. National Cancer Institute. (2023, February 16). *Prostate cancer treatment (PDQ) – patient version*. National Institutes of Health. <https://www.cancer.gov/types/prostate/patient/prostate-treatment-pdq>

include bone scan, MRI, or CT scans. Read more about these diagnostic tests in the “[Medical Specialists, Diagnostic Testing, Procedures, and Equipment Related to the Respiratory System.](#)”

Treatment

There are several types of treatment for patients with prostate cancer, depending on the stage of the cancer and if it has metastasized (i.e., spread to other areas of the body)¹⁰:

- Watchful waiting
- Surgery
- Radiation therapy and radiopharmaceutical therapy
- Hormone therapy
- Chemotherapy
- Targeted therapy
- Immunotherapy

WATCHFUL WAITING

Watchful waiting refers to treatment used for older men whose prostate cancer is found during a screening test, but do not have signs or symptoms. Watchful waiting means closely monitoring a patient’s condition without any treatment unless signs or symptoms appear, or test results change. Treatment is provided to relieve symptoms and improve quality of life.¹¹

10. National Cancer Institute. (2023, February 16). *Prostate cancer treatment (PDQ) – patient version*. National Institutes of Health. <https://www.cancer.gov/types/prostate/patient/prostate-treatment-pdq>

11. National Cancer Institute. (2023, February 16). *Prostate cancer treatment (PDQ) – patient version*. National Institutes of Health. <https://www.cancer.gov/types/prostate/patient/prostate-treatment-pdq>

SURGERY

There are many types of surgeries performed to treat prostate cancer¹²:

- **Radical prostatectomy** (RAD-ĭ-kăl prŌS-tă-TĚK-tŏ-mē): A surgical procedure to remove the prostate, surrounding tissue, and seminal vesicles. Removal of nearby lymph nodes may be done at the same time to check for possible metastasis. The main types of radical prostatectomy are as follows:
 - **Open radical prostatectomy** (OPEN RAD-ĭ-kăl prŌS-tă-TĚK-tŏ-mē): An incision (cut) is made in the retropubic area (lower abdomen) or the perineum (the area between the anus and scrotum). Surgery is performed through the incision.
 - **Radical laparoscopic prostatectomy** (RAD-ĭ-kăl lăp-ă-RŌS-kŏ-pĭk prŌS-tă-TĚK-tŏ-mē): Several small incisions (cuts) are made in the wall of the abdomen. A laparoscope (a thin, tube-like instrument with a light and lens for viewing) is inserted through one opening to guide the surgery. Surgical instruments are inserted through the other openings to do the surgery.
 - **Robot-assisted laparoscopic radical prostatectomy** (ROH-bot ă-SĪS-tĕd lăp-ă-RŌS-kŏ-pĭk RAD-ĭ-kăl prŌS-tă-TĚK-tŏ-mē): Several small cuts are made in the wall of the abdomen, as in radical laparoscopic prostatectomy. The surgeon inserts an instrument with a camera through one of the openings and surgical instruments through the other openings using robotic arms. The camera gives the surgeon a three-dimensional view of the prostate and surrounding structures. The surgeon uses the robotic arms to do the surgery while sitting at a computer monitor near the operating table.
- **Pelvic lymphadenectomy** (PĚL-vĭk lim-fad-ě-NEK-tŏ-mē): Lymph nodes are removed from the pelvis for examination under a microscope by a

12. National Cancer Institute. (2023, February 16). *Prostate cancer treatment (PDQ) – patient version*. National Institutes of Health. <https://www.cancer.gov/types/prostate/patient/prostate-treatment-pdq>

pathologist who looks for cancer cells. If the lymph nodes contain cancer, the doctor may not remove the prostate and may recommend other treatment.

- **Transurethral resection of the prostate** (trans-ŭ-RĒ-thrāl rĭ-SĚK-shŭn ōv thĕ PRŌS-tāt) (**TURP**): TURP is a surgical procedure to remove tissue from the prostate using a resectoscope (a thin, lighted tube with a cutting tool) inserted through the urethra. This procedure is done to treat benign prostatic hypertrophy, and it is sometimes done to relieve symptoms caused by a tumor in the prostate gland before other cancer treatment is given. TURP may also be done in men who cannot have a radical prostatectomy because their tumor is only in the prostate.

RADIATION THERAPY AND RADIOPHARMACEUTICAL THERAPY

Radiation therapy (RĀ-dē-Ā-shŭn THĚR-ă-pē) uses high-energy X-rays or other types of radiation to kill cancer cells or keep them from growing. There are different types of radiation therapy¹³ :

- External radiation therapy uses a machine outside the body to send radiation toward the area of the body with cancer. A computer may be used to make a three-dimensional (3-D) picture of the tumor and shape the radiation beams to fit the tumor. This allows a high dose of radiation to reach the tumor and causes less damage to nearby healthy tissue.
- Internal radiation therapy uses a radioactive substance sealed in needles, seeds, wires, or catheters that are placed directly into or near the cancer. In early-stage prostate cancer, radioactive seeds are placed in the prostate using needles that are inserted through the skin between the scrotum and rectum. The placement of the radioactive seeds in the

¹³. National Cancer Institute. (2023, February 16). *Prostate cancer treatment (PDQ) – patient version*. National Institutes of Health. <https://www.cancer.gov/types/prostate/patient/prostate-treatment-pdq>

prostate is guided by images from transrectal ultrasound or computed tomography (CT). The needles are removed after the radioactive seeds are placed in the prostate.

- **Radiopharmaceutical therapy** (RĀ-dē-ō-far-mă-SOO-tĩ-kăl THĚR-ă-pē) uses a radioactive substance to treat metastatic prostate cancer that has spread to the bone.

HORMONE THERAPY

Hormone therapy (HOR-mōn THĚR-ă-pē), also referred to as anti-androgen therapy, reduces the amount of testosterone or blocks its action to stop prostate cancer cells from growing. Hormone therapy includes medications, surgery, or other hormones. **Orchiectomy** (or-kē-EK-tō-mē) is the surgical removal of one or both testicles, the main source of testosterone, to decrease the amount of hormone being made.¹⁴

CHEMOTHERAPY

Chemotherapy (KĒ-mō-THĚR-ă-pē) uses medications to stop the growth of cancer cells, either by killing the cells or by stopping them from dividing. When chemotherapy is taken by mouth or injected into a vein or muscle, the drugs enter the bloodstream and can reach cancer cells throughout the body.¹⁵

14. National Cancer Institute. (2023, February 16). *Prostate cancer treatment (PDQ) – patient version*. National Institutes of Health. <https://www.cancer.gov/types/prostate/patient/prostate-treatment-pdq>

15. National Cancer Institute. (2023, February 16). *Prostate cancer treatment (PDQ) – patient version*. National Institutes of Health. <https://www.cancer.gov/types/prostate/patient/prostate-treatment-pdq>

TARGETED THERAPY

Targeted therapy (TAR-gět-ed THĚR-ă-pē) uses medications or other substances to identify and attack specific cancer cells. Targeted therapies usually cause less harm to normal cells than chemotherapy or radiation therapy.¹⁶

IMMUNOTHERAPY

Immunotherapy (ĩm-yū-nō-THĚR-ă-pē) uses the patient's immune system to fight cancer. Substances made by the body or made in a laboratory are used to boost, direct, or restore the body's natural defenses against cancer.¹⁷

Testicular Cancer

Testicular cancer (těs-TĪK-ū-lăr KAN-sěr) is cancer that begins in the cells that make sperm in the testicle. It is rare and is most frequently diagnosed in men ages 20 to 34. Most testicular cancers can be cured, even if diagnosed at an advanced stage. Common symptoms of testicular cancer are a painless lump in the testicle, a dull ache in the lower abdomen or the groin, a sudden build-up of fluid in the scrotum, and pain in a testicle or in the scrotum. Diagnostic tests include an ultrasound of the testes and blood tests for tumor markers. Treatment includes **inguinal orchiectomy** (IN-gwĩ-năl or-kē-EK-tǒ-mē), a procedure to remove the entire testicle through an incision in the inguinal region of the groin.¹⁸

16. National Cancer Institute. (2023, February 16). *Prostate cancer treatment (PDQ) – patient version*. National Institutes of Health. <https://www.cancer.gov/types/prostate/patient/prostate-treatment-pdq>

17. National Cancer Institute. (2023, February 16). *Prostate cancer treatment (PDQ) – patient version*. National Institutes of Health. <https://www.cancer.gov/types/prostate/patient/prostate-treatment-pdq>

18. National Cancer Institute. (2023, May 17). *Testicular cancer treatment (PDQ) –*

ERECTILE DYSFUNCTION (ED)

Erectile dysfunction (ĭ-RĒK-tĭl dĭs-FŬNK-shŏn) (**ED**) is the inability to achieve or maintain an erection. ED is a common condition as men age, with 40% of men at age 40 and up to 70% of men by age 70 years experiencing ED. ED is also associated with side effects of some medications and many medical disorders such as high blood pressure, diabetes, cardiovascular disease, kidney disease, prostate disorders, and low testosterone levels. ED may be treated with medications or an implanted device.¹⁹

HYDROCELE

A **hydrocele** (Hĭ-drŏ-sĕl) is a type of swelling in the scrotum, the pouch of skin that holds the testicles. This swelling happens when fluid collects in the thin sac that surrounds a testicle. Hydroceles are common in newborns. They often go away without treatment by age one.²⁰

Older children and adults can get a hydrocele due to an injury to the scrotum or other health problems. For example, a hydrocele may develop

patient version. National Institutes of Health. <https://www.cancer.gov/types/testicular/patient/testicular-treatment-pdq>

19. National Institute of Diabetes and Digestive and Kidney Diseases. (2017, July). *Definitions & facts for erectile dysfunction*. National Institutes of Health. <https://www.niddk.nih.gov/health-information/urologic-diseases/erectile-dysfunction/definition-facts>

20. Mayo Clinic. (2023, January 12). *Hydrocele*. <https://www.mayoclinic.org/diseases-conditions/hydrocele/symptoms-causes/syc-20363969>

after surgery for **varicocele** (VAR-ĭ-kō-sēl), enlarged veins of the spermatic cord that can cause scrotal swelling.

INFERTILITY

Nearly 1 in 7 couples is infertile, which means they haven't been able to conceive a child even though they've had frequent, unprotected sexual intercourse for a year or longer. In up to half of these couples, male infertility plays a role. Male infertility can be caused by low sperm production, abnormal sperm function, or blockages that prevent the delivery of sperm. Illnesses, injuries, chronic health problems, lifestyle choices, and other factors may contribute to male infertility.²¹

For a male to cause pregnancy, the following processes must occur²²:

- **Healthy sperm are produced.** At least one testicle must be functioning, and the body must produce testosterone and other hormones to trigger and maintain sperm production.
- **Sperm must be carried into the semen.** After sperm are produced in the testicles, tubes transport them until they mix with semen and are ejaculated out of the penis.
- **There must be enough sperm in the semen.** If the number of sperm in the semen (referred to as sperm count) is low, it decreases the odds that one sperm will fertilize a partner's egg. A low sperm count is fewer than 15 million sperm per milliliter of semen or fewer than 39 million per ejaculate. **Aspermia** (ā-SPUR-mē-ă) refers to failure to produce sperm.

21. Mayo Clinic. (2022, December 28). *Male infertility*. <https://www.mayoclinic.org/diseases-conditions/male-infertility/symptoms-causes/syc-20374773>

22. Mayo Clinic. (2022, December 28). *Male infertility*. <https://www.mayoclinic.org/diseases-conditions/male-infertility/symptoms-causes/syc-20374773>

- **Sperm must be functional and able to move.** If the movement (referred to as motility) or the function of sperm is abnormal, the sperm may not be able to reach or penetrate the partner's egg.

There are several possible causes of male infertility. If a couple is not able to conceive within one year of having unprotected sex, the couple can visit fertility specialists for diagnostic testing and infertility treatment.

PROSTATITIS

Prostatitis (pros-tă-TĪT-īs) refers to inflammation of the prostate gland and sometimes areas surrounding it. Prostatitis can be acute or chronic, and some types are caused by a bacterial infection. Symptoms of acute bacterial prostatitis are typically severe and come on suddenly, whereas chronic prostatitis develops slowly and lasts three or more months. Symptoms may include the following²³:

- Urinary frequency
- Urinary urgency
- A weak or an interrupted urine stream
- Dysuria
- Fever and/or chills
- Painful ejaculation
- Pain in the penis or testicles

A health care provider diagnoses prostatitis by performing diagnostic tests, such as a urinalysis and cystoscopy. Treatment depends upon the cause and may include antibiotics and pain relievers.

23. Mayo Clinic. (2022, February 19). *Prostatitis*. <https://www.mayoclinic.org/diseases-conditions/male-infertility/symptoms-causes/syc-20374773>

SEXUALLY TRANSMITTED INFECTIONS

Sexually transmitted infections affect both males and females. The terms **sexually transmitted infection** (SEKS-ū-ă-lē trāns-MĭT-ed ĭn-FĚK-shŏn) (**STI**) and **sexually transmitted disease** (SEKS-ū-ă-lē trāns-MĭT-ed diz-ĒZ) (**STD**) are used interchangeably. STI and STD imply the infection was acquired through sexual transmission. Examples of STIs include chlamydia, gonorrhea, human immunodeficiency virus (HIV), human papillomavirus (HPV), and herpes simplex virus. The only way to completely avoid STIs is to not have vaginal, anal, or oral sex. If you are sexually active, the following factors can lower your chances of getting an STI²⁴:

- Being in a long-term mutually monogamous relationship with a partner who has been tested and does not have STI
- Correctly using condoms every time you have sex

Chlamydia

Chlamydia (klă-MĭD-ē-ă) is the most common type of bacterial STI. It is caused by a bacteria called *Chlamydia trachomatis*. Chlamydia is often referred to as a “silent disease” because many people with chlamydia do not have any symptoms and unknowingly pass the infection to their sexual partner(s). Anyone can get chlamydia during oral, vaginal, or anal sex with someone who has chlamydia. A pregnant woman can also pass chlamydia to her baby during childbirth, causing eye infections or pneumonia.²⁵

24. Centers for Disease Control and Prevention. (2022, April 12). *Chlamydia – CDC basic fact sheet*. U.S. Department of Health & Human Services.
<https://www.cdc.gov/std/chlamydia/stdfact-chlamydia.htm>

25. Centers for Disease Control and Prevention. (2022, April 12). *Chlamydia – CDC*

Symptoms may not appear until several weeks after having sex with someone who has chlamydia. Symptoms in women include abnormal vaginal discharge, which may have a strong smell, and a burning sensation when urinating. Symptoms in men include discharge from the penis and a burning sensation when urinating. If untreated, chlamydia in females can lead to **pelvic inflammatory disease** (PĚL-vĭk ĭn-flă-MĂ-tör-ē dĭ-ZĚZ) (**PID**), which can cause permanent damage to the reproductive organs and infertility.²⁶

Chlamydia is diagnosed by a health care provider by a urine sample or by using a cotton swab to obtain a specimen that is sent to a lab for analysis. Chlamydia is treated with antibiotics. All sexual partners within the past 60 days should be notified and examined by a health care provider, keeping in mind that not having symptoms does not mean there is no infection. Reinfection is common, so people diagnosed with chlamydia should be retested three months after treatment of the initial infection, regardless of whether they believe that their sexual partners were successfully treated.²⁷

Gonorrhea

Gonorrhea (gon-ŏ-RE-ă) is a bacterial STI caused by *Neisseria gonorrhea*. *Neisseria gonorrhea* infects the mucous membranes of the reproductive tract, including the cervix, uterus, and Fallopian tubes in women, and the

basic fact sheet. U.S. Department of Health & Human Services.
<https://www.cdc.gov/std/chlamydia/stdfact-chlamydia.htm>

26. Centers for Disease Control and Prevention. (2022, April 12). *Chlamydia – CDC basic fact sheet*. U.S. Department of Health & Human Services.
<https://www.cdc.gov/std/chlamydia/stdfact-chlamydia.htm>

27. Centers for Disease Control and Prevention. (2022, April 12). *Chlamydia – CDC basic fact sheet*. U.S. Department of Health & Human Services.
<https://www.cdc.gov/std/chlamydia/stdfact-chlamydia.htm>

urethra in both women and men, causing inflammation and discharge. *Neisseria gonorrhea* can also infect the mucous membranes of the mouth, throat, eyes, and rectum. Gonorrhea is transmitted through sexual contact with the penis, vagina, mouth, or anus of an infected partner. Ejaculation does not have to occur for gonorrhea to be transmitted or acquired. Gonorrhea can also be spread perinatally from mother to baby during childbirth, which can cause blindness, joint infection, or a life-threatening blood infection in the baby if left untreated.²⁸

Many people infected with gonorrhea have no symptoms and can unknowingly pass the infection on to their sexual partner(s). Most women with gonorrhea are asymptomatic. Even when a woman has symptoms, they are often so mild and nonspecific that they are mistaken for a bladder or vaginal infection. The initial symptoms and signs in women include dysuria, increased vaginal discharge, or vaginal bleeding between periods. Women with gonorrhea are at risk of developing serious complications from the infection, such as pelvic inflammatory disease (PID).

When present, signs and symptoms of gonorrhea in men include dysuria (painful urination) or a white, yellow, or green urethral discharge that usually appears 1 to 14 days after infection. Men may also experience testicular or scrotal pain.

Symptoms of rectal gonorrhea infection in both men and women may include discharge, anal itching, soreness, bleeding, or painful bowel movements. Pharyngeal gonorrhea infection may cause a sore throat, but it is usually asymptomatic.²⁹

Urogenital gonorrhea can be diagnosed by testing urine, a urethral swab

28. Centers for Disease Control and Prevention. (2023, April 11). *Gonorrhea – CDC detailed fact sheet*. U.S. Department of Health & Human Services. <https://www.cdc.gov/std/gonorrhea/stdfact-gonorrhea-detailed.htm>

29. Centers for Disease Control and Prevention. (2023, April 11). *Gonorrhea – CDC detailed fact sheet*. U.S. Department of Health & Human Services. <https://www.cdc.gov/std/gonorrhea/stdfact-gonorrhea-detailed.htm>

(for men), or endocervical or vaginal swab (for women) using **nucleic acid amplification testing** (no-klē-ĭk ăS-ĭd ăm-plĭ-fĭ-KĀ-shŏn tĕst-ing) (**NAAT**). It can also be diagnosed using gonorrhea culture, which requires endocervical or urethral swab specimens.³⁰

Gonorrhea is treated with an intramuscular (IM) injection of antibiotics. It is important that individuals complete the treatment and abstain from unprotected sexual activity for at least seven days following treatment. All sexual partners within the past 60 days should be notified and examined, keeping in mind that having no symptoms does not mean there is no infection. Reinfection is common, so people with gonorrhea should be retested three months after treatment of the initial infection, regardless of whether they believe that their sexual partners were successfully treated.³¹

Human Immunodeficiency Virus (HIV)

Human immunodeficiency virus (hu-man im-yŭ-nŏ-dĕ-FISH-ĕn-sĕ Vĭ-rŭs) (**HIV**) is a virus that attacks the T-helper cells (a type of lymphocyte or white blood cell) of the immune system. If HIV is not treated, it can lead to **acquired immunodeficiency syndrome** (ă-KWĪRD im-yŭ-nŏ-dĕ-FISH-ĕn-sĕ SĪN-drŏm) (**AIDS**). There is currently no cure for HIV, so people who become infected with HIV have it for life. However, with proper medical care, HIV can be controlled, and people with HIV can live long, healthy lives while also preventing its spread to their partners.³²

30. Centers for Disease Control and Prevention. (2023, April 11). *Gonorrhea – CDC detailed fact sheet*. U.S. Department of Health & Human Services.

<https://www.cdc.gov/std/gonorrhea/stdfact-gonorrhea-detailed.htm>

31. Centers for Disease Control and Prevention. (2023, April 11). *Gonorrhea – CDC detailed fact sheet*. U.S. Department of Health & Human Services.

<https://www.cdc.gov/std/gonorrhea/stdfact-gonorrhea-detailed.htm>

32. Centers for Disease Control and Prevention. (2022, June 30). *What is HIV?* U.S.

Most people infected with HIV have flu-like symptoms within two to four weeks after becoming infected. Symptoms include fever, night sweats, fatigue, swollen lymph nodes, sore throat, muscle aches, and rash. If not treated, the infection becomes chronic, with or without symptoms, and can take up to ten years to develop AIDS. Without HIV treatment, people with AIDS typically only survive about three years.³³

HIV tests can be performed on blood or oral fluid. HIV is treated with medication called **antiretroviral therapy** (ăn-tē-rě-trō-Vĭ-răl THĚR-ă-pē) that reduces the amount of virus in the body, helps maintain a healthy immune system, and prevents AIDS from developing.³⁴

Herpes Simplex Virus

Genital herpes (JEN-ĭt-ăl HĚRP-ēz) is an STI caused by the **herpes simplex virus** (HUR-pēz SĪM-pleks Vĭ-rŭs) (**HSV**) that is characterized by blisters in the genital area. There are two types of herpes simplex viruses: HSV-1 and HSV-2. HSV-1 (oral herpes) causes mouth ulcers, commonly called “cold sores.” HSV-2 causes genital herpes when a person has genital contact with someone who has a genital HSV-2 infection. Additionally, a genital HSV-1 infection can occur when a person receives oral sex from a person with an HSV-1 oral ulcer.

Department of Health & Human Services. <https://www.cdc.gov/hiv/basics/whatishiv.html>

33. Centers for Disease Control and Prevention. (2022, June 30). *What is HIV?* U.S. Department of Health & Human Services. <https://www.cdc.gov/hiv/basics/whatishiv.html>

34. Centers for Disease Control and Prevention. (2022, June 30). *What is HIV?* U.S. Department of Health & Human Services. <https://www.cdc.gov/hiv/basics/whatishiv.html>

Herpes infection can also be passed from mother to child during pregnancy or childbirth, which can result in a potentially fatal neonatal herpes infection.³⁵

Herpes lesions typically appear as one or more vesicles (i.e., small blisters), on or around the genitals, rectum, or mouth. The vesicles break and leave painful ulcers that may take two to four weeks to heal after the initial herpes infection. Once a patient is infected with HSV, the virus remains in their body even after the symptoms are gone and can cause recurring outbreaks related to fever, stress, or other triggering factors.³⁶ See Figure 6.5³⁷ for an image of a mouth ulcer caused by HSV-1. Although this is not considered an STI, herpes lesions that occur on the genitals have a similar appearance.

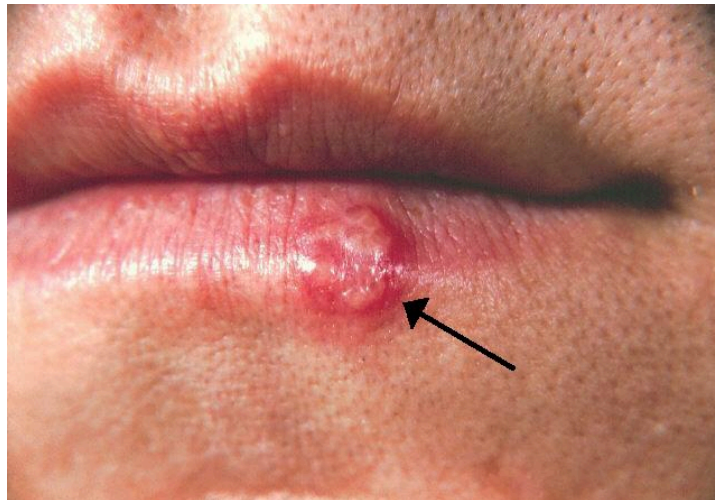

Figure 6.5 Mouth Ulcer Caused by HSV-1

- 35. Centers for Disease Control and Prevention. (2021, July 22). *Genital herpes – CDC detailed fact sheet*. U.S. Department of Health & Human Services. <https://www.cdc.gov/std/herpes/stdfact-herpes-detailed.htm>
- 36. Centers for Disease Control and Prevention. (2021, July 22). *Genital herpes – CDC detailed fact sheet*. U.S. Department of Health & Human Services. <https://www.cdc.gov/std/herpes/stdfact-herpes-detailed.htm>
- 37. “Herpes(PHIL_1573_lores).jpg” by [Centers for Disease Control and Prevention](#) is licensed in the [Public Domain](#).

HSV nucleic acid amplification tests (NAAT) are the best test for diagnosing herpes, but in some settings, a viral culture is the only test available. There is no cure for herpes. Antiviral medications can shorten outbreaks, and daily suppressive therapy can prevent outbreaks and transmission of the infection to partners.³⁸

Human Papillomavirus

Human papillomavirus (hu-man PAP-ĭ-LŌ-mă-Vĭ-rŭs) (**HPV**) is a common STI. Almost three quarters of sexually active individuals have been exposed to HPV during their lifetime. HPV spreads through sexual activity and skin-to-skin contact in the genital area with an infected person. Because some types of HPV are asymptomatic, people don't know they have the virus and, consequently, pass the virus to their sexual partners.³⁹

There are over 100 strains of HPV, and some strains of HPV can cause visible genital warts. Genital warts usually appear as a small bump or group of bumps in the genital area. They can be small or large, raised or flat, or shaped like a cauliflower. Some strains of HPV cause genital, anal, throat, and cervical cancers. For this reason, routine PAP smears for women can help prevent cervical cancer from HPV.⁴⁰

Treatments are available for genital warts, but there is no cure for HPV. The

38. Centers for Disease Control and Prevention. (2021, July 22). *Genital herpes – CDC detailed fact sheet*. U.S. Department of Health & Human Services. <https://www.cdc.gov/std/herpes/stdfact-herpes-detailed.htm>

39. Centers for Disease Control and Prevention. (2022, April 12). *Genital HPV infection – basic fact sheet*. U.S. Department of Health & Human Services. <https://www.cdc.gov/std/hpv/stdfact-hpv.htm>

40. Centers for Disease Control and Prevention. (2022, April 12). *Genital HPV infection – basic fact sheet*. U.S. Department of Health & Human Services. <https://www.cdc.gov/std/hpv/stdfact-hpv.htm>

HPV vaccine can protect against diseases (including cancers) caused by HPV. The HPV vaccine is recommended for all preteens (including boys and girls) at age 11 or 12 years and through age 26 years. Most sexually active adults have already been exposed to HPV, so vaccination is not recommended. People who are in a long-term, mutually monogamous relationship are not likely to get a new HPV infection.⁴¹

Syphilis

Syphilis (SIF-ĭ-lĭs) is an STI that can cause serious health problems without treatment. Infection develops in stages called primary, secondary, latent, and tertiary. Each stage can have different signs and symptoms. Syphilis is spread by direct contact with a syphilis sore during vaginal, anal, or oral sex. Syphilis can also be spread from a mother with syphilis to her unborn baby.⁴²

During the first (primary) stage of syphilis, a single sore or multiple sores appear in the location where syphilis entered the body. See Figure 6.6⁴³ for an image of a sore caused by syphilis, referred to as a chancre. Sores are typically firm, round, and painless. The sore usually lasts three to six weeks and heals regardless of whether treatment is received.

41. Centers for Disease Control and Prevention. (2022, April 12). *Genital HPV infection – basic fact sheet*. U.S. Department of Health & Human Services. <https://www.cdc.gov/std/hpv/stdfact-hpv.htm>

42. Centers for Disease Control and Prevention. (2022, February 10). *Syphilis – CDC basic fact sheet*. U.S. Department of Health & Human Services. <https://www.cdc.gov/std/syphilis/stdfact-syphilis.htm>

43. “[Extragenital syphilitic chancre of the left index finger PHIL_4147_lores.jpg](#)” by [Centers for Disease Control and Prevention](#) is licensed in the [Public Domain](#).

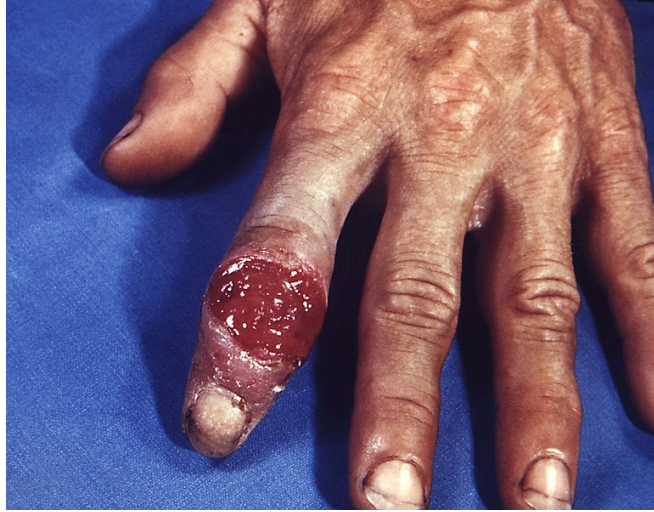

Figure 6.6 Syphilis Chancre

During the secondary stage, skin rashes and/or sores in the mouth, vagina, or anus appear. The rash can show up when the primary sore is healing or several weeks after the sore has healed. The rash can also be on the palms of the hands and/or the bottoms of the feet and look rough, red, or reddish-brown. Without treatment, syphilis can spread to the brain and nervous system (neurosyphilis), the eye (ocular syphilis), or the ear (otosyphilis). This can happen during any of the stages. Syphilis is treated with antibiotics, but antibiotics do not reverse any damages that occurred prior to treatment.⁴⁴

Trichomoniasis

Trichomoniasis (trīk-ō-mō-Nĭ-ă-sīs) is a common STI caused by infection with *Trichomonas vaginalis*, a protozoan (tiny, single-celled) parasite. Although symptoms vary, most people who have trichomoniasis cannot tell they have it. Men with trichomoniasis may notice itching or irritation inside the penis,

44. Centers for Disease Control and Prevention. (2022, February 10). *Syphilis – CDC basic fact sheet*. U.S. Department of Health & Human Services.
<https://www.cdc.gov/std/syphilis/stdfact-syphilis.htm>

burning after urinating or ejaculating, or discharge from the penis. Women with trichomoniasis may notice itching; burning; redness or soreness of the genitals; dysuria; or a clear, white, yellowish, or greenish vaginal discharge with a fishy smell. Trichomoniasis is diagnosed with a swab specimen evaluated in a laboratory. It is treated with antibiotics taken by mouth.⁴⁵

SPERMATOCELE

A **spermatocele** (spĕr-MĀT-ō-sēl) is an abnormal sac (cyst) that develops in the epididymis, the small, coiled tube located on the upper testicle that collects and transports sperm. The cause of spermatoceles is unknown but could be due to a blockage in one of the tubes that transport sperm. If a spermatocele grows large enough to cause discomfort, surgery may be required.⁴⁶

TESTICULAR TORSION

Testicular torsion (tĕs-TĪK-ū-lăr TOR-shŏn) occurs when a testicle rotates, twisting the spermatic cord that brings blood to the scrotum. The reduced blood flow causes sudden, severe pain and swelling. Testicular torsion commonly occurs between ages 12 and 18 and usually requires emergency

45. Centers for Disease Control and Prevention. (2022, April 25). *Trichomoniasis – CDC basic fact sheet*. U.S. Department of Health & Human Services. <https://www.cdc.gov/std/trichomonas/stdfact-trichomoniasis.htm>

46. Mayo Clinic. (2022, March 31). *Spermatocele*. <https://www.mayoclinic.org/diseases-conditions/spermatocele/symptoms-causes/syc-20377829>

surgery. If treated quickly, the testicle can usually be saved. But when blood flow has been cut off for too long, a testicle might become so badly damaged that it has to be removed.⁴⁷

47. Centers for Disease Control and Prevention. (2022, February 24). *Trichomoniasis – CDC basic fact sheet*. U.S. Department of Health & Human Services. <https://www.mayoclinic.org/diseases-conditions/testicular-torsion/symptoms-causes/syc-20378270>

6.7 Medical Specialists, Diagnostic Testing, and Procedures Related to the Male Reproductive System

MEDICAL SPECIALISTS

Urology (yū-RŌL-ŏ-jē) is the study of the male and female urinary systems and the male reproductive system.¹ A **urologist** (yū-RŌL-ŏ-jĭst) is a physician who specializes in the diagnosis and treatments of disorders of the urinary and reproductive systems.

- ▶ To learn more about urology and the training involved to become a urologist, visit the [American Urological Association, Why Urology?](https://www.auanet.org/about-us/aua-overview/why-urology)

1. American Urological Association. (n.d.). *Why urology?* <https://www.auanet.org/about-us/aua-overview/why-urology>

DIAGNOSTIC TESTING

Semen Analysis

A **semen analysis** (SĒ-mĕn ă-NĂL-ĭ-sĭs) evaluates the volume and quality of a man's sperm. It is one of the first tests performed when a couple experiences infertility. It is also performed to determine if a vasectomy was successful.

Semen analysis involves collecting a semen sample and evaluating it in a lab.²

When used as a fertility test in men, a semen analysis evaluates the following³:

- **pH level:** Whether semen is too acidic, which can affect sperm health.
- **Semen volume:** Amount of semen in the sample (in millimeters).
- **Sperm concentration:** Number of sperm per millimeter of semen.
- **Sperm morphology:** Size and shape of the sperm.
- **Sperm motility:** Ability of the sperm to swim toward an egg.
- **Time to liquefaction:** How quickly semen changes from a sticky substance to a liquid.
- **Vitality:** Percent of live sperm in the sample.
- **White blood cells:** A sign of infection or inflammation.

2. Cleveland Clinic. (2021, April 30). *Semen analysis*.

<https://my.clevelandclinic.org/health/diagnostics/21520-semen-analysis>

3. Cleveland Clinic. (2021, April 30). *Semen analysis*.

<https://my.clevelandclinic.org/health/diagnostics/21520-semen-analysis>

PROCEDURES

Circumcision

Circumcision (sĭr-kŭm-SIZH-ŭn) is the surgical removal of the foreskin (prepuce), a fold of skin covering the tip of the penis. It is a common procedure for newborn boys in certain parts of the world, including the United States. For some families, circumcision is a religious ritual or family tradition.⁴

Newborn circumcision is typically done in the hospital nursery by a pediatrician within a few days after birth. The penis and surrounding area are cleansed, and an anesthetic is injected into the base of the penis or applied to the penis as a cream. A special clamp or plastic ring is attached to the penis, and the foreskin will be removed. Afterward, the penis is covered with an ointment and wrapped loosely with gauze. The procedure generally takes about ten minutes.⁵

Circumcision is also used to treat men with **phimosis** (fĭ-MŌ-sĭs), a tightness of the prepuce (foreskin) that prevents its retraction over the penis. It may be congenital or the result of balanitis. **Balanitis** (băl-ă-NĪ-tĭs) is a common condition that causes an inflammation of the glans penis (i.e., the head of the penis). It can be caused by fungi, yeast, bacteria, or viruses, including those

4. Mayo Clinic. (2022, March 22). *Circumcision (male)*.

<https://www.mayoclinic.org/tests-procedures/circumcision/about/pac-20393550>

5. Mayo Clinic. (2022, March 22). *Circumcision (male)*.

<https://www.mayoclinic.org/tests-procedures/circumcision/about/pac-20393550>

that cause sexually transmitted infections (STI), but balanitis is not considered an STI.⁶

Hydrocelectomy

Hydrocelectomy (hī-drō-sē-LĚK-tō-mē) is the surgical removal of a fluid-filled sac around the testicle that is causing scrotal swelling (i.e., a hydrocele).

Vasectomy

A **vasectomy** (vă-SEK-tō-mē) is a surgical procedure that prevents sperm from leaving the body, providing permanent birth control, referred to as **sterilization** (ster-ĭ-lĭ-ZĀ-shŏn). The procedure closes off the ends of the vas deferens, the tubes that carry sperm. Semen samples are routinely checked after a vasectomy to confirm a successful procedure. Vasectomy is safe and effective for preventing pregnancy, but it doesn't protect against sexually transmitted infections.⁷

There are two types of vasectomies. One is an incision vasectomy, and the other is a no-scalpel vasectomy. The incision vasectomy requires two small incisions, whereas the no-scalpel vasectomy requires only one small puncture. Both are done in doctors' offices or outpatient surgery centers and use local anesthesia to numb the scrotum. Both types of vasectomies divide and close off the ends of the vas deferens, preventing sperm from getting through. The vas deferens is divided and tied, clipped, or cauterized (using an electrical current to close the incision).⁸

6. This work is a derivative of [StatPearls](#) by Wray, Velasquez, & Khetarpal and is licensed under [CC BY 4.0](#)
7. Cleveland Clinic. (2022, February 3). *Vasectomy*. <https://my.clevelandclinic.org/health/treatments/4423-vasectomy>
8. Cleveland Clinic. (2022, February 3). *Vasectomy*. <https://my.clevelandclinic.org/health/treatments/4423-vasectomy>



View a [MedlinePlus video](#) about a vasectomy procedure.

6.8 Male Reproductive System Learning Activities

Interactive Learning Activity: Label the anatomy of the male reproductive system by completing this drag and drop activity.



An interactive H5P element has been excluded from this version of the text. You can view it online here:

<https://wtcs.pressbooks.pub/medterm/?p=337#h5p-47>

Interactive Learning Activity: Study male reproductive system medical terms discussed in this chapter using these flashcards.



An interactive H5P element has been excluded from this version of the text. You can view it online here:

<https://wtcs.pressbooks.pub/medterm/?p=337#h5p-180>

Interactive Learning Activity: Test your knowledge about common male reproductive system terms by completing this activity.



An interactive H5P element has been excluded from this version of the text. You can view it online here:

<https://wtcs.pressbooks.pub/medterm/?p=337#h5p-52>

Interactive Learning Activity: Using the sample documentation provided, drag the terms on the right to their appropriate spaces within the documentation.



An interactive H5P element has been excluded from this version of the text. You can view it online here:

<https://wtcs.pressbooks.pub/medterm/?p=337#h5p-51>



Interactive Learning Activity: Practice identifying and defining word parts for terms discussed in this chapter.



An interactive H5P element has been excluded from this version of the text. You can view it online here:

<https://wtcs.pressbooks.pub/medterm/?p=337#h5p-198>

- ▶ You can also print this as a [Chapter 6 Practice Worksheet](#) and check your answers with this [Answer Key PDF](#).

6.9 Glossary

Acquired immunodeficiency syndrome (ă-KWĪRD im-yū-nō-dě-FISH-ě̃n-sē SĪN-drōm) (AIDS): A potentially life-threatening disease that is caused by infection with HIV commonly transmitted in infected blood especially during illicit intravenous drug use and in bodily secretions during sexual intercourse. ([Chapter 6.6](#))

Androgen (AN-drō-jě̃n): Hormones that stimulate or control the development of male characteristics; includes testosterone. ([Chapter 6.4](#), [Chapter 6.5](#))

Anorchism (ă-NOR-kĭzm): The absence of one or both testes. ([Chapter 6.4](#))

Antiretroviral therapy (ăn-tē-rě-trō-VĪ-răĭ THĒR-ă-pē): Treatment using medications that inhibit the replication of retroviruses, such as HIV, improving the health and prolonging the life of people infected. ([Chapter 6.6](#))

Aspermia (ā-SPUR-mē-ă): The complete absence of semen, a rare condition affecting male fertility. ([Chapter 6.6](#))

Azoospermia (ā-zō-ō-SPĚR-mē-ă): The absence of sperm in semen, often linked to infertility. ([Chapter 6.5](#))

Balanitis (băĭ-ă-NĪ-tĭs): Inflammation of the glans penis, often due to infection or irritation. ([Chapter 6.7](#))

Benign prostatic hyperplasia (bē-NĪN prōs-TĂT-ĭk hĭ-pěr-PLĀ-zhē-ă) (BPH): Noncancerous enlargement of the prostate gland. ([Chapter 6.6](#))

Bulbourethral glands (bul-bō-Ū-rĒ-thrăĭ glandz): Glands that produce a fluid that lubricates the urethra and neutralizes any acidity due to urine. ([Chapter 6.4](#))

Chemotherapy (KĒ-mō-THĒR-ă-pē): The use of drugs to destroy cancer cells, typically by stopping their ability to grow and divide. ([Chapter 6.6](#))

Chlamydia (klă-MĪD-ē-ă): A common sexually transmitted infection caused by the bacterium *Chlamydia trachomatis*. ([Chapter 6.6](#))

Circumcision (sĭr-kŭm-SIZH-ō̃n): The surgical removal of the foreskin from the penis. ([Chapter 6.4](#), [Chapter 6.7](#))

Coitus (KŌ-ĭ-tŭs): The sexual union of a male and female involving insertion of the penis into the vagina. ([Chapter 6.4](#))

Condom (KON-dŭm): A contraceptive device worn over the penis during sexual activity to prevent pregnancy and reduce the risk of STIs. ([Chapter 6.5](#))

Cryptorchidism (krip-TOR-kĭd-izm): A condition where one or both testes fail to descend into the scrotum before birth. ([Chapter 6.4](#))

Digital rectal exam (dĭj-ĭ-tăl RĚK-tăl ěgz-ăm): A manual examination of the prostate gland through the rectum to check for abnormalities. ([Chapter 6.6](#))

Ejaculation (i-jăk-yŭ-LĀ-shŏn): The discharge of semen from the male reproductive system. ([Chapter 6.5](#))

Epididymis (ep-ĭ-DID-ĭ-mĭs): A long, coiled tube attached to the back of the testis that stores and carries sperm. ([Chapter 6.4](#))

Erectile dysfunction (ě-RĚK-tĭl dis-FŬNGK-shŏn): The inability to achieve or maintain an erection sufficient for satisfactory sexual performance. ([Chapter 6.5](#), [Chapter 6.6](#))

Foreskin (FŌR-skin): The retractable fold of skin covering the end of the penis. ([Chapter 6.4](#))

Genital herpes (JEN-ĭt-ăl HUR-pĕz): A sexually transmitted infection (STI) caused by the herpes simplex virus, characterized by painful blisters in the genital area. ([Chapter 6.6](#))

Glans penis (glănz PĒ-nĭs): The bulbous tip of the penis. ([Chapter 6.4](#))

Gonorrhea (gon-ŏ-RĒ-ă): A sexually transmitted infection caused by the bacterium *Neisseria gonorrhoeae*. ([Chapter 6.6](#))

Herpes simplex virus (HUR-pĕz SĪM-pleks Vĭ-rŭs) (HSV): A virus causing contagious sores, most often around the mouth or on the genitals. ([Chapter 6.6](#))

Hormone therapy (HOR-mŏn THĚR-ă-pĕ): Treatment to alter hormone levels to slow or stop cancer cell growth. ([Chapter 6.6](#))

Human immunodeficiency virus (hu-man im-yŭ-nŏ-dĕ-FISH-ĕn-sĕ Vĭ-rŭs) (HIV): A virus that attacks the T-helper cells of the immune system. ([Chapter 6.6](#))

Human papillomavirus (hu-man PAP-ĭ-LŌ-mă-Vĭ-rŭs) (HPV): A group of viruses that can cause warts on the skin or mucous membranes and are associated with some types of cancer. ([Chapter 6.6](#))

Hydrocele (Hĭ-drō-sēl): A fluid-filled sac around a testicle, often causing swelling in the scrotum. ([Chapter 6.6](#))

Hydrocelectomy (hĭ-drō-sē-LĚK-tō-mē): Surgical removal of a hydrocele, a fluid-filled sac in the scrotum, to relieve swelling. ([Chapter 6.7](#))

Immunotherapy (ĭm-yū-nō-THĚR-ă-pē): Treatment that uses certain parts of a person's immune system to fight diseases such as cancer. ([Chapter 6.6](#))

Inguinal hernia (IN-gwĭ-năl HUR-nē-ă): A condition where part of the intestine protrudes through the inguinal canal into the scrotum. ([Chapter 6.4](#))

Inguinal orchiectomy (IN-gwĭ-năl or-kē-EK-tō-mē): Surgical removal of a testicle through an incision in the groin area. ([Chapter 6.6](#))

Libido (lĭ-BĚ-dō): Sexual desire or drive. ([Chapter 6.5](#))

Nucleic acid amplification testing (noō-klē-ĭk ĀS-ĭd ăm-plĭ-fĭ-KĀ-shŏn tĕst-ing) (NAAT): A laboratory test that increases the amount of DNA or RNA in a sample to detect the presence of specific organisms, such as bacteria or viruses. ([Chapter 6.6](#))

Open radical prostatectomy (OPEN RAD-ĭ-kăl prŌS-tă-TĚK-tō-mē): A surgical technique involving an incision to remove the prostate gland. ([Chapter 6.6](#))

Orchiectomy (or-kē-EK-tō-mē): Surgical removal of one or both testicles, often done for cancer treatment or hormone therapy. ([Chapter 6.6](#))

Orgasm (OR-găzm): The climax of sexual stimulation. ([Chapter 6.5](#))

Pelvic inflammatory disease (PĚL-vĭk ĭn-flă-MĀ-tŏr-ē dĭ-ZĚZ) (PID): A complication of STIs, such as chlamydia or gonorrhea, affecting female reproductive organs. ([Chapter 6.6](#))

Pelvic lymphadenectomy (PĚL-vĭk lim-fad-ě-NEK-tō-mē): Surgical removal of lymph nodes in the pelvis to check for cancer spread. ([Chapter 6.6](#))

Penis (PĚ-nĭs): The male organ used for urination and sexual intercourse. ([Chapter 6.4](#))

Phimosis (fĭ-MŌ-sĭs): A condition where the foreskin cannot be fully retracted over the glans penis, sometimes requiring circumcision for treatment. ([Chapter 6.7](#))

Prepuce (PRĚ-pyūs): Another term for foreskin, the skin covering the glans of the penis. ([Chapter 6.4](#))

Priapism (PRĪ-ă-pĭzm): A prolonged and often painful erection of the penis not associated with sexual desire. ([Chapter 6.5](#))

Prostate (PRŌS-tāt): A gland in the male reproductive system that produces some of the fluid in semen. ([Chapter 6.4](#))

Prostate cancer (PRŌS-tāt KAN-sěr): A form of cancer that develops in the prostate gland. ([Chapter 6.6](#))

Prostate-specific antigen (PRŌS-tāt spē-SIF-ĭk AN-tĭ-jěn) (PSA): A protein produced by the prostate gland; elevated levels may indicate prostate cancer. ([Chapter 6.6](#))

Prostatitis (prös-tă-TĪT-ĭs): Inflammation of the prostate gland, which can cause urinary problems and discomfort. ([Chapter 6.6](#))

PSMA PET scan (PSMA PĒ-Ē-TĚ skăn): An imaging test using a radioactive substance to detect prostate cancer cells by targeting PSMA protein. ([Chapter 6.6](#))

Puberty (PŪ-běr-tē): The period during which adolescents reach sexual maturity and become capable of reproduction. ([Chapter 6.5](#))

Radiation therapy (RĀ-dē-Ā-shŭn THĚR-ă-pē): Treatment using high-energy waves like X-rays to destroy cancer cells. ([Chapter 6.6](#))

Radical laparoscopic prostatectomy (RAD-ĭ-kăl lăp-ă-RŌS-kő-pĭk prŌS-tă-TĚK-tő-mē): Minimally invasive surgery using small incisions and a camera to remove the prostate. ([Chapter 6.6](#))

Radical prostatectomy (RAD-ĭ-kăl prŌS-tă-TĚK-tő-mē): Surgery to remove the entire prostate gland and some surrounding tissue. ([Chapter 6.6](#))

Radiopharmaceutical therapy (RĀ-dē-ō-far-mă-SOO-tĭ-kăl THĚR-ă-pē): Treatment using radioactive drugs to target and kill cancer cells. ([Chapter 6.6](#))

Robot-assisted laparoscopic radical prostatectomy (ROH-bot ă-SĪS-těd lăp-ă-RŌS-kő-pĭk RAD-ĭ-kăl prŌS-tă-TĚK-tő-mē): A robotic surgery method for prostate removal using laparoscopic techniques. ([Chapter 6.6](#))

Scrotum (SKRŌ-tŭm): A pouch of skin containing the testicles and part of the spermatic cord. ([Chapter 6.4](#))

Semen (SĒ-měn): The fluid that is ejaculated during orgasm, containing sperm and secretions from the male reproductive glands. ([Chapter 6.4](#))

Semen analysis (SĒ-měn ă-NĀL-ĭ-sĭs): A test to evaluate the characteristics

of a male's semen and the sperm contained therein, often used to assess fertility. ([Chapter 6.7](#))

Seminal vesicle biopsy (SEM-ĩ-năl VES-ĩ-kěl Bĩ-öp-sē): A procedure to remove fluid from seminal vesicles for cancer cell examination. ([Chapter 6.6](#))

Seminal vesicles (SEM-ĩ-năl VES-ĩ-kělz): Glandular pouches that secrete semen into the ejaculatory duct. ([Chapter 6.4](#))

Seminiferous tubules (sem-ĩ-NIF-ěr-űs TŪ-bŭls): Narrow, coiled tubules inside the testes where sperm are produced. ([Chapter 6.4](#))

Sexually transmitted disease (SEKS-ű-ă-lē trăns-MĪT-ed dĩ-ZĒZ) (STD): Diseases that are primarily transmitted through sexual activity. ([Chapter 6.6](#))

Sexually transmitted infection (SEKS-ű-ă-lē trăns-MĪT-ed ĩn-FĚK-shŏn) (STI): Infections typically spread through sexual contact. ([Chapter 6.6](#))

Sperm (SPURM): Male reproductive cells involved in sexual reproduction. ([Chapter 6.5](#))

Spermatic cord (spur-MAT-ĩk KORD): A bundle of nerves, ducts, and blood vessels connecting the testicles to the abdominal cavity. ([Chapter 6.4](#))

Spermatocele (spěr-MĀT-ŏ-sēl): A fluid-filled cyst in the epididymis, often painless and found near the testicles. ([Chapter 6.6](#))

Spermatogenesis (spur-mă-tŏ-JĚN-ě-sĩs): The process of sperm cell development. ([Chapter 6.5](#))

Sterilization (ster-ĩ-lĩ-ZĀ-shŭn): A permanent method of contraception that prevents pregnancy in women and the release of sperm in men. ([Chapter 6.7](#))

Syphilis (SIF-ĩ-lĩs): A sexually transmitted infection caused by the bacterium *Treponema pallidum*, characterized by various stages including sores, rashes, and potentially serious systemic effects if untreated. ([Chapter 6.6](#))

Targeted therapy (TAR-gět-ed THĚR-ă-pē): Cancer treatment that uses drugs to target specific genes and proteins involved in the growth and survival of cancer cells. ([Chapter 6.6](#))

Testes (TĚS-tēz): The male reproductive organs that produce sperm and testosterone. ([Chapter 6.4](#))

Testicular cancer (tēs-TĪK-ű-lăr KAN-sěr): Cancer that originates in the testicles, typically diagnosed in younger men. ([Chapter 6.6](#))

Testicular torsion (tēs-TĪK-ű-lăr TOR-shŏn): A medical emergency where

the spermatic cord becomes twisted, cutting off blood supply to the testicle. ([Chapter 6.6](#))

Testosterone (těs-TOS-tě-rōn): A primary male sex hormone responsible for the development of male secondary sexual characteristics. ([Chapter 6.5](#))

Torsion (TOR-shōn): The twisting of the spermatic cord, which can cut off blood supply to the testicle. ([Chapter 6.4](#))

Transrectal biopsy (trans-RĚK-tāl BĪ-öp-sē): Tissue sample removal from the prostate via the rectum for cancer testing. ([Chapter 6.6](#))

Transrectal MRI (trans-RĚK-tāl ěm-ĀR-ĀĪ): Magnetic resonance imaging of the prostate gland through the rectum. ([Chapter 6.6](#))

Transrectal MRI guided biopsy (trăns-RĚK-tāl MRĪ GĪ-ded BĪ-öp-sē): A procedure that uses magnetic resonance imaging (MRI) to guide the removal of tissue samples from the prostate through the rectum. ([Chapter 6.6](#))

Transrectal ultrasound (trans-RĚK-tāl ŮL-tră-sound): A diagnostic procedure using ultrasound inserted through the rectum to visualize the prostate. ([Chapter 6.6](#))

Transrectal ultrasound guided biopsy (trăns-RĚK-tāl ŮL-tră-sound GĪ-ded BĪ-öp-sē): A procedure in which a probe inserted into the rectum uses ultrasound to guide the removal of tissue samples from the prostate for analysis. ([Chapter 6.6](#))

Transurethral (trans-ŭ-RĚ-thrăl): Pertaining to going through or across the urethra. ([Chapter 6.6](#))

Transurethral incision of the prostate (trans-ŭ-RĚ-thrăl in-SIZH-ŭn ōv thě PRŌS-tăt) (TUIP): A surgical procedure to make incisions in the prostate gland to treat urinary problems due to BPH. ([Chapter 6.6](#))

Transurethral microwave thermotherapy (trans-ŭ-RĚ-thrăl MĪ-krō-wāv THUR-mō-THĚR-ă-pē) (TUMT): A treatment for BPH using microwave energy to reduce prostate size. ([Chapter 6.6](#))

Transurethral resection of the prostate (trans-ŭ-RĚ-thrăl rĭ-SĚK-shŭn ōv thě PRŌS-tăt) (TURP): A surgical procedure to remove part of the prostate gland to relieve urinary symptoms caused by an enlarged prostate. ([Chapter 6.6](#))

Trichomoniasis (trĭk-ō-mō-NĪ-ă-sĭs): A common sexually transmitted

infection caused by a protozoan parasite, often resulting in vaginal or urethral discharge. ([Chapter 6.6](#))

Urologist (yū-RŌL-ŏ-jĭst): A physician who specializes in the treatment of disorders of the urinary system and male reproductive system. ([Chapter 6.7](#))

Urology (yū-RŌL-ŏ-jē): Study of the male and female urinary tract systems and the male reproductive system. ([Chapter 6.7](#))

Varicocele (VAR-ĭ-kō-sēl): An enlargement of the veins within the scrotum, often associated with infertility. ([Chapter 6.6](#))

Vas deferens (VĀS DEF-ĕr-ĕnz): The duct that conveys sperm from the testicle to the urethra. ([Chapter 6.4](#))

Vasectomy (vă-SEK-tō-mē): A surgical procedure for male sterilization involving the cutting and sealing of part of each vas deferens. ([Chapter 6.4](#), [Chapter 6.7](#))

PART VII

CHAPTER 7 FEMALE REPRODUCTIVE SYSTEM TERMINOLOGY

7.1 Female Reproductive System Introduction

Learning Objectives

- Apply the rules of medical language to build, analyze, spell, pronounce, abbreviate, and define terms as they relate to the female reproductive system
- Identify meanings of keyword components of the female reproductive system
- Categorize diagnostic, therapeutic, procedural, or anatomic terms related to the female reproductive system
- Use terms related to the female reproductive system
- Use terms related to the diseases and disorders of the female reproductive system

Introduction to the Female Reproductive System

The female reproductive system produces hormones and matures eggs (called ova) during the monthly menstrual cycle. Every month, an egg (called an ovum) is released from one of the female's ovaries with the potential to become fertilized by male sperm. If fertilization occurs, female hormones develop the fertilized egg into a fetus and, ultimately, a baby ready for delivery in about 40 weeks.

This chapter will review common word components related to the female reproductive system to assist learning how to analyze, build, and define

medical terms. Other female reproductive terms, whose definitions cannot be easily built from word components, will be described in context based on the anatomy and physiology of the female reproductive system and common diseases and disorders. Medical specialists, diagnostic tests, and procedures related to the female reproductive system will also be discussed. Additional information about pregnancy will be discussed in the “[Obstetrics Terminology](#)” chapter.



View the following YouTube video¹ on the anatomy and physiology of the female reproductive system:
[Reproductive System, Part 1 – Female Reproductive System: Crash Course A&P #40](#)

1. CrashCourse. (2015, October 26). *Reproductive system, Part 1 – Female reproductive system: Crash Course Anatomy & Physiology #40* [Video]. YouTube. <https://youtu.be/RFDatCchpus?si=1h92ZbG3QUjVHw6b>

7.2 Word Components Related to the Female Reproductive System

This section will describe common word components related to the female reproductive system. These word components help build definitions for many medical terms. Other common prefixes are described in [Chapter 1.3](#), and common suffixes are described in [Chapter 1.5](#).

COMMON PREFIXES RELATED TO THE FEMALE REPRODUCTIVE SYSTEM

- **a-**: Absence of, without
- **an-**: Absence of, without
- **dys-**: Painful, difficult, abnormal, labored
- **endo-**: Within
- **oligo-**: Small amount
- **peri-**: Surrounding

COMMON WORD ROOTS WITH A COMBINING VOWEL RELATED TO THE FEMALE REPRODUCTIVE SYSTEM

- **arche/o**: First, beginning
- **cervic/o**: Cervix
- **colp/o**: Vagina
- **endometri/o**: Endometrium
- **episi/o**: Vulva
- **gyn/o**: Woman
- **gynec/o**: Woman
- **hemat/o**: Blood
- **hymen/o**: Hymen
- **hyster/o**: Uterus
- **leuk/o**: White
- **mamm/o**: Breast
- **mast/o**: Breast
- **men/o**: Menstruation
- **metr/i**: Uterus
- **my/o**: Muscle
- **oophor/o**: Ovary
- **pelv/i**: Pelvis, pelvic bones, pelvic cavity
- **perine/o**: Perineum
- **py/o**: Pus
- **salping/o**: Uterine tube, fallopian tube
- **son/o**: Sound waves
- **trachel/o**: Cervix
- **vagin/o**: Vagina
- **vulv/o**: Vulva

COMMON SUFFIXES RELATED TO THE FEMALE REPRODUCTIVE SYSTEM

- **-al**: Pertaining to
- **-atresia**: Occlusion, closure
- **-cleisis**: Surgical closure
- **-ectomy**: Excision, surgical removal
- **-gram**: The record, radiographic image
- **-graphy**: Process of recording, radiographic imaging
- **-itis**: Inflammation
- **-logist**: Specialist who studies and treats
- **-logy**: Study of
- **-osis**: Abnormal condition
- **-pexy**: Surgical fixation, suspension
- **-plasty**: Surgical repair
- **-rrhagia**: Rapid flow of blood
- **-rrhaphy**: Suturing, repairing
- **-rrhea**: Flow, discharge
- **-salpinx**: Uterine (fallopian) tube
- **-scope**: Instrument used for visual examination
- **-scopy**: Visually examining
- **-tomy**: Cut into, incision

7.3 Examples of Female Reproductive System Terms Easily Defined By Their Word Components

Here are examples of common medical terms related to the female reproductive system that can be easily defined by breaking the terms into their word components.

Amenorrhea

1. Break down the medical term into word components:
A/men/o/rrhea
2. Label the word components: **A** = P; **men** = WR; **o** = CV;
rrhea = S
3. Define the word components: **A** = absence of; **men** = menstruation; **rrhea** = flow
4. Create a final definition of the medical term: **Absence of menstrual flow**

Colposcopy

1. Break down the medical term into word components:

Colp/o/scopy

2. Label the word components: **Colp** = WR; **o** = CV; **scopy** = S
3. Define the word components: **Colp** = vagina; **scopy** = visual examination
4. Create a final definition of the medical term: **Visual examination of the vagina**

Gynecologist

1. Break down the medical term into word components:
Gynec/o/logist
2. Label the word components: **Gynec** = WR; **o** = CV; **logist** = S
3. Define the word components: **gynec** = women; **logist** = specialist who studies and treats
4. Create a final definition of the medical term: **Specialist who studies and treats female disorders and diseases**



Interactive Learning Activity: Practice defining and pronouncing female reproductive system medical terms by breaking them down into word parts.



An interactive H5P element has been excluded from this version of the text. You can view it online here:

<https://wtcs.pressbooks.pub/medterm/?p=3753#h5p-29>

- ▶ You can also print this as a [Chapter 7 Student Companion Worksheet](#) and check your answers with this [Answer Key](#).

7.4 Anatomy of the Female Reproductive System

Anatomy of the female reproductive system includes the external genitals, the internal reproductive system, and the breasts.

EXTERNAL FEMALE GENITALS

See Figure 7.1¹ for an illustration of the external female genitals. The external female reproductive structures, referred to collectively as the **vulva** (VŬL-vă), include the following²:

- The **mons pubis** (MÖNZ PYŬ-bĭs) is a pad of fat that is located anteriorly over the pubic bone. After puberty, it becomes covered in pubic hair.
- The **labia majora** (LĀ-bē-uh MĀ-jör-uh) are larger outer folds of hair-covered skin that begin just posterior to the mons pubis.
- The **labia minora** (LĀ-bē-uh mĭ-NÖR-uh) are thinner, hairless, and more pigmented folds found medially to the labia majora.
 - Although they naturally vary in shape and size from woman to woman, the labia minora serve to protect the female urethra and the entrance to the female reproductive tract.

1. "[Vulva_Figure_28_02_02.jpg](#)" by OpenStax College is licensed under [CC BY 3.0](#)

2. [Anatomy & Physiology](#) by [OpenStax](#) is licensed under [CC BY 4.0](#). Access for free at <https://openstax.org/books/anatomy-and-physiology/pages/1-introduction>

- The superior, anterior portions of the labia minora come together to encircle the **clitoris** (KLĪT-ō-rĭs). The clitoris is erectile tissue that originates from the same fetal cells as the penis and has abundant nerves that are important in sexual sensation and orgasm.
- The vestibule is the area between the labia minora and behind the clitoris that contains the urethral and vaginal openings. It is flanked by outlets to the vestibular glands, also known as **Bartholin's glands** (BAR-tō-lĭns glăns), that secrete mucus to keep the vestibular area moist. Read more about the urethra in the "[Anatomy of the Urinary System](#)" section in the "Urinary System Terminology" chapter.
- The **perineum** (pěr-ĭ-NĒ-um) is the area between the vaginal opening and the anus.
-

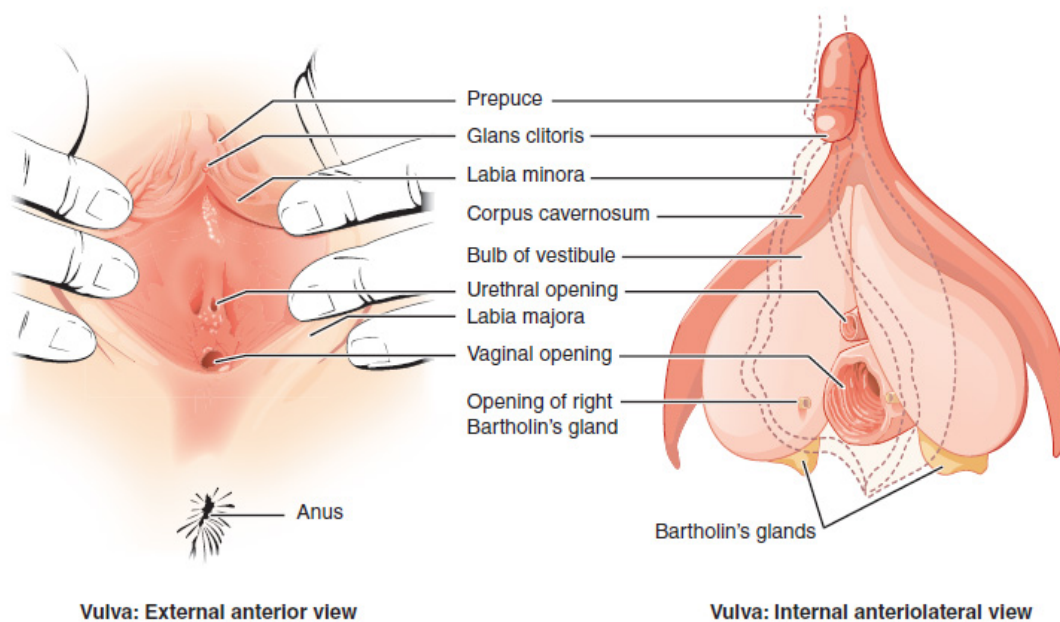


Figure 7.1 Vulva, Collective Term for External Female Genitalia

INTERNAL FEMALE REPRODUCTIVE ORGANS

The internal female reproductive organs include the vagina, uterus, cervix, ovaries, and Fallopian tubes. See Figure 7.2³ for an illustration of the internal and external structures of the female reproductive system.

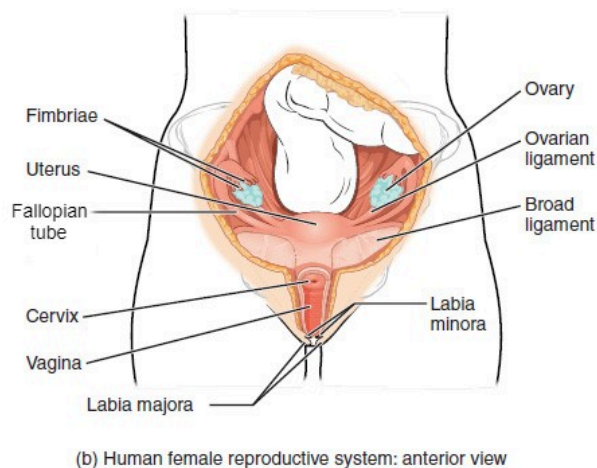
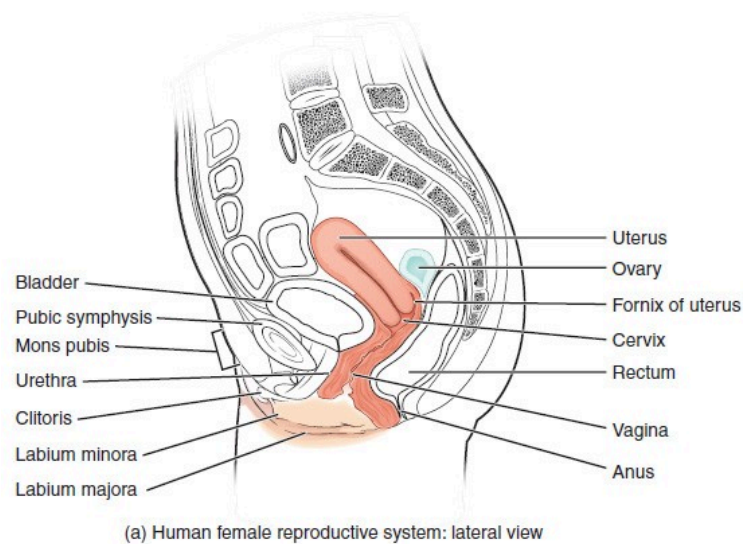


Figure 7.2 Female Reproductive System

3. This image is derivative of “[Figure_28_02_01.JPG](#)” by OpenStax College is licensed under [CC BY 3.0](#)

Vagina

The **vagina** (vă-JĪN-uh) is a muscular canal that is approximately ten centimeters (cm) long. It serves as the entrance to the reproductive tract, as well as the exit from the uterus during menstruation and childbirth.⁴

The vagina is composed of smooth muscle that allows for expansion during intercourse and childbirth. The vagina is lined with mucous membranes that secrete mucus to keep it moist. The superior portion of the vagina meets the cervix (the opening and lower part of the uterus). The inferior portion of the vagina may have a thin, perforated hymen that partially surrounds the opening to the vagina.⁵

The vagina contains a normal population of healthy bacteria called normal flora that help protect against infection. In a healthy woman, the most common type of normal flora is *Lactobacillus* that secretes lactic acid. The lactic acid protects the vagina by maintaining an acidic pH (below 4.5). Lactic acid, in combination with other vaginal secretions, makes the vagina a self-cleansing organ. However, douching can disrupt the normal balance of healthy microorganisms and increase a woman's risk for infections and irritation. It is recommended that women do not douche and that they allow the vagina to maintain its normal healthy population of protective normal flora.⁶

4. [Anatomy & Physiology](https://openstax.org/books/anatomy-and-physiology/pages/1-introduction) by [OpenStax](https://openstax.org) is licensed under [CC BY 4.0](https://creativecommons.org/licenses/by/4.0/). Access for free at <https://openstax.org/books/anatomy-and-physiology/pages/1-introduction>

5. [Anatomy & Physiology](https://openstax.org/books/anatomy-and-physiology/pages/1-introduction) by [OpenStax](https://openstax.org) is licensed under [CC BY 4.0](https://creativecommons.org/licenses/by/4.0/). Access for free at <https://openstax.org/books/anatomy-and-physiology/pages/1-introduction>

6. [Anatomy & Physiology](https://openstax.org/books/anatomy-and-physiology/pages/1-introduction) by [OpenStax](https://openstax.org) is licensed under [CC BY 4.0](https://creativecommons.org/licenses/by/4.0/). Access for free at <https://openstax.org/books/anatomy-and-physiology/pages/1-introduction>

Uterus and Cervix

The **uterus** (YŪ-těr-us) is a muscular, pear-shaped organ that is approximately five cm wide by seven cm long. It is composed of three sections⁷:

- The inferior portion, called the **cervix** (SĚR-vĭks), connects the uterus and the vagina.
- The middle section of the uterus is called the corpus (body of the uterus).
- The superior portion is called the fundus.

An opening in the middle of the cervix allows menstrual blood to exit and sperm to enter the uterus. The cervix dilates (opens) during childbirth to allow the baby to exit the mother's body. The corpus of the uterus expands during pregnancy. The fundus is the location of the uterus that is commonly felt by the health care provider during prenatal exams to indirectly measure the growth of the fetus.⁸

The wall of the uterus is made up of these three layers⁹:

- **Perimetrium** (pār-ĭ-MĒ-trē-um): The serous membrane surrounding the uterus.
- **Myometrium** (my-ō-MĒ-trē-um): A thick layer of smooth muscle responsible for uterine contractions.

7. [Anatomy & Physiology](https://openstax.org/books/anatomy-and-physiology/pages/1-introduction) by [OpenStax](https://openstax.org) is licensed under [CC BY 4.0](https://creativecommons.org/licenses/by/4.0/). Access for free at <https://openstax.org/books/anatomy-and-physiology/pages/1-introduction>

8. [Anatomy & Physiology](https://openstax.org/books/anatomy-and-physiology/pages/1-introduction) by [OpenStax](https://openstax.org) is licensed under [CC BY 4.0](https://creativecommons.org/licenses/by/4.0/). Access for free at <https://openstax.org/books/anatomy-and-physiology/pages/1-introduction>

9. [Anatomy & Physiology](https://openstax.org/books/anatomy-and-physiology/pages/1-introduction) by [OpenStax](https://openstax.org) is licensed under [CC BY 4.0](https://creativecommons.org/licenses/by/4.0/). Access for free at <https://openstax.org/books/anatomy-and-physiology/pages/1-introduction>

- **Endometrium** (en-dō-MĒ-trē-um): The innermost layer that provides the site for implantation of a fertilized egg or sheds during menstruation if an egg is not fertilized.

Ovaries

The **ovary** (Ō-vār-ē) is the female reproductive gland located in the pelvic cavity. There are two ovaries, one at the entrance to each Fallopian tube, which are attached to the uterus via the ovarian ligaments. The ovaries create oocytes (eggs) and hormones.¹⁰

Fallopian Tubes

The **Fallopian** (fă-LŌP-ē-an) **tubes** transport oocytes from the ovary to the uterus. Each of the Fallopian tubes is close to, but not directly connected to, the ovary, so the **fimbriae** (FĭM-brē-ē) catch the oocyte like a baseball in a glove. The middle region of the Fallopian tube, called the ampulla, is where fertilization often occurs. The fertilized egg then moves from the Fallopian tube into the uterus, where it implants into the endometrium.¹¹

BREASTS

Although the breasts are located far from the other reproductive organs, they are considered accessory organs of the female reproductive system. The

10. [Anatomy & Physiology](https://openstax.org/books/anatomy-and-physiology/pages/1-introduction) by [OpenStax](https://openstax.org) is licensed under [CC BY 4.0](https://creativecommons.org/licenses/by/4.0/). Access for free at <https://openstax.org/books/anatomy-and-physiology/pages/1-introduction>

11. [Anatomy & Physiology](https://openstax.org/books/anatomy-and-physiology/pages/1-introduction) by [OpenStax](https://openstax.org) is licensed under [CC BY 4.0](https://creativecommons.org/licenses/by/4.0/). Access for free at <https://openstax.org/books/anatomy-and-physiology/pages/1-introduction>

function of female breasts is to supply milk to an infant in a process called **lactation** (lak-TĀ-shŏn).¹²

The external features of the breast include a nipple surrounded by a pigmented areola. The areolar region is characterized by small, raised areolar glands that secrete lubricating fluid during lactation to protect the nipple from chafing. When a baby nurses (i.e., draws milk from the breast), the entire areolar region is taken into their mouth.¹³

A breast is made up of three main parts: lobules, ducts, and connective tissue. The lobules are the mammary glands composed of alveoli (tiny sacs) that produce milk. The **lactiferous** (lak-TĪF-ěr-us) **ducts** are tubes that carry milk to the nipple. The connective tissue (which consists of fibrous and fatty tissue) surrounds and holds everything together.¹⁴

An infant can draw milk from the lobules and through the ducts and the nipple by suckling. Alveoli are surrounded by fat tissue, which determines the size of the breast. Breast size differs between individuals and does not affect

12. *Anatomy & Physiology* by OpenStax is licensed under CC BY 4.0. Access for free at <https://openstax.org/books/anatomy-and-physiology/pages/1-introduction>

13. *Anatomy & Physiology* by OpenStax is licensed under CC BY 4.0. Access for free at <https://openstax.org/books/anatomy-and-physiology/pages/1-introduction>

14. Centers for Disease Control and Prevention. (2023, July 25). *What is breast cancer?* https://www.cdc.gov/cancer/breast/basic_info/what-is-breast-cancer.htm

the amount of milk produced.¹⁵ See Figure 7.3¹⁶ for an illustration of a breast and milk flow.

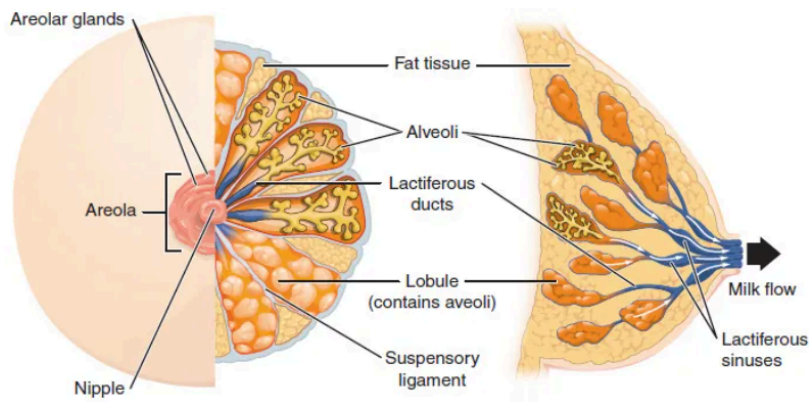


Figure 7.3 Breast and Milk Flow

Some women have **fibrocystic breasts** (fī-brō-SĭS-tĭk breasts) with connective tissue that feels lumpy or ropelike in texture. Fibrocystic breast changes are common and no longer considered a disease, although it was formerly referred to as fibrocystic breast disease. Some women also experience breast pain, tenderness, and lumpiness, especially in the upper, outer areas of the breasts, just before menstruation.¹⁷

15. *Anatomy & Physiology* by OpenStax is licensed under CC BY 4.0. Access for free at <https://openstax.org/books/anatomy-and-physiology/pages/1-introduction>
16. “Anatomy_of_the_breast” by OpenStax is licensed under CC BY 4.0. Access for free at <https://openstax.org/books/anatomy-and-physiology/pages/1-introduction>
17. Mayo Clinic. (2023, April 4). *Fibrocystic breasts*. <https://www.mayoclinic.org/diseases-conditions/fibrocystic-breasts/symptoms-causes/syc-20350438>

7.5 Physiology of the Female Reproductive System

Menstruation (men-strĪ-Ā-shŏn), also called menses, commonly referred to as a woman's "period," is vaginal bleeding that occurs as part of a monthly cycle. Every month, the female body prepares for possible pregnancy. If no pregnancy occurs, the uterus sheds the endometrial lining. Menstrual flow is part blood and part endometrial lining that passes out of the uterus, through the cervix, and into the vagina. Menstruation typically starts in females between the ages of 11 and 14 and continues until menopause at an average age of 51. In addition to bleeding, females may experience additional emotional and physical symptoms, which is referred to as premenstrual syndrome (PMS).¹ Premenstrual syndrome (PMS) is discussed in more detail in the "[Diseases and Disorders of the Female Reproductive System](#)" section of this chapter.

THE MENSTRUAL CYCLE

The menstrual cycle is driven by a monthly hormonal cycle as the female's body prepares an egg for fertilization and possible pregnancy. The menstrual cycle is counted from the first day of a bleeding of one cycle to the first day of

1. [Anatomy & Physiology](#) by [OpenStax](#) is licensed under [CC BY 4.0](#). Access for free at <https://openstax.org/books/anatomy-and-physiology/pages/1-introduction>

the next menstrual cycle. Menstrual flow usually lasts about three to five days. The typical volume of blood lost during menstruation is approximately 30 milliliters (mL). Amounts greater than 80 mL, menstrual flow longer than five days, or bleeding between cycles can be symptoms of a disorder.²

The average menstrual cycle takes about 28 days and occurs in three phases, called the follicular, ovulatory, and luteal phases, also referred to as menses, proliferative, and secretory uterine cycles. Hormone levels change throughout the menstrual cycle. See Figure 7.4 for an illustration of the phases of the menstrual cycle.³

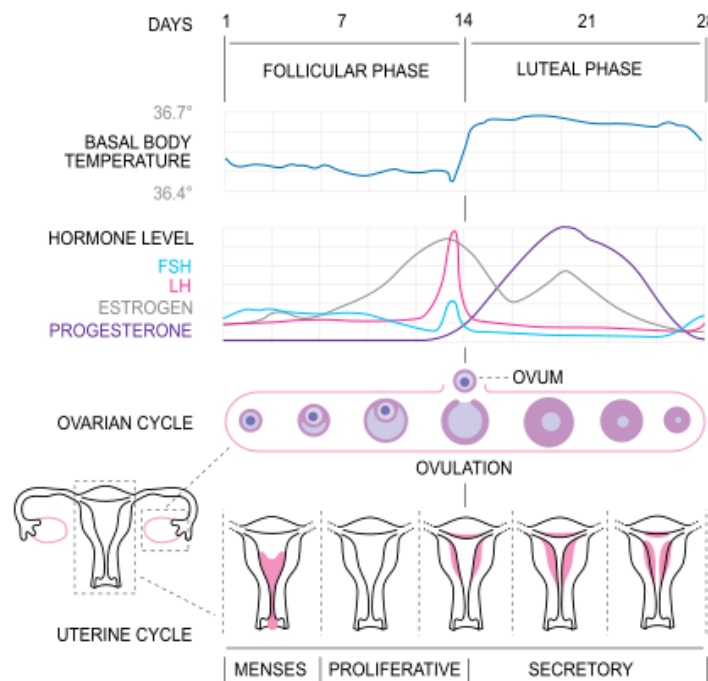


Figure 7.4 Phases of the Menstrual Cycle

2. [Anatomy & Physiology](https://openstax.org/books/anatomy-and-physiology/pages/1-introduction) by [OpenStax](https://openstax.org/books/anatomy-and-physiology/pages/1-introduction) is licensed under [CC BY 4.0](https://creativecommons.org/licenses/by/4.0/). Access for free at <https://openstax.org/books/anatomy-and-physiology/pages/1-introduction>

3. [“MenstrualCycle2_en.svg.png”](#) by [Isometrik](#) is licensed under [CC BY 3.0](https://creativecommons.org/licenses/by/3.0/)

Follicular Phase

The **follicular phase** (Föl-ĭk-yŭ-lăř fāz), also referred to as the pre-ovulatory or proliferative phase, begins when menstrual flow ceases and the endometrium in the uterus begins to thicken. During the follicular phase of the menstrual cycle, the following events occur⁴:

- Two hormones, **follicle stimulating hormone** (FŌL-ĭ-kl stim-YŪ-lā-ting HŌR-mŏn) (**FSH**) and **luteinizing hormone** (LŪ-tē-ĭ-nīz-ĭng HŌR-mŏn) (**LH**), are released from the brain and travel in the blood to the ovaries. These hormones stimulate the growth of ova (eggs) in their own shells called **follicles** (FŌL-ĭ-klz).
- The FSH and LH hormones also trigger an increase in the production of the hormone **estrogen** (ĔS-trŏ-jen), which is produced by the developing follicles. As the estrogen level continues to rise, it turns off the production of FSH, like a switch. This careful balance of hormones allows the body to limit the number of follicles to be released.
- As the follicular phase progresses, one follicle in one ovary becomes dominant and continues to mature. This dominant follicle, called the Graafian follicle, suppresses the growth of all other follicles. In addition, this dominant follicle continues to produce estrogen.

Ovulatory Phase

The ovulatory phase usually starts about 14 days after the follicular phase began. During this phase, the following events occur⁵:

- The rise in estrogen from the Graafian (dominant) follicle triggers a surge in the amount of luteinizing hormone (LH) produced by the brain. This

4. Cleveland Clinic. (2022, November 28). *Female reproductive system*.
<https://my.clevelandclinic.org/health/articles/9118-female-reproductive-system>

5. Cleveland Clinic. (2022, November 28). *Female reproductive system*.
<https://my.clevelandclinic.org/health/articles/9118-female-reproductive-system>

surge causes the Graafian (dominant) follicle to release the **ovum** (Ō-vum).

- When the ovum is released from the follicle, it is referred to as **ovulation** (ov-yŭ-LĀ-shŏn). The ovum is captured by the **fimbriae** (FĭM-brē-ā), the finger-like projections on the end of the Fallopian tubes. The fimbriae sweep the egg into the Fallopian tube.
- For one to five days prior to ovulation, many women notice an increase in cervical mucus that looks like egg white. This mucus helps capture and nourish the sperm on the way to meet the egg for fertilization.

Luteal Phase

The luteal (postovulatory) phase begins right after ovulation and involves the following processes⁶:

- After the ovum is released, the empty follicle develops into a new structure called the corpus luteum. The **corpus luteum** (KŌR-pus LŪ-tē-um) is a temporary, hormone-producing gland involved in ovulation and early pregnancy.
- The corpus luteum secretes estrogen and **progesterone** (pro-JĔS-tĕr-ŏn). Progesterone prepares the uterus for **implantation** (ĭm-plan-TĀ-shŏn) of a fertilized egg into the uterine lining and is an important hormone during pregnancy.
- If the egg becomes fertilized by sperm, which is referred to as **conception** (kŏn-sĕp-shŏn), it is referred to as an **embryo** (Ĕm-brē-ō). The embryo travels through the Fallopian tubes and implants in the endometrial lining of the uterus.
- If the egg isn't fertilized, it dissolves in the uterus, the endometrial lining breaks down and sheds because it is no longer needed, and menses (bleeding) begins. This is also referred to as the menses or menstrual phase and lasts between 3-5 days. See Figure 7.5⁷ for an illustration of the

6. Cleveland Clinic. (2022, November 28). *Female reproductive system*.
<https://my.clevelandclinic.org/health/articles/9118-female-reproductive-system>

progression of a follicle to a corpus luteum.

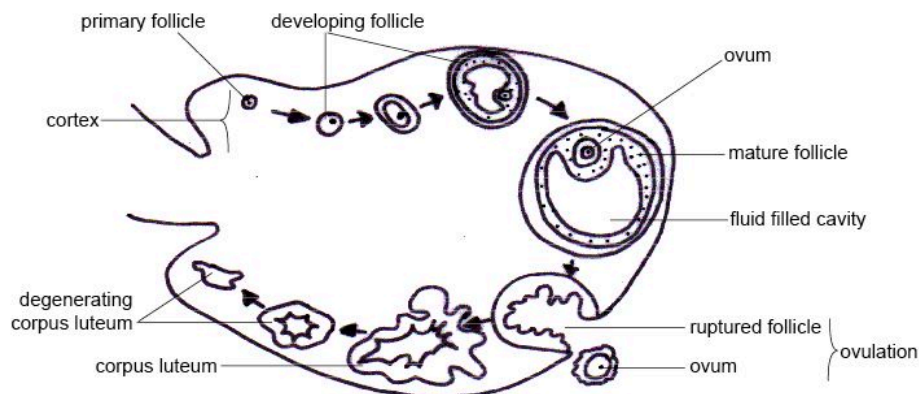


Figure 7.5 Progression from Oocyte to Degenerating Corpus Luteum



View a supplementary MedLine video⁸ on ovulation:
[Ovulation Video](#)

Fertilization, pregnancy, and contraception are discussed in the “[Obstetrics Terminology](#)” chapter.

7. “[Anatomy and physiology of animals Ovarian cycle showing from top left clockwise.jpg](#)” by [Sunshineconnelly](#) at [English Wikibooks](#) is licensed under [CC BY 3.0](#)

8. A.D.A.M. (2022, January 10). *Ovulation* [Video]. Medline Plus.
<https://medlineplus.gov/ency/anatomyvideos/000094.htm>

OTHER MEDICAL TERMS RELATED TO THE FEMALE REPRODUCTIVE SYSTEM

- **Adnexa** (ăd-NĚK-să): Accessory structures of the uterus, such as the Fallopian tubes and ovaries.
- **Amenorrhea** (ā-men-ŏ-RĒ-ă): Absence of menstrual flow.
- **Anovulation** (an-ov-yŭ-LĀ-shŏn): Absence of ovulation.
- **Contraception** (kon-tră-SEP-shŏn): Intentional prevention of pregnancy.
- **Dysmenorrhea** (dis-men-ŏ-RĒ-ă): Painful menstrual flow.
- **Dyspareunia** (dis-pă-RŪ-nĕ-ă): Painful sexual intercourse.
- **Fistula** (FIS-chŭ-lă): An abnormal passageway between two organs or an internal organ and the body surface. Although uncommon, a vaginal fistula can develop between the vagina and another organ, such as the urinary bladder, colon, or rectum.
- **Infertility** (ĭn-fĕr-TĪL-ĭ-tĕ): The inability to conceive.
- **Mastitis** (mas-TĪT-ĭs): Inflammation of the breast that tends to occur when a woman is lactating.
- **Menorrhagia** (mĕn-ŏ-RĀ-jĕ-ă): Excessive menstrual bleeding.
- **Menometrorrhagia** (mĕn-ŏ-mĕt-rŏ-RĀ-jĕ-ă): Excessive and prolonged uterine bleeding occurring at irregular and/or frequent intervals.
- **Metrorrhagia** (mĕ-trŏ-RĀ-jă): Bleeding from the uterus between menstrual periods.
- **Menarche** (mĕn-ĂR-kĕ): The first occurrence of menstruation.
- **Oligomenorrhea** (ŏl-ĭ-gŏ-mĕn-ŏ-RĒ-ă): Infrequent or very light menstruation.
- **Polymenorrhea** (pŏl-ĕ-mĕn-ŏ-RĒ-ă): Frequent menstruation in which menstrual cycles are shorter than 21 days in length.
- **Sexual intercourse** (Sĕk-shŭ-ăĭ ĭn-tĕr-kŏrs): Sexual contact between individuals that includes insertion of a penis into a vagina.
- **Tubal ligation** (TOO-băĭ lĭ-GĀ-shŏn): Surgical closure or blocking of the Fallopian tubes to prevent pregnancy; also referred to as sterilization.

7.6 Diseases and Disorders of the Female Reproductive System

ABNORMAL VAGINAL BLEEDING

Abnormal vaginal bleeding (ăb-nŏr-măl vă-jĭ-năl blēd-ing) refers to very heavy menstrual flow during menses, bleeding between menstrual cycles, or menses that lasts more than seven days. It also refers to bleeding that happens before puberty or after menopause. Very heavy bleeding during menses and/or bleeding that lasts more than seven days is called **menorrhagia** (mĕn-ō-RĀ-jē-ă). For example, women with menorrhagia may bleed enough to soak through one or more tampons or sanitary pads every hour.¹

A common cause of abnormal bleeding is hormone imbalance referred to **dysfunctional uterine bleeding** (dĭs-fŭnk-shŭn-ăl yŪ-tĕr-ĭn blēd-ing). Dysfunctional uterine bleeding commonly occurs in teenagers or women approaching **menopause** (MEN-ŏ-poz) or the absence of menstruation when an egg is not released from the ovaries as it should (anovulation). Anovulation is a common condition for teenagers who recently started their menstrual cycles, as well as for women approaching menopause. When anovulation occurs, extended estrogen release causes the endometrial lining of the uterus

1. Family Doctor. (2023, June). *Abnormal uterine bleeding*. American Academy of Family Physicians. <https://familydoctor.org/condition/abnormal-uterine-bleeding>

to continue to grow until it gets too thick. When this thickened lining is shed during menstruation, it causes the bleeding to be very heavy. A hormonal imbalance can also cause the body not to know when to shed the lining, causing **irregular bleeding** (ĩ-rĕg-yŭ-lăř blĕd-ing) or “spotting” between periods.²

Abnormal vaginal bleeding can also be caused by uterine fibroids (benign growths in the uterus), conditions related to pregnancy, and cancer of the uterus or cervix. Diagnostic testing includes pelvic ultrasounds and procedures such as endometrial biopsy or hysteroscopy. Treatment is based on the cause of the abnormal bleeding and may include medications, dilation and curettage (D&C), endometrial ablation, or hysterectomy.³ **Endometrial ablation** (en-dō-MĒ-trĕ-ăl ă-BLĀ-shŏn) is a procedure that destroys the endometrial lining of the uterus to reduce or stop heavy menstrual bleeding. D&C and hysterectomies are further discussed in the “[Medical Specialists, Diagnostic Testing, and Procedures Related to the Female Reproductive System](#)” section of this chapter.

Medications and medication-secreting devices used to treat dysfunctional uterine bleeding are birth control pills and **intrauterine devices** (ĩN-tră-yŭ-tĕr-ĕn dī-VĪS-ĭz) (**IUDs**). An IUD is a small, T-shaped device that typically contains hormones to prevent ovulation and the thickening of endometrial lining and prevent pregnancy. It is inserted through the cervix by a health care provider. Birth control pills contain hormones that prevent pregnancy by preventing the thickening of the endometrial lining. They can also help keep the menstrual cycle regular and reduce cramping during menstruation.

2. Family Doctor. (2023, June). *Abnormal uterine bleeding*. American Academy of Family Physicians. <https://familydoctor.org/condition/abnormal-uterine-bleeding>
3. Family Doctor. (2023, June). *Abnormal uterine bleeding*. American Academy of Family Physicians. <https://familydoctor.org/condition/abnormal-uterine-bleeding>

However, some types of birth control pills, especially the progestin-only pill, can cause abnormal bleeding.⁴

CANCER

Common cancers affecting the female reproductive system include breast, cervical, ovarian, and endometrial.

Breast Cancer

Breast cancer (brest KAN-sĕr) occurs when breast cells mutate and become cancerous cells that multiply and form tumors. There are different kinds of breast cancer, depending on which cells in the breast turn into cancer. Most breast cancers begin in the ducts (called invasive ductal carcinoma) or lobules (called invasive lobular carcinoma). There are also other kinds of breast cancer. Breast cancer can spread outside the breast to other parts of the body through blood and lymph vessels. When breast cancer spreads to other parts of the body, it is said to have **metastasized** (mě-tăs-tă-sīzd).⁵

People of both genders who have a strong family history of breast cancer or inherited changes in BRCA1 and BRCA2 genes have a high risk of getting

4. Family Doctor. (2023, June). *Abnormal uterine bleeding*. American Academy of Family Physicians. <https://familydoctor.org/condition/abnormal-uterine-bleeding>
5. Centers for Disease Control and Prevention. (2023, July 25). *What is breast cancer?* https://www.cdc.gov/cancer/breast/basic_info/what-is-breast-cancer.htm

breast cancer. See Figure 7.6⁶ for an illustration of signs of breast cancer. Warning signs of breast cancer include the following⁷:

- New lump in the breast or armpit.
- Thickening or swelling of part of the breast.
- Irritation or dimpling of breast skin.
- Redness or flaky skin in the nipple area or the breast.
- Pulling in of the nipple or pain in the nipple area.
- Nipple discharge other than breast milk, including blood.
- Any change in the size or the shape of the breast.
- Pain in any area of the breast.

6. “En_Breast_cancer_illustrations.png” by [Morning2k](#) for the [National Institutes of Health](#) is licensed in the [Public Domain](#).

7. Centers for Disease Control and Prevention. (2023, July 25). *What is breast cancer?* https://www.cdc.gov/cancer/breast/basic_info/what-is-breast-cancer.htm

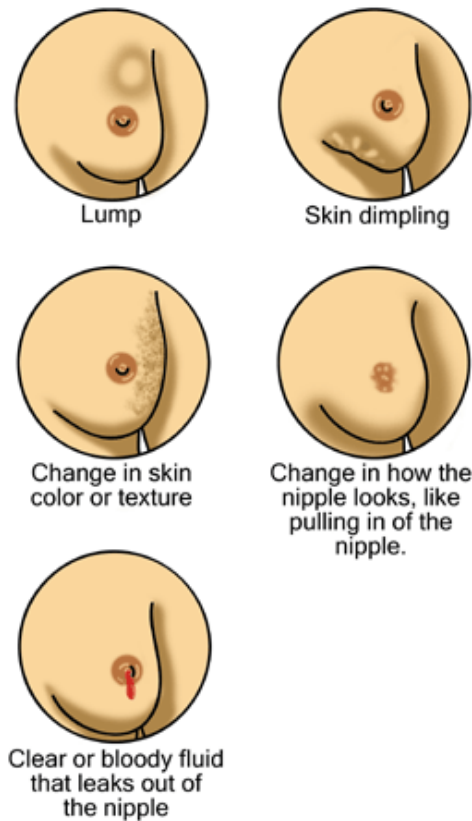


Figure 7.6 Signs of Breast Cancer

The American Cancer Society recommends a mammogram every year for most women starting at age 45.⁸ A **mammogram** (MĂM-ō-grăm) is a radiographic image of breast tissue that can detect signs of cancer, often before a lump is felt.

People suspected of having breast cancer or those at high risk may have additional diagnostic tests, such as the following⁹:

8. American Cancer Society. (2023). *Breast cancer*. <https://www.cancer.org/cancer/types/breast-cancer/screening-tests-and-early-detection/american-cancer-society-recommendations-for-the-early-detection-of-breast-cancer.html>

9. Centers for Disease Control and Prevention. (2023, July 25). *What is breast*

- **Breast ultrasound** (brĕst ŭl-tră-sound): A breast ultrasound uses sound waves to make images, called sonograms, of areas inside the breast.
- **Diagnostic mammogram** (dī-ăg-nŏs-tĭk mă-mŏ-grăm): If an area of the breast looks abnormal on a screening mammogram, a diagnostic mammogram is performed to get a more detailed X-ray of the breast.
- **Breast magnetic resonance imaging** (brĕst măg-NĚT-ĭk rĕz-ŏ-NĂNS ĭM-ă-jĭng) (**MRI**): A breast MRI is a kind of body scan that uses a magnet linked to a computer. The MRI scan makes detailed pictures of areas inside the breast.
- **Biopsy** (Bĭ-ŏp-sĕ): Tissue, fluid, and/or lymph nodes are removed by a health care provider and sent to a laboratory to be examined under a microscope. There are different kinds of biopsies, such as a fine-needle aspiration, sentinel lymph node biopsy, core biopsy, or open biopsy.

If breast cancer is diagnosed, other diagnostic tests are performed to check for metastasis, including chest X-rays, CT scans, and PET scans. Read more information about these types of diagnostic tests in the “[Medical Specialists, Diagnostic Testing, and Procedures Related to the Respiratory System](#).”

Breast cancer is treated in several ways, depending on the type of breast cancer and how far it has spread in the body. People with breast cancer often get more than one kind of treatment. Treatments may include the following¹⁰:

- **Surgery** (SŭR-jĕr-ĕ): There are different types of surgery, depending on how far the cancer has spread in the breasts, lymph nodes, and surrounding tissue.
 - **Breast-conserving surgery** (brĕst kŏn-sĕr-vĭng sŭr-jĕr-ĕ): Breast-

cancer? https://www.cdc.gov/cancer/breast/basic_info/what-is-breast-cancer.htm

10. National Cancer Institute. (2023, August 23). *Breast cancer treatment – (PDQ) patient version*. National Institutes of Health. https://www.cancer.gov/types/breast/patient/breast-treatment-pdq#_185

conserving surgery removes the cancer and some normal tissue around it, but not the breast itself. This type of surgery may also be called lumpectomy, partial mastectomy, segmental mastectomy, quadrantectomy, or breast-sparing surgery.

- **Total mastectomy** (tō-tāl mas-TEK-tō-mē): Total mastectomy removes the breast that has cancer and some of the lymph nodes in the armpit. This procedure is also called a simple mastectomy.
- **Modified radical mastectomy** (mōd-ī-fīd rād-ī-kāl mas-TEK-tō-mē): The whole breast that has cancer and most of the lymph nodes surrounding the breast are removed.
- **Chemotherapy** (kē-mō-THĚR-ă-pē): Specific medications are prescribed by physicians to shrink or kill specific types of cancer cells. Chemotherapy may be given as pills or administered intravenously, depending on the type of medication prescribed.
- **Hormonal therapy** (hōr-MŌ-nāl THĚR-ă-pē): Special medications are used to block cancer cells from getting the hormones they need to grow.
- **Targeted therapy** (TĀR-gī-těd THĚR-ă-pē): Targeted therapy works with the body's immune system to help it fight cancer cells or to control side effects from other cancer treatments.
- **Radiation therapy** (rā-dē-Ā-shōn THĚR-ă-pē): Radiation therapy uses high-energy rays (similar to X-rays) to kill the cancer cells.

Doctors from different specialties often work together to treat breast cancer.

Surgeons (SŪR-jōns) are doctors who perform operations. **Medical oncologists** (mēd-ī-kāl ōn-KOL-ō-jīsts) are physicians who specialize in the treatment of cancer with medication. **Radiation oncologists** (rā-dē-Ā-shōn ōn-KOL-ō-jīsts) are physicians who specialize in the treatments of cancer with radiation.

Cervical Cancer

Cervical cancer (SĚR-vi-kāl KAN-sēr) is mostly caused by the **human papillomavirus** (HYŪ-măn pă-pī-lō-mă VĪ-rūs) (**HPV**). HPV is passed from one person to another during sexual contact. HPV causes cervical cells to change into abnormal cells (called dysplasia), which over time can become cancer.

Cervical cancer is highly curable when found and treated early. Early cervical cancer does not cause symptoms, so routine PAP smears are recommended to screen for cancer. Most women between the ages of 21 and 65 should have a PAP smear every three to five years, depending upon their risk factors.¹¹

The **Papanicolaou smear** (păp-ă-NĒ-kă-low smēr), commonly referred to as a PAP smear, is a cytological study that screens for cancer in the cervix before symptoms even occur. During a PAP smear, a health care provider inserts a **speculum** (SPEK-yŭ-lŭm) into the patient's vagina to allow visualization of the cervix and obtains samples of cervical cells for laboratory analysis. An **HPV test** (H-P-V tĕst) is also typically performed during a PAP smear to check for infection with high-risk types of HPV that cause cancer.¹²

There are several types of abnormal cells that may be found on PAP smears. For example, **low-grade squamous intraepithelial lesions** (lō-grād SKWĀ-mŭs ĭn-tră-ĕ-pĭ-THĒ-lĕ-ăl LĒ-zhŭns) (**LSIL**) refer to slightly abnormal changes that are usually caused by an HPV infection that require additional diagnostic testing. **High-grade squamous intraepithelial lesions** (hī-grād SKWĀ-mŭs ĭn-tră-ĕ-pĭ-THĒ-lĕ-ăl LĒ-zhŭns) (**HSIL**) refer to abnormal cervical cells that could become cancer if not treated. **Adenocarcinoma in situ** (ăd-ĕ-nō-kă-r-sĭ-NŌ-mă ĭn Sĭ-tŭ) means an advanced lesion (i.e., area of abnormal tissue) was found in the tissue of the cervix and requires a biopsy.¹³

11. National Cancer Institute. (2021, September). *Understanding cervical changes: A health guide*. National Institutes of Health.
<https://www.cancer.gov/publications/patient-education/understanding-cervical-changes>

12. National Cancer Institute. (2021, September). *Understanding cervical changes: A health guide*. National Institutes of Health.
<https://www.cancer.gov/publications/patient-education/understanding-cervical-changes>

13. National Cancer Institute. (2021, September). *Understanding cervical changes: A health guide*. National Institutes of Health.

Additional diagnostic testing, such as a colposcopy, is performed for abnormal cell changes on PAP smears. A **colposcopy** (kŏl-PŎS-kŏ-pē) is a procedure in which a lighted, magnifying instrument called a colposcope is used to visually examine the cervix and potentially remove tissue for biopsy.¹⁴

Treatment for cervical cancers often includes excisional or ablative treatments¹⁵:

- Cold knife **conization** (kŏn-Ī-ZĀ-shŏn): A scalpel or laser knife is used to remove a cone-shaped section of abnormal tissue in the cervix. This procedure is done at the hospital and requires general anesthesia.
- **Loop electrosurgical excision procedure** (lŏŏp ě-lĕk-trŏ-SŬR-jĭ-kăl ěk-SĪZ-shŭn prŏ-SĒ-jŭr) (**LEEP**): Electrical current is passed through a thin wire loop to remove abnormal tissue in the cervix. Local anesthesia is used to numb the area, so this procedure can be performed in the health care provider's office.
- **Cryotherapy** (krĭ-ŏ-THĚR-ă-pē): A special cold probe is used to destroy abnormal tissue by freezing it. This procedure is done in the health care provider's office. It takes only a few minutes and usually does not require anesthesia.
- **Laser therapy** (LĀ-zĕr THĚR-ă-pē): A laser (narrow beam of intense light) is used to destroy abnormal tissue. This procedure is done at the hospital,

<https://www.cancer.gov/publications/patient-education/understanding-cervical-changes>

14. National Cancer Institute. (2021, September). *Understanding cervical changes: A health guide*. National Institutes of Health.
<https://www.cancer.gov/publications/patient-education/understanding-cervical-changes>

15. National Cancer Institute. (2021, September). *Understanding cervical changes: A health guide*. National Institutes of Health.
<https://www.cancer.gov/publications/patient-education/understanding-cervical-changes>

and general anesthesia is used.

Endometrial Cancer

The most common type of uterine cancer is **endometrial cancer** (en-dō-MĒ-trē-ăl KAN-sěr). A common symptom of endometrial cancer is postmenopausal vaginal bleeding.¹⁶

Diagnostic testing for endometrial cancer includes a transvaginal ultrasound and endometrial sampling. **Endometrial sampling** (ĕn-dō-MĒ-trē-ăl sām-plĭng) is the removal of tissue from the endometrium by a health care provider who inserts a brush, curette, or thin, flexible tube through the cervix and into the uterus. The tool is used to gently scrape a small amount of tissue from the endometrium and then remove the tissue samples. A pathologist views the tissue under a microscope to look for cancer cells. Alternatively, dilation and curettage (D&C) or hysteroscopy may be performed.¹⁷ Read more information about D&C and hysteroscopy procedures in the “[Medical Specialists, Diagnostic Testing, and Procedures Related to the Female Reproductive System](#)” section.

If endometrial cancer is diagnosed, additional diagnostic tests are performed to see if the cancer has spread to other parts of the body, including chest X-rays, CT scans, MRIs, and PET scans. Read more information about these types of diagnostic tests in the “[Medical Specialists, Diagnostic Testing, and Procedures Related to the Respiratory System](#).”

Treatment for endometrial cancer may include surgery, such as a hysterectomy, bilateral oophorectomy, and lymph node dissection. Hysterectomy and oophorectomy are discussed in more detail in the “[Medical](#)

16. National Cancer Institute. (2023, June 26). *Endometrial cancer screening (PDQ) – patient version*. National Institutes of Health. <https://www.cancer.gov/types/uterine/patient/endometrial-screening-pdq>

17. National Cancer Institute. (2023, June 26). *Endometrial cancer screening (PDQ) – patient version*. National Institutes of Health. <https://www.cancer.gov/types/uterine/patient/endometrial-screening-pdq>

Specialists, Diagnostic Testing, and Procedures Related to the Female Reproductive System” section. A **lymph node dissection** (lĭmf nōd dĭ-sĕk-shŏn) is a surgical procedure in which the lymph nodes are removed from the pelvic area, and a sample of tissue is examined under a microscope by a pathologist for signs of metastatic cancer. This procedure is also called **lymphadenectomy** (lĭmf-ăd-ĕ-NEK-tŏ-mĕ). Other treatments include radiation therapy, chemotherapy, hormone therapy, and targeted therapy.¹⁸

Ovarian Cancer

Ovarian cancer (ŏ-VAR-ĕ-ăn KAN-sĕr) is cancer that grows in the tissues of the ovary. Ovarian cancer has few symptoms other than possible pain and/or swelling in the pelvic area, so it often metastasizes before it is diagnosed. Some types of ovarian cancer are caused by mutations in genes called BRCA1 or BRCA2, so women who have a family history of ovarian cancer are at an increased risk. Other types of ovarian cancer are caused by metastatic cancer from other sites, such as breast, cervical, or colon cancer. Some women who have an increased risk of ovarian cancer may choose to have an oophorectomy to remove healthy ovaries as a preventative measure.¹⁹

Diagnostic tests for ovarian cancer include blood tests, a transvaginal ultrasound, or CT scans. After ovarian cancer has been diagnosed, additional diagnostic tests, such as an MRI or PET scans, are done to determine if cancer cells have spread within the ovaries or to other parts of the body. Treatment may include surgery, such as a hysterectomy, salpingo-oophorectomy, or omentectomy. Hysterectomy, salpingo-oophorectomy, and oophorectomy

¹⁸. National Cancer Institute. (2023, June 26). *Endometrial cancer screening (PDQ) – patient version*. National Institutes of Health. <https://www.cancer.gov/types/uterine/patient/endometrial-screening-pdq>

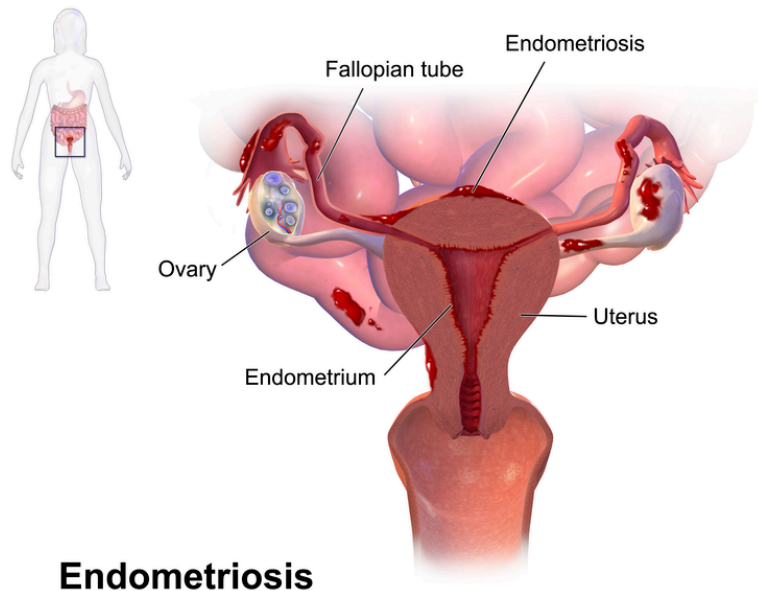
¹⁹. National Cancer Institute. (2022, December 22). *Ovarian, epithelial, fallopian tube, and primary peritoneal cancer treatment (PDQ®)– patient version*. National Institutes of Health. <https://www.cancer.gov/types/ovarian/patient/ovarian-epithelial-treatment-pdq>

procedures are discussed in more detail in the “[Medical Specialists, Diagnostic Testing, and Procedures Related to the Female Reproductive System](#)” section. An **omentectomy** (ō-měn-TEK-tō-mē) is removal of tissue in the peritoneum that contains blood vessels, nerves, lymph vessels, and lymph nodes. The **peritoneum** (pěr-ĭ-tō-NĒ-ŭm) is the tissue that lines the abdominal wall and covers most of the organs in the abdomen. Additional treatments may include chemotherapy, targeted therapy, radiation therapy, and immunotherapy.²⁰

ENDOMETRIOSIS

Endometriosis (en-dō-mē-trē-Ō-sīs) is a disorder in which tissue similar to the endometrium grows outside the uterus, typically on the ovaries, in Fallopian tubes, and in the pelvis. Estrogen causes these implants to thicken, bleed, and break down during menstrual cycles. Because there is no way for the blood to exit the body, surrounding tissue becomes inflamed and creates scar tissue, which can interfere with the normal functioning of nearby organs and cause pain. Endometriosis can also cause infertility if the ovaries are affected.²¹ See Figure 7.7²² for an illustration of endometriosis.

20. National Cancer Institute. (2022, December 22). *Ovarian, epithelial, fallopian tube, and primary peritoneal cancer treatment (PDQ®)– patient version*. National Institutes of Health. <https://www.cancer.gov/types/ovarian/patient/ovarian-epithelial-treatment-pdq>
21. Mayo Clinic. (2018, July 24). *Endometriosis*. <https://www.mayoclinic.org/diseases-conditions/endometriosis/symptoms-causes/syc-20354656>
22. “[Blausen_0349_Endometriosis.png](#)” by Blausen.com staff (2014). “[Medical gallery of Blausen Medical 2014](#) is licensed under [CC BY 3.0](#)



Endometriosis

Figure 7.7 Endometriosis

Symptoms of endometriosis include **dysmenorrhea** (dīs-mĕn-ŏ-RĒ-ă) or painful menstruation for several days that may include low back and abdominal pain. **Dyspareunia** (dīs-pār-ĕn-ŪR-ē-ă) or pain with intercourse is common, as well as pain with bowel movements or urination. Excessive bleeding or bleeding between menstruation may occur.²³

Endometriosis may be diagnosed with a transvaginal ultrasound or a laparoscopy. During a **laparoscopy** (lăp-ă-RŌS-kŏ-pē), the patient is under general anesthesia, and a surgeon makes a tiny incision near the navel and inserts a laparoscope, looking for signs of endometrial tissue outside the uterus. A laparoscopy can be performed to provide information about the location, extent, and size of endometrial implants, as well as remove them for

23. Mayo Clinic. (2018, July 24). *Endometriosis*. <https://www.mayoclinic.org/diseases-conditions/endometriosis/symptoms-causes/syc-20354656>

biopsy. In severe cases of endometriosis, an oophorectomy (removal of an ovary) or a hysterectomy may be required.²⁴

MENOPAUSE

Menopause (MEN-ō-poz), the cessation of menstruation, is part of the normal aging process and typically occurs in the 40s or 50s. A woman has reached menopause when she has not had a period for one year. Menopause occurs because the woman's ovaries stop producing the hormones estrogen and progesterone. Menopause can also be triggered by surgical removal of the ovaries because of their role in producing these hormones.

Many women experience symptoms for many years before menopause²⁵ :

- A change in menses, such as shorter or longer menses, lighter or heavier menstrual flow, or more or less time between menstrual cycles
- Hot flashes and/or night sweats
- Trouble sleeping
- Vaginal dryness
- Bladder incontinence
- Mood swings
- Trouble focusing
- Less hair on head and more on face

24. Mayo Clinic. (2018, July 24). *Endometriosis*. <https://www.mayoclinic.org/diseases-conditions/endometriosis/symptoms-causes/syc-20354656>

25. MedlinePlus [Internet]. Bethesda (MD): National Library of Medicine (US); [updated 2016, Oct 1]. Menopause; [reviewed 2016, cited 2023, Oct 8.] <https://medlineplus.gov/menopause.html>

For some women, menopausal symptoms can be severe and disruptive, requiring treatment by a health care provider.

OVARIAN CYST

An **ovarian cyst** (ō-VĀR-ē-an sĭst) is a fluid-filled sac in the ovary. The two most common types of ovarian cysts are follicle cysts and corpus luteum cysts. In a normal menstrual cycle, an ovary releases an ovum (egg) each month. The ovum grows inside a tiny sac called a follicle that breaks open to release the egg. Follicle cysts form when the follicle doesn't break open to release the egg, causing it to continue growing into a cyst. Follicle cysts often have no symptoms and typically resolve in one to three months.

During normal ovulation, after the follicle breaks open and releases the egg, the empty follicle sac shrinks into a mass of cells called a corpus luteum. Corpus luteum cysts form if the empty follicle sac doesn't shrink as it should, but instead reseals itself and builds up with fluid. Most corpus luteum cysts go away after a few weeks, but they can grow to ten centimeters (four inches) wide and cause pain. They may also bleed or cause the ovary to twist, requiring surgery such as a laparoscopy or a laparotomy²⁶ :

- **Laparoscopy** (lap-uh-ROSS-kuh-pee): During this surgery, the physician makes a very small incision above or below the umbilicus (navel) and inserts instruments with a camera to look inside the pelvic area and remove the cyst, which is then sent to a pathology lab for analysis. This type of surgery is typically performed for smaller cysts that appear benign (i.e., not cancerous) on the ultrasound.
- **Laparotomy** (lap-uh-ROT-uh-mee): A laparotomy is typically performed

26. Office on Women's Health. (2021, February 22). *Ovarian cysts*.

<https://www.womenshealth.gov/a-z-topics/ovarian-cysts>

for large cysts or those that are suspicious on ultrasound as cancerous. This surgery uses a larger incision in the abdomen to remove the cyst, and then the cyst is sent to a pathology lab for analysis.

PELVIC INFLAMMATORY DISEASE

Pelvic inflammatory (PĚL-vĭk ĭn-flă-MĂ-tŏ-rē) **disease (PID)** is inflammation of some or all of the female reproductive organs, resulting from the spread of bacteria from the cervix and vagina. PID is a serious complication of chlamydia and gonorrhea. The most common symptoms of PID are the following²⁷:

- Lower abdominal and pelvic pain
- Increased vaginal discharge
- Irregular menstrual bleeding
- Fever (>38° C or >101°F)
- Pain with intercourse
- Painful and frequent urination
- Cervical motion tenderness

Complications of PID include tubo-ovarian abscess, infertility, ectopic pregnancy, and chronic pelvic pain. A **tubo-ovarian abscess** (TŪ-bō ō-VAR-ē-ăĭn-ăb-sēs) is an inflammatory mass involving the Fallopian tube and ovary and requires hospital admission. Treatment includes broad-spectrum antibiotics with or without a drainage procedure. Surgery may be required for

27. Centers for Disease Control and Prevention. (2021, July 22). *Pelvic inflammatory disease (PID)- CDC detailed fact sheet*. <https://www.cdc.gov/std/pid/stdfact-pid-detailed.htm>

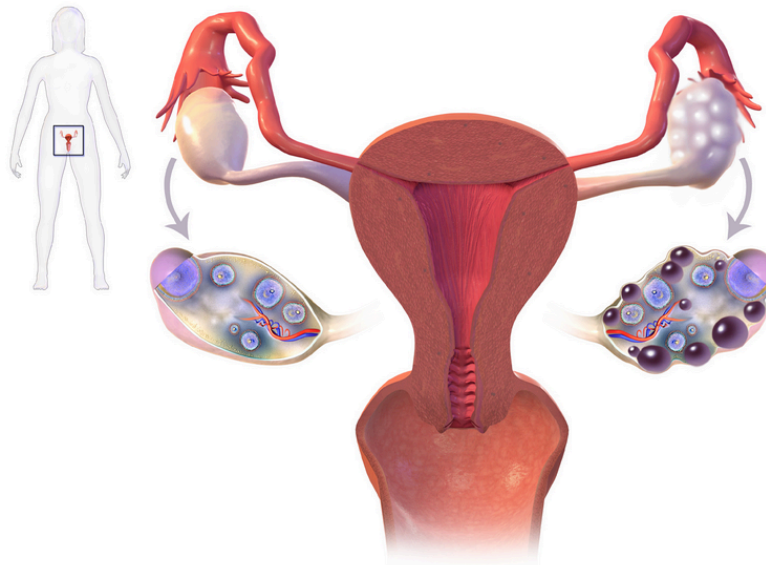
patients with a suspected rupture or who fail to respond to antibiotics.²⁸ An **ectopic pregnancy** (ĕk-TŌP-ĭk PRĔG-năn-sē) is the implantation of an embryo outside of the uterus, typically in the fallopian tube.

POLYCYSTIC OVARY SYNDROME

Polycystic ovary syndrome (pŏl-ē-SĬS-tĭk Ō-vă-rē SĬN-drŏm) (**PCOS**) is a condition characterized by hormone imbalances, ovulatory dysfunction, and multiple ovarian cysts (i.e., small sacs of fluid). Fluid-filled cysts containing immature eggs are called follicles. Instead of releasing an egg during ovulation, the follicles (cysts) build up and enlarge. See Figure 7.8²⁹ for an illustration of PCOS.

28. Centers for Disease Control and Prevention. (2021, July 22). *Pelvic inflammatory disease (PID)- CDC detailed fact sheet*. <https://www.cdc.gov/std/pid/stdfact-pid-detailed.htm>

29. “PCOS_ %28Part_ 2%29.png” by BruceBlaus is licensed under [CC BY 4.0](https://creativecommons.org/licenses/by/4.0/)



Polycystic Ovary Syndrome

Figure 7.8 PCOS

PCOS has no known cause, but it is associated with obesity and excessive insulin production. Common symptoms of PCOS include oligomenorrhea, amenorrhea, polymenorrhea, and enlarged ovaries due to multiple cysts or follicles. High levels of androgen hormones associated with PCOS can cause **hirsutism** (HĪR-sū-tīz-ŭm) or excess facial and body hair. PCOS can also cause infertility.³⁰

PCOS is diagnosed with blood tests and a transvaginal ultrasound. Treatments for PCOS include birth control pills to control menstrual cycles, diabetes medications to reduce insulin resistance, and medication to promote ovulation.

30. Mayo Clinic. (2022, September 8). *Polycystic ovary syndrome (PCOS)*. <https://www.mayoclinic.org/diseases-conditions/pcos/symptoms-causes/syc-20353439>

PREMENSTRUAL SYNDROME (PMS)

Premenstrual syndrome (prē-MĚN-stroo-ăl SĬN-drōm) (**PMS**) is a syndrome involving physical and emotional symptoms occurring up to ten days before menstruation. Symptoms may include fluid retention (bloating), headaches, nervous tension, irritability, and breast tenderness. For some women, these symptoms can be so severe it causes them to miss work or school.

Researchers think that PMS happens in the days after ovulation because estrogen and progesterone levels begin falling dramatically if the egg is not fertilized. PMS symptoms go away within a few days after menses begins and hormone levels begin rising again.³¹

PREMENSTRUAL DYSPHORIC DISORDER

Premenstrual dysphoric (prē-MĚN-strŭ-ăl dis-FŌR-ĭk) **disorder (PMDD)** is a disorder that affects about 5% of menstruating females. It has similar symptoms as premenstrual syndrome (PMS) but is more serious. PMDD causes severe irritability, depression, or anxiety in the week or two before the menstrual cycle, and these issues go away two to three days after menstruation starts. Symptoms can include the following³²:

- Lasting irritability or anger that may affect other people

31. Office On Women's Health. (2021, February 22). *Premenstrual syndrome (PMS)*. <https://www.womenshealth.gov/menstrual-cycle/premenstrual-syndrome#>

32. Office On Women's Health. (2021, February 22). *Premenstrual dysphoric disorder (PMDD)*. <https://www.womenshealth.gov/menstrual-cycle/premenstrual-syndrome/premenstrual-dysphoric-disorder-pmdd>

- Feelings of sadness or despair, or even thoughts of suicide
- Feelings of tension or anxiety
- Panic attacks
- Mood swings or crying often
- Lack of interest in daily activities and relationships
- Trouble thinking or focusing
- Tiredness or low energy
- Food cravings or binge eating
- Trouble sleeping
- Feeling out of control
- Physical symptoms, such as cramps, bloating, breast tenderness, headaches, and joint or muscle pain

Women with PMDD require medications and other treatments such as the following ³³ :

- Antidepressants called selective serotonin reuptake inhibitors (SSRIs) that increase serotonin levels in the brain
- Birth control pills to help regulate hormone levels
- Over-the-counter pain relievers, such as ibuprofen, naproxen, or aspirin to help relieve physical symptoms
- Stress management and relaxation techniques
- Healthy lifestyle changes, such as healthy food choices across the food groups, cutting back on salty and sugary foods, and getting more physical activity

33. Office on Women's Health. (2021, February 22). *Premenstrual dysphoric disorder (PMDD)*. <https://www.womenshealth.gov/menstrual-cycle/premenstrual-syndrome/premenstrual-dysphoric-disorder-pmdd>

PROLAPSE

A **prolapse** (PRŌ-laps) is the displacement of an organ or anatomic structure from its normal position. A **uterine prolapse** (ŪT-ě-rīn PRŌ-laps) is the downward displacement of the uterus into the vagina. A uterine prolapse occurs when the pelvic floor muscles and ligaments stretch and weaken until they no longer provide enough support for the uterus. As a result, the uterus slips down into or protrudes out of the vagina. Uterine prolapse most often affects people after menopause who have had one or more vaginal deliveries. Surgery may be required to treat the prolapse.³⁴

An anterior **vaginal prolapse** (vă-jī-năl PRŌ-laps), also known as a **cystocele** (SĪS-tō-sēl) or a protrusion of the bladder, is when the bladder drops from its usual position in the pelvis into the vagina. Anterior vaginal prolapse occurs when the pelvic floor becomes weak or if too much pressure is put on the pelvic floor. This can happen over time, during vaginal childbirth, or with chronic constipation, violent coughing, or heavy lifting. Surgery may be required to treat the prolapse.³⁵

A posterior vaginal prolapse, also known as a **rectocele** (RĚK-tō-sēl) or rectal prolapse, is when the rectum protrudes into the vagina.

34. Mayo Clinic. (2022, September 8). *Uterine prolapse*.

<https://www.mayoclinic.org/diseases-conditions/uterine-prolapse/symptoms-causes/syc-20353458>

35. Mayo Clinic. (2023, April 6). *Anterior vaginal prolapse*.

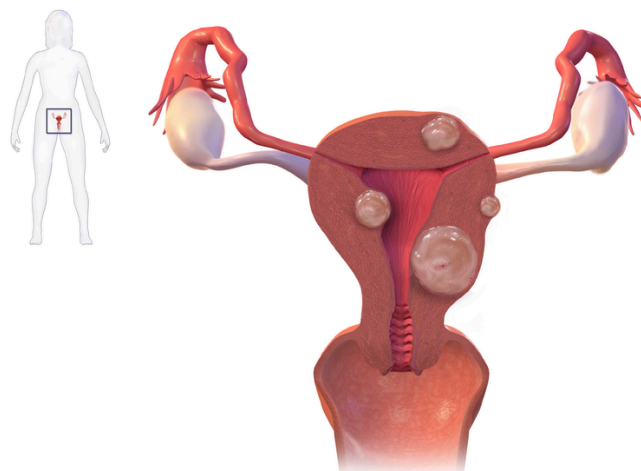<https://www.mayoclinic.org/diseases-conditions/cystocele/symptoms-causes/syc-20369452>

SEXUALLY TRANSMITTED INFECTIONS

Sexually transmitted infections (STI), also known as sexually transmitted diseases, can cause serious disease in both men and women. For brevity of this textbook, STIs are thoroughly discussed in the “Sexually Transmitted Infections” subsection of the “[Diseases and Disorders of the Male Reproductive System](#)” section in the “Male Reproductive System Terminology” chapter. Review that section for information about signs and symptoms of several STIs in females.

UTERINE FIBROID

A **uterine fibroid** (ŪT-ě-rīn FIB-royd) is a benign tumor in the muscular wall of the uterus in women. See Figure 7.9³⁶ for an illustration of fibroids.



Uterine Fibroids

Figure 7.9 Fibroids

36. “[Uterine_Fibroids.png](#)” by [BruceBlaus](#) is licensed under [CC By 4.0](#)

The cause of fibroids is unknown. Symptoms of uterine fibroids are as follows³⁷:

- Dysmenorrhea
- Menorrhagia
- Metrorrhagia
- A feeling of fullness in the lower abdomen
- Frequent urination
- Dyspareunia
- Lower back pain
- Reproductive problems, such as infertility, multiple miscarriages, or early labor

Symptomatic uterine fibroids may be treated with birth control pills or medications to shrink the fibroids. For women with fibroids with moderate or severe symptoms, several types of surgery may be used to treat them³⁸:

- **Myomectomy** (mī-ō-MĚK-tŏ-mē): Surgery that removes fibroids without taking out healthy tissue of the uterus. This surgery is best for women who wish to have children after treatment. It can be major surgery (involving cutting into the abdomen) or performed with laparoscopy or hysteroscopy.
- **Hysterectomy** (his-tě-REK-tŏ-mē): Surgery to remove the uterus when fibroids are large, if the woman is experiencing very heavy bleeding, or if the woman is near menopause or does not want future pregnancy. Read more about different types of hysterectomies in the “[Medical Specialties, Diagnostic Testing, and Procedures Related to the Female Reproductive System](#)” section.

37. Office on Women’s Health. (2021, February 19). *Uterine fibroids*.
<https://www.womenshealth.gov/a-z-topics/uterine-fibroids>

38. Office on Women’s Health. (2021, February 19). *Uterine fibroids*.
<https://www.womenshealth.gov/a-z-topics/uterine-fibroids>

- **Endometrial ablation** (ĕn-dō-MĒ-trē-ăl ă-blā-shŏn): The lining of the uterus is removed or destroyed to control very heavy bleeding. This can be done using several methods such as a laser, wire loops, electric current, microwaves, freezing, and other methods. This procedure usually is considered minor surgery and can be done on an outpatient basis or in a doctor's office. A woman cannot have future pregnancies after this procedure.
- **Myolysis** (mī-OL-ŏ-sĭs): A needle is inserted into the fibroids, guided by laparoscopy, and electric current or freezing is used to destroy the fibroids.
- **Uterine fibroid embolization** (ŪT-ĕ-rĭn Fĭ-brŏyd ĕm-bō-lĭ-ZĀ-shŏn) (**UFE**) or **uterine artery embolization** (ŪT-ĕ-rĭn ăr-tĕr-ē ĕm-bō-lĭ-ZĀ-shŏn) (**UAE**): A thin tube is threaded into the blood vessels that supply blood to the fibroid, then tiny plastic particles are injected into the blood vessels to block the blood supply to the fibroid. The lack of blood supply causes the fibroid to shrink.

TOXIC SHOCK SYNDROME

Toxic shock syndrome (TŌK-sĭk SHŌK SĪN-drŏm) (**TSS**) is a severe bacterial infection that has many causes, including superabsorbent **tampon** (TĀM-pon) use. Tampons are cotton plugs used to absorb menstrual flow. TSS is caused by *Staphylococcus* and *Streptococcus* bacteria, and symptoms include sudden high fever, vomiting or diarrhea, a rash resembling a sunburn on the palms and soles, confusion, muscle aches, headaches, low blood pressure, and seizures. TSS can cause acute kidney failure and death. To help prevent TSS, the U.S. Food and Drug Administration requires manufacturers to use standard measurement and labeling for absorbency and to print guidelines

on the boxes. Women should use the lowest absorbency tampon required for their flow and change tampons at least every four to eight hours.³⁹

VAGINAL CANDIDIASIS

Vaginal candidiasis (vă-jĩ-năl kăn-dĩ-Dĩ-ă-sĩs), also called a yeast infection, is a common fungal infection of the vagina and the vulva that causes thick, white discharge and intense itching. It is typically treated with medication inserted vaginally.⁴⁰

39. Mayo Clinic. (2022, March 23). *Toxic shock syndrome*.

<https://www.mayoclinic.org/diseases-conditions/toxic-shock-syndrome/symptoms-causes/syc-20355384>

40. Mayo Clinic. (2022). *Yeast infection (Vaginal)*. <https://www.mayoclinic.org/diseases-conditions/yeast-infection/symptoms-causes/syc-20378999>

7.7 Medical Specialists, Diagnostic Testing, and Procedures Related to the Female Reproductive System

MEDICAL SPECIALISTS

Gynecology (gī-ně-KOL-ŏ-jē) refers to the study of the female reproductive system. A **gynecologist** (gīn-ě-KOL-ŏ-jĭst) (GYN) is a physician who specializes in the diagnosis and treatment of diseases and disorders of the female reproductive system. **Obstetrics** (ŏb-STĚT-rĭks) is a specialty regarding pregnancy, labor, and delivery of a baby. An **obstetrician** (OB) is a physician who specializes in providing medical care through pregnancy, labor, and delivery of a baby. Other subspecialties in women's health include contraception, reproductive endocrinology, infertility, adolescent gynecology, endoscopy, and gynecological oncology.¹

1. American Board of Medical Specialties. (n.d.). *American board of obstetrics and gynecology specialties & subspecialties*. <https://www.abms.org/board/american-board-of-obstetrics-gynecology/>

- ▶ To learn more about obstetrics or gynecology, visit the specialty and subspecialty page of the [American Board of Obstetrics and Gynecology](#).

COMMON DIAGNOSTIC TESTS AND PROCEDURES

Many diagnostic tests and procedures are discussed as they apply to female reproductive system disorders in the “[Diseases and Disorders of the Female Reproductive System](#)” section. Common diagnostic tests and procedures used for multiple disorders are described below.

Dilation & Curettage (D&C)

Dilation & curettage (dī-LĀ-shŏn and kūr-ĕ-tāj) (**D&C**) is a procedure performed by a physician in which the opening of the cervix is stretched so that a surgical tool can be inserted into the uterus to scrape away the excess endometrial lining. The removed lining is then biopsied for abnormal tissue. A D&C is performed to determine the cause of abnormal vaginal bleeding, as well as to treat it.² See Figure 7.10³ for an illustration of a D&C.

2. Family Doctor. (2023, June 8). *Abnormal vaginal bleeding*. American Academy of Family Physicians. <https://familydoctor.org/condition/abnormal-uterine-bleeding>

3. “[Dilation_%26_curettage.svg.png](#)” by [Andrew c](#) is licensed under [CC BY-SA 3.0](#)

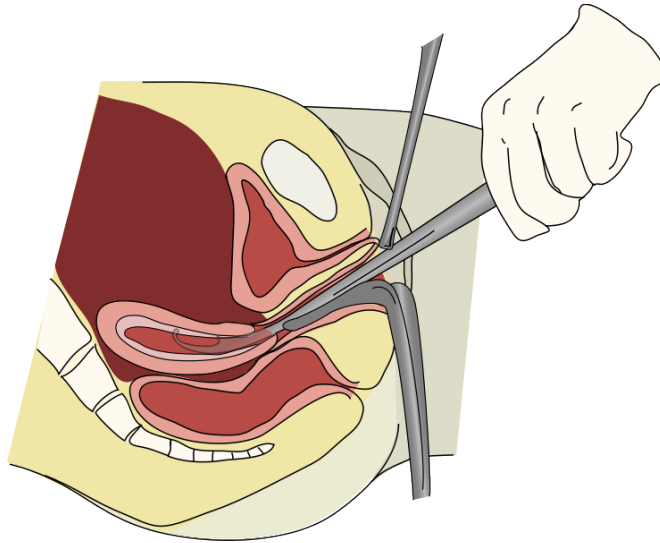


Figure 7.10 D&C

Hysterectomy, Oophorectomy, and Salpingectomy

A **hysterectomy** (his-tě-REK-tǒ-mē) is a surgery used to treat a variety of disorders, such as dysfunctional uterine bleeding, fibroids, severe endometriosis, endometrial cancer, and ovarian cancer. See Figure 7.11⁴ for an illustration of different types of hysterectomies. There are several types of hysterectomies⁵:

- **Total hysterectomy** (tō-tāl his-tě-REK-tǒ-mē): Surgery to remove the uterus, including the cervix. If the uterus and cervix are taken out through the vagina, the operation is called a **vaginal hysterectomy** (vă-jǐ-nāl his-tě-REK-tǒ-mē). If the uterus and cervix are taken out through a large incision in the abdomen, the operation is called a **total abdominal hysterectomy** (tō-tāl ăb-DŎM-ĭ-nāl his-tě-REK-tǒ-mē). If the uterus and

4. “[me_hysterectomy-en.svg](#)” by [Hic et nunc](#) is licensed in the [Public Domain](#).

5. National Cancer Institute. (2020, November 13). *Endometrial cancer treatment (PDQ) – Patient version*. <https://www.cancer.gov/types/uterine/patient/endometrial-treatment-pdq#top>

cervix are taken out through a small incision in the abdomen using a laparoscope, the operation is called a **total laparoscopic hysterectomy** (tō-tāl lăp-ăr-ō-SKŌP-ĭk his-tě-REK-tō-mē). A **subtotal hysterectomy** (sŭb-tō-tāl his-tě-REK-tō-mē) removes part of the uterus but leaves the cervix intact.

- **Radical hysterectomy** (răd-ĭ-kăl his-tě-REK-tō-mē): Surgery to remove the uterus, cervix, and part of the vagina. The ovaries, Fallopian tubes, or nearby lymph nodes may also be removed during this procedure, referred to as a **total hysterectomy/bilateral salpingectomy oophorectomy** (tō-tāl his-tě-REK-tō-mē / bī-LĀT-ěr-ăl sāl-pĭn-JEK-tō-mē ō-ō-fō-REK-tō-mē) (**TAH/BSO**). An **oophorectomy** (ō-ō-fō-REK-tō-mē) is the surgical removal of one ovary. A **bilateral oophorectomy** (bī-LĀT-ěr-ăl ō-ō-fō-REK-tō-mē) is the removal of both ovaries. A **salpingectomy** (sāl-pĭn-JEK-tō-mē) is the removal of a Fallopian tube. A **salpingo-oophorectomy** (sāl-pĭn-jō-ō-ōf-ō-RĚK-tō-mē) is removal of one Fallopian tube and the associated ovary. **Bilateral salpingo-oophorectomy** (bī-LĀT-ěr-ăl sāl-pĭng-gō-ō-ō-fō-REK-tō-mē) means removal of both ovaries and Fallopian tubes.

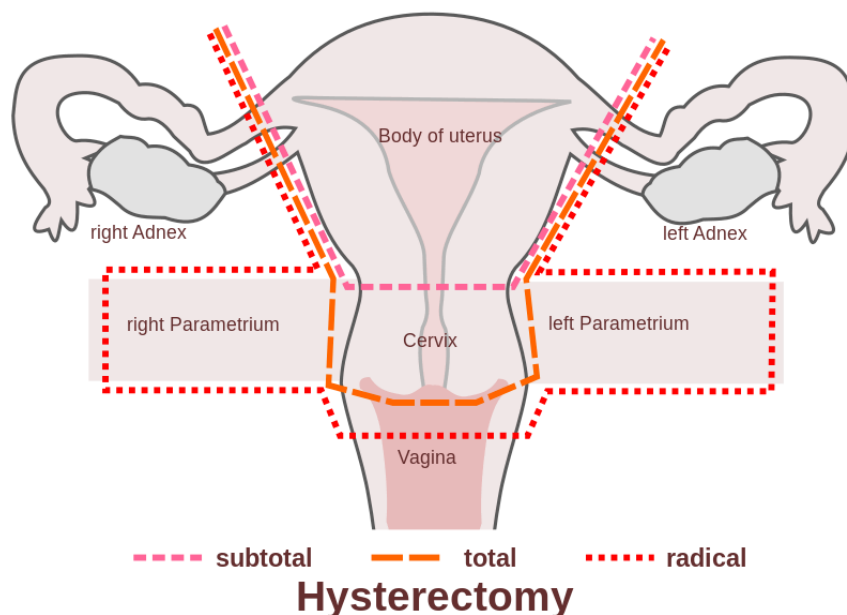


Figure 7.11 Types of Hysterectomies

Hysterosalpingogram

A **hysterosalpingogram** (hĭs-tĕ-RO-săĭl-pĭnj-ō-gram) is a common imaging procedure performed to assess for potential causes of infertility in women. During the procedure, radiopaque dye is injected into the uterus and fills the uterine cavity, continues into the Fallopian tubes, and eventually reaches fimbriated ends next to the ovaries. Structures are visualized with an X-ray.

Hysteroscopy

A **hysteroscopy** (his-tĕ-ROS-kŏ-pĕ) is a procedure to visually examine the uterus for abnormal areas. A hysteroscope is a thin, tube-like instrument with a light and a lens for viewing and is inserted through the vagina and cervix into the uterus. It may also have a tool to remove tissue samples, which are examined under a microscope for signs of cancer.⁶ See Figure 7.12⁷ for an illustration of hysteroscopy.

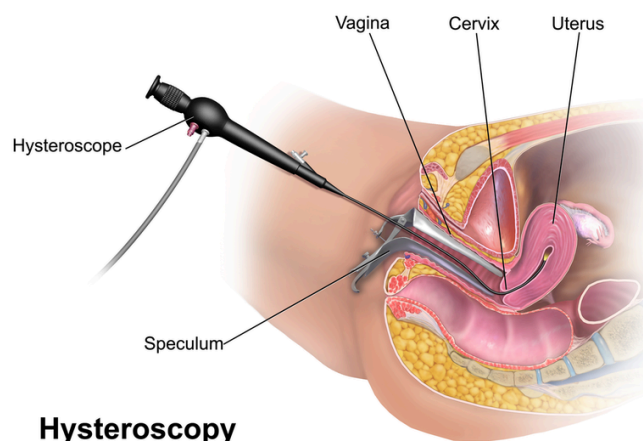


Figure 7.12 Hysteroscopy

6. National Cancer Institute. (2023, June 26). *Endometrial cancer screening (PDQ) – Patient version*. <https://www.cancer.gov/types/uterine/patient/endometrial-screening-pdq>

7. “Hysteroscopy.png” by BruceBlaus is licensed under [CC BY-SA 4.0](https://creativecommons.org/licenses/by-sa/4.0/)

Mammogram

A **mammogram** (MĂM-ō-grăm) is a radiographic image of breast tissue to detect signs of breast cancer. See Figure 7.13⁸ for an image of a women undergoing a mammogram.

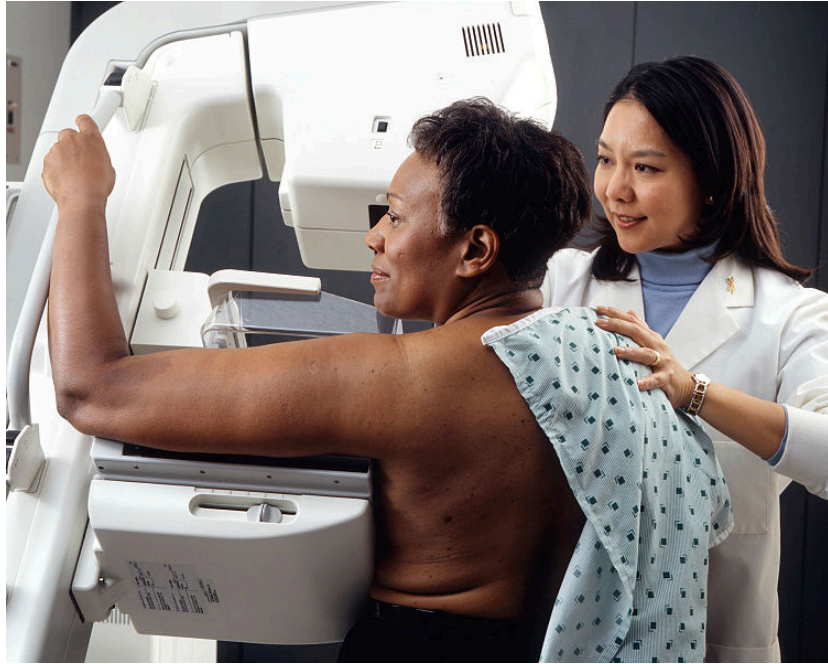

Figure 7.13 Mammogram

Pap Smear

A **Papanicolaou smear** (păp-ă-NĒ-kă-low smēr) or Pap smear is a diagnostic test that screens for suspicious changes in cells of the cervix. During a Pap smear, a health care provider inserts a **speculum** (SPEK-yŭ-lŭm) into the vagina to allow visualization of the cervix. Cells are collected from the cervix using sterile swabs and/or cytobrushes and sent to a lab for analysis for

8. [“Woman receives mammogram.jpg”](#) by Rhoda Baer and is licensed in the [Public Domain](#).

abnormal cells or cancer. See Figure 7.14⁹ for an image of a cytobrush used to collect cervical cell samples during a PAP smear.



Figure 7.14
Cytobrush

Transvaginal Ultrasound

A **transvaginal ultrasound** (trăns-vă-jǐ-năl ŪL-tră-sound) is a procedure used to examine the vagina, uterus, Fallopian tubes, and bladder. An ultrasound transducer (probe) is inserted into the vagina and used to bounce high-energy sound waves (ultrasound) off internal tissues or organs and make

9. "[Cytobrush for sampling endocervical cells.jpg](#)" by [Whispyhistory](#) is licensed under [CC BY-SA 4.0](#)

echoes. The echoes form a picture of body tissues called a sonogram. See Figure 7.15¹⁰ for an illustration of the ultrasound transducer placement during a transvaginal ultrasound.

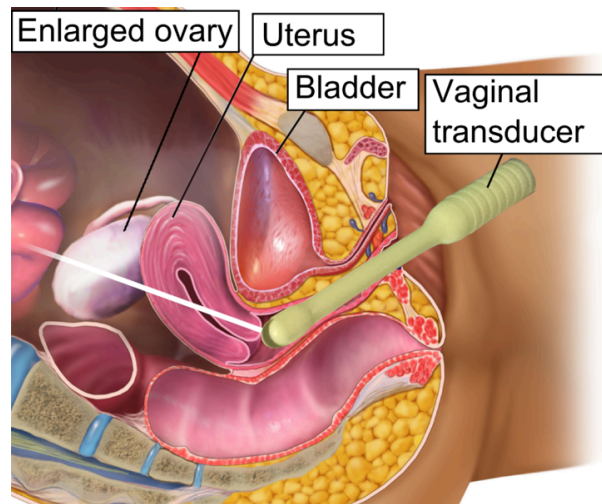


Figure 7.15 Transvaginal Ultrasound

Tubal Ligation

Tubal ligation (TOO-bäl lī-GĀ-shŏn) is surgical procedure performed to prevent pregnancy and is also called female sterilization and commonly referred to as “getting your tubes tied.” “Tubal” refers to the Fallopian tubes, and “ligation” means to tie off. During this surgery, both Fallopian tubes are blocked or cut to prevent fertilization of the egg by sperm. The procedure is usually performed in the hospital or in an outpatient surgical clinic. After the procedure, the woman still has a monthly menstrual cycle and menstrual flow.¹¹

10. “[Vaginal ultrasonography in OHSS - coronal.png](#)” by [BruceBlaus](#) CC BY 3.0

11. Johns Hopkins Medicine. (n.d.). *Tubal ligation*.
<https://www.hopkinsmedicine.org/health/treatment-tests-and-therapies/tubal-ligation>

7.8 Female Reproductive System Learning Activities

Interactive Learning Activity: Label the anatomy of the female reproductive system.



An interactive H5P element has been excluded from this version of the text. You can view it online here:

<https://wtcs.pressbooks.pub/medterm/?p=285#h5p-30>

Interactive Learning Activity: Study female reproductive system medical terms discussed in this chapter.



An interactive H5P element has been excluded from this version of the text. You can view it online here:

<https://wtcs.pressbooks.pub/medterm/?p=285#h5p-181>

Interactive Learning Activity: Test your knowledge on terms related to the female reproductive system.



An interactive H5P element has been excluded from this version of the text. You can view it online here:

<https://wtcs.pressbooks.pub/medterm/?p=285#h5p-37>

Interactive Learning Activity: Using the sample documentation provided, drag the terms on the right to their appropriate spaces within the documentation.



An interactive H5P element has been excluded from this version of the text. You can view it online here:

<https://wtcs.pressbooks.pub/medterm/?p=285#h5p-34>

Interactive Learning Activity: Using the sample documentation provided, drag the terms on the right to their appropriate spaces within the documentation.



An interactive H5P element has been excluded from this version of the text. You can view it online here:

<https://wtcs.pressbooks.pub/medterm/?p=285#h5p-35>

Interactive Learning Activity: Using the sample documentation provided, drag the terms on the right to their appropriate spaces within the documentation.



An interactive H5P element has been excluded from this version of the text. You can view it online here:

<https://wtcs.pressbooks.pub/medterm/?p=285#h5p-36>



Interactive Learning Activity: Practice identifying and defining word parts for terms discussed in this chapter.



An interactive H5P element has been excluded from this version of the text. You can view it online here:

<https://wtcs.pressbooks.pub/medterm/?p=285#h5p-199>

- ▶ You can also print this as a [Chapter 7 Practice Worksheet](#) and check your answers with this [Answer Key PDF](#).

7.9 Glossary

Abnormal vaginal bleeding (ăb-nŏr-măł vă-jĩ-năł blēd-ing): Unusual bleeding from the vagina, including very heavy menstrual flow, bleeding between cycles, or prolonged bleeding. ([Chapter 7.6](#))

Adenocarcinoma in situ (ăd-ě-nŏ-kăř-sĩ-NŌ-mă ĩn SĪ-tū): A condition where advanced, precancerous cells are found in the glandular tissue of the cervix. ([Chapter 7.6](#))

Adnexa (ăd-NĚK-să): The accessory structures of the uterus, including the fallopian tubes and ovaries. ([Chapter 7.5](#))

Amenorrhea (ā-men-ŏ-RĒ-ă): The absence of menstrual flow. ([Chapter 7.5](#))

Anovulation (an-ov-yŭ-LĀ-shŏn): The absence of ovulation when an egg is not released from the ovaries. ([Chapter 7.5](#))

Bartholin's glands (BAR-tŏ-lĩns glăns): Glands that secrete mucus to keep the vestibular area moist, located near the vaginal opening. ([Chapter 7.4](#))

Bilateral oophorectomy (bĩ-LĀT-ěr-ăł ō-ŏ-fŏ-REK-tŏ-mē): Removal of both ovaries. ([Chapter 7.7](#))

Bilateral salpingo-oophorectomy (bĩ-LĀT-ěr-ăł săł-pĩng-gŏ-ō-ŏ-fŏ-REK-tŏ-mē): Removal of both ovaries and both Fallopian tubes. ([Chapter 7.7](#))

Biopsy (BĪ-ŏp-sē): A diagnostic procedure where tissue, fluid, or lymph nodes are removed for examination under a microscope. ([Chapter 7.6](#))

Breast cancer (brest KAN-sěr): Malignant tumors developing from breast tissue cells. ([Chapter 7.6](#))

Breast-conserving surgery (brěst kŏn-sěr-vĩng sŭr-jěr-ē): Surgical procedure removing only the cancerous part of the breast, not the entire breast. ([Chapter 7.6](#))

Breast magnetic resonance imaging (brěst măg-NĚT-ĩk rěz-ŏ-NĀNS ĨM-ă-jĩng (MRI): A diagnostic imaging technique used to create detailed images of the breast tissue, often used in detecting and evaluating breast abnormalities. ([Chapter 7.6](#))

Breast ultrasound (brěst ũl-tră-sound): A diagnostic imaging technique using sound waves to create images of the breast tissue. ([Chapter 7.6](#))

Cervical cancer (SĚR-vi-kāl KAN-sěr): Cancer arising from the cervix, often associated with human papillomavirus (HPV) infection. ([Chapter 7.6](#))

Cervix (SĚR-víks): The lower part of the uterus, connecting the uterus to the vagina. ([Chapter 7.4](#))

Chemotherapy (kē-mō-THĚR-ă-pē): The use of drugs to destroy or inhibit the growth of cancerous cells. ([Chapter 7.6](#))

Clitoris (KLĪT-ō-rīs): Erectile tissue originating from the same fetal cells as the penis, containing abundant nerves important in sexual sensation and orgasm. ([Chapter 7.4](#))

Cold knife conization (kǒn-ī-ZĀ-shǒn): A procedure using a scalpel or laser to remove a cone-shaped section of abnormal cervical tissue. ([Chapter 7.6](#))

Colposcopy (kǒl-PŎS-kō-pē): A procedure using a lighted magnifying instrument to examine the cervix and potentially remove tissue for biopsy. ([Chapter 7.6](#))

Conception (kǒn-sěp-shǒn): The process of a sperm fertilizing an ovum, forming a zygote. ([Chapter 7.5](#))

Contraception (kon-tră-SEP-shǒn): Methods or devices used to prevent pregnancy. ([Chapter 7.5](#))

Corpus luteum (KŌR-pus LŪ-tē-um): A temporary endocrine structure in female ovaries that is involved in the production of relatively high levels of progesterone and moderate levels of estrogen and inhibin A. ([Chapter 7.5](#))

Cryotherapy (krī-ō-THĚR-ă-pē): A treatment method using extreme cold to destroy abnormal tissue. ([Chapter 7.6](#))

Cystocele (SĪS-tō-sēl): A prolapse of the bladder into the vagina, often referred to as an anterior vaginal prolapse. ([Chapter 7.6](#))

Diagnostic mammogram (dī-ăg-nŏs-tĭk mǎ-mō-grǎm): An enhanced mammogram used when an area of the breast looks abnormal on a screening mammogram. ([Chapter 7.6](#))

Dilation & Curettage (dī-LĀ-shǒn and kūr-ě-tāj) (D&C): A surgical procedure to remove tissue from the inside of the uterus. ([Chapter 7.7](#))

Dysfunctional uterine bleeding (dĭs-fŭnk-shŭn-ăl yŪ-těr-ĭn blēd-ing): Abnormal bleeding from the uterus, often due to hormonal imbalances. ([Chapter 7.6](#))

Dysmenorrhea (dīs-mĕn-ŏ-RĒ-ă): Painful menstruation, often with cramps. ([Chapter 7.5](#), [Chapter 7.6](#))

Dyspareunia (dīs-pār-ĕn-ŪR-ē-ă): Pain during sexual intercourse. ([Chapter 7.5](#), [Chapter 7.6](#))

Ectopic pregnancy (ĕk-TŌP-ĭk PRĒG-năn-sē): A pregnancy where the embryo implants outside the uterus, typically in a fallopian tube. ([Chapter 7.6](#))

Embryo (Ĕm-brē-ŏ): The early developmental stage of an organism following fertilization. ([Chapter 7.5](#))

Endometrial ablation (en-dō-MĒ-trē-ăl ă-BLĀ-shŏn): A procedure that destroys the lining of the uterus to reduce or stop heavy menstrual bleeding. ([Chapter 7.6](#))

Endometrial cancer (en-dō-MĒ-trē-ăl KAN-sĕr): Cancer that originates in the lining of the uterus (endometrium). ([Chapter 7.6](#))

Endometrial sampling (ĕn-dō-MĒ-trē-ăl săm-plĭng): A procedure to remove tissue from the endometrium for examination under a microscope. ([Chapter 7.6](#))

Endometriosis (en-dō-mē-trē-Ō-sĭs): A painful condition where tissue similar to the lining of the uterus grows outside the uterus. ([Chapter 7.6](#))

Endometrium (en-dō-MĒ-trē-um): The innermost lining of the uterus, providing the site for implantation of a fertilized egg or shedding during menstruation. ([Chapter 7.4](#))

Estrogen (ĔS-trŏ-jen): A hormone produced by the ovaries, playing a key role in the female reproductive system, including the menstrual cycle and pregnancy. ([Chapter 7.5](#))

Fallopian tubes (fă-LŌP-ē-an): Tubes that transport oocytes from the ovary to the uterus. ([Chapter 7.4](#))

Fibrocystic breasts (fĭ-brŏ-SĪS-tĭk brests): Condition characterized by lumpy or ropelike breast tissue, often experiencing pain, tenderness, and lumpiness especially before menstruation. ([Chapter 7.4](#))

Fimbriae (FĭM-brē-ă): The fringe-like projections at the end of the fallopian tubes, near the ovaries, which help to guide the ovum into the tube after ovulation. ([Chapter 7.4](#), [Chapter 7.5](#))

Fistula (FIS-chŭ-lă): An abnormal passageway between two organs or between an internal organ and the body surface. In the context of the female

reproductive system, it could be between the vagina and another organ such as the urinary bladder, colon, or rectum. ([Chapter 7.5](#))

Follicles (FÖL-ĭ-klz): In the context of the female reproductive system, these are the fluid-filled sacs in the ovaries, each containing an immature ovum (egg). ([Chapter 7.5](#))

Follicle stimulating hormone (FÖL-ĭ-kl stim-YŪ-lā-ting HÖR-mōn) (FSH): A hormone released by the brain that stimulates the growth of ova (eggs) in the ovaries. ([Chapter 7.5](#))

Follicular phase (Föl-ĭk-yŭ-lār fāz): The menstrual cycle phase where the endometrium thickens, and follicle growth is stimulated by FSH and LH. ([Chapter 7.5](#))

Gynecologist (gĭn-ĕ-KOL-ŏ-jĭst): A physician who specializes in the diagnosis and treatment of disorders of the female reproductive system and the breasts. ([Chapter 7.7](#))

Gynecology (gĭ-nĕ-KOL-ŏ-jĕ): Study of the female reproductive system. ([Chapter 7.7](#))

High-grade squamous intraepithelial lesions (hĭ-grād SKWĀ-mŭs ĭn-tră-ĕ-pĭ-THĒ-lĕ-ăl LĒ-zhŭns) (HSIL): More serious changes in the cervical cells that indicate a higher risk of progressing to cervical cancer. ([Chapter 7.6](#))

Hirsutism (HĭR-sŭ-tĭz-ŭm): Excessive hair growth on the face and body, often a symptom of PCOS. ([Chapter 7.6](#))

Hormonal therapy (hŏr-MŌ-năl THĒR-ă-pĕ): Treatment using hormones to block cancer cells from getting the hormones they need to grow. ([Chapter 7.6](#))

HPV test (H-P-V tĕst): A test to check for infection with high-risk types of human papillomavirus that can lead to cervical cancer. ([Chapter 7.6](#))

Human papillomavirus (HYŪ-măn pă-pĭ-lŏ-mă Vĭ-rŭs) (HPV): A group of viruses, some of which can cause genital warts and are associated with an increased risk of cervical and other types of cancers. ([Chapter 7.6](#))

Hysterectomy (his-tĕ-REK-tŏ-mĕ): Surgical removal of the uterus, which may include the cervix, ovaries, fallopian tubes, and other surrounding structures. ([Chapter 7.6](#), [Chapter 7.7](#))

Hysterosalpingogram (hĭs-tĕ-RO-săl-pĭnj-ŏ-gram): A common imaging procedure performed to assess for potential causes of infertility in women.

During the procedure, radiopaque dye is injected into the uterus and fills the uterine cavity, continues into the fallopian tubes, and eventually reaches fimbriated ends next to the ovaries. Structures are visualized with an x-ray. ([Chapter 7.7](#))

Hysteroscopy (his-tě-ROS-kǒ-pē): A procedure to look inside the uterus using a thin, telescope-like device inserted through the vagina and cervix. ([Chapter 7.7](#))

Implantation (ĩm-plan-TĀ-shǒn): The process by which a fertilized egg attaches to the lining of the uterus (endometrium) to begin pregnancy. ([Chapter 7.5](#))

Infertility (ĩn-fěR-TĪL-ĩ-tē): The inability to conceive after a year or more of regular sexual activity without contraception. ([Chapter 7.5](#))

Intrauterine devices (ĨN-tră-yŪ-těR-ēn dī-VĪS-iz): Contraceptive devices inserted into the uterus to prevent pregnancy. ([Chapter 7.6](#))

Irregular bleeding (ĩ-rěg-yŭ-lăR blēd-ing): Bleeding between menstrual periods or after menopause. ([Chapter 7.6](#))

Labia majora (LĀ-bē-uh MĀ-jǒR-uh): Larger outer folds of hair-covered skin that begin just posterior to the mons pubis. ([Chapter 7.4](#))

Labia minora (LĀ-bē-uh mĩ-NŌR-uh): Thinner, hairless, and more pigmented folds found medially to the labia majora, protecting the female urethra and the entrance to the female reproductive tract. ([Chapter 7.4](#))

Lactation (lak-TĀ-shǒn): The process of producing milk in the mammary glands to feed an infant. ([Chapter 7.4](#))

Lactiferous (lak-TĪF-ěr-us) ducts: Tubes carrying milk from the mammary glands (lobules) to the nipple. ([Chapter 7.4](#))

Laparoscopy (lăp-ă-RŌS-kǒ-pē): A surgical procedure using a laparoscope to examine the organs inside the abdomen. ([Chapter 7.6](#))

Laparotomy (lap-uh-ROT-uh-mee): A surgical procedure with a large incision in the abdomen to access the abdominal organs. ([Chapter 7.6](#))

Laser therapy (LĀ-zěr THĒR-ă-pē): The use of an intense light beam (laser) to treat various medical conditions, including removing abnormal cervical tissue. ([Chapter 7.6](#))

Loop electrosurgical excision procedure (lōōp ě-lěk-trō-SŪR-jĩ-kăl ěk-SĪZ-shŭn prō-SĒ-jŭr) (LEEP): A surgical technique used to remove abnormal

cervical tissue using a thin wire loop that carries an electric current. ([Chapter 7.6](#))

Low-grade squamous intraepithelial lesions (lō-grād SKWĀ-mūs ĩn-tră-ě-pĩ-THĒ-lē-ăl LĒ-zhũns) (LSIL): Changes in the cervical cells that are often associated with HPV infection and are typically mild, often resolving on their own. ([Chapter 7.6](#))

Luteinizing hormone (LŪ-tē-ĩ-nĩz-ĩng HŌR-mōn) (LH): A hormone involved in triggering ovulation and the development of the corpus luteum. ([Chapter 7.5](#))

Lymphadenectomy (lĩmf-ăd-ě-NEK-tŏ-mē): Another term for lymph node dissection, often used in the context of cancer treatment. ([Chapter 7.6](#))

Lymph node dissection (lĩmf nŏd dĩ-sěk-shŏn): Surgical removal of lymph nodes to examine for the presence of cancer. ([Chapter 7.6](#))

Mammogram (MĀM-ŏ-grām): An X-ray image of the breast used to detect and diagnose breast abnormalities. ([Chapter 7.6](#), [Chapter 7.7](#))

Mastitis (mas-TĪT-ĩs): Inflammation of the breast, often occurring during lactation. ([Chapter 7.5](#))

Medical oncologists (měd-ĩ-kăl ōn-KOL-ŏ-jĩsts): Physicians specializing in treating cancer with medication. ([Chapter 7.6](#))

Menarche (měn-ĀR-kē): The first occurrence of menstruation in a female. ([Chapter 7.5](#))

Menometrorrhagia (měn-ŏ-mět-rŏ-RĀ-jē-ă): Excessive and prolonged uterine bleeding occurring at irregular and/or frequent intervals. ([Chapter 7.5](#))

Menopause (MEN-ŏ-poz): The end of menstrual cycles in a woman's life, marking the end of reproductive years. ([Chapter 7.6](#))

Menorrhagia (měn-ŏ-RĀ-jē-ă): Excessive menstrual bleeding. ([Chapter 7.5](#), [Chapter 7.6](#))

Menstruation (men-strŪ-Ā-shŏn): The monthly shedding of the endometrial lining in females, typically involving vaginal bleeding. ([Chapter 7.5](#))

Metastasized (mě-tăs-tă-sĩzd): The process by which cancer spreads from the primary site to other parts of the body. ([Chapter 7.6](#))

Metrorrhagia (mē-trŏ-RĀ-jă): Bleeding from the uterus at any time other than normal menstruation. ([Chapter 7.5](#))

Modified radical mastectomy (mōd-ī-fīd rād-ī-kāl mas-TEK-tō-mē):

Surgery removing the entire breast with cancer, most of the lymph nodes, and sometimes other tissues. ([Chapter 7.6](#))

Mons pubis (MÖNZ PYŪ-bīs): A rounded mass of fatty tissue lying over the joint of the pubic bones, becoming covered in hair after puberty. ([Chapter 7.4](#))

Myolysis (mī-OL-ō-sīs): A procedure involving the destruction of fibroids using electric current or freezing. ([Chapter 7.6](#))

Myomectomy (mī-ō-MĚK-tō-mē): Surgical removal of fibroids from the uterus. ([Chapter 7.6](#))

Obstetrics (ōb-STĚT-rīks) (OB): The branch of medicine and surgery concerned with childbirth and the care of women giving birth. ([Chapter 7.7](#))

Oligomenorrhea (ōl-ī-gō-mĕn-ō-RĒ-ă): Infrequent or very light menstruation. ([Chapter 7.5](#))

Omentectomy (ō-mĕn-TEK-tō-mē): Surgical removal of the omentum, a part of the peritoneum in the abdomen. ([Chapter 7.6](#))

Oophorectomy (ō-ō-fō-REK-tō-mē): Surgical removal of one or both ovaries. ([Chapter 7.7](#))

Ovarian cancer (ō-VAR-ē-ăn KAN-sĕr): Cancer that originates in the ovarian tissues. ([Chapter 7.6](#))

Ovarian cyst (ō-VĀR-ē-an sĭst): A fluid-filled sac in the ovary, often part of the normal menstrual cycle or a benign condition. ([Chapter 7.6](#))

Ovary (Ō-vār-ē): Female reproductive gland responsible for producing oocytes (eggs) and hormones. ([Chapter 7.4](#))

Ovulation (ov-yŭ-LĀ-shŏn): The release of an ovum (egg) from the dominant follicle in the ovary, typically occurring around the middle of the menstrual cycle. ([Chapter 7.5](#))

Ovum (Ō-vum): The female reproductive cell, or egg, which, when fertilized by a sperm, can develop into an embryo. ([Chapter 7.5](#))

Papanicolaou smear (păp-ă-NĒ-kă-low smēr) (Pap smear): A screening procedure for cervical cancer and precancerous conditions, involving the collection of cells from the cervix. ([Chapter 7.6](#), [Chapter 7.7](#))

Pelvic inflammatory disease (PĚL-vĭk ĭn-flă-MĀ-tō-rĕ) (PID): An infection of the female reproductive organs, often caused by sexually transmitted infections. ([Chapter 7.6](#))

Perineum (pěr-ĭ-NĒ-um): The area between the vaginal opening and the anus. ([Chapter 7.4](#))

Peritoneum (pěr-ĭ-tō-NĒ-ŭm): The membrane lining the abdominal cavity and covering most of the abdominal organs. ([Chapter 7.6](#))

Polycystic ovary syndrome (pōl-ē-SĪS-tĭk Ō-vă-rē SĪN-drōm) (PCOS): A hormonal disorder causing enlarged ovaries with small cysts on the outer edges. ([Chapter 7.6](#))

Polymenorrhea (pōl-ē-mĕn-ō-RE-ă): Condition characterized by frequent menstrual cycles, shorter than 21 days in length. ([Chapter 7.5](#))

Premenstrual dysphoric disorder (prē-MĒN-strŭ-ăl dis-FŌR-ĭk) (PMDD): A severe form of PMS characterized by significant mood disturbances. ([Chapter 7.6](#))

Premenstrual syndrome (prē-MĒN-strŭ-ăl SĪN-drōm) (PMS): A group of symptoms that occur in women, typically between ovulation and a period. ([Chapter 7.6](#))

Progesterone (pro-JĚS-tĕr-ōn): A hormone released by the corpus luteum in the ovary. It plays a role in the menstrual cycle and in maintaining the early stages of pregnancy. ([Chapter 7.5](#))

Prolapse (PRŌ-laps): The slipping down or displacement of an organ or part, such as the uterus. ([Chapter 7.6](#))

Radiation oncologists (rā-dē-Ā-shŏn ōn-KOL-ŏ-jĭsts): Doctors who treat cancer using radiation therapy. ([Chapter 7.6](#))

Radiation therapy (rā-dē-Ā-shŏn THĚR-ă-pē): The use of high-energy rays to kill or damage cancer cells. ([Chapter 7.6](#))

Radical hysterectomy (răd-ĭ-kăl his-tĕ-REK-tŏ-mē): Extensive surgery to remove the uterus, cervix, part of the vagina, and sometimes other tissues for cancer treatment. ([Chapter 7.7](#))

Rectocele (RĚK-tŏ-sēl): A posterior vaginal prolapse where the rectum protrudes into the vagina. ([Chapter 7.6](#))

Salpingectomy (sal-pĭn-JEK-tŏ-mē): Surgical removal of one or both Fallopian tubes. ([Chapter 7.7](#))

Salpingo-oophorectomy (săl-pĭng-gŏ-ŏ-ŏf-ŏ-REK-tŏ-mē): Removal of a Fallopian tube and its corresponding ovary. ([Chapter 7.7](#))

Sexual intercourse (Sĕk-shū-ăl ĩn-tĕr-kōrs): The physical act of sex, involving the insertion of the penis into the vagina. ([Chapter 7.5](#))

Speculum (SPEK-yŭ-lŭm): An instrument used to widen the opening of the vagina during medical examinations. ([Chapter 7.6](#), [Chapter 7.7](#))

Subtotal hysterectomy (sŭb-tō-tăl his-tĕ-REK-tŏ-mĕ): Removal of part of the uterus, leaving the cervix in place. ([Chapter 7.7](#))

Surgeons (SŬR-jŏns): Medical doctors who perform operations. ([Chapter 7.6](#))

Surgery (SŬR-jĕr-ĕ): Medical procedures involving the manual and instrumental techniques to treat diseases, injuries, or deformities. ([Chapter 7.6](#))

Tampon (TĀM-pon): A plug of soft material inserted into the vagina to absorb menstrual blood. ([Chapter 7.6](#))

Targeted therapy (TĀR-gĭ-tĕd THĚR-ă-pĕ): Treatment that uses drugs to target specific molecules involved in cancer growth and progression. ([Chapter 7.6](#))

Total abdominal hysterectomy (tō-tăl ăb-DŎM-ĭ-năl his-tĕ-REK-tŏ-mĕ): Removal of the uterus through an incision in the abdomen. ([Chapter 7.7](#))

Total hysterectomy (tō-tăl his-tĕ-REK-tŏ-mĕ): Removal of the entire uterus, including the cervix. ([Chapter 7.7](#))

Total hysterectomy/bilateral salpingectomy oophorectomy (tō-tăl his-tĕ-REK-tŏ-mĕ / bĭ-LĀT-ĕr-ăl săl-pĭn-JEK-tŏ-mĕ ō-ŏ-fŏ-REK-tŏ-mĕ) (TAH/BSO): A surgical procedure involving the removal of the uterus (hysterectomy), both Fallopian tubes (salpingectomy), and both ovaries (oophorectomy). ([Chapter 7.7](#))

Total laparoscopic hysterectomy (tō-tăl lăp-ăr-ŏ-SKŌP-ĭk his-tĕ-REK-tŏ-mĕ): Removal of the uterus using laparoscopic techniques, involving small incisions and a camera. ([Chapter 7.7](#))

Total mastectomy (tō-tăl mas-TEK-tŏ-mĕ): Surgical removal of the entire breast that has cancer. ([Chapter 7.6](#))

Toxic shock syndrome (TŌK-sĭk SHŌK SĬN-drŏm): A rare, life-threatening complication of certain bacterial infections, associated with tampon use. ([Chapter 7.6](#))

Transvaginal ultrasound (trăns-vă-jǐ-năl ŮL-tră-sound): An ultrasound procedure where a probe is inserted. ([Chapter 7.7](#))

Tubal ligation (TOO-băl lī-GĀ-shǒn): A permanent surgical procedure for female sterilization, involving sealing, tying, or cutting the Fallopian tubes. ([Chapter 7.5](#), [Chapter 7.7](#))

Tubo-ovarian abscess (TŪ-bō ō-VAR-ē-ăn ăb-sēs): An inflammatory mass involving the fallopian tube and ovary, often a complication of PID. ([Chapter 7.6](#))

Uterine artery embolization (ŪT-ě-rĭn ăr-těr-ē ěm-bō-lǐ-ZĀ-shǒn): Another term for uterine fibroid embolization. ([Chapter 7.6](#))

Uterine fibroid (ŪT-ě-rĭn FĪ-brǒyd): Benign tumors in the muscular wall of the uterus. ([Chapter 7.6](#))

Uterine fibroid embolization (ŪT-ě-rĭn FĪ-brǒyd ěm-bō-lǐ-ZĀ-shǒn): A procedure to block blood flow to fibroids, causing them to shrink. ([Chapter 7.6](#))

Uterine prolapse (ŪT-ě-rĭn PRŌ-laps): A condition where the uterus sags or slips from its normal position into the vaginal canal. ([Chapter 7.6](#))

Uterus (YŪ-těr-us): A muscular, pear-shaped organ responsible for housing and nourishing a developing fetus. ([Chapter 7.4](#))

Vagina (vă-JĪN-uh): A muscular canal serving as the entrance to the reproductive tract and the exit from the uterus during menstruation and childbirth. ([Chapter 7.4](#))

Vaginal candidiasis (vă-jǐ-năl kăn-dĭ-DĪ-ă-sĭs): A fungal infection in the vagina, commonly known as a yeast infection, causing itching and a thick, white discharge. ([Chapter 7.6](#))

Vaginal hysterectomy (vă-jǐ-năl his-tě-REK-tǒ-mē): Removal of the uterus through the vagina. ([Chapter 7.7](#))

Vaginal prolapse (vă-jǐ-năl PRŌ-laps): A condition where the vagina itself sags or slips out of its normal position. ([Chapter 7.6](#))

Vulva (VŮL-vă): The external part of the female genitalia, which includes the labia majora, labia minora, clitoris, and the opening of the vagina. ([Chapter 7.4](#))

PART VIII

CHAPTER 8 OBSTETRICS TERMINOLOGY


8.1 Obstetrics Introduction

Learning Objectives

- Apply the rules of medical language to build, analyze, spell, pronounce, abbreviate, and define terms as they relate to obstetrics
- Identify meanings of key word components related to obstetrics
- Categorize diagnostic, therapeutic, procedural, or anatomic terms related to obstetrics
- Use terms related to obstetrics
- Use terms related to obstetric disorders

Introduction to Obstetrics

Obstetrics (ŏb-STE-triks) (**OB**) is a medical specialty concerning care of the mother and fetus during pregnancy, childbirth, and immediately after childbirth. This chapter will review common word components related to fertilization, pregnancy, and childbirth to assist learning how to analyze, build, and define medical terms. Other terms whose definitions cannot be easily built from word components will be described in context. Medical specialists, diagnostic tests, and procedures related to fertilization, pregnancy, and childbirth will also be discussed. Additional information about the female reproductive system is discussed in the “[Female Reproductive System Terminology](#)” chapter.

View this YouTube video¹ for an introduction to
 pregnancy and development: [Reproductive System, Part 4 – Pregnancy & Development: Crash Course A&P #43](https://youtu.be/BtsSbZ85yiQ?si=DSdQWrT6Gels3QxG)

1. CrashCourse. (2015, November 23). *Reproductive system, Part 4 – Pregnancy & development: Crash Course Anatomy & Physiology #43* [Video]. YouTube. All rights reserved. <https://youtu.be/BtsSbZ85yiQ?si=DSdQWrT6Gels3QxG>

8.2 Word Components Related to Obstetrics

This section will describe common word components related to fertilization, pregnancy, and childbirth. These word components help build definitions for many medical terms. Other common prefixes are described in [Chapter 1.3](#), and common suffixes are described in [Chapter 1.5](#).

COMMON PREFIXES RELATED TO OBSTETRICS

- **ante-**: Before
- **dys-**: Painful, labored, difficult
- **intra-**: Within
- **micro-**: Small
- **multi-**: Many
- **neo-**: New
- **nulli-**: None
- **post-**: After
- **pre-**: Before

COMMON WORD ROOTS WITH A COMBINING VOWEL RELATED TO OBSTETRICS

- **amni/o, amnion/o**: Amnion, amniotic fluid
- **cephal/o**: Head
- **chori/o**: Chorion
- **embryo/o**: Embryo
- **episi/o**: Vulva
- **esophag/o**: Esophagus
- **fet/o** or **fet/i**: Fetus, unborn offspring
- **gravid/o**: Pregnancy
- **hydr/o**: Water
- **lact/o**: Milk
- **nat/o**: Birth
- **olig/o**: Scanty, few
- **omphal/o**: Umbilicus, navel
- **par/o**: To bear, labor, childbirth, give birth to
- **part/o**: To bear, labor, childbirth, give birth to
- **prim/i**: First
- **pseud/o**: False
- **puerper/o**: Childbirth
- **pylor/o**: Pylorus, pyloric sphincter
- **terat/o**: Malformations

COMMON SUFFIXES RELATED TO OBSTETRICS

- **-a**: No meaning, noun ending

- **-al**: Pertaining to
- **-amnios**: Amnion, amniotic fluid
- **-centesis**: Surgical withdrawal of fluid
- **-cyesis**: Pregnancy
- **-e**: Noun ending, no meaning
- **-gen**: Substance that produced, agent that produced
- **-genic**: Producing, originating, causing
- **-graphy**: Process of recording
- **-ic**: Pertaining to
- **-is**: Noun suffix, no meaning
- **-itis**: Inflammation
- **-logist**: Specialist who studies and treats
- **-logy**: Study of
- **-oid**: Resembling
- **-oma**: Tumor
- **-rrhea**: Discharge, flow
- **-rrhexis**: Rupture
- **-stenosis**: Constriction, narrowing
- **-tocia**: Birth, labor
- **-tomy**: Incision, cut into
- **-um**: Noun ending, no meaning
- **-us**: Noun ending, no meaning

8.3 Examples of Obstetrical Terms Easily Defined By Their Word Components

Here are examples of common medical terms related to obstetrics that can be easily defined by breaking the terms into their word components.

Amniocentesis

1. Break down the medical term into word components:
Amni/o/centesis
2. Label the word components: **Amni** = WR; **o** = CV; **centesis** = S
3. Define the word components: **Amni** = amniotic fluid; **centesis** = surgical withdrawal of fluid
4. Create a final definition of the medical term: **Surgical withdrawal of amniotic fluid**

Postpartum

1. Break down the medical term into word components:
Post/part/um
2. Label the word parts: **Post** = P; **part** = WR
3. Define the word components: **Post** = after; **part** =

childbirth; **um**=no meaning

4. Create a final definition of the medical term: **After childbirth**

Teratogenic

1. Break down the medical term into word components:
Terat/o/genic
2. Label the word parts: **Terat** = WR; **o** = CV; **genic** = S
3. Define the word components: **Terat** = malformations;
genic = producing
4. Create a final definition of the medical term: **Producing malformations**



Interactive Learning Activity: Practice defining and pronouncing obstetrics medical terms by breaking them down into word parts.



An interactive H5P element has been excluded from this version of the text. You can view it online here:

<https://wtcs.pressbooks.pub/medterm/?p=4273#h5p-40>

- You can also print this as a [Chapter 8 Student Companion Worksheet](#) and check your answers with this [Answer Key](#).

8.4 Fertilization, Pregnancy, Labor, Delivery, Newborn Care, and Postpartum Care

FERTILIZATION

There are two types of gametes involved in reproduction: the male gametes, called sperm, and female gametes, called ova. The male gametes are produced in the testes through a process called spermatogenesis, which begins at about 12 years of age. The female gametes are present at birth but are immature. They are stored in the ovaries until puberty, when one ovum ripens and is released about every 28 days in a process called **oogenesis** (ō-ō-JEN-ě-sīs).¹

After the ovum is released from the ovary, it is drawn into the Fallopian tube. If sexual intercourse occurs, millions of sperm are ejaculated into the vagina, but only a few reach the ovum. **Fertilization** (fě-r-tī-lī-zā-shōn) occurs when a sperm and an ovum combine, also referred to as **conception** (kōn-SEP-shōn). See Figure 8.1² for an image of conception.

1. This work is a derivative of [Lifespan Development](#) by Julie Lazzara and is licensed under [CC BY 4.0](#)

2. "[Sperm-egg.jpg](#)" by Unknown author is licensed in the [Public Domain](#).

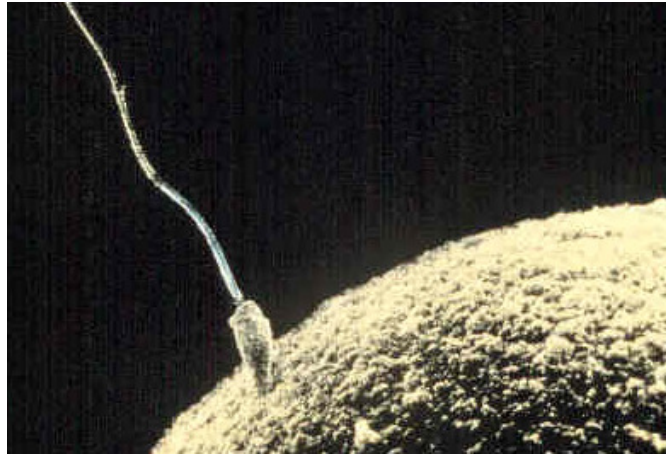


Figure 8.1 Conception

After a single sperm has entered the ovum, the wall of the ovum becomes hard and prevents other sperm from entering. The head of the sperm, containing the genetic information from the father, unites with the nucleus of the ovum, and a new cell is formed. Reproductive cells are haploid cells containing half of the genetic material needed to form a human being, so their combination forms a diploid cell called a **zygote** (ZĪ-gōt).³

During the first week after conception, the zygote divides and multiplies, going from a one-cell structure to two cells, then four cells, then eight cells, and so on. This process of cell division is called **mitosis** (mī-TŌ-sīs). The zygote continues to divide and travel through the Fallopian tube for about 7-10 days, at which point it arrives in the uterus. Once in the uterus, the zygote implants itself in the **endometrium** (en-dō-MĒ-trē-ŭm), the inner lining of the uterus, where the embryonic stage begins about three weeks after conception.⁴

Human chorionic gonadotropin (hū-MĀN kor-ē-ON-ĭk gō-năd-ō-TRO-pin) is a hormone produced by cells that will eventually make up the placenta in

3. This work is a derivative of [Lifespan Development](#) by Julie Lazzara and is licensed under [CC BY 4.0](#)

4. This work is a derivative of [Lifespan Development](#) by Julie Lazzara and is licensed under [CC BY 4.0](#)

the early stages of pregnancy. HCG can be detected by a blood pregnancy test at around 7-12 days after conception and by a urine pregnancy test about two weeks after conception. HCG increases quickly (almost doubling every three days) for the first eight to ten weeks of pregnancy.⁵



View the following YouTube video⁶ illustrating conception: [Fertilization](#)

EMBRYONIC STAGE

An **embryo** (EM-brē-ō) is an organism in its early stages of development, specifically from Day 16 through Week 8. See Figure 8.2⁷ for an image of a human embryo.

5. Cleveland Clinic. (2022, March 11). *Human chorionic gonadotropin*. <https://my.clevelandclinic.org/health/treatments/4423-vasectomy>

6. Nucleus Medical Media. (2013, January 31). *Fertilization* [Video]. YouTube. All rights reserved. https://youtu.be/_5OvgQW6FG4?si=sITDwkcpfKtYJ9LC

7. “9-Week_Human_Embryo_from_Ectopic_Pregnancy.jpg” by Ed Uthman from Houston, TX, USA is licensed under [CC BY 2.0](#)

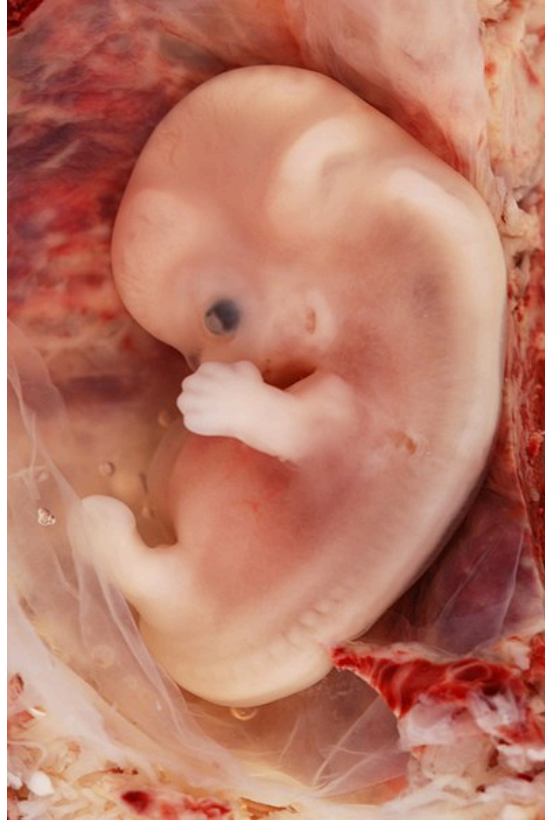

Figure 8.2 Human Embryo

During the embryonic stage, blood vessels grow, forming the placenta. The **placenta** (plă-SEN-tă) is a structure that connects the fetus to the uterus, providing oxygen and nutrients from the mother to the developing embryo via the **umbilical cord** (ŭm-BĬL-ĭ-kăl kōrd). Basic structures of the embryo start to develop into areas that will become the head, chest, and abdomen. During the embryonic stage, the heart begins to beat, and organs form and begin to function. At 22 days after conception, the neural tube forms along the back of the embryo, developing into the spinal cord and brain.⁸

About 20 percent of embryos do not successfully make it through the embryonic stage, usually due to chromosomal abnormalities. It is during this stage that the major structures of the body are forming, making the

8. This work is a derivative of [Lifespan Development](#) by Julie Lazzara and is licensed under [CC BY 4.0](#)

embryonic period a vulnerable time if the embryo is exposed to a harmful substance. **Teratogens** (těr-AT-ŏ-jěnz), agents that cause malformations in a developing embryo, include alcohol, drugs, diseases, chemicals, and environmental exposures. Many mothers are not aware they are pregnant during the embryonic period, further increasing the risk of teratogen exposure to the developing embryo.⁹

FETAL STAGE

When the embryo is about nine weeks old until birth, it is called a **fetus** (FĒ-tŭs). At the beginning of this stage, the fetus is about the size of a kidney bean and begins to take on the recognizable form of a human being. See Figure 8.3¹⁰ for an image of an early fetus.

9. This work is a derivative of [Lifespan Development](#) by Julie Lazzara and is licensed under [CC BY 4.0](#)

10. [“Human fetus 10 weeks with amniotic sac - therapeutic abortion.jpg”](#) by [suparna sinha](#) is licensed under [CC BY-SA 2.0](#)

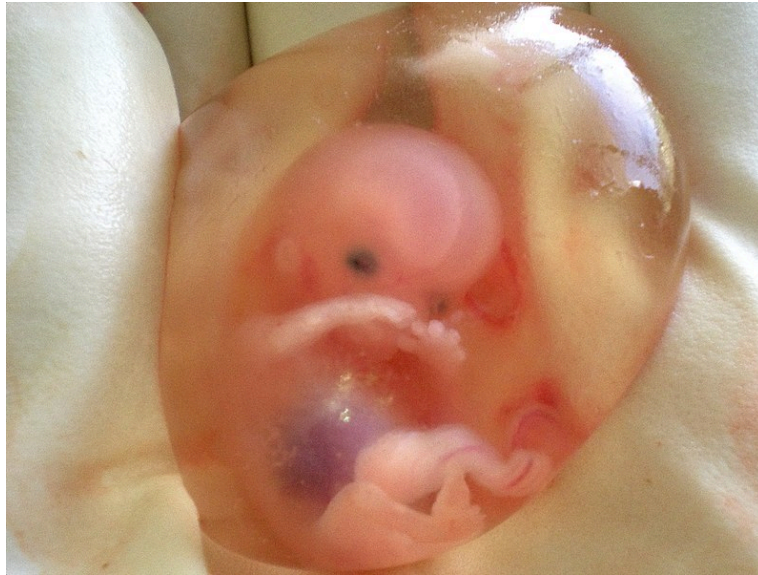

Figure 8.3 Fetus

Mothers experience **quickening** (KWĪK-ĕn-ĭng), the first feeling of movement of the fetus in utero, around 16 to 20 weeks. By the time the fetus reaches the sixth month of development (23-24 weeks), it weighs up to 1.4 pounds. Hearing has developed, so the fetus can respond to sounds. The internal organs, such as the lungs, heart, stomach, and intestines, have formed enough that a fetus born prematurely at this point has a chance of survival with intensive medical care.

Between the seventh and ninth months, the fetus is primarily preparing for birth. It is exercising its muscles, and its lungs begin to expand and contract. Around 36 weeks, the fetus is almost ready for birth. It weighs about six pounds and is about 18.5 inches long. By Week 37 all organ systems are developed enough that the fetus could survive outside the mother's uterus without many of the risks associated with premature birth. The fetus

continues to gain weight and grow in length until approximately 40 weeks. See Figure 8.4¹¹ for an illustration of fetal growth.¹²

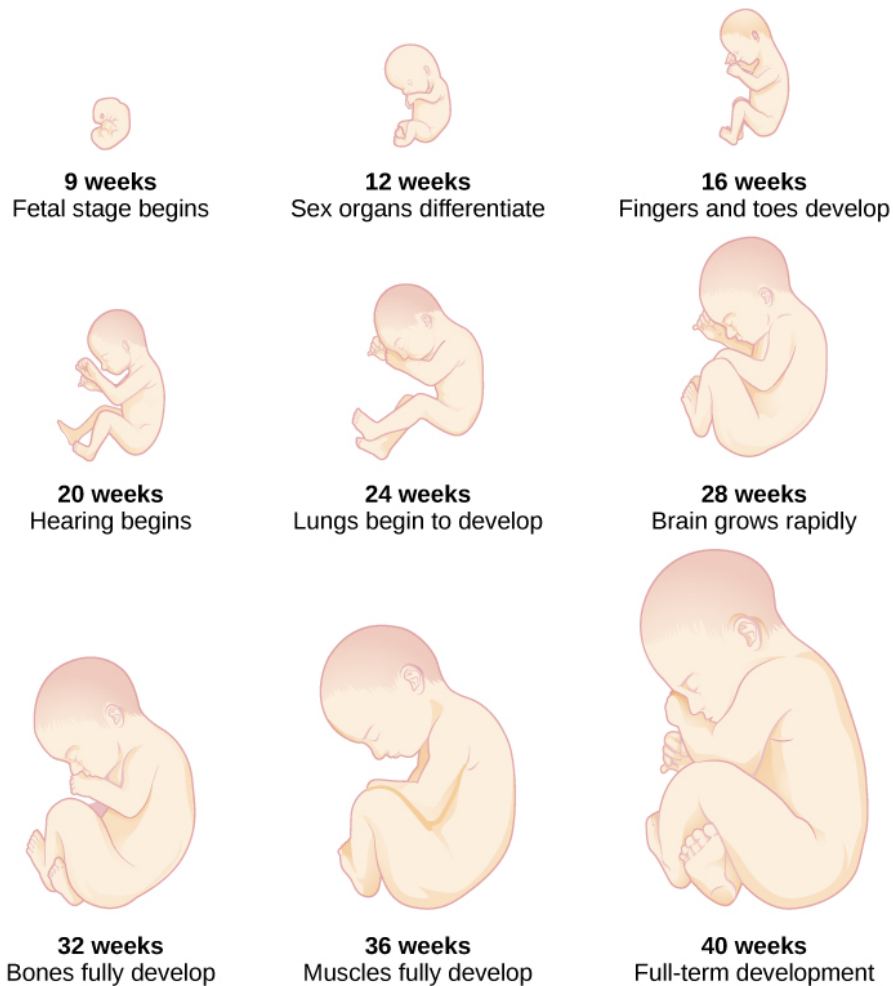

Figure 8.4 Fetal Growth

11. “CNX_Psych_09_02_Stages.jpg” by unknown author is licensed under [CC BY 4.0](#). Access for free at <https://open.maricopa.edu/devpsych/chapter/chapter-2-genetics-and-prenatal-development/>

12. This work is a derivative of [Lifespan Development](#) by Julie Lazzara and is licensed under [CC BY 4.0](#)

View the following TED Talk video¹³ showing human development from conception on: [Conception to Birth – Visualized](https://www.ted.com/talks/alexander_tsiaras_conception_to_birth_visualized)

PREGNANCY

A full-term pregnancy lasts approximately 270 days (approximately 38.5 weeks) from conception to birth. Because it is easier to remember the first day of the **last menstrual period** (last MEN-strū-ăl PĒ-rē-öd) (**LMP**) than to estimate the date of conception, obstetricians set the due date as 284 days (approximately 40.5 weeks) from the LMP. This assumes that conception occurred on Day 14 of the woman's cycle. These 40 weeks of pregnancy are usually discussed in terms of three **trimesters** (TRĪ-mēs-těrz), each trimester lasting approximately 13 weeks.

During the first trimester, it is common for the mother to experience nausea as a result of higher levels of estrogen in her body, commonly called “morning sickness.” Other symptoms during pregnancy may include

13. Tsiaras, A. (2010, December). *Conception to birth — Visualized* [Video]. Ted.com. All rights reserved. https://www.ted.com/talks/alexander_tsiaras_conception_to_birth_visualized

heartburn, gas, hemorrhoids, backache, leg cramps, insomnia, constipation, and varicose veins.¹⁴ See Figure 8.5¹⁵ for an image of a pregnant woman.



Figure 8.5 Pregnancy

Labor and Delivery

The process of childbirth, referred to as labor and delivery, is divided into three stages:

- First Stage: Cervical dilation

¹⁴. This work is a derivative of [Lifespan Development](#) by Julie Lazzara and is licensed under [CC BY 4.0](#)

¹⁵. “[PregnantWoman.jpg](#)” by [Ken Hammond](#) is licensed in the [Public Domain](#).

- Second Stage: Expulsion or birth
- Third Stage: Delivery of the placenta

See Figure 8.6¹⁶ for an illustration of childbirth.

¹⁶. [“2920_Stages_of_Childbirth-02.jpg”](#) by OpenStax College is licensed under [CC BY 4.0](#)

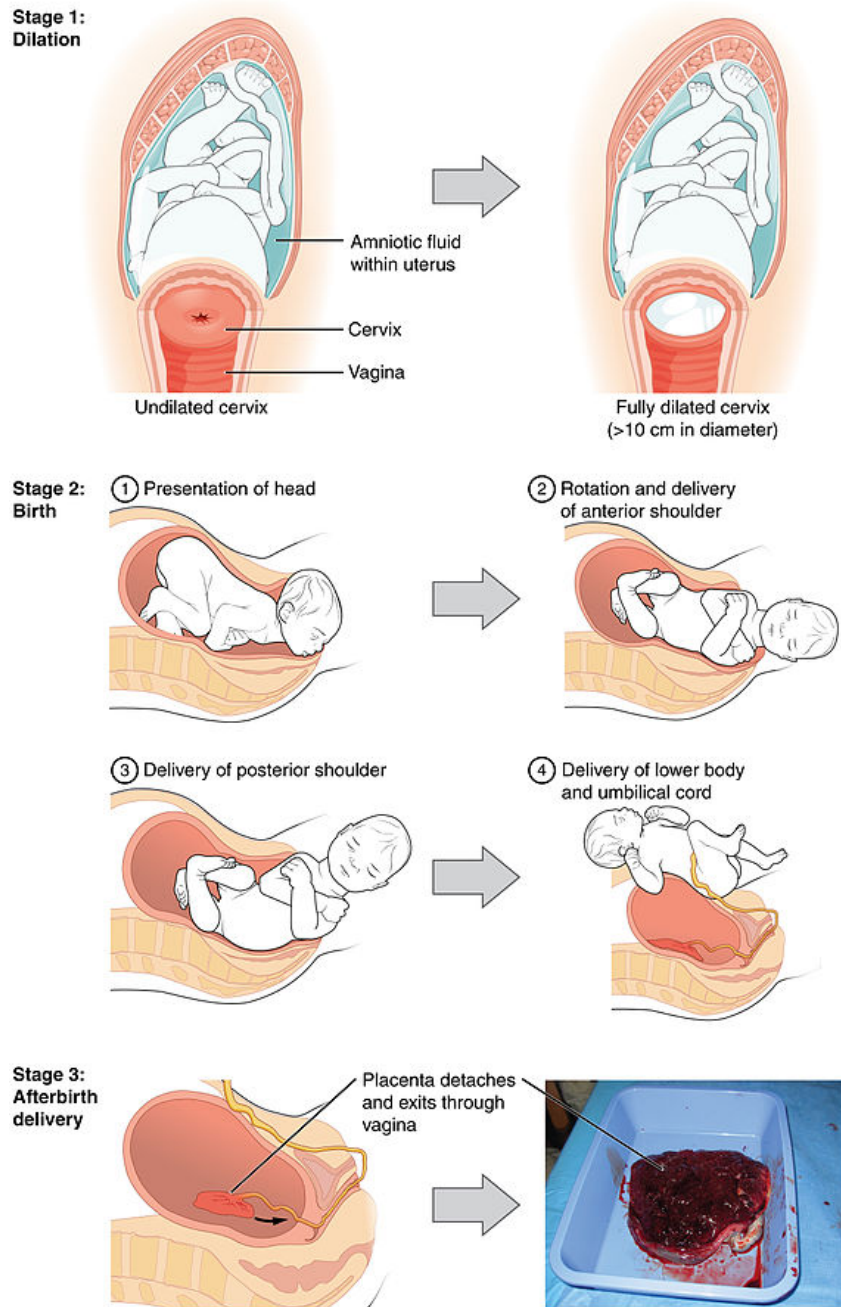


Figure 8.6 Stages of Childbirth

First Stage: Cervical Dilation

The first stage of labor begins with uterine contractions that initially last about 30 seconds and are spaced 15 to 20 minutes apart. Uterine contractions are the rhythmic tightening and shortening of the uterine muscles during labor. These contractions increase in duration and frequency to more than a

minute long and three to four minutes apart. Women are typically advised to go to the hospital for delivery when contractions are coming about every five minutes. Some women experience **Braxton-Hicks** (BRAX-tŏn HIKS) contractions, which are irregular false contractions that occur before actual labor begins. Women are counseled that real labor pains typically increase with walking, resulting in the cessation of walking until the contraction stops. Labor may also begin with clear or pink-tinged mucus discharge (called a mucus plug) or a gush of amniotic fluid.¹⁷

During labor, the cervix dilates to ten centimeters (just under four inches) so it is wide enough to deliver the newborn's head. Dilation may take around 12-16 hours for woman delivering their first child or about 6-9 hours for women who have previously given birth. However, labor varies widely among women and may take over 24 hours. In each subsequent labor, the labor stage tends to be shorter.¹⁸

Second Stage: Expulsion or Birth

The second stage involves the passage of the baby through the birth canal. **Parturition** (pär-tū-RĪSH-ŭn) is a medical term for the act of giving birth. This stage takes about 10-40 minutes. Contractions usually come about every 2-3 minutes, and the mother pushes and relaxes as directed by the medical staff.

Normally, the head of the baby emerges first, referred to as a **cephalic presentation** (sě-FAL-ĭk prē-zen-TĀ-shŏn). **Crowning** (KROWN-ĭng) refers to the appearance of the baby's head at the vaginal opening.

The baby's head is turned when it is in the head-down position, referred to as **cephalic version** (sě-FAL-ĭk VĚR-zhŏn), so that one shoulder can emerge,

17. This work is a derivative of [Lifespan Development](#) by Julie Lazzara and is licensed under [CC BY 4.0](#)

18. This work is a derivative of [Lifespan Development](#) by Julie Lazzara and is licensed under [CC BY 4.0](#)

followed by the other shoulder. The rest of the baby quickly passes through, and then the umbilical cord is clamped and cut.¹⁹

In some cases, the baby is not in a head-down position during labor and delivery. **Breech** (brēch) refers to a feet-first position that requires additional interventions by medical staff and perhaps delivery by cesarean section.

Third Stage: Delivery of Placenta

The third stage is relatively painless in comparison to the other stages. During this stage, the placenta is delivered. This typically occurs within 20 minutes after delivery of the baby.²⁰ Following delivery, if the mother experienced tearing of the perineum, it is repaired by the obstetrician or midwife. The **perineum** (pěr-ĭ-NĒ-ŭm) is the area between the vagina and the anus. An **episiotomy** (ěp-ĭ-zē-OT-ŏ-mē) is a surgical incision of the vulva to widen the vaginal opening to prevent ripping or tearing of the perineum during delivery.



View the following YouTube video²¹ on childbirth: [Patient Education Animation: Labor and Vaginal Birth](#)

19. This work is a derivative of [Lifespan Development](#) by Julie Lazzara and is licensed under [CC BY 4.0](#)

20. This work is a derivative of [Lifespan Development](#) by Julie Lazzara and is licensed under [CC BY 4.0](#)

21. Nucleus Medical Media. (2012, August 20). *Patient education animation: Labor and vaginal birth* [Video]. YouTube. All rights reserved. https://youtu.be/ZDP_ewMDxCo?si=kFvTtxtkYvr0TH8Te

Cesarean Section

Cesarean section (si-ZAR-ē-ăn SEK-shŏn), also known as C-section, is delivery of the fetus through an abdominal incision made by the obstetrician.

Cesarean sections are performed when a vaginal delivery would put the baby or mother at risk. Common reasons for C-sections include obstructed labor based on the shape of the mother's pelvis, breech presentation of the baby, complications with the placenta or umbilical cord, twin pregnancy, or high blood pressure in the mother.²²

Newborn Assessment

The average newborn weighs approximately 7.5 pounds. In the minutes following birth, a newborn must undergo dramatic body system changes to be able to survive outside the womb. The **Apgar score** (AP-gar skŏr) is an evaluation of a newborn's physical condition within one to five minutes after birth and was developed by and named for Virginia Apgar (making this an eponym).

The technique for determining an Apgar score is quick, easy, painless, and does not require any instruments except for a stethoscope. A convenient way to remember the five scoring criteria is to apply the mnemonic APGAR²³:

- **A**pppearance (skin color)
- **P**ulse (heart rate)
- **G**rimace (reflex)
- **A**ctivity (muscle tone)
- **R**espiration

22. This work is a derivative of [Lifespan Development](#) by Julie Lazzara and is licensed under [CC BY 4.0](#)

23. This work is a derivative of [Anatomy & Physiology](#) by [OpenStax](#) and is licensed under [CC BY 4.0](#). Access for free at <https://openstax.org/books/anatomy-and-physiology/pages/1-introduction>

Skin color, heart rate, reflex, muscle tone, and respiration are assessed, and each criterion is assigned a score of 0, 1, or 2. Scores are taken at one minute after birth and again at five minutes after birth. After each time the scores are taken, the five scores are added together. High scores (out of a possible 10) indicate the baby has made the transition well, whereas lower scores indicate that the baby may be in distress. See Figure 8.7²⁴ for APGAR criteria.²⁵

APGAR Evaluation of newborn infants			
SIGN	0	1	2
Heart rate	Absent	Below 100	Over 100
Respiratory effort	Absent	Slow, irregular	Good, crying
Muscle tone	Limp	Some flexion	Active motion
Reflex*	No response	Grimace	Cough or sneeze
Color	Blue, Pale	Body pink, Extremities blue	Completely pink
➤ 7 to 10 is normal ➤ 4 to 6 is moderately depressed ➤ 0 to 3 needs immediate resuscitation			

*Response to catheter in nostrils

Figure 8.7 APGAR

Of the five Apgar criteria, heart rate and respiration are the most critical. Poor scores for either of these measurements may indicate the need for immediate medical attention to resuscitate or stabilize the newborn. In

24. “APGAR_score.jpg” by [Dr.Vijaya chandar](#) is licensed under [CC BY-SA 4.0](#)

25. This work is a derivative of [Anatomy & Physiology](#) by [OpenStax](#) and is licensed under [CC BY 4.0](#). Access for free at <https://openstax.org/books/anatomy-and-physiology/pages/1-introduction>

general, any score lower than 7 at the five-minute mark indicates that medical assistance may be needed. A total score below 5 indicates an emergency situation. Normally, a newborn will get an intermediate score of 1 for some of the Apgar criteria and will progress to a 2 by the five-minute assessment. Scores of 8 or above are normal.²⁶

Many newborns are covered with **lanugo** (lă-NOO-gō), a fine, downy hair and **vernix** (VĚR-nĭks), a white, waxy substance covering the skin. Within 24-48 hours of birth, newborns pass their first stool, called **meconium** (mē-KŌ-nē-ŭm). Meconium is dark, thick, and sticky. Sometimes a fetus passes meconium if they are stressed during labor and delivery. If the fetus inhales meconium into the lungs in utero, it can cause severe respiratory complications. This condition is called **meconium aspiration** (mě-KŌ-nē-ŭm AS-pĭ-RĀ-shŏn).

POSTPARTUM PERIOD

The **postpartum** (pōst-PĀR-tŭm) period begins immediately after childbirth as the mother's body, including hormone levels and uterus size, returns to a nonpregnant state. The terms puerperium, puerperal period, or postpartum period are commonly used to refer to the first six weeks following childbirth. During this time, the mother is monitored for bleeding, bowel and bladder function, and baby care. The infant's health is also monitored, and vaccines are administered. The postpartum period can be divided into three stages²⁷:

26. This work is a derivative of [Anatomy & Physiology](#) by [OpenStax](#) and is licensed under [CC BY 4.0](#). Access for free at <https://openstax.org/books/anatomy-and-physiology/pages/1-introduction>

27. This work is a derivative of [Lifespan Development](#) by Julie Lazzara and is licensed under [CC BY 4.0](#)

- Acute phase: Six to 12 hours after childbirth
- Subacute postpartum period: Two to six weeks after childbirth
- Delayed postpartum period, which can last up to six months.

Acute Phase

The first 6 to 12 hours after childbirth is the initial or acute phase of the postpartum period. During this time the mother is monitored by nurses or midwives for potential complications such as postpartum hemorrhage. Immediately after childbirth, the infant is placed directly on the mother's chest whenever possible. See Figure 8.8²⁸ for an image of chest-to-chest positioning of the mother and infant.²⁹

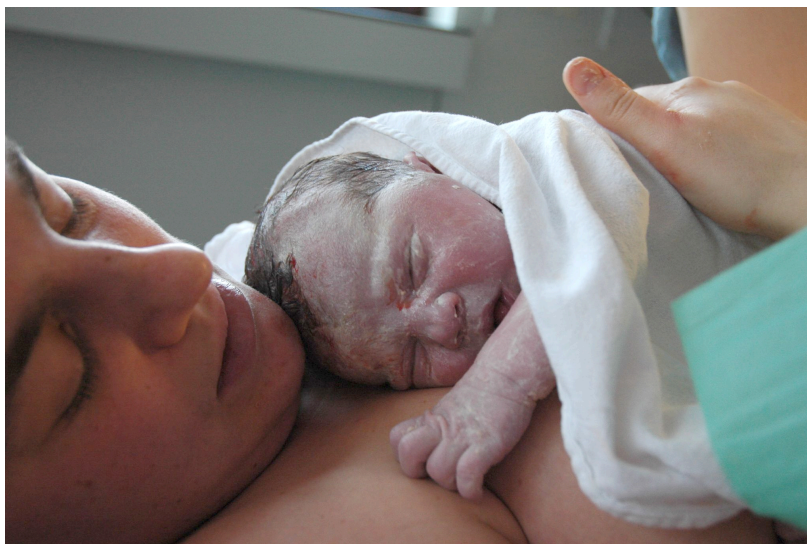

Figure 8.8 Postpartum Chest to Chest Positioning

28. "[Postpartum_baby2.jpg](#)" by [Tom Adriaenssen](#) is licensed under [CC BY-SA 2.0](#)

29. This work is a derivative of [Lifespan Development](#) by Julie Lazzara and is licensed under [CC BY 4.0](#)

The greatest health risk during the acute phase is postpartum bleeding. Following delivery, the area where the placenta was attached to the uterine wall bleeds, and the uterus must contract to prevent blood loss. After contraction takes place, the fundus (top) of the uterus can be palpated as a firm mass at the level of the navel. It is important that the uterus remains firm, and nurses or midwife will make frequent assessments of both the fundus and the amount of bleeding. Uterine massage is commonly used to help the uterus contract and prevent postpartum hemorrhage.³⁰

Subacute Postpartum Period

The subacute postpartum period lasts two to six weeks. During this time, **lochia** (LŌ-kē-ă), vaginal discharge after birth, will turn color from bright red, to brownish, to yellow. It will gradually decrease in amount and cease at around five or six weeks.³¹

At two to four days postpartum, a woman's breast milk will generally come in and is called **lactation** (lăk-TĀ-shŏn). Mothers are encouraged to breastfeed their babies every three hours during the day and night. During pregnancy and the first few days after delivery, **colostrum** (kŏ-LOS-trŭm), a thin, milky fluid, is secreted by the breast. Colostrum is rich in immunoglobulin A (IgA), which helps protect the infant from infection. Colostrum also helps to establish a normal gut microbiome in the infant and further protects against infection. Human colostrum is ideal for newborns and is preferable over formula or milk from other animals.³²

30. This work is a derivative of [Lifespan Development](#) by Julie Lazzara and is licensed under [CC BY 4.0](#)

31. This work is a derivative of [Lifespan Development](#) by Julie Lazzara and is licensed under [CC BY 4.0](#)

32. This work is a derivative of [StatPearls](#) by Jozsa & Thistle and is licensed under [CC BY 4.0](#)

Approximately 70-80% of postpartum women will experience the “baby blues” for a few days due to the rapid change in hormone levels. However, some women experience more serious clinical depression during pregnancy or after childbirth, referred to as **peripartum depression** (pěr-ĩ-PÄR-tŭm di-PRESH-ŭn), also known as postpartum depression. They may feel depressed, anxious, guilty, agitated, or weepy. They may not want to hold or care for their newborn, even in cases in which the pregnancy was desired and intended. Family and friends who recognize these symptoms in a pregnant or postpartum woman should encourage them to see a health care provider for treatment.³³

Delayed Postpartum Period

The delayed postpartum period starts after the subacute postpartum period and lasts up to six months. During this time, the mother’s muscles and connective tissue return to a pre-pregnancy state. During this period, infant sleeping during the night gradually increases and maternal sleep generally improves.³⁴

Other Definitions Related to Obstetrics

- **Abortion** (ă-BOR-shŏn) (**AB**): Termination of pregnancy before the fetus is viable. Medically, this term refers to spontaneous miscarriages, as well as elective termination of pregnancy.
- **Ectopic pregnancy** (ek-TOP-ik PREG-năn-sē): Pregnancy occurring outside the uterus, commonly in the Fallopian tube.
- **Gestation** (jës-TĀ-shŏn): The period of development during pregnancy.

33. This work is a derivative of [Lifespan Development](#) by Julie Lazzara and is licensed under [CC BY 4.0](#)

34. This work is a derivative of [Lifespan Development](#) by Julie Lazzara and is licensed under [CC BY 4.0](#)

- **Gravida** (GRĂV-ĩ-dă): A woman who is or has been pregnant, regardless of outcome.
- **Induction** (in-DŮK-shŏn): A process of bringing on or starting labor through medical interventions such as a membrane sweep and/or the intravenous administration of oxytocin to the mother.
- **Multigravida** (mŭl-tĩ-GRĂV-ĩ-dă): A woman who has been pregnant two or more times regardless of outcome.
- **Multipara** (mŭl-TĪP-ă-ră): A woman who has given multiple births to an offspring after 20 weeks, live or stillborn.
- **Neonate** (NĒ-ŏ-nāt): An infant from birth to four weeks of age.
- **Nulligravida** (nŭl-ĩ-GRĂV-ĩ-dă): A woman who has never been pregnant.
- **Oligohydramnios** (ŏl-ĩg-ŏ-hĩ-DRĂM-nē-ŏs): Minimal amniotic fluid within the placental sac that can restrict the fetus from movement and growth.
- **Oxytocin** (ŏk-sē-TŌ-sĩn): A hormone that stimulates contractions during labor and the secretion of milk.
- **Para** (PĂR-ă): A woman who has given birth to an offspring after 20 weeks, live or stillborn.
- **Placenta abruptio** (plă-SENT-ā ă-BRŮP-shē-ŏ): Premature separation of the placenta from the uterine wall.
- **Placenta previa** (plă-SENT-ā PRĒ-vē-ă): An abnormally low implantation of the placenta on the uterine wall, which can result in hemorrhage. Mothers with placenta previa may require a C-section.
- **Prenatal** (prē-NĀT-ăl): Pertaining to before birth.
- **Stillborn** (STIL-bŏrn): The birth of an infant who has died in the uterus.

8.5 Complications of Pregnancy and Delivery

Several complications may occur during pregnancy, labor, delivery, and postpartum.

COMPLICATIONS OF PREGNANCY

There are several complications that can occur during pregnancy that pose health risks to mother and child. Common complications include the following¹:

- **Gestational diabetes** (jěs-TĀ-shŏn-ăl dī-ă-BĒ-tīs): High blood sugar levels that develop in a woman during pregnancy who has not been previously diagnosed with diabetes. After pregnancy, blood sugars typically return to normal although the mother has increased risk of developing type 2 diabetes mellitus later in life.
- **Hyperemesis gravidarum** (HĪ-pěr-ěm-Ē-sīs GRAV-ĭ-dar-ŭm): Severe, persistent vomiting during pregnancy causing dehydration and weight loss. It is more severe than nausea associated with “morning sickness.”
- **Preeclampsia** (prē-ě-KLAMP-sē-ă): High blood pressure during pregnancy with additional signs like edema and protein in the urine. If not effectively treated, preeclampsia can evolve into **eclampsia** (ě-KLAMP-sē-ă), severe complication characterized by seizures and a risk of

1. This work is a derivative of [Lifespan Development](#) by Julie Lazzara and is licensed under [CC BY 4.0](#)

coma and death.

- **Deep vein thrombosis** (dēp vān throm-BOH-sīs): The formation of a blood clot in a deep vein, most commonly in the legs.
- **Postpartum hemorrhage** (pōst-PÄR-tūm HEM-ör-ij): Cumulative blood loss greater than 1,000 mL with signs and symptoms of hypovolemia within 24 hours of the birth process, regardless of the route of delivery. **Hypovolemia** (hī-pō-vō-LĒ-mē-ă) is a life-threatening condition where the plasma (liquid portion of the blood) is too low, resulting in the organs not receiving enough oxygenated blood flow. The most common cause of postpartum hemorrhage is lack of effective contraction of the uterus after childbirth.²
- **Pregnancy-related death** (PRĚG-nān-sē ri-LĀ-tīd dĕth): The Centers for Disease Control and Prevention defines a pregnancy-related death as the death of a woman during pregnancy or within one year of the end of pregnancy from a pregnancy complication, a chain of events initiated by pregnancy, or the aggravation of an unrelated condition by the physiologic effects of pregnancy. Most of these pregnancy-related deaths are preventable. It is important for all women of reproductive age to adopt healthy lifestyles (e.g., maintain a healthy diet and weight, be physically active, quit all substance use, prevent injuries) and address any health problems before getting pregnant. A healthy pregnancy begins before conception and continues with prenatal care, along with early recognition and management of complications if they arise.³

2. This work is a derivative of [StatPearls](#) by Wormer, Jamil, & Bryant and is licensed under [CC BY 4.0](#)

3. Centers for Disease Control and Prevention. (2023, April 26). *Preventing pregnancy-related deaths*. Department of Health & Human Services. <https://www.cdc.gov/reproductivehealth/maternal-mortality/preventing-pregnancy-related-deaths.html>

CONGENITAL ANOMALY

A **congenital anomaly** (kŏn-JĔN-ĭ-tăĭ ă-NOM-ă-lĕ) is an abnormality in a baby that is present at birth. Many congenital anomalies are caused by **teratogens** (tĕr-AT-ŏ-jĕnz), substances toxic to a developing fetus. For example, excessive alcohol intake by the mother can cause fetal alcohol spectrum disorder.

Maternal diseases during pregnancy can also cause a birth defect or a chronic health problem. Some diseases that are known to potentially have an adverse effect on the fetus include diabetes, cytomegalovirus, toxoplasmosis, rubella, varicella, hypothyroidism, and infections caused by *streptococcus B*. For example, if an unvaccinated mother contracts rubella during the first three months of pregnancy, damage can occur to the baby's eyes, ears, heart, or brain.⁴

Fetal Alcohol Spectrum Disorders

One of the most commonly used teratogens is alcohol. Because half of all pregnancies in the United States are unplanned, it is recommended that women of child-bearing age take great caution against drinking alcohol when not using birth control and when pregnant. Alcohol consumption, particularly during the second month of prenatal development, but at any point during pregnancy, may lead to neurocognitive and behavioral difficulties that can last a lifetime.⁵

There is no acceptable safe limit for alcohol use during pregnancy, but binge drinking (five or more drinks on a single occasion) or having seven or more drinks during a single week places a child at particularly high risk. In extreme cases, alcohol consumption can lead to fetal death, but more

4. This work is a derivative of [Lifespan Development](#) by Julie Lazzara and is licensed under [CC BY 4.0](#)

5. This work is a derivative of [Lifespan Development](#) by Julie Lazzara and is licensed under [CC BY 4.0](#)

frequently it can result in **fetal alcohol spectrum disorders** (FĚ-tăl AL-kő-hőł SPEK-trům dīs-ÖR-děrz) (**FASD**). This terminology is now used when looking at the effects of exposure and replaces the term fetal alcohol syndrome. It is preferred because it recognizes that symptoms occur on a spectrum and that all individuals do not have the same characteristics. Children with FASD share certain physical features such as flattened noses, small eye openings, small heads, intellectual developmental delays, and behavioral problems. See Figure 8.9⁶ for an image of a child with FASD.⁷

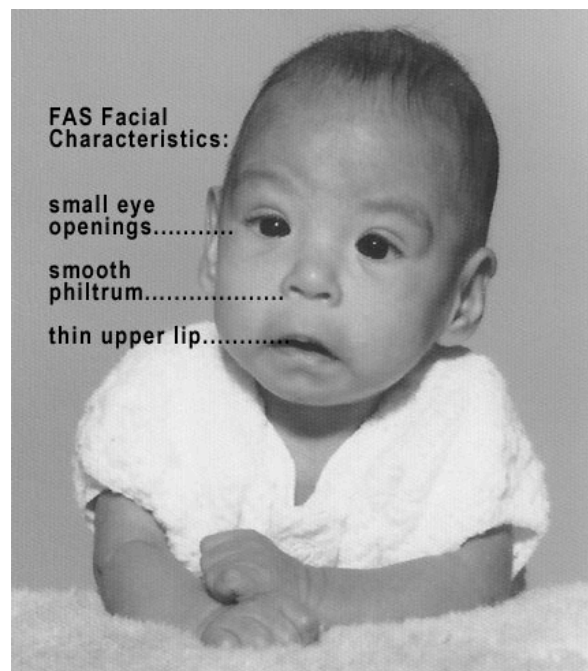


Figure 8.9 Fetal Alcohol Spectrum Disorder

6. "[Photo_of_baby_with_FAS.jpg](#)" by [Teresa Kellerman](#) is licensed under [CC BY-SA 3.0](#)

7. This work is a derivative of [Lifespan Development](#) by Julie Lazzara and is licensed under [CC BY 4.0](#)

PREMATURE LABOR AND PREMATURE INFANT

Preterm labor (PRĒ-tûrm LĀ-bŏr) is defined as labor occurring between 20 and 37 weeks of gestation. There are many potential causes of preterm labor, such as stress, infection, placental abruption, placenta previa, substance use, history of preterm birth or abortion, inadequate prenatal care, smoking, maternal age <18 or >40, poor nutrition, low body mass index, fetal congenital anomaly, fetal growth restriction, oligohydramnios, polyhydramnios, vaginal bleeding, **premature preterm rupture of membranes** (prĕ-mă-CHŪR prĕ-tûrm RŮP-chĕr ōv MEM-brānz) (**PPROM**), and other environmental factors.⁸

The main concern with premature labor is the prematurity of the infant, which can cause respiratory distress and impaired neurological development. A **premature infant** (prĕ-mă-CHŪR IN-fănt) refers to an infant who is born before completing 37 weeks of gestation. Treatment of premature labor is based on the gestational age at which the mother presents to the hospital and may include medications to stop labor from progressing, such as magnesium sulfate.⁹

Cerclage (sĕr-KLĀZH) is a procedure typically performed during the second semester of pregnancy to prevent preterm labor and miscarriage. During the procedure, the cervix is sewed shut with sutures to prevent dilation and premature delivery. It is performed in women whose cervix isn't strong enough to stay closed as the pregnancy grows. The suture is removed when the fetus is full-term, which allows vaginal delivery to proceed.¹⁰

8. This work is a derivative of [StatPearls](#) by Suman & Luther and is licensed under [CC BY 4.0](#)

9. This work is a derivative of [StatPearls](#) by Suman & Luther and is licensed under [CC BY 4.0](#)

10. The American College of Obstetricians and Gynecologists. (2021, November).

MISCARRIAGE AND STILLBIRTH

Pregnancy loss is experienced in over ten percent of pregnancies, typically due to chromosomal abnormalities before the 12th week of pregnancy.

Miscarriage (MĪS-kă-r-ĭj) refers to loss of a fetus before the 20th week of pregnancy. It typically causes cramping and bleeding, similar to heavy menses. In some cases, a surgical procedure called dilation and evacuation (D&E) is required. Normal menstrual cycles generally return within a few months.¹¹

Stillbirth (STĪL-bûrth), also known as **intrauterine fetal demise** (ĪN-tră-YŪ-tə-rĭn FĒT-ăl dĕ-MĪZ), refers to the loss of a fetus after 20 weeks' gestation. About 24,000 babies are stillborn every year in the United States. Although many times the cause of the stillbirth is unknown, there are several potential causes, such as infection, chromosomal abnormalities, placental problems.¹²

Cervical cerclage. <https://www.acog.org/womens-health/faqs/cervical-cerclage>

11. This work is a derivative of [Lifespan Development](#) by Julie Lazzara and is licensed under [CC BY 4.0](#)

12. This work is a derivative of [Lifespan Development](#) by Julie Lazzara and is licensed under [CC BY 4.0](#)

8.6 Medical Specialists, Diagnostic Testing, and Procedures Related to Pregnancy

Medical Specialists

Obstetrics (öb-STE-triks) (**OB**) is a medical specialty dealing with pregnancy, childbirth, and postpartum, also known as **puerperium** (pū-ěr-PĒ-rē-ŭm), the period from delivery until the reproductive organs return to normal (approximately six weeks).

An **obstetrician** (ob-stě-TRISH-ăn) is a physician who specializes in obstetrics (OB) and gynecology (GYN) and are commonly referred to as “OB/GYNs.”

Midwifery (mĭd-WIF-ěr-ē) is the practice of assisting in childbirth. A **midwife** (MĪD-wĭf) is an individual who practices midwifery. A **certified nurse-midwife** (SĔR-tĭ-fĭd NŬRS mĭd-wĭf) (**CNM**) is a type of advanced practice registered nurse who has completed advanced education and training. CNMs provide health care to women, including family planning, gynecological checkups, prenatal care, delivery of babies, and postpartum care.

A **pediatrician** (pĕd-ē-ă-TRISH-ăn) is a doctor who focuses on the health of infants, children, and adolescents. Pediatric care starts at birth.

Neonatologists (nē-ō-nă-TOL-ŏ-jĭsts) are physicians who specialize in the care of newborns. Newborns can present a unique set of health challenges that require special medical expertise, especially premature newborns and those with underdeveloped organs.

DIAGNOSTIC TESTING

Amniocentesis

Amniocentesis (am-nē-ō-sen-TĒ-sīs) is a procedure that removes a small amount of amniotic fluid from the uterus under ultrasound guidance. The fluid is tested for potential fetal abnormalities. See Figure 8.10¹ for an illustration of amniocentesis.

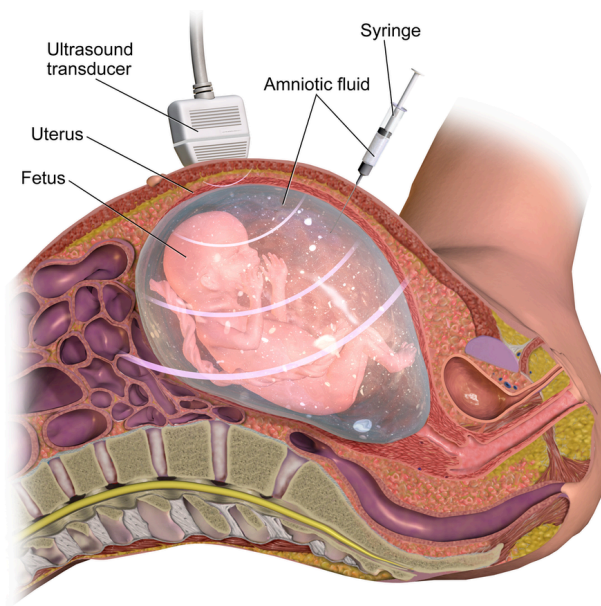


Figure 8.10 Amniocentesis

Chorionic Villus Sampling

Chorionic villus sampling is performed to diagnose chromosome problems or other genetic diseases in a fetus by checking chorionic villi, the tiny finger-like growths found in the placenta. Chorionic villi contain the same chromosomes as the fetus, so this test can show if an extra chromosome, missing

1. “Amniocentesis.png” by [BruceBlaus](#) is licensed under [CC BY-SA 4.0](#)

chromosomes, or damaged chromosomes are present that can cause serious health problems.²

Contraction Stress Test

A **contraction stress test** (kŏn-TRAK-shŏn STRĒS test) involves monitoring the baby's heart rate while inducing contractions in the mother. This diagnostic test may be performed if there are abnormal results from a nonstress test. Fetal heart monitoring is used while oxytocin is administered to the mother, causing the uterus to contract. Every contraction means the baby gets less blood and oxygen for a short while. A contraction stress test shows how the baby's heart rate reacts to the stress of contractions. If the baby's heart rate slows down rather than speeds up after a contraction, the baby may have problems during labor. If the results are abnormal, delivery may be induced.³ **Induction** (in-DUK-shŏn) is when a provider administers medicine or uses other methods to artificially start labor before it begins naturally.

Noninvasive Prenatal Testing

Noninvasive prenatal testing (nŏn-ĭn-VĀ-sĭv prĕ-NĀ-tĕl TĒS-tĭng), sometimes called noninvasive prenatal screening, is a method of determining the risk that the fetus will be born with certain genetic abnormalities. This testing analyzes small fragments of DNA that are circulating in a pregnant woman's blood. It is considered noninvasive because it requires drawing blood only from the pregnant woman and does not pose any risk to the fetus.⁴

2. Medline Plus. (2021). *Chorionic villus sampling (CVS)*. <https://medlineplus.gov/lab-tests/chorionic-villus-sampling-cvs/>

3. A.D.A.M. Medical Encyclopedia [Internet]. Atlanta (GA): A.D.A.M., Inc.; c1997-2023. Monitoring your baby before labor; [reviewed 2022, Apr 19; cited 2023, Oct 20]. <https://medlineplus.gov/ency/patientinstructions/000485.htm>

4. Medline Plus. (2021). *What is noninvasive prenatal testing and what disorders*

Nonstress Test

A **nonstress test** (NŎN-strĕs tĕst) is a safe, noninvasive test that measures the heart rate of the fetus as it moves within the uterus. In most healthy babies, the fetal heart rate increases during their movement in the uterus. If nonstress test results show the fetal heart rate is not normal, it may mean that the baby is not getting enough oxygen. If this happens, additional testing may be performed, or delivery may be induced.

Pelvic Ultrasound

A pelvic ultrasound, also called **pelvic sonography** (PEL-vik sŏ-NOG-ră-fĕ), is the process of recording sound waves pertaining to the pelvis. It is performed during pregnancy to check the growth and wellness of the fetus and to estimate a due date. A prenatal ultrasound evaluation of fetal well-being is also referred to as a **biophysical profile** (BĪ-ŏ-FĪZ-ĭ-kăl PRO-fĭl).

PROCEDURES

Fetal Heart Monitoring

Fetal heart monitoring (FĒ-tăl HĀRT MON-ĭt-or-ing) refers to tracking the heart rate of the fetus. The most common form of monitoring is external electronic fetal monitoring. Sensors are strapped to the mother's abdomen, and instruments record the baby's heartbeat. If the mother is in labor, the contractions are also monitored to see how the baby is responding to the contractions.⁵

can it screen for? <https://medlineplus.gov/genetics/understanding/testing/nipt/>

5. Familydoctor.org. (2017, October 20). *Monitoring baby's heart rate during*

Internal monitoring uses an electrode attached to a wire that is placed directly on the baby's scalp to monitor the heartbeat. The electrode is threaded through the cervix and into the uterus, where it is attached to the baby's scalp. A small tube can also be inserted to measure contractions. The two devices can provide more accurate measurements of the baby's heartbeat and the mother's contractions.⁶

In Vitro Fertilization

In vitro fertilization (in VĪ-trō FĔR-tĭ-lĭ-ZĀ-shŏn) (**IVF**) is an assisted reproductive technology. There are many different indications for IVF. For example, a woman may produce normal eggs, but the eggs cannot reach the uterus because the uterine tubes are blocked or otherwise compromised. A man may have a low sperm count, low sperm motility, sperm with an unusually high percentage of morphological abnormalities, or sperm that are incapable of penetrating the zona pellucida of an egg. There are five basic steps of IVF⁷:

- **Stimulation** (STĪM-yū-LĀ-shŏn) (also called superovulation): Medicines, called fertility drugs, are given to the woman to boost egg production.
- **Egg retrieval** (Ĕg rĭ-TREE-vəl): A minor surgery, called follicular aspiration, is done to remove the eggs from the woman's ovaries. The health care provider inserts a thin needle through the vagina into the ovary and into

labor. American Academy of Family Physicians. <https://familydoctor.org/monitoring-babys-heart-rate-labor/>

6. Familydoctor.org. (2017, October 20). *Monitoring baby's heart rate during labor*. American Academy of Family Physicians. <https://familydoctor.org/monitoring-babys-heart-rate-labor/>

7. A.D.A.M. Medical Encyclopedia [Internet]. Atlanta (GA): A.D.A.M., Inc.; c1997-2023. In vitro fertilization (IVF); [reviewed 2022, Jan 10; cited 2023, Oct 20]. <https://medlineplus.gov/ency/article/007279.htm>

the follicles containing mature eggs. The needle is connected to a suction device, which pulls the eggs and fluid out of each follicle, one at a time. If a woman does not produce any eggs, donated eggs may be used.

- **Insemination** (in-sem-ĭ-NĀ-shŏn) and **fertilization** (fĕr-tĭ-lĭ-ZĀ-shŏn): Sperm is mixed with the best quality eggs, called insemination. The sperm most often enters (fertilizes) an egg a few hours after insemination. If the chance of fertilization is low, the sperm may be directly injected into the egg, called intracytoplasmic sperm injection.
- **Embryo culture** (ĔM-brĕ-ō Kŭl-chĕr): The retrieved egg is maintained and monitored under stable conditions promoting cell division until it is ready to be transferred into the uterus. The process usually takes 3-5 days.
- **Embryo transfer** (ĔM-brĕ-ō TRĀNS-fĕr): Embryos are placed into the woman's uterus 3 to 5 days after egg retrieval and fertilization. The doctor inserts a thin tube containing the embryos into the vagina, through the cervix, and up into the uterus. If an embryo implants in the endometrium and grows, pregnancy results. More than one embryo may be placed into the uterus at the same time, which can lead to twins, triplets, or more. Unused embryos may be frozen and implanted or donated at a later date.

8.7 Obstetrics Learning Activities

Interactive Learning Activity: Study the obstetrics medical terms discussed in this chapter.



An interactive H5P element has been excluded from this version of the text. You can view it online here:

<https://wtcs.pressbooks.pub/medterm/?p=312#h5p-182>

Interactive Learning Activity: Test your knowledge on terms related to obstetrics.



An interactive H5P element has been excluded from this version of the text. You can view it online here:

<https://wtcs.pressbooks.pub/medterm/?p=312#h5p-44>

Interactive Learning Activity: Using the sample documentation provided, drag the terms on the right to their appropriate spaces within the documentation.



An interactive H5P element has been excluded from this version of the text. You can view it online here:

<https://wtcs.pressbooks.pub/medterm/?p=312#h5p-43>

8.8 Glossary

Abortion (ă-BOR-shŏn) (AB): The termination of pregnancy by the removal or expulsion of an embryo or fetus before it is viable. ([Chapter 8.4](#))

Amniocentesis (am-nē-ō-sen-TĒ-sīs): A procedure that removes and tests amniotic fluid for fetal abnormalities. ([Chapter 8.6](#))

Apgar score (AP-gar skŏr): A quick test performed on a newborn baby at 1 and 5 minutes after birth to assess the baby's heart rate, respiration, muscle tone, skin color, and reflexes. ([Chapter 8.4](#))

Biophysical profile (BĪ-ō-FĪZ-ĭ-kăl PRO-fĭl): Fetal well-being assessment combining nonstress test results and ultrasound findings. ([Chapter 8.6](#))

Braxton-Hicks (BRAX-tŏn HIKS): Irregular, often painless contractions that occur throughout pregnancy, also known as false labor. ([Chapter 8.4](#))

Breech (brĕch): A fetal position where the buttocks or feet are positioned to be delivered first rather than the head. ([Chapter 8.4](#))

Cephalic presentation (sĕ-FAL-ĭk prĕ-zen-TĀ-shŏn): The common childbirth position where the baby's head comes out first. ([Chapter 8.4](#))

Cephalic version (sĕ-FAL-ĭk VĚR-zhŏn): A procedure used to turn a fetus from a breech position or side-lying position into a head-down (cephalic) position before labor begins. ([Chapter 8.4](#))

Cerclage (sĕr-KLĀZH): A procedure in which the cervix is stitched shut to prevent dilation and premature delivery. ([Chapter 8.5](#))

Certified nurse-midwife (SĚR-tĭ-fĭd NŪRS mĭd-wĭf) (CNM): An advanced practice registered nurse who provides prenatal, delivery, postpartum and gynecological care. ([Chapter 8.6](#))

Cesarean section (si-ZAR-ĕ-ăn SEK-shŏn) (C section): A surgical procedure in which one or more incisions are made through a mother's abdomen (laparotomy) and uterus (hysterotomy) to deliver one or more babies. ([Chapter 8.4](#))

Colostrum (kŏ-LOS-trŭm): A form of milk produced by the mammary glands of mammals in late pregnancy and the few days after giving birth. ([Chapter 8.4](#))

Conception (kǒn-SEP-shǒn): The moment when a sperm cell successfully fertilizes an ovum, leading to the beginning of a pregnancy. ([Chapter 8.4](#))

Congenital anomaly (kǒn-JĚN-ĭ-tǎi ǎ-NOM-ǎ-lē): A structural, functional, or metabolic abnormality present at birth that can lead to physical or mental disabilities. ([Chapter 8.5](#))

Contraction stress test (kǒn-TRAK-shǒn STRĒS test): A test that monitors the fetal heart rate in response to induced contractions. ([Chapter 8.6](#))

Crowning (KROWN-ĭng): The appearance of the baby's head at the vaginal opening during childbirth. ([Chapter 8.4](#))

Deep vein thrombosis (dēp vān throm-BOH-sīs) (DVT): The formation of a blood clot in a deep vein, predominantly in the legs, which can be a risk in pregnancy due to increased blood clotting. ([Chapter 8.5](#))

Eclampsia (ě-KLAMP-sē-ǎ): A severe complication of preeclampsia, involving seizures or coma in the pregnant woman. ([Chapter 8.5](#))

Ectopic pregnancy (ek-TOP-ik PREG-nǎn-sē): A pregnancy in which the fertilized egg implants outside the uterus, often in the Fallopian tube. ([Chapter 8.4](#))

Egg retrieval (Ěg rĭ-TREE-vəl): A minor surgery to collect mature eggs from the ovaries. ([Chapter 8.6](#))

Embryo (EM-brē-ō): An organism in early stages of development, specifically from day 16 through week 8 of human pregnancy. ([Chapter 8.4](#))

Embryo culture (ĚM-brē-ō Kŭl-chər): Maintaining and monitoring embryos until ready for transfer in IVF. ([Chapter 8.6](#))

Embryo transfer (ĚM-brē-ō TRĀNS-fər): Placing embryos into the uterus in IVF. ([Chapter 8.6](#))

Endometrium (en-dō-MĒ-trē-ŭm): The mucous membrane lining the uterus, which thickens during the menstrual cycle in preparation for possible implantation of an embryo. ([Chapter 8.4](#))

Episiotomy (ěp-ĭ-zē-OT-ō-mē): A surgical incision of the vulva to widen the vaginal opening to prevent ripping or tearing of the perineum during delivery. ([Chapter 8.4](#))

Fertilization (fĕr-tĭ-lĭ-ZĀ-shǒn): The union of a male sperm cell and a female egg cell to form a zygote, initiating the development of a new individual. ([Chapter 8.4](#), [Chapter 8.6](#))

Fetal alcohol spectrum disorders (FĚ-tăl AL-kő-hől SPEK-trům dīs-ÖR-děrz) (FASD): The effects caused by maternal alcohol intake during pregnancy, ranging from physical, mental, and behavioral disabilities. ([Chapter 8.5](#))

Fetal heart monitoring (FĚ-tăl HÄRT MON-īt-or-ing): Tracking the fetal heart rate during pregnancy and labor. ([Chapter 8.6](#))

Fetus (FĚ-tūs): A developing human from roughly the end of the eighth week after conception to the moment of birth. ([Chapter 8.4](#))

Gestation (jěs-TĀ-shǒn): The period of development of the fetus in the mother's uterus, typically lasting from conception to birth. ([Chapter 8.4](#))

Gestational diabetes (jěs-TĀ-shǒn-ăl dī-ă-BĚ-tīs): A form of diabetes that occurs only during pregnancy and usually resolves after delivery. ([Chapter 8.5](#))

Gravida (GRĀV-ī-dă): A pregnant woman; often used in medical contexts to specify a woman's number of pregnancies. ([Chapter 8.4](#))

Human chorionic gonadotropin (hū-MĀN kor-ē-ON-ĭk gō-năd-ō-TRO-pin): A hormone produced during pregnancy by cells that will eventually form the placenta. ([Chapter 8.4](#))

Hyperemesis gravidarum (Hĭ-pěr-ēm-Ē-sīs GRAV-ī-dar-ŭm): A severe form of nausea and vomiting in pregnancy that can lead to dehydration and weight loss. ([Chapter 8.5](#))

Hypovolemia (hĭ-pō-vō-LĒ-mē-ă): A decrease in the volume of blood plasma, which can be a critical condition following postpartum hemorrhage. ([Chapter 8.5](#))

In vitro fertilization (in Vĭ-trō FĚR-tĭ-lĭ-ZĀ-shǒn) (IVF): An assisted reproductive technology in which eggs are fertilized outside the body and transferred to the uterus. ([Chapter 8.6](#))

Induction (in-DŮK-shǒn): The process of artificially initiating childbirth by stimulating uterine contractions. ([Chapter 8.4](#), [Chapter 8.6](#))

Insemination (in-sem-ī-NĀ-shǒn): Mixing eggs with sperm in IVF. ([Chapter 8.6](#))

Intrauterine fetal demise (ĭN-tră-YŪ-tə-rĭn FĚT-ăl dĕ-MĪZ): Fetal death that occurs after 20 weeks of pregnancy. ([Chapter 8.5](#))

Lactation (lăk-TĀ-shǒn): The secretion of milk by the mammary glands. ([Chapter 8.4](#))

Lanugo (lă-NOO-gō): Fine, soft hair, especially that which covers the body and limbs of a human fetus or newborn. ([Chapter 8.4](#))

Last menstrual period (last MEN-strū-ăl PĒ-rē-öd) (LMP): The first day of a woman's last menstrual cycle, used as a marker to estimate the date of conception. ([Chapter 8.4](#))

Lochia (LŌ-kē-ă): Vaginal discharge after giving birth (puerperium), containing blood, mucus, and uterine tissue. ([Chapter 8.4](#))

Meconium (mē-KŌ-nē-ŭm): The first stool of a newborn. ([Chapter 8.4](#))

Meconium aspiration (mě-KŌ-nē-ŭm AS-pĭ-RĀ-shŏn): A medical condition affecting newborns in which meconium is ingested into their lungs in utero. ([Chapter 8.4](#))

Midwife (MĪD-wĭf): An individual who practices midwifery. ([Chapter 8.6](#))

Midwifery (mĭd-WIF-ěr-ē): The practice of assisting women in childbirth. ([Chapter 8.6](#))

Miscarriage (MĪS-kār-ĭj): Loss of a fetus before the 20th week of pregnancy. ([Chapter 8.5](#))

Mitosis (mī-TŌ-sĭs): A type of cell division that results in two daughter cells each having the same number and kind of chromosomes as the parent nucleus. ([Chapter 8.4](#))

Multigravida (mŭl-tĭ-GRĀV-ĭ-dă): A woman who has been pregnant more than once. ([Chapter 8.4](#))

Multipara (mŭl-TĪP-ă-ră): A woman who has given birth to more than one child. ([Chapter 8.4](#))

Neonate (NĒ-ō-nāt): A newborn child, specifically within the first four weeks after birth. ([Chapter 8.4](#))

Neonatologists (nē-ō-nă-TOL-ŏ-jĭsts): Physicians who specialize in the medical care of newborns. ([Chapter 8.6](#))

Noninvasive prenatal testing (nŏn-ĭn-VĀ-sĭv prē-NĀ-tăl TĚS-tĭng): A blood test of the mother to determine risk of fetal genetic abnormalities. ([Chapter 8.6](#))

Nonstress test (NŌN-strēs tĕst): A test that monitors the fetal heart rate in response to fetal movement. ([Chapter 8.6](#))

Nulligravida (nŭl-ĭ-GRĀV-ĭ-dă): A woman who has never been pregnant. ([Chapter 8.4](#))

Obstetrician (ob-stě-TRISH-ăn): A physician who specializes in obstetrics (OB) and gynecology (GYN). ([Chapter 8.6](#))

Obstetrics (őb-STE-triks) (OB): A medical specialty concerning care of the mother and fetus during pregnancy, childbirth, and immediately after childbirth. ([Chapter 8.1](#), [Chapter 8.6](#))

Oligohydramnios (öl-ĭg-ō-hī-DRĂM-nē-ōs): A condition in pregnancy characterized by a deficiency in amniotic fluid, which can compromise the fetus's development. ([Chapter 8.4](#))

Oogenesis (ō-ő-JEN-ě-sīs): The process in female reproduction where ova (egg cells) are produced in the ovaries. ([Chapter 8.4](#))

Oxytocin (ők-sē-TŌ-sĭn): A hormone that causes the uterus to contract during labor and stimulates the mammary glands to release milk. ([Chapter 8.4](#))

Para (PĂR-ă): A term used in obstetrics to indicate the number of live births a woman has had. ([Chapter 8.4](#))

Parturition (păr-tŭ-RĬSH-ŭn): The act of giving birth; the process of childbirth. ([Chapter 8.4](#))

Pediatrician (pēd-ē-ă-TRISH-ăn): A doctor who focuses on the health of infants, children, and adolescents. ([Chapter 8.6](#))

Pelvic sonography (PEL-vik sō-NOG-ră-fē): An ultrasound of the pelvic region, used during pregnancy to evaluate fetal growth and well-being. ([Chapter 8.6](#))

Perineum (pěr-ĭ-NĒ-ŭm): The area between the anus and the vulva in females, and between the anus and the scrotum in males. ([Chapter 8.4](#))

Peripartum depression (pěr-ĭ-PĂR-tŭm di-PRESH-ŭn): Depression that occurs during pregnancy or within four weeks of childbirth. ([Chapter 8.4](#))

Placenta (plă-SEN-tă): An organ that develops in the uterus during pregnancy, providing oxygen and nutrients to the growing baby and removing waste products. ([Chapter 8.4](#))

Placenta abruptio (plă-SENT-ă ă-BRŮP-shē-ō): A condition in which the placenta separates from the wall of the uterus prematurely during pregnancy. ([Chapter 8.4](#))

Placenta previa (plă-SENT-ă PRĒ-vē-ă): A condition in which the placenta

covers the cervix, often leading to severe bleeding before or during delivery. ([Chapter 8.4](#))

Postpartum (pōst-PÄR-tŭm): The period after childbirth when the mother's body, including hormone levels and uterus size, returns to a pre-pregnancy state. ([Chapter 8.4](#))

Postpartum hemorrhage (pōst-PÄR-tŭm HEM-ŏr-ij): Heavy bleeding after giving birth, which can be a serious complication. ([Chapter 8.5](#))

Preeclampsia (prē-ě-KLAMP-sē-ă): A pregnancy complication characterized by high blood pressure and signs of damage to another organ system, often the kidneys. ([Chapter 8.5](#))

Pregnancy-related death (PRĚG-năn-sē ri-LĀ-tĭd děth): The death of a woman during pregnancy, childbirth, or shortly after, due to complications from the pregnancy. ([Chapter 8.5](#))

Premature infant (prē-mă-CHŪR IN-fănt): An infant born before completing 37 weeks of gestation. ([Chapter 8.5](#))

Premature preterm rupture of membranes (prē-mă-CHŪR prē-tŭrm RŮP-chĕr ŏv MEM-brānz) (PPROM): Rupture of the amniotic sac before 37 weeks of pregnancy. ([Chapter 8.5](#))

Prenatal (prē-NĀT-ăl): Pertaining to the period before birth, during pregnancy. ([Chapter 8.4](#))

Preterm labor (PRĚ-tŭrm LĀ-bŏr): Labor occurring between 20 and 37 weeks of gestation. ([Chapter 8.5](#))

Puerperium (pŭ-ěr-PĚ-rē-ŭm): The period from delivery until the reproductive organs return to normal, approximately six weeks. ([Chapter 8.6](#))

Quickening (KWĪK-ĕn-ĭng): The first feeling of movement of the fetus in utero, typically experienced by the mother around 16 to 20 weeks of pregnancy. ([Chapter 8.4](#))

Stillbirth (STĪL-bŭrth): Loss of a fetus after 20 weeks' gestation, also called intrauterine fetal demise. ([Chapter 8.5](#))

Stillborn (STIL-bŏrn): The birth of a fetus that has died in the uterus, typically after surviving at least the first 28 weeks of pregnancy. ([Chapter 8.4](#))

Stimulation (STĪM-yŭ-LĀ-shŏn): Also called superovulation, this therapy refers to administering fertility medication to boost egg production. ([Chapter 8.6](#))

Teratogens (těr-AT-ř-jěnz): Agents that cause malformations in a developing embryo, including alcohol, drugs, diseases, chemicals, and environmental exposures. ([Chapter 8.4](#), [Chapter 8.5](#))

Trimesters (TRĪ-měs-těrz): Three periods of approximately three months each, into which a typical pregnancy is divided for medical purposes. ([Chapter 8.4](#))

Umbilical cord (ŭm-BĪL-ĭ-kāl křrd): A flexible cord-like structure containing blood vessels, connecting the fetus to the placenta. ([Chapter 8.4](#))

Vernix (VĚR-nĭks): A greasy deposit covering the skin of a baby at birth. ([Chapter 8.4](#))

Zygote (ZĪ-gřt): The initial cell formed when a sperm cell fertilizes an ovum, representing the earliest developmental stage of the embryo. ([Chapter 8.4](#))

PART IX

CHAPTER 9

CARDIOVASCULAR SYSTEM TERMINOLOGY

9.1 Cardiovascular System Introduction

Learning Objectives


- Apply the rules of medical language to build, analyze, spell, pronounce, abbreviate, and define terms as they relate to the cardiovascular system
- Identify meanings of key word components of the cardiovascular system
- Categorize diagnostic, therapeutic, procedural, or anatomic terms related to the cardiovascular system
- Use terms related to the cardiovascular system
- Use terms related to the diseases and disorders of the cardiovascular system

Introduction to the Cardiovascular System

The cardiovascular system consists of the heart and a complex network of arteries and veins. The heart serves as a pump to transport blood throughout the body. The healthy functioning of the cardiovascular system is foundational to the health of all other body systems because the transportation of blood directly impacts the cellular functioning of all tissues and organs.

This chapter will review common word components related to the cardiovascular system to assist learners in analyzing, building, and defining

medical terms. Other terms, whose definitions cannot be easily built from word components, will be described in context based on the anatomy and physiology of the cardiovascular system and common diseases and disorders. Medical specialists, diagnostic tests, and procedures related to the cardiovascular system will also be discussed.

View the following YouTube video¹ on the heart:  [The Heart, Part 1 – Under Pressure: Crash Course Anatomy & Physiology #25](https://youtu.be/X9ZZ6tcxArl?si=IDbroqj9mvfnGdar)

1. CrashCourse. (2015, July 6). *The heart, Part 1 – Under pressure: Crash Course Anatomy & Physiology #25* [Video]. YouTube. All rights reserved. <https://youtu.be/X9ZZ6tcxArl?si=IDbroqj9mvfnGdar>

9.2 Word Components Related to the Cardiovascular System

This section will describe common word components related to the cardiovascular system. These word components help build definitions for many medical terms. Other common prefixes are described in [Chapter 1.3](#), and common suffixes are described in [Chapter 1.5](#).

COMMON PREFIXES RELATED TO THE CARDIOVASCULAR SYSTEM

- **a-**: Absence of, without
- **bi-**: Two
- **brady-**: Slow
- **dys-**: Bad, abnormal, painful, difficult
- **endo-**: Within, in
- **epi-**: On, upon, over
- **hyper-**: Above, excessive
- **hypo-**: Below, deficient
- **inter-**: Between
- **pan-**: All, total
- **peri-**: Surrounding, around
- **poly-**: Excessive, over, many
- **tachy-**: Fast, rapid
- **tri-**: Three

COMMON WORD ROOTS WITH A COMBINING VOWEL RELATED TO THE CARDIOVASCULAR SYSTEM

- **angi/o**: Vessel
- **aort/o**: Aorta
- **arteri/o**: Artery
- **ather/o**: Yellowish, fatty plaque
- **atri/o**: Atrium
- **card/i** or **cardi/o**: Heart
- **coron/o**: Heart, crown, or circle
- **ech/o**: Sound
- **electr/o**: Electricity
- **isch/o**: Deficiency, blockage
- **my/o** or **myos/o**: Muscle
- **plasm/o**: Plasma
- **symptomato/o**: Symptom
- **thromb/o**: Clot
- **valv/o** or **valvul/o**: Valve
- **vas/o**: Vessel
- **ven/o**: Vein
- **ventricul/o**: Ventricle

COMMON SUFFIXES RELATED TO THE CARDIOVASCULAR SYSTEM

- **-ac**: Pertaining to
- **-ade**: Process of
- **-al**: Pertaining to

- **-apheresis:** Removal
- **-ar:** Pertaining to
- **-centesis:** Surgical puncture to aspirate fluid
- **-dynia:** Pain
- **-ectomy:** Excision, surgical removal
- **-emia:** Condition of blood
- **-genic:** Producing, originating, causing
- **-gram:** Record, radiographic image
- **-graph:** Instrument used to record
- **-graphy:** Process of recording, radiographic imaging
- **-ia:** Condition of, diseased state, abnormal state
- **-ic:** Pertaining to
- **-ion:** Process
- **-itis:** Inflammation
- **-lgia:** Pain
- **-logist:** Specialist who studies and treats
- **-lysis:** Loosening, dissolution, separating
- **-megaly:** Enlarged, enlargement
- **-oma:** Tumor
- **-osis:** Abnormal condition
- **-ous:** Pertaining to
- **-pathy:** Disease
- **-penia:** Abnormal reduction in number
- **-pexy:** Surgical fixation, suspension
- **-plasty:** Surgical repair
- **-poiesis:** Formation
- **-sclerosis:** Hardening
- **-scope:** Instrument used to view
- **-scopy:** Process of viewing
- **-stasis:** Stop, stopping, controlling
- **-stenosis:** Narrowing, constriction
- **-tomy:** Cut into, incision

9.3 Examples of Cardiovascular Terms Easily Defined By Their Word Components

Here are examples of common medical terms related to the cardiovascular system that can be easily defined by breaking the terms into their word components.

Cardiologist

1. Break down the medical term into word components:
Cardi/o/logist
2. Label the word components: **Cardi** = WR; **o** = CV; **logist** = S
3. Define the word components: **Cardi** = heart; **logist** = specialist who studies and treats
4. Create a final definition of the medical term: **A specialist who studies and treats diseases of the heart**

Bradycardia

1. Break down the medical term into word components:
Brady/cardi/a

2. Label the word components: **Brady** = P; **card** = WR; **ia** = S
3. Define the word components: **Brady** = slow; **card** = heart; **ia**=condition of
4. Create a final definition of the medical term: **Condition of slow heart (rate)**

Electrocardiogram

1. Break down the medical term into word components:
Electr/o/cardi/o/gram
2. Label the word components: **Electr** = WR; **o** = CV; **cardi** = WR; **o** = CV; **gram** = S
3. Define the word components: **Electr** = electricity; **cardi** = heart; **gram** = record
4. Create a final definition of the medical term: **A record of electrical (activity) of the heart**

Interactive Learning Activity: Practice defining and pronouncing cardiovascular system medical terms by breaking them down into word parts.



An interactive H5P element has been excluded from this version of the text. You can view it online here:

<https://wtcs.pressbooks.pub/medterm/?p=4355#h5p-144>



Interactive Learning Activity: Practice defining and pronouncing cardiovascular system medical terms by breaking them down into word parts.



An interactive H5P element has been excluded from this version of the text. You can view it online here:

<https://wtcs.pressbooks.pub/medterm/?p=4355#h5p-157>

- ▶ You can also print these flashcard activities as a [Chapter 9 Student Companion Worksheet](#) and check your answers with this [Answer Key](#).

9.4 Anatomy of the Cardiovascular System

THE HEART

The heart is located within the thoracic cavity, medially between the lungs, and in the space known as the mediastinum. The great veins (the superior and inferior venae cavae) and the great arteries (the aorta and pulmonary artery) are attached to the superior surface of the heart called the base. See Figure 9.1¹ for an illustration of the heart in the thoracic cavity.² The inferior tip of the heart, the **apex** (Ā-peks), lies just to the left of the sternum between the junction of the fourth and fifth ribs. Health care professionals must know the position of the heart when placing a **stethoscope** (STETH-ō-skōp) to listen to heart and lung sounds, referred to as **auscultation** (os-kŭl-TĀ-shŏn).³

1. [“2001_Heart_Position_in_ThoraxN.jpg”](#) by OpenStax College is licensed under [CC BY 3.0](#)
2. [“Position of the Heart in the Thorax”](#) by [OpenStax College](#) is licensed under [CC BY 4.0](#). Access for free at <https://openstax.org/books/anatomy-and-physiology/pages/19-1-heart-anatomy>
3. This work is a derivative of [Anatomy and Physiology](#) by [OpenStax](#) licensed under [CC BY 4.0](#). Access for free at <https://openstax.org/books/anatomy-and-physiology/pages/1-introduction>

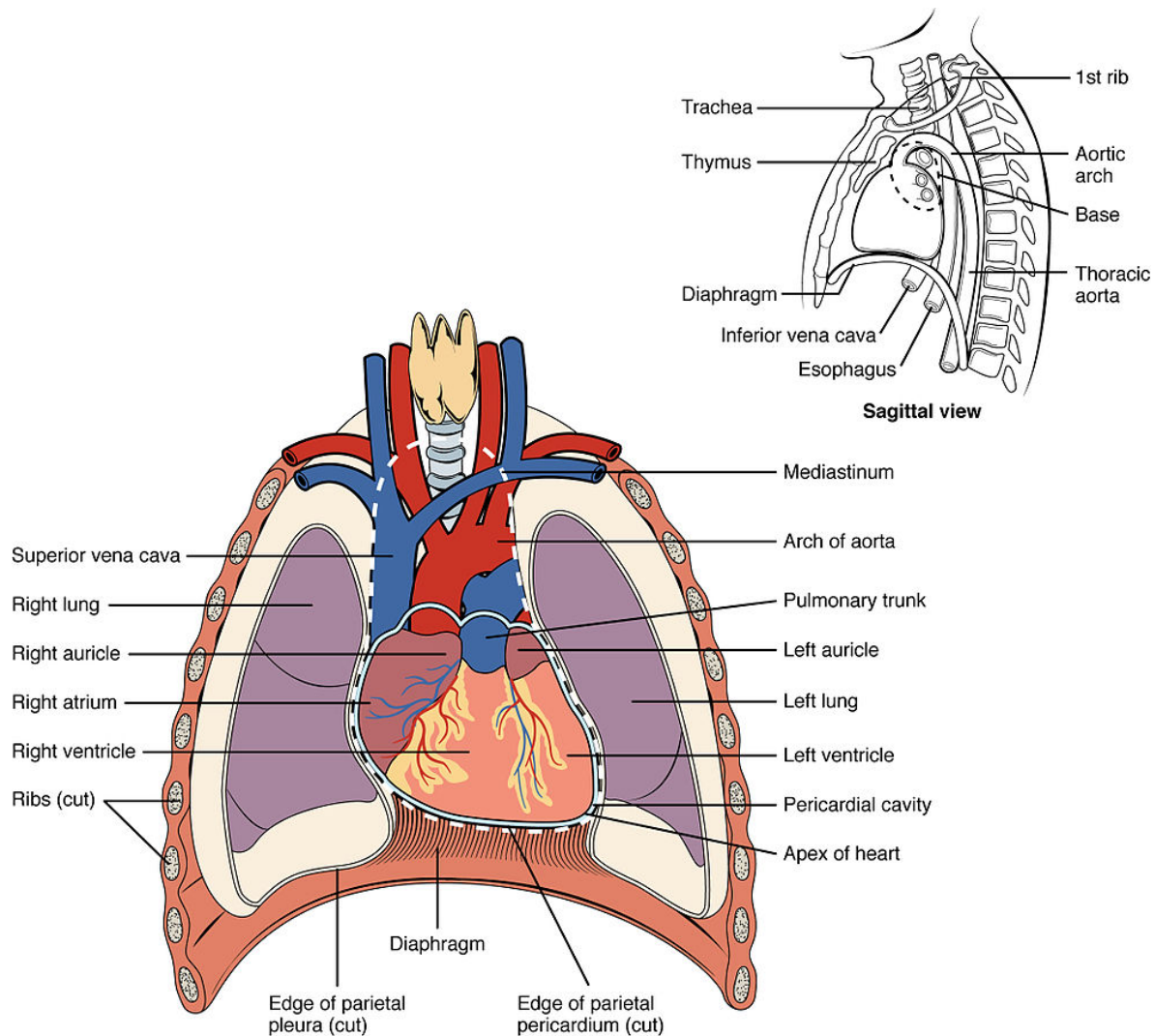


Figure 9.1 Position of the Heart in the Thoracic Cavity

See Figure 9.2⁴ for an illustration of the heart. The heart consists of four chambers: two atria and two ventricles. The right atrium receives deoxygenated blood from the body via the inferior and superior vena cava. The right ventricle pumps the deoxygenated blood to the lungs. The left

4. ["Heart_diagram-en.svg.png"](#) by [ZooFari](#) is licensed under [CC BY-SA 3.0](#)

atrium receives oxygenated blood from the lungs and propels it into the left ventricle. The left ventricle pumps blood to the rest of the body.⁵

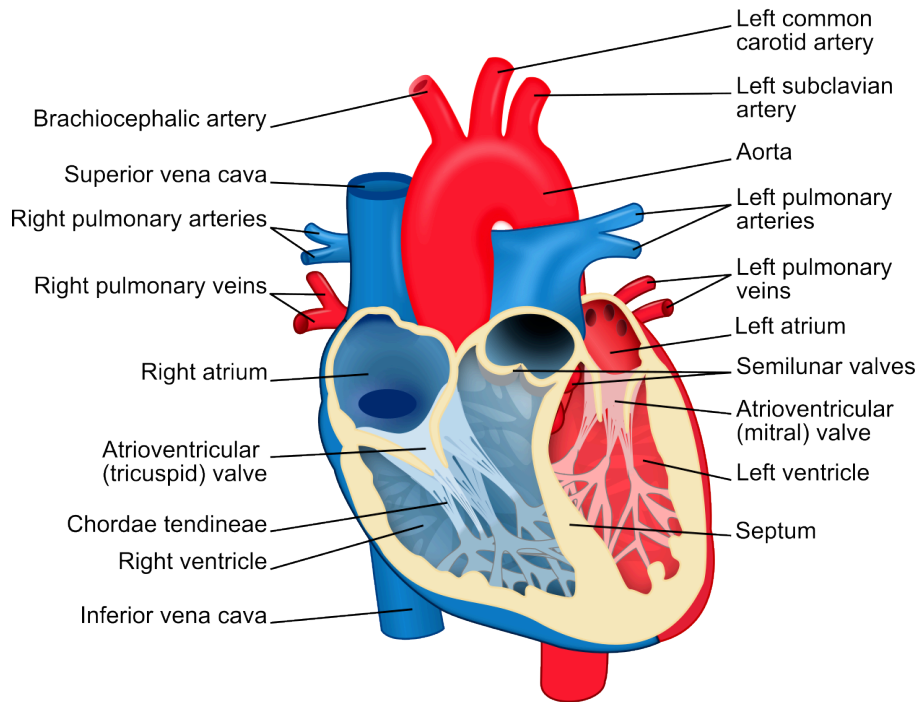


Figure 9.2 Anatomy of the Heart

BLOOD VESSELS

After blood is pumped out of the left ventricle through the aorta, it is carried throughout the body via systemic arteries. An **artery** (AR-těr-ē) is a blood vessel that carries blood away from the heart. Arteries branch into ever-smaller vessels called **arterioles** (ar-TĒR-ē-ōlz) and eventually into tiny vessels

5. This work is a derivative of [Anatomy and Physiology](https://openstax.org/books/anatomy-and-physiology/pages/1-introduction) by OpenStax licensed under CC BY 4.0. Access for free at <https://openstax.org/books/anatomy-and-physiology/pages/1-introduction>

called capillaries. See Figure 9.3⁶ for an illustration of the systemic arteries that carry oxygenated blood throughout the body to organs and tissues, as indicated by the red color.

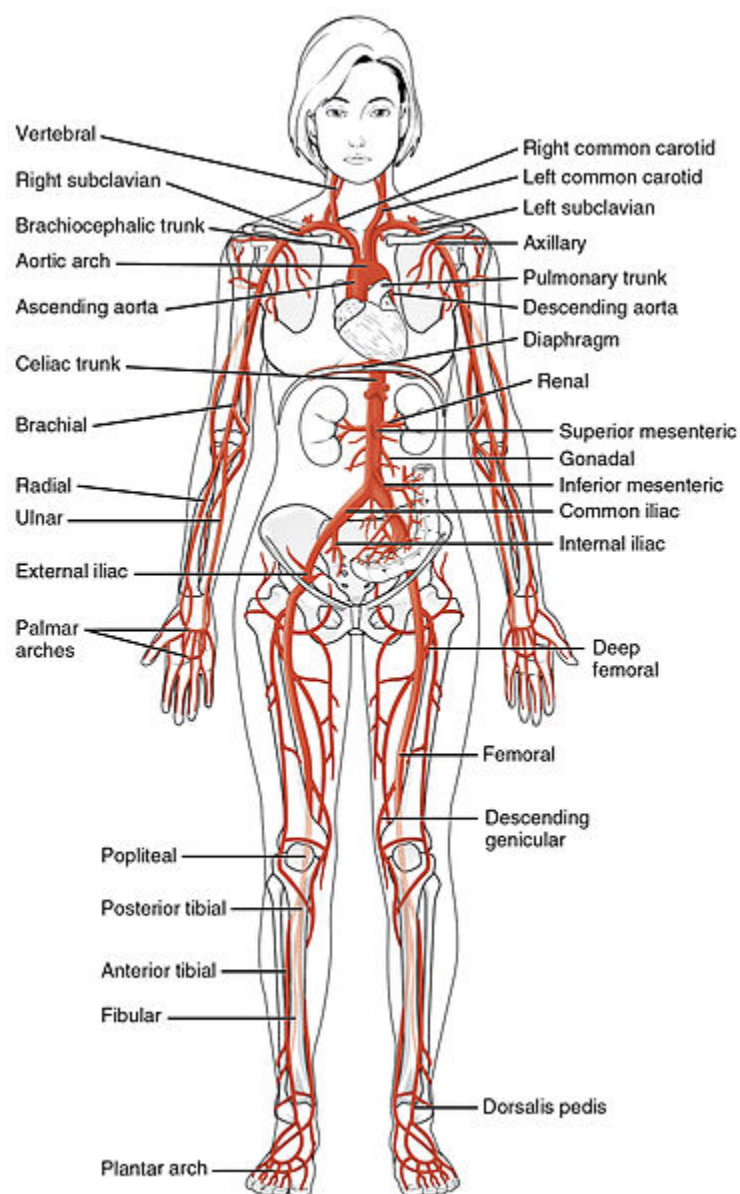


Figure 9.3 Arteries

6. “2120_Major_Systemic_Artery.jpg” by OpenStax College is licensed under [CC BY 3.0](#)

Oxygen and nutrients are exchanged with cells at the **capillary** (KAP-ĭ-lār-ē) level. A capillary is a microscopic channel that supplies blood to the tissue cells. Capillaries connect arterioles and **venules** (VEN-yoolz), small **veins** (VĀNZ). See Figure 9.4⁷ for an illustration of capillaries supplying blood to tissue cells.⁸

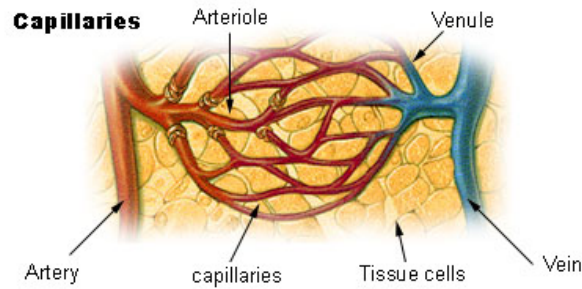


Figure 9.4 Capillaries

Veins return blood to the heart. Two large veins, the **inferior vena cava** and **superior vena cava** (VĒ-nă KĀ-vă), connect to the heart. See Figure 9.5⁹ for an illustration of the systemic veins that carry deoxygenated blood back to the heart, indicated in blue. Medications may be administered by health care professionals into veins, referred to **intravenous** (ĭn-tră-VĒ-nŭs) **(IV)** medications.¹⁰

7. “[Illu_capillary_en.jpg](#)” by unknown author is licensed in the [Public Domain](#).
8. This work is a derivative of [Anatomy and Physiology](#) by [OpenStax](#) licensed under [CC BY 4.0](#). Access for free at <https://openstax.org/books/anatomy-and-physiology/pages/1-introduction>
9. “[2131_Major_Systematic_Veins.jpg](#)” by OpenStax College is licensed under [CC BY 3.0](#)
10. This work is a derivative of [Anatomy and Physiology](#) by [OpenStax](#) licensed

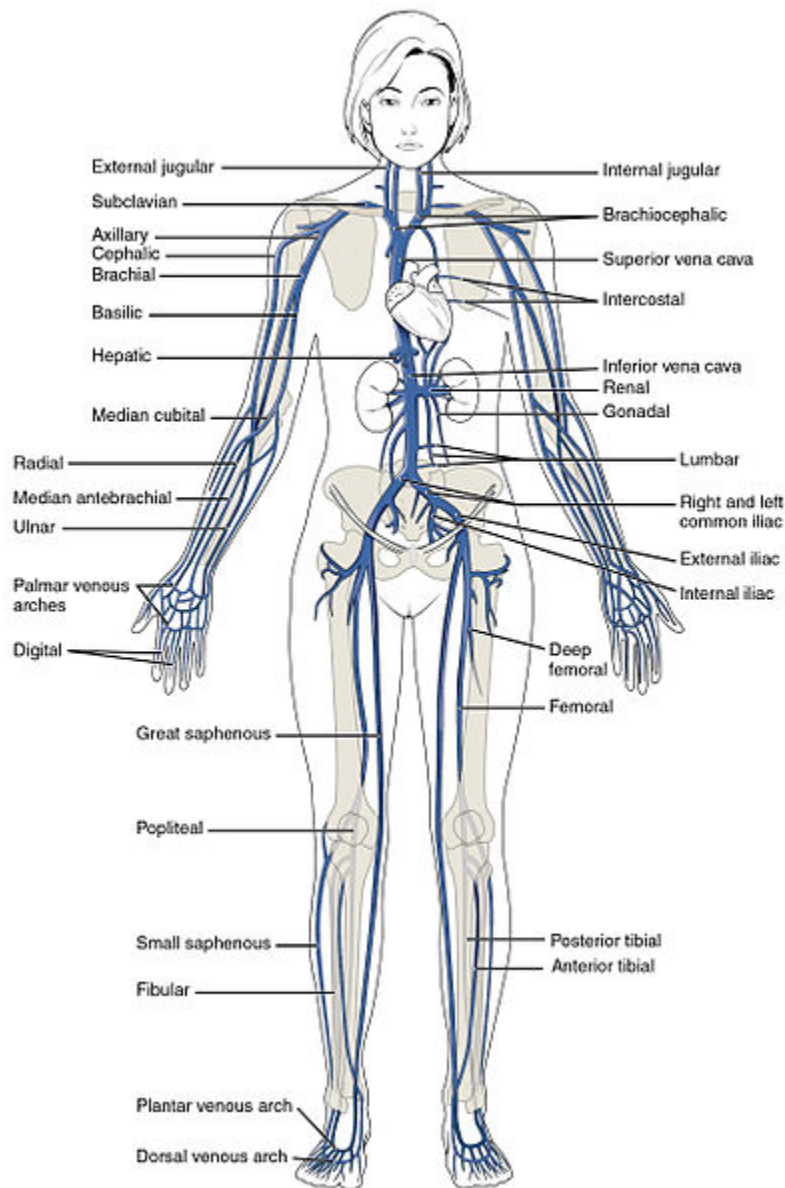


Figure 9.5 Systemic Veins

under [CC BY 4.0](https://openstax.org/books/anatomy-and-physiology/pages/1-introduction). Access for free at <https://openstax.org/books/anatomy-and-physiology/pages/1-introduction>

View the following YouTube video¹¹ on blood vessels:

▶ [Blood Vessels, Part 1 – Form and Function: Crash Course Anatomy & Physiology #27](https://youtu.be/v43ej5lCeBo)

Coronary Arteries and Veins

Coronary arteries are arteries that branch off the aorta and carry oxygenated blood to the heart muscle itself. Coronary veins bring deoxygenated blood back to the right atrium. Blood circulates through the coronary arteries and veins with each heartbeat. See Figure 9.6¹² for an illustration of the coronary arteries and veins.

11. CrashCourse. (2015, July 20). *Blood Vessels, Part 1 – Form and function: Crash Course Anatomy & Physiology #27*. [Video]. YouTube. All rights reserved. <https://youtu.be/v43ej5lCeBo>

12. “[Surface Anatomy of the Heart](#)” by [OpenStax College](#) is licensed under [CC BY 4.0](#)

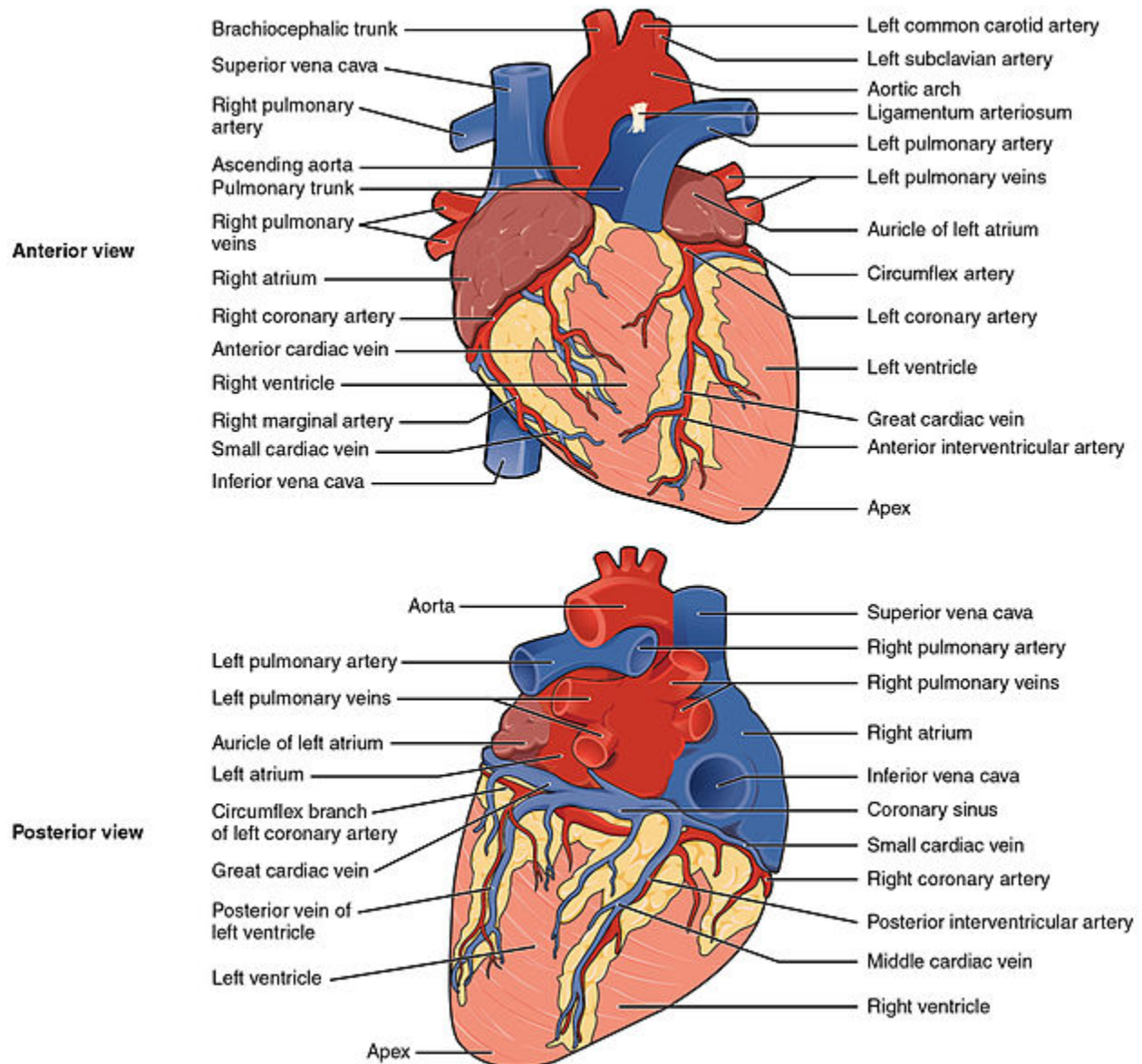


Figure 9.6 Coronary Arteries in the Heart

When a person has a **myocardial infarction** (mī-ō-kar'dē-ăl in-FARK-shŏn) (**MI**), a blockage in a coronary artery causes a lack of oxygenated blood flow to the heart muscle. If a significant area of the heart's muscle tissue dies from lack of oxygenation, the heart is no longer able to pump.

9.5 Physiology of the Cardiovascular System

PULMONARY AND SYSTEMIC CIRCULATION

There are two distinct but linked circuits in the human circulation called pulmonary and systemic circuits.

The pulmonary circuit transports oxygenated blood from the right ventricle to the lungs, where carbon dioxide is delivered for exhalation, oxygen is picked up, and this newly oxygenated blood returns to the left atrium of the heart.¹

The systemic circuit transports oxygenated blood from the left ventricle of the heart, through the aorta, and into the systemic arteries throughout the body where it diffuses into the tissues at the capillaries. Deoxygenated blood travels back to the heart by entering small veins that merge and eventually drain into the superior and inferior vena cava and into the right atrium of the heart. See Figure 9.7² for an illustration of blood flow through the pulmonary and systemic circuits.³

1. This work is a derivative of [Anatomy and Physiology](#) by [OpenStax](#) licensed under [CC BY 4.0](#). Access for free at <https://openstax.org/books/anatomy-and-physiology/pages/1-introduction>
2. "[2003_Dual_System_of_Human_Circulation.jpg](#)" by OpenStax College is licensed under [CC BY 3.0](#)
3. This work is a derivative of [Anatomy and Physiology](#) by [OpenStax](#) licensed

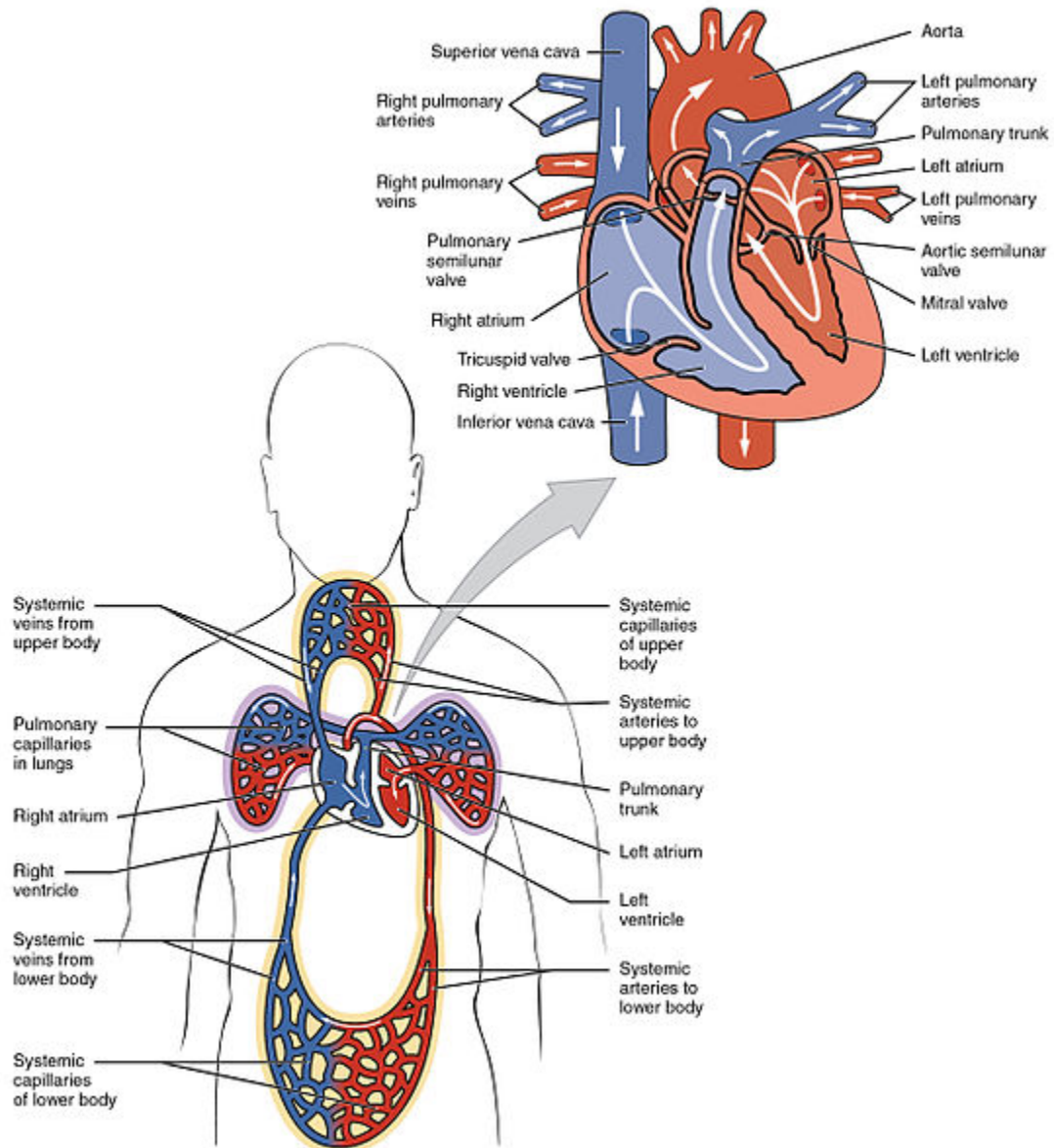


Figure 9.7 Blood Flow Through the Heart and the Pulmonary and Systemic Circuits

under CC BY 4.0. Access for free at <https://openstax.org/books/anatomy-and-physiology/pages/1-introduction>

Transportation

The systemic and pulmonary circuits transport blood and its components for physiological processes that occur throughout the body⁴:

- The right ventricle pumps deoxygenated blood through the pulmonary arteries away from the heart to the lungs. (Note this is the only place in the body where arteries carry deoxygenated blood.) Oxygen from air inhaled into the lungs diffuses into the pulmonary capillaries through the thin walls of the alveoli. At the same time, carbon dioxide diffuses out of the pulmonary capillaries into the alveoli and then exhaled out of the body. The pulmonary veins return oxygenated blood to the left atria of the heart, which moves into the left ventricle where it is pumped out to the rest of the body via the aorta to the systemic arteries.
- Nutrients from the foods eaten are absorbed in the small intestine, where they diffuse into the systemic circulation and are transported to the liver through the hepatic portal vein and then throughout the rest of the body.
- Systemic arteries carry oxygenated blood to the liver where it mixes with the nutrient-rich blood coming in from the hepatic portal vein. Wastes and toxins are filtered out of the blood, bile is produced to help remove wastes and break down fats, medications are metabolized, and nutrients are broken down.
- Systemic arteries carry blood to the kidneys, where wastes are filtered out and urine is created.
- Endocrine glands scattered throughout the body release hormones into the bloodstream where they are transported to distant target cells.

Heart Rate

Heart rate (HART RĀT) (**HR**) is the number of heart beats per minute (bpm).

4. This work is a derivative of [Anatomy and Physiology](https://openstax.org/books/anatomy-and-physiology) by [OpenStax](https://openstax.org/books/anatomy-and-physiology) licensed under [CC BY 4.0](https://creativecommons.org/licenses/by/4.0/). Access for free at <https://openstax.org/books/anatomy-and-physiology/pages/1-introduction>

HR can vary considerably among people based on their age, as well as their fitness level. For an adult, normal resting HR is 60–100 bpm. Although similar to the pulse, the heart rate is auscultated directly using a stethoscope and is a more accurate measurement than the pulse.⁵

Abnormal heart rates are referred to as bradycardia and tachycardia.

Bradycardia (brād-i-KARD-ē-ă) refers to a slow heart rate, less than 60 bpm in an adult. **Tachycardia** (tak-ē-KARD-ē-ă) refers to a fast heart rate, greater than 100 bpm in an adult. Read more about bradycardia and tachycardia in the “[Diseases and Disorders of the Cardiovascular System](#)” section.

Pulse

Each time the heart pumps, ejecting blood forcefully into the circulation, the arteries expand and recoil to accommodate the surge of blood moving through them. This expansion and recoiling of the arterial wall are called the **pulse** (PULS) and allow for the measurement of heart rate. The pulse can be palpated manually by placing the tips of the fingers across an artery that runs close to the body surface, such as the radial artery (on the thumb side of the wrist) or the common carotid artery (in the neck).⁶ These sites and other pulse sites are shown in Figure 9.8⁷ below.

5. This work is a derivative of [Anatomy and Physiology](#) by [OpenStax](#) licensed under [CC BY 4.0](#). Access for free at <https://openstax.org/books/anatomy-and-physiology/pages/1-introduction>
6. This work is a derivative of [Anatomy and Physiology](#) by [OpenStax](#) licensed under [CC BY 4.0](#). Access for free at <https://openstax.org/books/anatomy-and-physiology/pages/1-introduction>
7. “[2110_Pulse_Sites.jpg](#)” by OpenStax College is licensed under [CC BY 3.0](#)

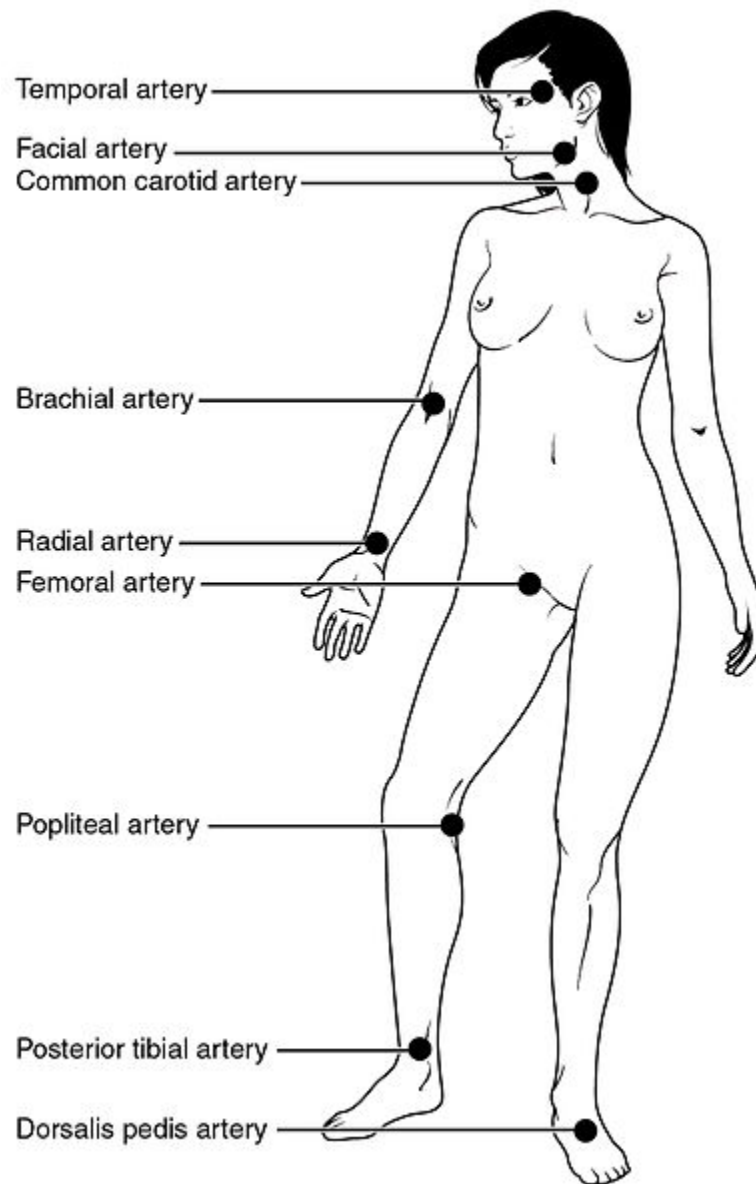


Figure 9.8 Pulse Sites

Both the rate and the strength of the pulse are important clinically. A high pulse rate can be temporarily caused by physical activity, but an extended fast or irregular pulse may indicate a heart condition. The pulse strength indicates the strength of ventricular contraction, cardiac output, and perfusion. **Cardiac output** (KAR-dē-ăk OUT-put) is the amount of blood pumped by the heart per

minute. **Perfusion** (pěr-FŪ-zhǒn) is the passage of blood through the blood vessels.⁸

If the pulse is strong, then cardiac output is high and perfusion to that site is good. If the pulse is weak, cardiac output is low or perfusion is impaired, and medical intervention may be warranted.

Cardiac Cycle

The period of time that begins with contraction of the atria, continues through ventricular contraction, and ends with ventricular relaxation is known as the cardiac cycle. The phase of the cardiac cycle when ventricles contract and eject blood is called **systole** (SIS-tǒ-lē). The phase of the cardiac cycle where the heart muscles relax, allowing the chambers to fill with blood, is called **diastole** (dī-AS-tǒ-lē).⁹

Blood Pressure

Blood pressure (BLŮD PRESH-ŭr) (**BP**) is the force of the blood against the vessel walls. In clinical practice, blood pressure is typically measured using a **sphygmomanometer** (sfīg-mō-mǎn-ŎM-ět-ěr), commonly called a blood pressure cuff. The cuff is placed over the brachial artery of the patient's upper arm and inflated with air to temporarily **occlude** (ǒ-KLOOD) (block) blood flow and measure blood pressure. Blood pressure is recorded as a ratio of two numbers expressed as systolic pressure over diastolic pressure, measured in millimeters of mercury (mm Hg). For example, 120/80 mm Hg is a normal adult blood pressure. The systolic pressure is the higher value and reflects the

8. This work is a derivative of [Anatomy and Physiology](https://openstax.org/books/anatomy-and-physiology/pages/1-introduction) by [OpenStax](https://openstax.org/books/anatomy-and-physiology/pages/1-introduction) licensed under [CC BY 4.0](https://creativecommons.org/licenses/by/4.0/). Access for free at <https://openstax.org/books/anatomy-and-physiology/pages/1-introduction>
9. This work is a derivative of [Anatomy and Physiology](https://openstax.org/books/anatomy-and-physiology/pages/1-introduction) by [OpenStax](https://openstax.org/books/anatomy-and-physiology/pages/1-introduction) licensed under [CC BY 4.0](https://creativecommons.org/licenses/by/4.0/). Access for free at <https://openstax.org/books/anatomy-and-physiology/pages/1-introduction>

arterial pressure resulting from the ejection of blood during ventricular contraction called systole. The diastolic pressure is the lower value and represents the arterial pressure of blood during ventricular relaxation called diastole.¹⁰

Low blood pressure, called **hypotension** (hī-pō-TEN-shŏn), has several causes, such as dehydration, vomiting, diarrhea, or medications used to treat hypertension. Treatment for hypotension typically includes fluid replacement. High blood pressure is called **hypertension** (hī-pěr-TEN-shŏn) (**HTN**). Hypertension has a variety of causes, with risk factors such as obesity, lack of exercise, smoking, high salt diet, diabetes, and kidney disease.

10. This work is a derivative of [Anatomy and Physiology](https://openstax.org/books/anatomy-and-physiology) by [OpenStax](https://openstax.org) licensed under [CC BY 4.0](https://creativecommons.org/licenses/by/4.0/). Access for free at <https://openstax.org/books/anatomy-and-physiology/pages/1-introduction>

9.6 Diseases and Disorders of the Cardiovascular System

ANEURYSM

An **aneurysm** (AN-yŭ-rizm) is a dilation or bulging of a blood vessel caused by weakened vessel walls. Aneurysms can occur in vessels throughout the body but are more commonly found in arteries due to their increased pressure. Aneurysms can be caused by a variety of factors, including smoking, atherosclerosis (fatty plaque buildup in a vessel), and hypertension.¹ See Figure 9.9² for an illustration of thoracic and abdominal aneurysms.

1. Centers for Disease Control and Prevention. (2021, September 27). *Aortic aneurysm*. Department of Health & Human Services. https://www.cdc.gov/heartdisease/aortic_aneurysm.htm

2. “[Aortic_aneurysm.jpg](#)” by [en:National Institutes of Health](#) is licensed in the [Public Domain](#).

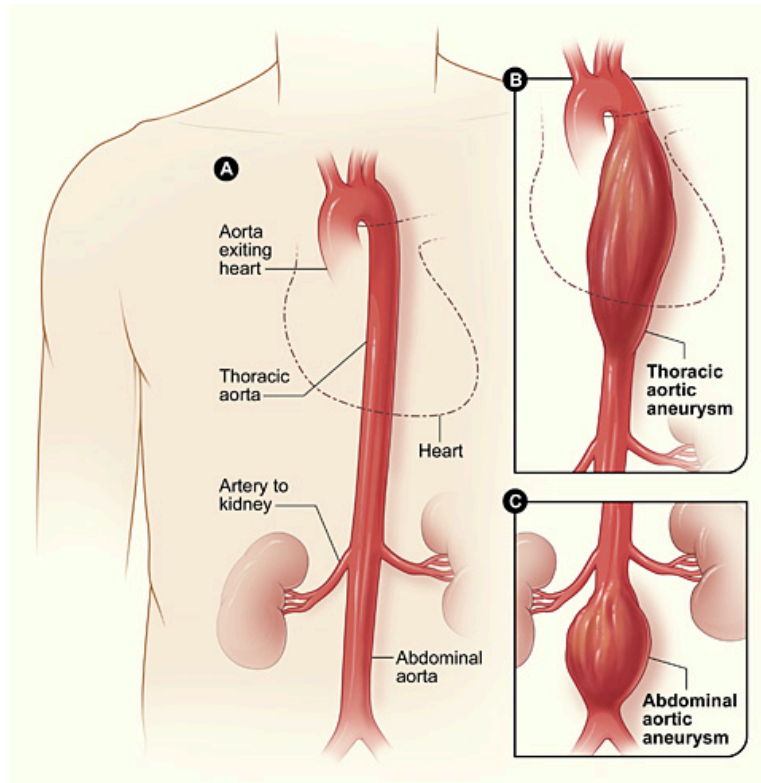


Figure 9.9 Thoracic and Abdominal Aneurysms

Aneurysms are often asymptomatic and detected incidentally during diagnostic tests that are being done for other reasons. The force of blood pumping through the vessel with an aneurysm can split the layers of the artery wall, allowing blood to leak in between them, called a dissection. An aneurysm can burst completely, called a rupture, and cause severe, life-threatening bleeding. Aneurysms are managed with antihypertensive medications or may require surgical repair.³

3. Centers for Disease Control and Prevention. (2021, September 27). *Aortic aneurysm*. Department of Health & Human Services. https://www.cdc.gov/heartdisease/aortic_aneurysm.htm

ARRHYTHMIA

A heart rhythm that follows the regular conduction system of the heart is called **normal sinus rhythm** (SĪ-nūs RITH-ŭm). For example, bradycardia and tachycardia that occurs during normal sinus rhythm have abnormally slow or fast rates but have a regular rhythm.

- **Bradycardia** (brad-ē-KAR-dē-ă) refers to a slow resting heart rate of less than 60 beats per minute. A normal resting heart rate for an adult is 60 to 100 beats per minute (bpm). However, heart rates can vary widely among individuals based on several factors like age, fitness level, overall health, and medication side effects. Physically fit athletes may have a heart rate of 50 to 60 bpm at rest with no symptoms. However, individuals with bradycardia whose heart is not pumping enough blood to sufficiently supply the brain and body tissues with oxygen may have symptoms, such as feeling tired, dizzy, short of breath, or confused. Individuals with symptomatic bradycardia may experience **syncope** (SING-kō-pē), a medical term for a brief lapse in consciousness, commonly referred to as fainting. Bradycardia is a common side effect of many cardiac medications and can also be caused by several cardiac diseases and disorders. Treatment of symptomatic bradycardia includes medications to increase heart rate or surgical implantation of a pacemaker in the heart to maintain a normal heart rate.
- **Tachycardia** (tak-ē-KAR-dē-ă) is a rapid heart rate greater than 100 bpm. Tachycardia can be caused by stress, side effects of medications, and several medical conditions. When the heart beats too rapidly, its chambers do not have time to sufficiently fill with blood, resulting in a decreased amount of oxygenated blood being pumped to body tissues and organs. For this reason, symptoms of tachycardia are similar to symptoms of bradycardia. The individual may also have **palpitations** (pal-pĭ-TĀ-shōnz), a sensation that the heart is racing, pounding, fluttering, or skipping a beat. Treatment is based on the underlying cause and may include medications or surgery.

Arrhythmia (ā-RITH-mē-ă) does not mean an absence of a heartbeat, but rather means the absence of a normal heart rhythm due to disrupted electrical activity of the conduction system. Examples of common arrhythmias are atrial fibrillation, heart block, ventricular tachycardia, and ventricular fibrillation.

- **Atrial fibrillation** (Ā-trē-ăl fīb-rī-LĀ-shŏn) (**A Fib**) is characterized by atrial quivering instead of contracting. A Fib can cause a decrease in the volume of blood propelled with each heartbeat because the ventricles do not completely fill with blood before contracting. A Fib also increases the risk of a cerebrovascular accident (also known as a stroke).
- **Heart block** (hărt blŏk) refers to a disruption in the normal conduction pathway of electrical signals through the atria and ventricles. Heart block can vary in severity from first-degree heart block, which is the least severe and often has no symptoms, to third-degree heart block that can be life-threatening. Symptoms of heart block may include bradycardia, missed heart beats, fatigue, dizziness, chest pain, and shortness of breath.
- **Ventricular tachycardia** (ven-TRĪK-yū-lăr tak-ĭ-KAR-dē-ă) (**V Tach**) refers to a very rapid heartbeat that originates in the ventricles. **Ventricular fibrillation** (ven-TRĪK-yū-lăr fīb-rī-LĀ-shŏn) (**V Fib**) is a disorganized heart rhythm that causes the ventricles to quiver instead of contract. Ventricular tachycardia and ventricular fibrillation are life-threatening arrhythmias that require rapid emergency response and the use of a defibrillator to resolve the abnormal rhythm.

A **defibrillator** (dē-FIB-rī-lā-tŏr) is a device used by trained medical personnel who apply an electrical charge to the heart in an attempt to restart the SA node and establish a normal sinus rhythm. **Automated external defibrillators** (aw-tŏ-măt'-ĕd ĕks-tĕr'năl dē-fīb'-rī-lā-tŏrs) (**AEDs**) are life-saving devices available in public areas to help individuals who are experiencing a **cardiac arrest** (KAR-dē-ăk ār-REST) survive. Cardiac arrest is caused by arrhythmias that cause the heart to suddenly stop pumping blood. The average response time after calling 911 is 8 to 12 minutes, and for each minute defibrillation is delayed, the odds of survival are reduced by approximately 10%, so having access to an AED and knowing how to perform cardiopulmonary

resuscitation (CPR) are critical. CPR refers to repeated compressions of the chest in an attempt to restore blood circulation following a cardiac arrest. While CPR is being performed, special pads are applied to the individual's chest. The AED automatically analyzes the heart's rhythm and, if indicated, delivers an electrical shock to help the heart reestablish an effective rhythm until paramedics arrive. See Figure 9.10⁴ for an image of an AED.



Figure 9.10 Automatic External Defibrillator (AED)

Individuals who have experienced a cardiac arrest due to life-threatening arrhythmias may have an **implantable cardioverter defibrillator** (ĩm-plănt'-ă-bŭl kär'dē-ō-vŭr'-tŏr dē-fīb'-rĩ-lā-tŏr) (**ICD**) surgically placed in their chest. An ICD continuously analyzes the heart rhythm and provides an automatic electric shock to convert a dangerous heart rhythm to a normal heart rhythm.

4. “[Saver_One_AED.jpg](#)” by unknown author via [Anatoliy Smaga](#) is licensed under [CC BY 4.0](#)

ATHEROSCLEROSIS

Atherosclerosis (ă-thĕr-ō-sklĕ-RO-sĭs) refers to hardening and narrowing of arteries due to the buildup of cholesterol and other fats called plaque within the lining of the arteries. Plaque creates inflammation and decreases the amount of blood flow through an artery, also referred to as decreased perfusion. Plaque can also grow so large that it causes a blockage of blood flow in the artery. When this accumulation of plaque occurs in the coronary arteries of the heart, it is called **coronary artery disease** (KOR-ō-nā-rē AR-tĕr-ē dĭ-ZĒZ) (**CAD**) or atherosclerotic heart disease. Read more information about coronary artery disease in a later subsection of this section. See Figure 9.11⁵ for an illustration of the narrowing of a coronary artery by an atherosclerotic plaque.

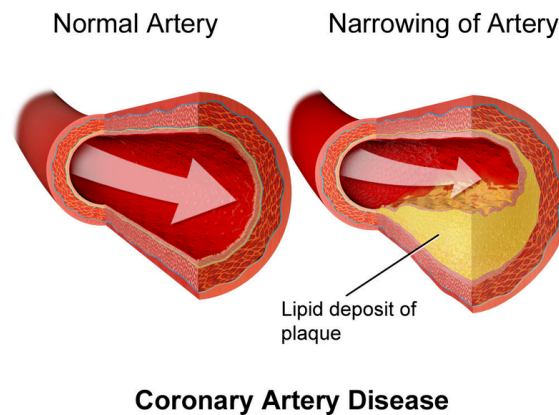


Figure 9.11 Atherosclerotic Plaque

Cerebrovascular disease (sĕr'-brō-VAS-kyū-lăř dĭ-ZĒZ) (**CVD**) occurs when

5. "[Blausen_0259_CoronaryArteryDisease_02.png](#)" by Blausen.com staff (2014). "[Medical gallery of Blausen Medical 2014.](#)" WikiJournal of Medicine is licensed under [CC BY 3.0](#)

arteries in the brain or neck become thick, hard, or full of plaque and blood flow is restricted, which can cause a cerebrovascular accident (commonly known as a stroke). **Peripheral artery disease** (pěr-IF-ěr-ăl AR-těr-ē dĩ-ZĚZ) (**PAD**) occurs when blood vessels are obstructed in peripheral regions of the body, commonly causing pain during activity and possibly causing ulcers in the legs and feet.

A clinician may hear a **bruit** (brwē) when auscultating over an artery if atherosclerosis is present. A bruit sounds like an abnormal blowing, swishing sound. For example, a carotid bruit indicates the individual is at risk for a stroke.

CARDIOMYOPATHY

Cardiomyopathy (kar-dē-ō-my-OP-ă-thē) refers to disease of the heart muscle. When cardiomyopathy occurs, the normal muscle in the heart can thicken, enlarge, stiffen, or thin out. As a result, the heart muscle's ability to pump blood is reduced, which can lead to irregular heartbeats or the backup of blood into the lungs or rest of the body. Cardiomyopathy can be acquired (i.e., developed because of another disorder), inherited, or occur due to an unknown cause. Categories of cardiomyopathy include dilated, hypertrophic, and restrictive.⁶ See Figure 9.12⁷ for an illustration of common types of cardiomyopathy.

6. Centers for Disease Control and Prevention. (2023, February 21). *Cardiomyopathy*. Department of Health & Human Services. <https://www.cdc.gov/heartdisease/cardiomyopathy.htm>

7. “[Major categories of cardiomyopathy.png](#)” by [Npatchett](#) is licensed under [CC BY-SA 4.0](#)

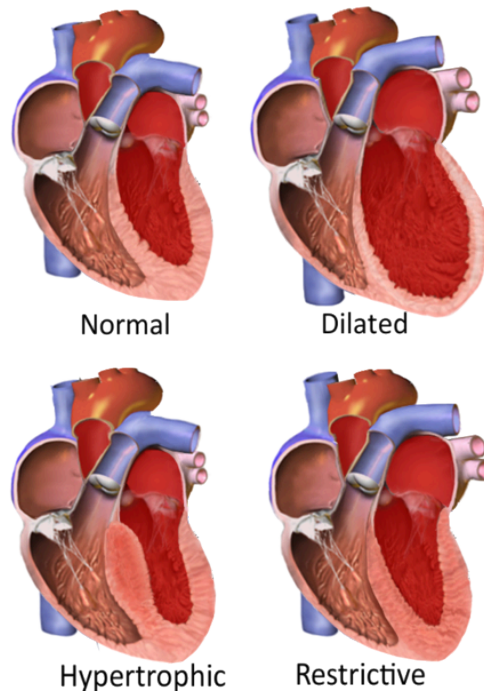


Figure 9.12 Categories of Cardiomyopathy

CONGENITAL HEART CONDITIONS

A **congenital** (kŏn-JĔN-ĭ-tăĭ) condition means it is present at birth. There are several types of congenital heart disorders. Some are caused by openings present in the heart that do not close as they should after birth. See Figure 9.13⁸ for an illustration of common congenital cardiac disorders.

8. [“2009_Congenital_Heart_Defects.jpg”](#) by OpenStax College is licensed under CC BY 3.0

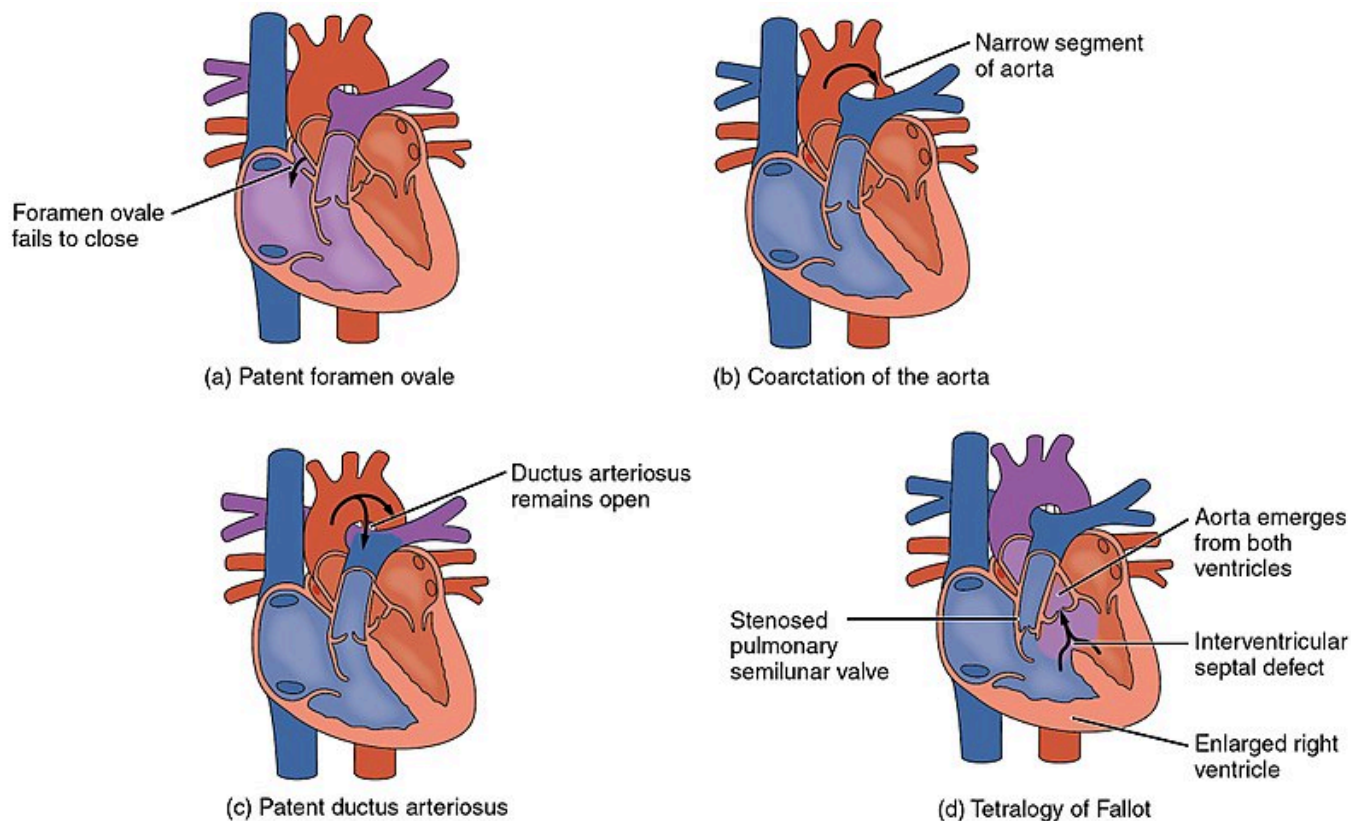


Figure 9.13 Examples of Congenital Heart Disorders

- **Patent ductus arteriosus** (PĀ-těnt DŮK-tŭs är-tēr'-ē-ō-sŭs) occurs when the ductus arteriosus fails to close after birth. The ductus arteriosus is a vessel in the fetal heart that connects the pulmonary trunk and aorta, bypassing the pulmonary circulation.
- **Patent foramen ovale** (PĀ-těnt fŏ-rā'-mĕn ō-vā'-lē) is a hole in the septum between the atria of the heart that does not close at birth.
- **Coarctation** (kō-ark-TĀ-shŏn) of the aorta is a narrowing of the aorta that forces the heart to pump harder to move blood through the aorta.
- **Atrial septal defect** (Ā-trē-ăl SĚP-tăl dī-FĚKT) (**ASD**) refers to an opening that exists in the septum (wall) between the left and right atria.
- **Ventricular septal defect** (ven-TRĪK-yŭ-lăr SĚP-tăl dī-FĚKT) (**VSD**) is an opening that exists in the septum (wall) between the left and right ventricles.

Tetralogy of Fallot (tĕt'ră-lō-jē ōf fă-LŌ) is a serious congenital disorder with

high mortality. It includes several abnormal conditions in the heart that allow unoxygenated blood from the right ventricle to flow into the left ventricle and mix with the blood that is relatively high in oxygen. Symptoms of Tetralogy of Fallot include a heart murmur, dyspnea, low blood oxygen saturation, clubbing of the fingers and toes, difficulty in eating, and failure to grow and develop. A **murmur** (MUR-mŭr) is an abnormal heart sound heard on auscultation by a stethoscope that may sound like a “whooshing” sound. Tetralogy of Fallot is diagnosed by echocardiography. Treatment involves extensive surgical repair.⁹

CORONARY ARTERY DISEASE

Coronary artery disease (KOR-ŏ-nā-rē AR-tēr-ē dĩ-ZĒZ) (**CAD**) occurs when atherosclerosis (i.e., buildup of plaque) in the coronary arteries obstructs the flow of oxygenated blood to the heart muscle. As oxygenated blood flow to the cardiac muscle cells is reduced, referred to as **ischemia** (ĩs-KEE-mē-ă), individuals often experience chest pain called **angina** (an-JĪ-nă). See Figure 9.14¹⁰ for an image of a blockage of coronary arteries on an angiogram.

9. This work is a derivative of Anatomy & Physiology by [OpenStax](#) and is licensed under [CC BY 4.0](#). Access for free at <https://openstax.org/details/books/anatomy-and-physiology-2e>

10. “[2016_Occluded_Coronay_Arteries.jpg](#)” by OpenStax College is licensed under [CC BY 3.0](#)

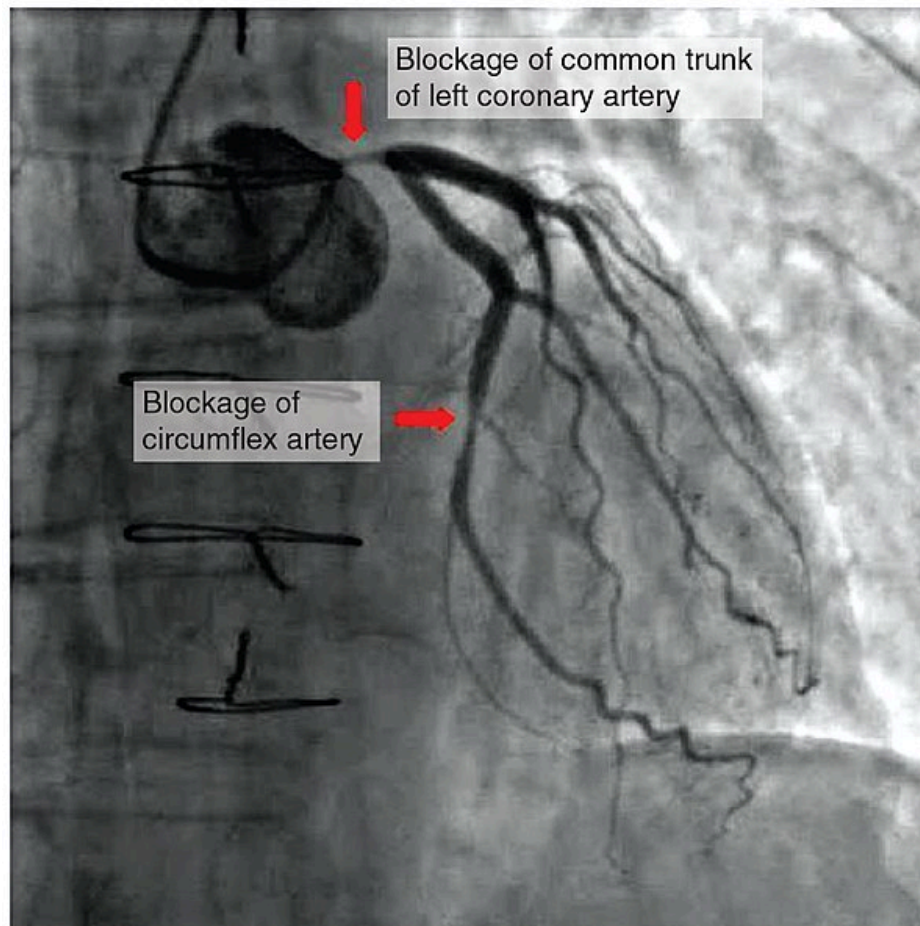


Figure 9.14 Angiogram of Atherosclerotic Coronary Arteries

CAD is progressive and, if left untreated, can cause a myocardial infarction (MI). Risk factors include smoking, family history, hypertension, obesity, diabetes, lack of physical activity, stress, hyperlipidemia, and excessive alcohol use. Treatments may include medication, changes to diet and exercise, angioplasty with insertion of a stent, or coronary artery bypass graft (CABG).¹¹ Read more about these procedures in the “[Medical Specialists](#),”

11. Centers for Disease Control and Prevention. (2023, May 15). *About heart disease*. Department of Health & Human Services. <https://www.cdc.gov/heartdisease/about.htm>

DEEP VEIN THROMBOSIS

A **deep vein thrombosis** (dēp vān THROM-bō-sīs) (**DVT**) is a blood clot in a deep vein that most often occurs in the lower extremities. DVTs can break free and become life-threatening emboli that travel to other areas of the body and cause blockages. For example, a pulmonary embolus (PE) is a medical emergency caused by a DVT that became an embolus and lodged in the lung.

Symptoms of a DVT often include calf pain in one leg with swelling, redness, and warmth of that leg. A DVT is diagnosed with a Doppler ultrasound that identifies altered blood flow in a vessel due to a clot.¹²

EDEMA

Despite the presence of valves within veins that prevent the backflow of blood, over the course of a day, some blood will inevitably pool in the lower limbs, due to the pull of gravity. Any blood that accumulates in a vein will increase the pressure within it. Increased pressure will promote the flow of fluids out of the capillaries and into the interstitial fluid. The presence of excess tissue fluid around the cells leads to a condition called **edema** (e-DĒ-ma). Medications, such as diuretics, and compression stockings are used to

¹². This work is a derivative of [StatPearls](#) by Baker, Anjum, & dela Cruz and is licensed under [CC BY 4.0](#)

help minimize the edema. See Figure 9.15¹³ for an image of a patient with edema.

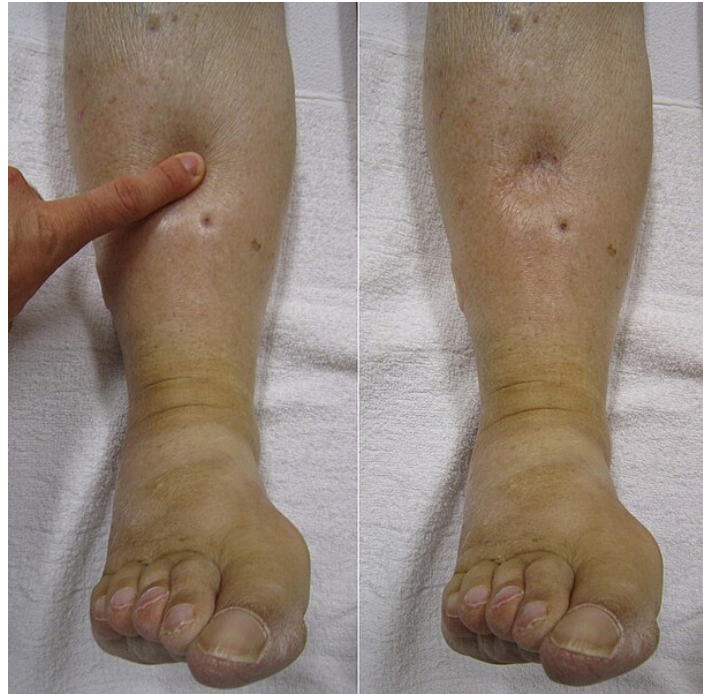

Figure 9.15 Edema

HEART FAILURE

Heart failure (HART FĀL-yŭr) (**HF**) occurs when the heart loses its effectiveness in pumping blood. When the heart is not pumping effectively, symptoms of fatigue, shortness of breath, edema, or lung congestion can occur. Chronic HF is a progressive disorder that can be represented on a continuum. The continuum ranges from individuals who are at risk for HF but are asymptomatic, to individuals who have end-stage heart failure and require end-of-life care. Treatments may include medication, a low sodium

¹³. “[Combinpedal.jpg](#)” by [James Heilman, MD](#) is licensed under [CC BY-SA 3.0](#)

diet, and fluid restrictions.¹⁴ See Figure 9.16¹⁵ for an illustration of common symptoms of heart failure.

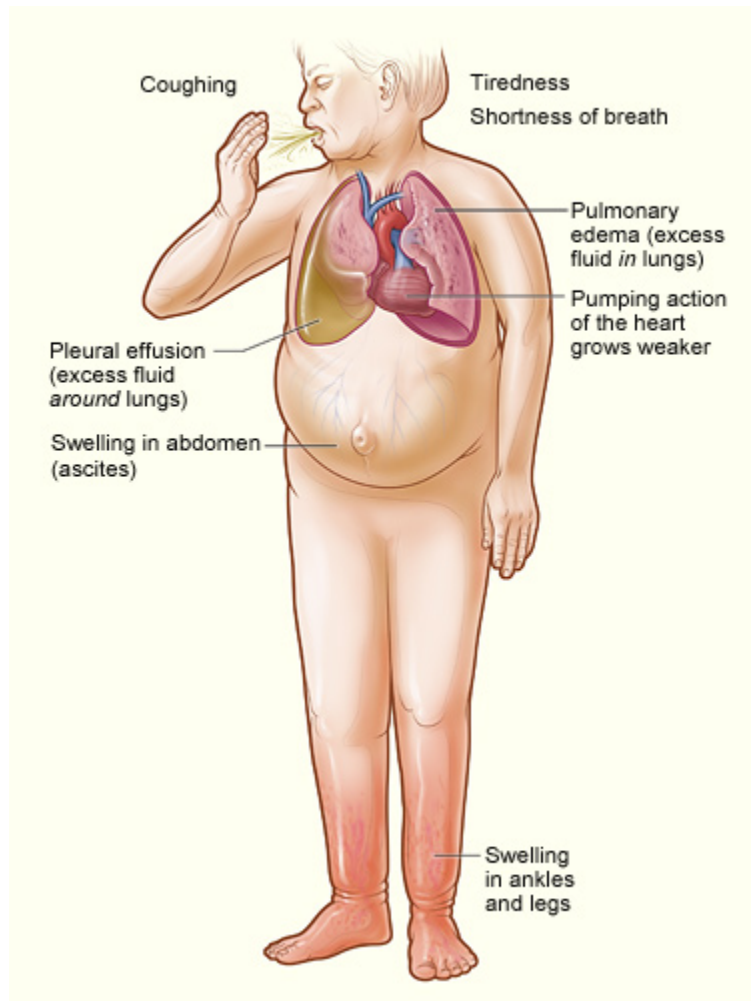


Figure 9.16 Heart Failure

14. Centers for Disease Control and Prevention. (2023, April 14). *Heart disease*. Department of Health & Human Services. <https://www.cdc.gov/heartdisease/about.htm>
15. “Heartfailure.jpg” by National Heart, Lung, and Blood Institute, National Institutes of Health is licensed in the Public Domain.

There are many potential causes of HF, including coronary artery disease (CAD), myocardial infarction (MI), hypertension, valve disorders, and cardiomyopathy. Treatment for heart failure may include medications to eliminate excess fluid, a low salt diet, fluid restrictions, implanted devices that assist the heart to pump blood, and heart transplant surgery.¹⁶

HYPERTENSION

Hypertension (hī-pěr-TEN-shŏn) refers to elevated blood pressure greater than 120/80 mm Hg in an adult. Hypertension is very common, affecting millions of individuals worldwide. See Figure 9.17¹⁷ for an image of a **sphygmomanometer** (sfig-mō-mă-NOM-ět-ěr) used to obtain blood pressure readings.

- ¹⁶. Centers for Disease Control and Prevention. (2023, April 14). *Heart disease*. Department of Health & Human Services. <https://www.cdc.gov/heartdisease/about.htm>
- ¹⁷. “[Grade 1 hypertension.jpg](#)” by [Steven Fruitsmaak](#) is licensed under [CC BY 3.0](#)

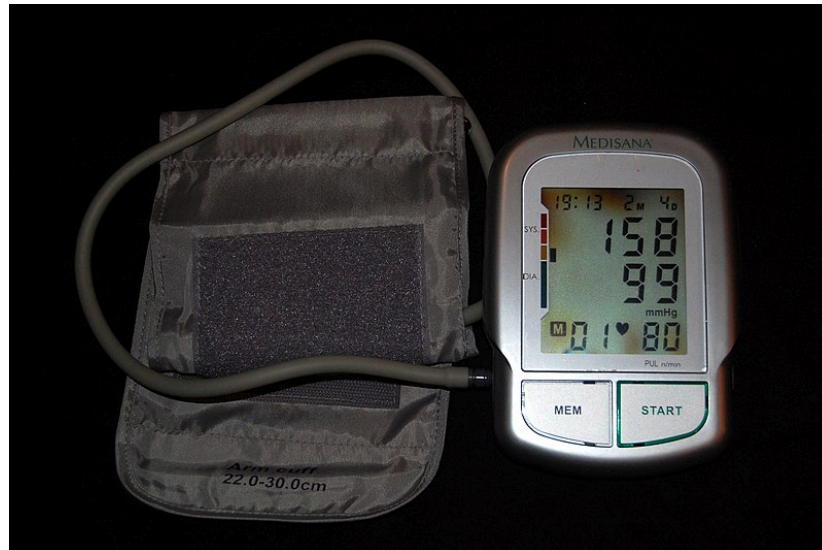

Figure 9.17 Sphygmomanometer

Risk factors for developing hypertension include age, ethnicity, family history, and lifestyle factors. Individuals with obesity, diets high in sodium, excessive alcohol intake, chronic stress, and limited physical activity are at higher risk for developing hypertension. Many people with hypertension do not have symptoms, so they are unaware they have the disorder until a complication like a myocardial infarction, stroke, or heart failure occurs. Treatment includes medications and healthy lifestyle changes like adopting a heart-healthy diet, exercising regularly, stopping smoking, getting good sleep, losing weight, and managing stress.¹⁸

MYOCARDIAL INFARCTION

18. National Heart, Lung, and Blood Institute. (2022, March 24). *What is high blood pressure*. National Institutes of Health. <https://www.nhlbi.nih.gov/health/high-blood-pressure>

Myocardial infarction (mī-ō-kar'dē-ăl in-FARK-shŏn) (**MI**), commonly called a heart attack, is caused by blockage of blood flow to the heart tissue, resulting in death of the cardiac muscle cells. **Acute coronary syndrome** (ə-KYŪT KOR-ŏ-nā-rē SĪN-drŏm) (**ACS**) is a general term used for medical situations in which blood supplied to the heart muscle is suddenly insufficient. An MI is commonly caused by atherosclerosis causing a blockage in a coronary artery. It can also occur when a piece of an atherosclerotic plaque breaks off and travels through the coronary arterial system until it lodges in one of the smaller vessels. See Figure 9.18¹⁹ for a depiction of an individual experiencing an MI and the damage occurring to the cardiac muscle as a result of the coronary artery blockage.

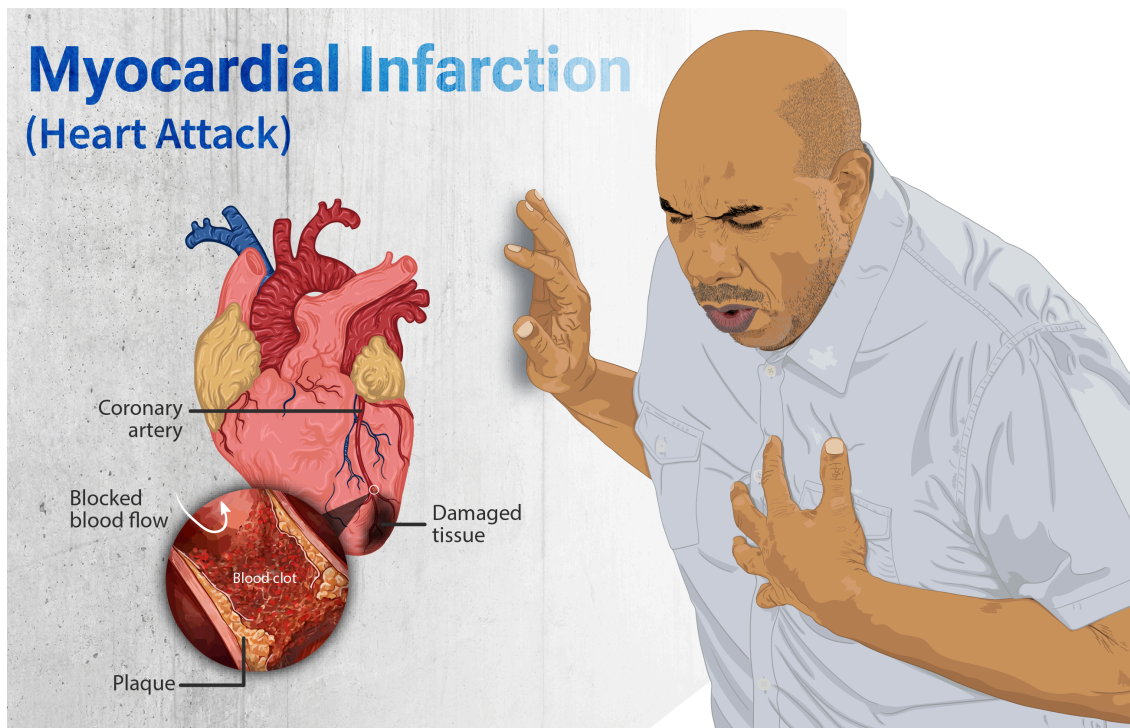


Figure 9.18 Myocardial Infarction

¹⁹. “[Depiction of a person suffering from a heart attack \(Myocardial Infarction\).png](https://www.myupchar.com/en)” by <https://www.myupchar.com/en> is licensed under [CC BY-SA 4.0](https://creativecommons.org/licenses/by-sa/4.0/)

A classic symptom of an MI includes sudden crushing pain beneath the sternum called **angina** (an-JĪ-nă) that may radiate down the left arm. Individuals often describe angina as “it feels as if something is sitting on my chest.” Other common symptoms include dyspnea, diaphoresis, nausea, and light-headedness. **Diaphoresis** (dī-ă-fō-RĒ-sīs) means profuse (excessive) sweating. However, females may not experience these symptoms and only have a feeling similar to indigestion.²⁰

An MI is a medical emergency. The faster the response, the more cardiac muscle cells that can be saved, so anyone who is suspected of having an MI should call 911. An MI is diagnosed with an **electrocardiogram** (ē-lĕk-trō-KĂR-dē-ō-grăġ) (**ECG**) and blood tests called cardiac enzymes. Cardiac enzymes include creatine kinase and cardiac troponin, both of which are released by damaged cardiac muscle cells.²¹

Immediate treatment typically includes administration of oxygen, aspirin (to stop the plaque from growing), and a medication called nitroglycerin (to help dilate the blood vessels to get more oxygenated blood to the cardiac muscle). Based on the results of the ECG and cardiac enzyme tests, the individual may undergo **thrombolysis** (thrŏm-BOL-ĭ-sīs), a procedure that involves administering a clot-dissolving medication to restore blood flow in a coronary artery. An alternative to thrombolysis is **angioplasty** (AN-jee-ŏ-plas-tē) or **coronary artery bypass graft surgery** (KOR-ŏ-nă-rē AR-tēr-ē bĭ-păs graft Sŭr-jĕr-ē) (**CABG**). Read more about these procedures in the “[Medical Specialists, Diagnostic Testing, and Procedures Related to Cardiovascular System](#)” section of this chapter.²²

20. American Heart Association. (n.d.). *Heart attack*. <https://www.heart.org/en/health-topics/heart-attack>

21. American Heart Association. (n.d.). *Heart attack*. <https://www.heart.org/en/health-topics/heart-attack>

22. American Heart Association. (n.d.). *Heart attack*. <https://www.heart.org/en/health-topics/heart-attack>

VALVULAR HEART DISEASE

The heart has four valves that open and close at specific times during the cardiac cycle to control or regulate the blood flowing into and out of the heart. See Figure 9.19²³ for an illustration of the heart valves including the tricuspid, pulmonary, mitral, and aortic. Three of the heart valves (tricuspid, pulmonary, and aortic valves) are composed of three leaflets or flaps that work together to open and close to allow blood to flow forward and not backwards through the opening. The mitral valve (also known as the bicuspid valve) only has two flaps that open and close.

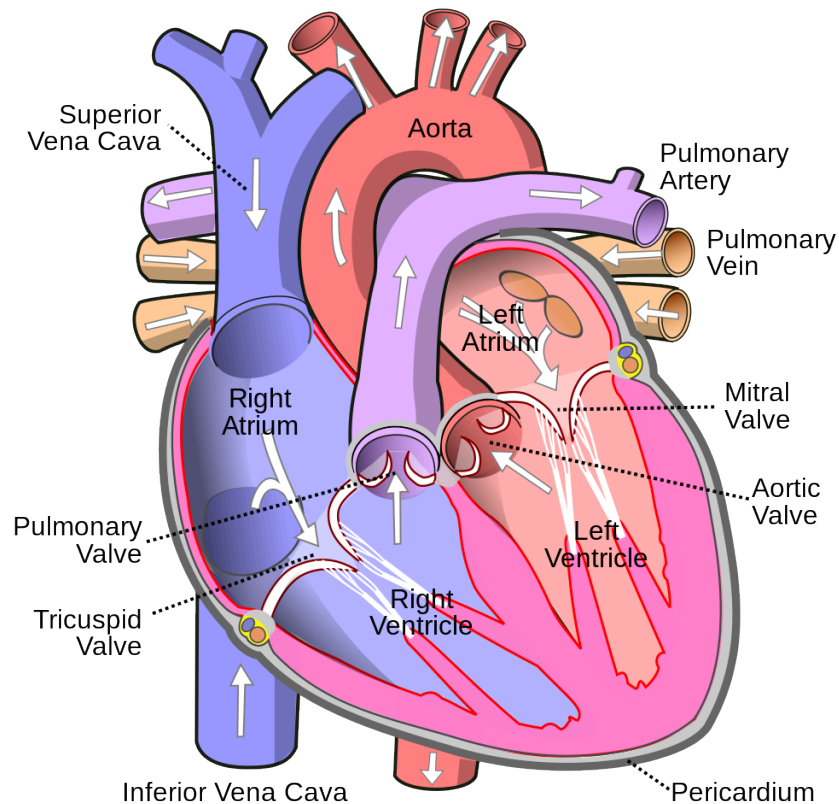


Figure 9.19 Heart Valves

23. “[Diagram of the human heart \(cropped\).svg](#)” by [Wapcaplet](#) is licensed under [CC BY 3.0](#)

Healthy heart valves fully open and close during the heartbeat, but patients with **valvular heart disease** (văl'-vyū-lăr härt dĩ-zēz') have diseased valves that do not fully open and close. Diseased valves that become “leaky” and don’t completely close cause a condition called **regurgitation** (rē-gŭr'-jĩ-tā'-shŭn). When regurgitation occurs, blood flows backwards and not enough blood is pushed forward through the heart. **Aortic insufficiency** (ā-OR-tĩk in-sŭ-FISH-ĕn-sē) **(AI)** is a valvular heart disease that occurs when the aortic valve does not close properly and allows regurgitation of blood back into the left ventricle.

Another type of valve disorder occurs when the opening of the valve is narrowed and stiff, causing it to not open fully when blood is trying to pass through. This disorder is called **stenosis** (stĕ-NŌ-sīs).²⁴

There are several causes of valvular heart disease, including congenital heart conditions, infections, degenerative conditions (i.e., they wear out with age), and conditions linked to other types of heart disease. A **murmur** (MUR-mŭr), an abnormal heart sound heard on auscultation by a stethoscope, is a classic sign of a valvular heart disorder. Other symptoms include shortness of breath, chest pain, fatigue, dizziness, and palpitations.²⁵

Valvular heart disease is diagnosed by echocardiography. Treatment may include medications to treat the symptoms or surgery to repair or replace the valves.²⁶ Read more about these procedures in the “[Medical Specialists, Diagnostic Testing, and Procedures Related to the Cardiovascular System.](#)”

24. Centers for Disease Control and Prevention. (2019, December 9). *Valvular heart disease*. Department of Health & Human Services. https://www.cdc.gov/heartdisease/valvular_disease.htm
25. Centers for Disease Control and Prevention. (2019, December 9). *Valvular heart disease*. Department of Health & Human Services. https://www.cdc.gov/heartdisease/valvular_disease.htm
26. Centers for Disease Control and Prevention. (2019, December 9). *Valvular heart disease*. Department of Health & Human Services. https://www.cdc.gov/heartdisease/valvular_disease.htm

VARICOSE VEINS

Varicose veins (VAR-i-kōs VĀNZ) are a common condition caused by weak or damaged vein walls and valves. Veins have one-way valves that open and close to keep blood flowing toward the heart. Weak or damaged valves or walls in the veins can cause blood to pool and even flow backward.²⁷ See Figure 9.20²⁸ for an image of varicose veins.

Symptoms include bulging, bluish veins, and a feeling of heaviness or discomfort in the legs and feet. Without treatment, they tend to grow worse over time. The use of compression stockings (commonly known as TED hose), as well as elevating the feet and legs whenever possible, may be helpful in alleviating the symptoms of varicose veins. However, severe cases may require resolution through medical procedures.²⁹

27. National Heart, Lung, and Blood Institute. (2023). *Varicose veins*.
<https://www.nhlbi.nih.gov/health/varicose-veins>

28. “[Varicose_ASV1.jpg](#)” by [Nini00](#) is licensed under [CC BY-SA 3.0](#)

29. National Heart, Lung, and Blood Institute. (2023). *Varicose veins*.
<https://www.nhlbi.nih.gov/health/varicose-veins>

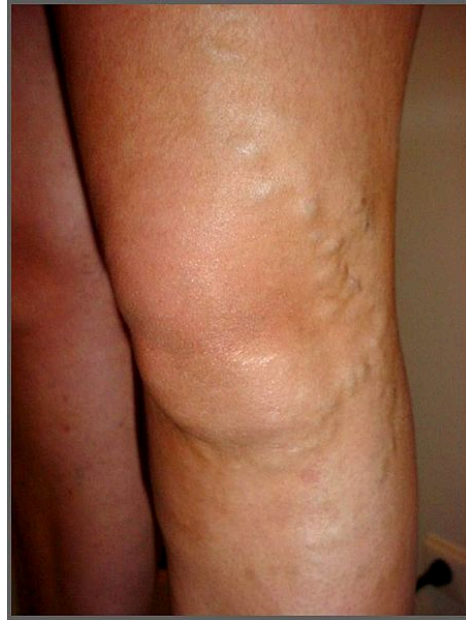

Figure 9.20 Varicose Veins

Procedures used to treat varicose veins include the following³⁰:

- **Endovenous laser ablation** (ĕn'-dō-vē'-nŭs lā'-zōr āb-lā'-shŭn) to close off a varicose vein. A health care provider uses laser or radiofrequency energy to heat the inside of the vein and close it off.
- **Sclerotherapy** (sklĕr-ō-THER-ă-pē) to seal off a varicose vein. The health care provider injects liquid or foam chemicals into the vein to create a plug that seals it shut.
- **Phlebectomy** (flĕ-BĔK-tō-mē) to remove small varicose veins. The health care provider makes small cuts to remove smaller veins near the skin.
- **Surgery** to tie off and remove large varicose veins in a procedure called vein ligation or stripping.

30. National Heart, Lung, and Blood Institute. (2023). *Varicose veins*.
<https://www.nhlbi.nih.gov/health/varicose-veins>

9.7 Medical Specialists, Diagnostic Testing, and Procedures Related to the Cardiovascular System

MEDICAL SPECIALISTS

Cardiology (kă-r-dē-ōl'ō-jē) is the study of the heart. Specialty roles related to cardiology include cardiologists, cardiovascular surgeons, electrophysiologists, cardiovascular technologists and technicians, cardiovascular perfusionists, cardiac care nurses, cardiology nurse practitioners, and cardiology physician assistants.

Cardiologists

A **cardiologist** (kar-dē-OL-ō-jīst) is a physician who specializes in the diagnosis and treatment of heart disease. Cardiovascular surgeons surgically treat heart disorders. An electrophysiologist is a physician who specializes in the diagnosis and treatment of issues related to the heart's electrical conduction system.

► Read more information about cardiologists on the [American Medical Association's Cardiovascular Disease Specialty web page](#).

Vascular Surgeon

Vascular surgery includes repair and replacement of diseased or damaged blood vessels, removal of plaque from vessels, and insertion of venous catheters, and traditional surgery.¹

Vascular Sonographer

Vascular sonographers use ultrasound machines to produce images of patients' veins and arteries using high-frequency sound waves. Physicians use these images that show the movement of blood through vessels to diagnose and treat various conditions.²

Cardiovascular Technologists and Technicians

Cardiovascular technologists and technicians perform cardiovascular diagnostic tests and procedures such as electrocardiography, stress testing, Holter monitor testing, ambulatory blood pressure (BP) testing, and pacemaker monitoring.

- ▶ Read more about cardiovascular technologist and technician positions on the U.S. Bureau of Labor Statistics [29-2031 Cardiovascular Technologists and Technicians](#) page.

1. Society for Vascular Surgery. (2023). *What is a vascular surgeon?*
<https://vascular.org/patients-and-referring-physicians/common-questions/what-vascular-surgeon>
2. American Registry of Radiologic Technologists. (n.d). *Vascular sonography*.
<https://www.arrt.org/pages/earn-arrt-credentials/credential-options/vascular-sonography>

Cardiovascular Perfusionist

Cardiovascular perfusionists operate circulation equipment that artificially support or temporarily replace a patient's circulatory or respiratory function. An example of such equipment is a heart-lung machine used during some types of coronary artery bypass surgery.

- ▶ Visit the [Mayo Clinic: Cardiovascular Perfusionist web page](#) for more information.

Cardiac Care Nurses

Cardiac care nurses provide care for patients with a variety of heart diseases or conditions in a cardiac care unit (CCU) in hospitals. They administer heart medications, help patients recover from heart surgery, or perform emergency care like assisting in defibrillation.

Cardiology Nurse Practitioners

Cardiology nurse practitioners (NPs) are registered nurses with advanced education and clinical experience to provide care for patients with chronic and acute cardiac diseases. Many cardiology NPs work in private practices, inpatient hospitals, outpatient clinic settings, or multiple practice settings where they assess the health status of patients, prescribe pharmacological and nonpharmacological treatments, and collaborate with an interdisciplinary team.

- ▶ Read more information on "[A Day in the Life of a Cardiology Nurse Practitioner \(NP\)](#)" web page by the American Association of Nurse Practitioners.

Cardiology Physician Assistants

Cardiology physician assistants (PAs) work in collaboration with cardiologists and cardiovascular surgeons. They provide a broad range of medical care to patients with varied clinical duties depending on the subspecialty and setting. PAs take medical histories, perform physical examinations, order and interpret laboratory and diagnostic tests, diagnose illness, develop and manage treatment plans for their patients, prescribe medications, perform procedures, and assist in surgery.

- ▶ Read more information about cardiology PAs on the [“PAs in Cardiology” PDF](#) from the American Academy of Physician Assistants website.

Radiology Technologist

A **radiology technologist** (rā-dē-ŎL-ŏ-jē tĕk-nŎL-ŏ-jĭst), commonly called an X-ray tech, is a health care professional who is specially trained to perform medical imaging like X-rays, CT scans, MRIs, and PET scans. To become a radiology technologist or MRI technologist, a person completes an associate degree and passes a certification exam.

- ▶ Read more information about the occupational outlook for radiology technologists on the [U.S. Bureau of Labor Statistics](#) webpage.

DIAGNOSTIC TESTING

Cardiac Catheterization and Angiogram

Cardiac catheterization (kär'dē-āk kăth-ě-těr-ĭ-ZĀ-shŏn) is a valuable diagnostic procedure in the evaluation and management of cardiovascular disorders. Cardiac catheterization, performed in association with a coronary angiogram, is a diagnostic procedure used to visualize the coronary arteries, heart chambers, and great vessels. It involves the insertion of a thin, flexible tube (catheter) into the blood vessels, usually through the femoral or radial artery, to access the inside of the heart and its surrounding structures.

During a **coronary angiogram** (KOR-ŏ-nā-rē AN-jee-ō-gram), dye is injected into the blood vessels of the heart, and then a series of X-ray images (angiograms) are taken to view the coronary arteries. If a blockage is discovered, an angioplasty can be performed. Read more about angioplasty under the “Procedures” subsection later in this section.

See Figure 9.21³ for an image of a cardiac catheterization procedure showing the image of the patient's coronary arteries and heart chambers displayed on the monitor during the angiogram.

3. [“A cardiac catheterization procedure in the Naval Medical Center San Diego hospital’s cardiac catheterization laboratory.jpg”](#) by Navy Medicine is licensed in the [Public Domain](#).

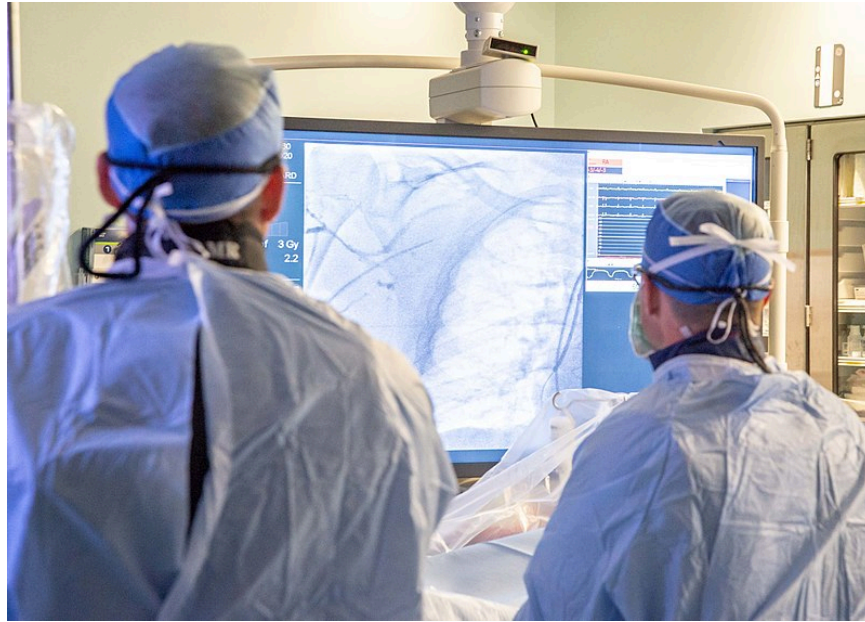

Figure 9.21 Angiogram and Cardiac Catheterization

Cardiac Stress Test

A **cardiac stress test** (kär'-dē-āk strēs tĕst), also known as an exercise stress test or treadmill test, is a diagnostic procedure used to evaluate the performance and function of the heart during physical activity. It helps identify potential heart problems, such as coronary artery disease (CAD), arrhythmias, and heart valve issues. During a cardiac stress test procedure, a patient is asked to walk on a treadmill or pedal a stationary bicycle to evaluate the heart's function during strenuous activity. In patient circumstances where walking on a treadmill is not appropriate, medication is administered intravenously to mimic the stress on the heart induced by exercise, referred to as a chemical stress test. See Figure 9.22⁴ for an image of a cardiac stress test.

4. [“a-cardiologist-examining-a-patient-undergoing-cardiac-stress-test-8460228”](#) by [Los Muertos Crew](#) via [Pexels](#) is licensed under [CC0](#).

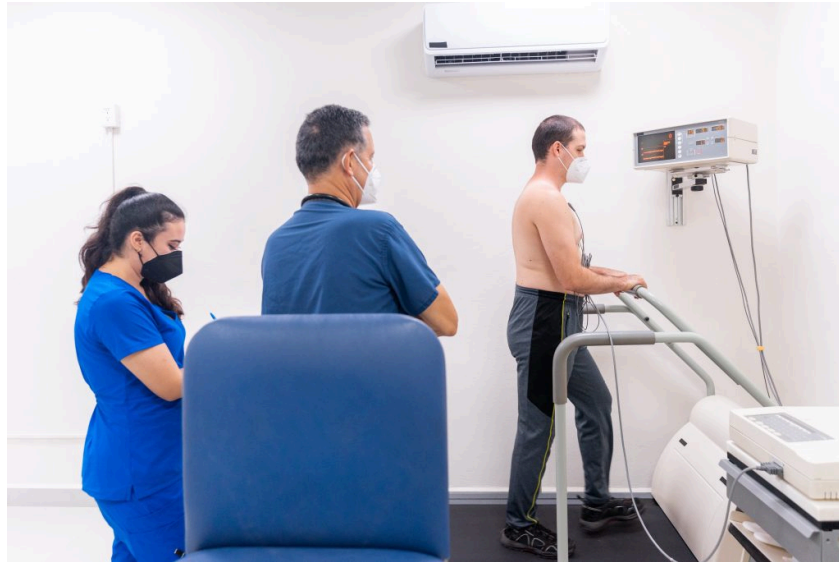

Figure 9.22 Cardiac Stress Testing

Electrocardiogram

An **electrocardiogram** (ē-lĕk-trō-KĀR-dē-ō-grăġm) (**EKG** or **ECG**) is a diagnostic test that records the electrical activity of the heart. It is performed to diagnose a myocardial infarction (MI) or cardiac rhythm abnormalities. See Figure 9.23⁵ for an image of a patient undergoing an ECG.

5. “[ambulance-emergency-medic-health-3592155](#)” by [OsloMetX](#) via [pixabay](#) is licensed under [CC0](#)

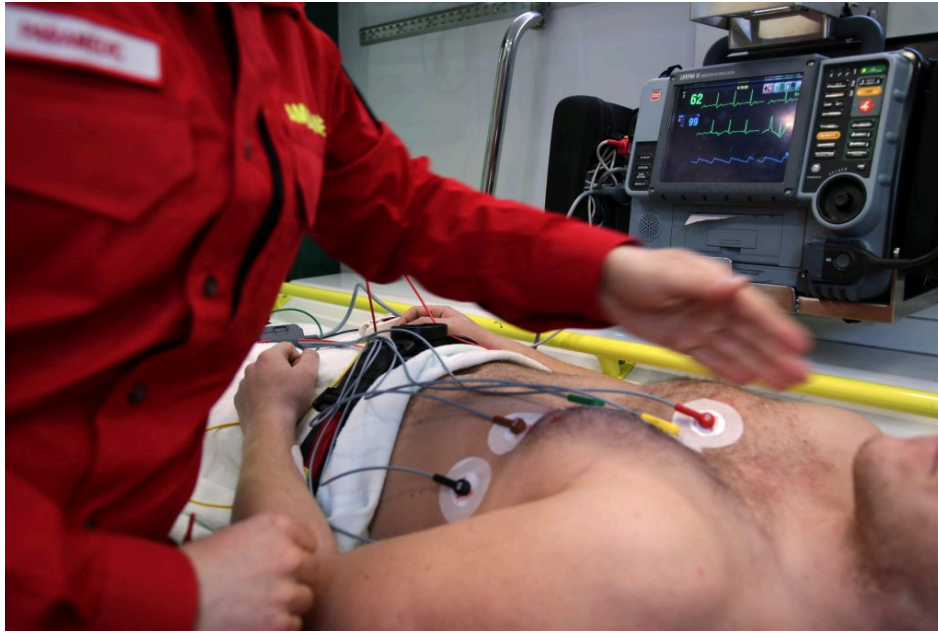


Figure 9.23 ECG Test

During an ECG, surface electrodes are placed on specific anatomical sites on the body to record electrical activity. An example of a 12-lead ECG is presented in Figure 9.24.⁶

6. “12_lead_ECG.jpg” by [Peterhcharlton](#) is licensed under [CC BY 4.0](#)

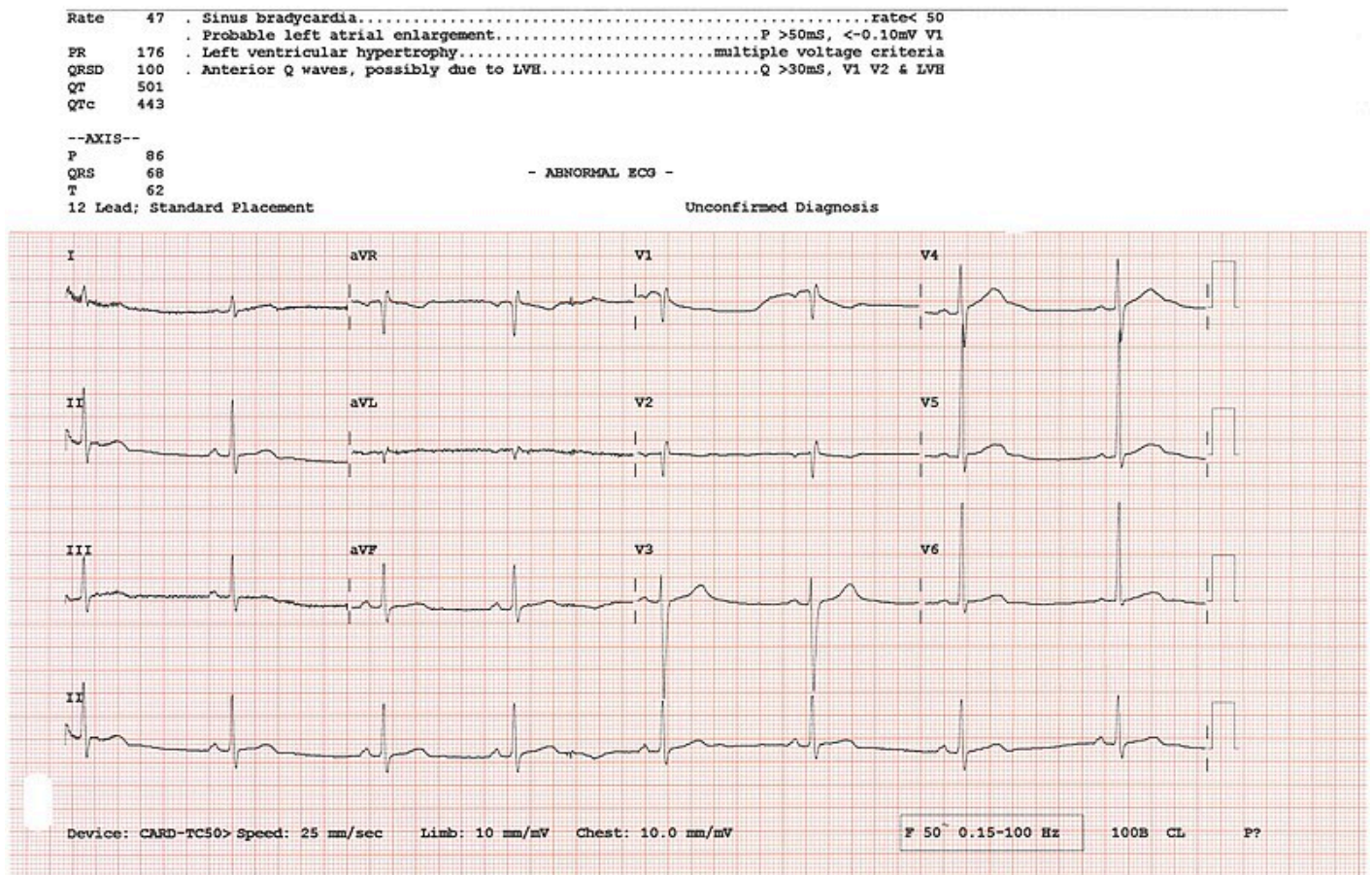


Figure 9.24 ECG Reading

Echocardiogram

An **echocardiogram** (ek-ō-KAR-dē-ō-gram) (**ECHO**) is a noninvasive diagnostic test that uses sound waves (ultrasound) to create real-time images of the heart's structure and function. A trained sonographer or cardiologist applies a gel and a transducer to the patient's chest. The transducer is moved to different areas of the chest to obtain various views of the heart, including the heart chambers, valves, walls, and blood flow patterns. Doppler ultrasound is also used during echocardiography to determine the speed and direction of blood flow through the valves and chambers of the heart. An

echocardiogram is often used to diagnose heart failure and valve disorders impacting the flow of blood through and out of the heart.⁷

A **transesophageal echocardiogram** (trăn-sē-sǒf-ă-JĒ-ăl ek-ō-KAR-dē-ō-gram) (**TEE**) uses an ultrasound probe placed in the patient's esophagus to provide a more direct view of heart structures.

Holter Monitor

A **Holter monitor** (HOL-těr MON-ĭ-tǒr) is a portable device that continuously records a patient's heart rhythm and electrical activity over an extended period, typically 24 to 48 hours. See Figure 9.25⁸ for an illustration of a Holter monitor. Its primary purpose is to detect and document irregularities in the heart's electrical patterns, such as arrhythmias, which may not be captured during brief in-office ECGs. Additionally, patients may activate a trigger on a Holter device to denote the occurrence of cardiac symptoms, such as increased shortness of breath, fatigue, or dizziness. A cardiologist reviews ECG tracings to identify arrhythmias.

7. Johns Hopkins Medicine. (n.d.). *Echocardiogram*.

<https://www.hopkinsmedicine.org/health/treatment-tests-and-therapies/echocardiogram>

8. "Holter_Monitor.png" by BruceBlaus is licensed under [CC BY-SA 4.0](#)

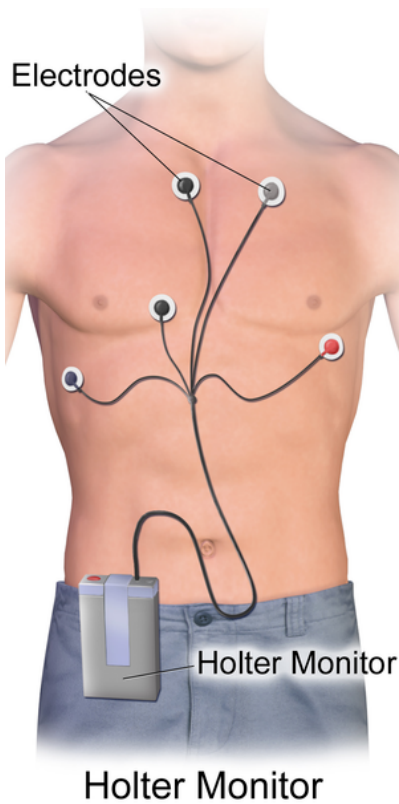


Figure 9.25 Holter Monitor

SPECT Scan

A **single-photon emission computerized tomography scan** (sĭng'-gŭl fō'-tŏn ē-mĭsh'-ŭn kŏm-pyŭ'-tə-rĭzd tŏ-mŏg'-rə-fē skăn) (**SPECT**) analyzes the function of the body's organs, tissues, and bones. For example, a SPECT scan can show how well blood is flowing in the coronary arteries or arteries in the brain. It can also show how completely the heart chambers empty during contractions. A SPECT scan is a type of nuclear imaging test, which means it uses a radioactive substance and a special camera to create 3D pictures. A radioactive substance is administered via **intravenous** (ĭn-tră-VĒ-nŭs) (**IV**) infusion (i.e., into a vein). The SPECT machine is a large circular device containing a camera that detects the radioactive tracer the body absorbs. During the scan, the patient lies on a table while the SPECT machine rotates around them and takes images of their internal organs and other structures.

The pictures are sent to a computer that uses the information to create 3D images of the body.⁹

PROCEDURES

Cardiac Ablation

Cardiac ablation (kär'dē-āk ă-BLĀ-shŏn) uses heat or cold energy to create tiny scars in the heart to block irregular electrical signals and restore a typical heartbeat. This procedure is used to correct various types of arrhythmias. Cardiac ablation is most often done using thin, flexible tubes called catheters inserted through veins or arteries but can also be performed during cardiac surgery.¹⁰

Angioplasty

During a cardiac catheterization, if a blockage is found, an **angioplasty** (AN-jee-ō-plas-tē) may be performed, also referred to as a **percutaneous transluminal coronary angioplasty** (pěr-kyū-TĀ-nē-ŭs trāns-LOO-mĭ-nāl KOR-ŏ-nā-rē AN-jee-ō-plas-tē) (**PTCA**). During an angioplasty, a catheter with a balloon at the tip is inserted into the narrowed coronary artery. The balloon is inflated to widen the artery and improve blood flow. A small mesh device, known as a stent, is often inserted to help keep the coronary artery open after

9. Mayo Clinic. (2022, July 27). *SPECT scan*. <https://www.mayoclinic.org/tests-procedures/spect-scan/about/pac-20384925>

10. Mayo Clinic. (2022, February 22). *Cardiac ablation*. <https://www.mayoclinic.org/tests-procedures/cardiac-ablation/about/pac-20384993>

the procedure is completed. See Figure 9.26¹¹ for an illustration of an angioplasty with stent placement.

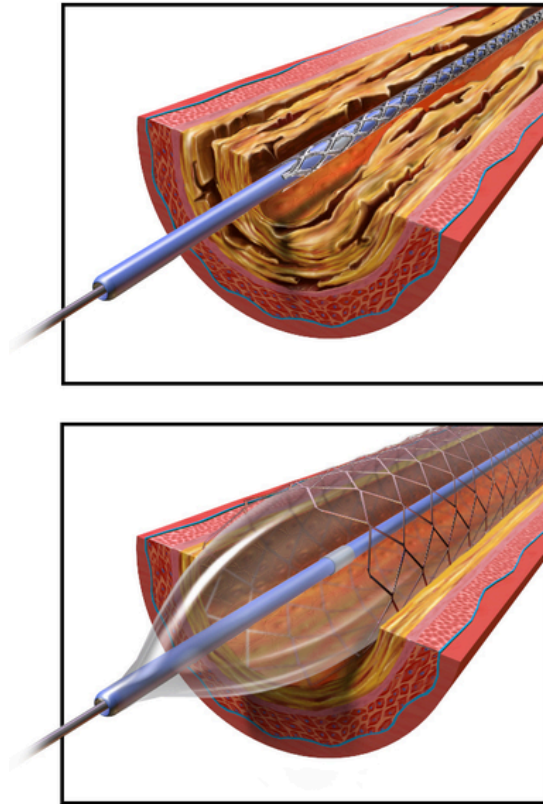


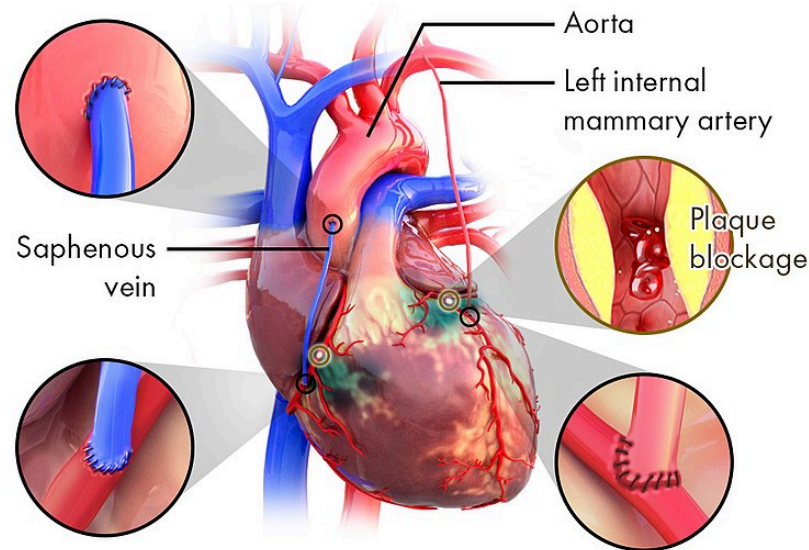
Figure 9.26 Angioplasty with Stent Placement

Coronary Artery Bypass Surgery

Coronary artery bypass (KOR-ō-nā-rē AR-tēr-ē bī-pās) surgery, also called **coronary artery bypass graft** (KOR-ō-nā-rē AR-tēr-ē bī-pās graft) (**CABG**), creates a new path for blood to flow around a blocked or partially blocked coronary artery. The surgery involves taking a healthy blood vessel, often from the chest or leg area, and connecting it underneath the blocked artery to

11. “[Angioplasty - Balloon Inflated with Stent.png](#)” by [BruceBlaus](#) is licensed under [CC BY-SA 4.0](#)

improve blood flow to heart muscle. During surgery, a heart-lung machine may be used to artificially keep oxygenated blood flowing through the patient's body. CABG doesn't cure the heart disease, but it can reduce symptoms and may reduce the risk of heart disease-related death.¹² See Figure 9.27¹³ for an illustration of a CABG.



CORONARY ARTERY BYPASS SURGERY

Figure 9.27 Coronary Artery Bypass Surgery

Heart Transplant

A **heart transplant** (härt träs'-plänt) replaces a patient's failing heart with a donor heart. The failing heart may be a result of end-stage heart failure,

¹². Mayo Clinic. (2022, December 3). *Coronary artery bypass surgery*.
<https://www.mayoclinic.org/tests-procedures/coronary-bypass-surgery/about/pac-20384589>

¹³. "Coronary Artery Bypass Surgery.jpg" by BruceBlaus is licensed under CC BY-SA 4.0

arrhythmias, a congenital heart condition, or other severe heart condition. A healthy heart is donated via organ donation from someone who died. During the transplant procedure, the surgeon removes the patient's failing heart and then connects the donor heart by sewing together the recipient's and donor vena cavae, aorta, pulmonary artery, and left atrium. In patients with congenital heart disease, the surgeon might also transplant the lungs with the heart. For the rest of the patient's life, they are prescribed immunosuppressive and other medications to prevent their body from rejecting the donated heart.¹⁴ See Figure 9.28¹⁵ for an illustration of a heart transplant.

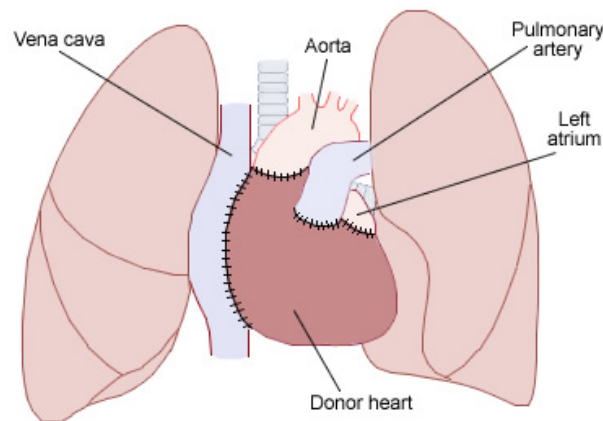


Figure 9.28 Heart Transplant

Pericardiocentesis

Pericardiocentesis (per-ĩ-kar-dē-ō-sen-TĒ-sīs) is a procedure that involves

14. American Heart Association. (2023, September 19). *Heart transplant*.
<https://www.heart.org/en/health-topics/congenital-heart-defects/care-and-treatment-for-congenital-heart-defects/heart-transplant>
15. “Heart_transplant.jpg” by D Dinneen~commonswiki is licensed under [CC BY-SA 3.0](#)

draining fluid from the pericardial sac around the heart. It involves the cardiologist inserting a needle into the patient's chest until the tip of the needle is inside the pericardium and then draining fluid or placing a drain that can remove fluid slowly over time. Before inserting the needle, the physician and the imaging technician use ultrasound guidance via an echocardiogram to help insert the needle at the specific point needed and prevent injury to the heart.¹⁶ See Figure 9.29¹⁷ for an illustration of pericardiocentesis.

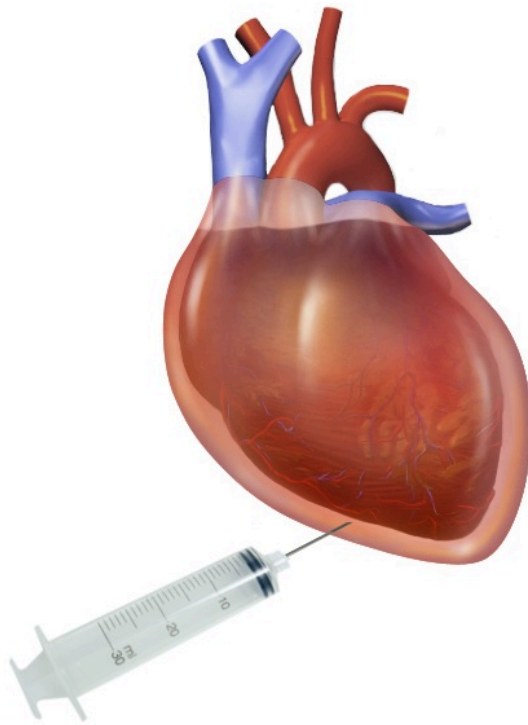


Figure 9.29 Pericardiocentesis

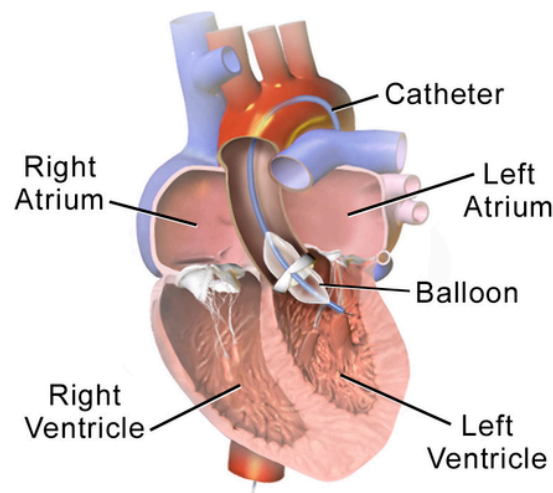
¹⁶. Cleveland Clinic. (2022, February 26). *Pericardiocentesis*.

<https://my.clevelandclinic.org/health/treatments/22613-pericardiocentesis>

¹⁷. “[Pericardiocentesis.jpg](#)” by [Npatchett](#) is licensed under [CC BY-SA 4.0](#)

Valvuloplasty

A **valvuloplasty** (val-VŪ-lō-plas-tē) is a procedure performed by a cardiovascular surgeon to repair a heart valve that has a narrowed opening, referred to as stenosis. Valvuloplasty is performed during a cardiac catheterization. Similar to an angioplasty, a soft, thin tube with a balloon at the tip is inserted into a blood vessel, usually in the groin. The catheter is carefully guided to the narrowed valve in the heart. Once in position, the balloon is inflated to widen the valve, improving blood flow. The balloon is then deflated, and the catheter with balloon is removed.¹⁸ See Figure 9.30¹⁹ for an illustration of a valvuloplasty on the aortic valve.



Balloon Valvuloplasty for Aortic Stenosis

Figure 9.30 Valvuloplasty

¹⁸. Mayo Clinic. (2022, March 18). *Valvuloplasty*. <https://www.mayoclinic.org/tests-procedures/valvuloplasty/pyc-20384961>

¹⁹. “*Valvuloplasty_Aortic.png*” by [BruceBlaus](#) is licensed under [CC BY-SA 4.0](#)

Valve Replacement

If a malfunctioning heart valve can't be repaired, the valve may be surgically replaced, referred to as a **valve replacement** (vălv rē-plās'-měnt). The cardiovascular surgeon removes the heart valve and replaces it with a mechanical valve, or a valve made from cow, pig, or human heart tissue (called a biological valve). Biological valves often need to be replaced because they break down over time. Mechanical valves are more durable but require the patient to take blood-thinning medications for the rest of their life to prevent blood clots.²⁰ See Figure 9.31²¹ for an illustration of valve replacement with a mechanical valve.

20. Mayo Clinic. (2022, December 14). *Heart valve surgery*.

<https://www.mayoclinic.org/tests-procedures/heart-valve-surgery/about/pac-20384901>

21. "Blausen_0056_ArtificialHeartValve.png" by [BruceBlais](#) is licensed under [CC BY 3.0](#)

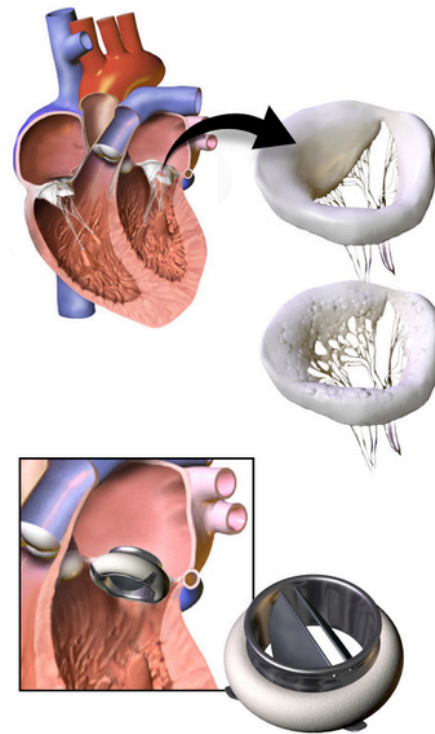


Figure 9.31 Valve Replacement With a Mechanical Valve

9.8 Cardiovascular Learning Activities

Interactive Learning Activity: Label the parts of the heart using this drag and drop activity.



An interactive H5P element has been excluded from this version of the text. You can view it online here:

<https://wtcs.pressbooks.pub/medterm/?p=691#h5p-148>

Interactive Learning Activity: Study cardiovascular system medical terms discussed in this chapter using these flashcards.



An interactive H5P element has been excluded from this version of the text. You can view it online here:

<https://wtcs.pressbooks.pub/medterm/?p=691#h5p-183>

Interactive Learning Activity: Test your knowledge of the cardiovascular system by completing this activity.



An interactive H5P element has been excluded from this version of the text. You can view it online here:

<https://wtcs.pressbooks.pub/medterm/?p=691#h5p-153>

Interactive Learning Activity: Using the sample documentation provided, drag the terms on the right to their appropriate spaces within the documentation.



An interactive H5P element has been excluded from this version of the text. You can view it online here:

<https://wtcs.pressbooks.pub/medterm/?p=691#h5p-151>

Interactive Learning Activity: Using the sample documentation provided, drag the terms on the right to their appropriate spaces within the documentation.



An interactive H5P element has been excluded from this version of the text. You can view it online here:

<https://wtcs.pressbooks.pub/medterm/?p=691#h5p-58>



Interactive Learning Activity: Practice identifying and defining word parts for terms discussed in this chapter.



An interactive H5P element has been excluded from this version of the text. You can view it online here:

<https://wtcs.pressbooks.pub/medterm/?p=691#h5p-200>

- ▶ You can also print this as a [Chapter 9 Practice Worksheet](#) and check your answers with this [Answer Key PDF](#).

9.9 Glossary

Acute coronary syndrome (ə-KYŪT KOR-ŏ-nā-rē SĪN-drōm) (ACS): A term used to describe a range of conditions associated with sudden, reduced blood flow to the heart, including myocardial infarction. ([Chapter 9.6](#))

Aneurysm (AN-yŭ-rizm): A dilation or bulging of a blood vessel caused by weakened vessel walls, potentially leading to rupture. ([Chapter 9.6](#))

Angina (an-JĪ-nă): Chest pain caused by reduced blood flow to the heart muscle, often associated with coronary artery disease. ([Chapter 9.6](#))

Angioplasty (AN-jee-ō-plas-tē): A procedure to restore blood flow through the artery by inserting and inflating a tiny balloon; it may also involve placing a stent to keep the artery open. ([Chapter 9.6](#), [Chapter 9.7](#))

Aortic insufficiency (ā-OR-tĭk in-sŭ-FISH-ĕn-sē): A condition where the aortic valve does not close tightly, allowing blood to flow backward into the heart. ([Chapter 9.6](#))

Apex (Ā-peks): The inferior tip of the heart, located just to the left of the sternum between the junction of the fourth and fifth ribs. ([Chapter 9.4](#))

Arrhythmia (ā-RITH-mē-ă): An abnormal heart rhythm resulting from variations in the normal sequence of electrical impulses. ([Chapter 9.6](#))

Arterioles (ar-TĒR-ē-ōlz): Small branches of an artery leading into capillaries. ([Chapter 9.4](#))

Artery (AR-tĕr-ē): A blood vessel that carries blood away from the heart, branching into smaller vessels called arterioles. ([Chapter 9.4](#))

Atherosclerosis (ă-thĕr-ō-sklĕ-RO-sĭs): Hardening and narrowing of arteries due to the buildup of cholesterol and other fats, known as plaque, within the lining of the arteries. ([Chapter 9.6](#))

Atrial fibrillation (Ā-trē-ăl fĭb-rĭ-LĀ-shŏn) (A Fib): A common type of arrhythmia characterized by rapid and irregular beating of the atrial chambers of the heart. ([Chapter 9.6](#))

Atrial septal defect (Ā-trē-ăl SĚP-tăl dĭ-FĚKT): A congenital heart defect characterized by an opening in the septum between the left and right atria. ([Chapter 9.6](#))

Auscultation (os-kŭl-TĀ-shŏn): The process of listening to the internal sounds of the body, typically with a stethoscope, used in diagnosing conditions of the heart and lungs. ([Chapter 9.4](#))

Automated external defibrillator (aw-tŏ-māt'-ĕd ěks-tĕr'năl dĕ-fĭb'-rĭ-lā-tŏr) (AED): A portable device used in emergencies to treat sudden cardiac arrest by administering an electric shock. ([Chapter 9.6](#))

Blood pressure (BLŮD PRESĤ-ŭr) (BP): The force of blood against the walls of arteries, typically measured in millimeters of mercury (mm Hg). ([Chapter 9.5](#))

Bradycardia (brad-ĕ-KAR-dĕ-ă): A heart rate that is slower than normal, less than 60 bpm in adults, which can be normal or indicative of an underlying condition. ([Chapter 9.5](#), [Chapter 9.6](#))

Bruit (BRWĒ): An abnormal sound or murmur heard during auscultation of an artery, often due to atherosclerosis or narrowing. ([Chapter 9.6](#))

Capillary (KAP-ĭ-lār-ĕ): A microscopic channel that supplies blood to the tissue cells and connects arterioles with venules. ([Chapter 9.4](#))

Cardiac ablation (kăr'dĕ-ăk ă-BLĀ-shŏn): A procedure used to destroy problematic heart tissue that causes irregular heartbeats. ([Chapter 9.7](#))

Cardiac arrest (KAR-dĕ-ăk ăr-REST): A sudden cessation of heart function, often due to arrhythmias. ([Chapter 9.6](#))

Cardiac catheterization (kăr'dĕ-ăk kăth-ĕ-tĕr-ĭ-ZĀ-shŏn): A diagnostic procedure in which a catheter is inserted into a large blood vessel that leads to the heart. ([Chapter 9.7](#))

Cardiac output (KAR-dĕ-ăk OUT-put): The amount of blood pumped by the heart per minute. ([Chapter 9.5](#))

Cardiac stress test (kăr'-dĕ-ăk strĕs tĕst): A test that measures the heart's ability to respond to external stress in a controlled clinical environment. ([Chapter 9.7](#))

Cardiologist (kar-dĕ-OL-ŏ-jĭst): A physician who specializes in the diagnosis and treatment of heart diseases and conditions. ([Chapter 9.7](#))

Cardiology (kăr-dĕ-ŏl'ŏ-jĕ): The study of the heart and its functions in health and disease. ([Chapter 9.7](#))

Cardiomyopathy (kar-dĕ-ŏ-my-OP-ă-thĕ): A group of diseases that affect the heart muscle, leading to impaired cardiac function. ([Chapter 9.6](#))

Cerebrovascular disease (sěr'-brō-VAS-kyū-lār dī-ZĒZ) (CVD): A group of conditions affecting the blood vessels and blood supply to the brain, including stroke. ([Chapter 9.6](#))

Coarctation (kō-ark-TĀ-shŏn): A congenital condition characterized by the narrowing of the aorta, leading to reduced blood flow. ([Chapter 9.6](#))

Congenital (kŏn-JĒN-ĭ-tāl): A conditions present at birth, which can include a variety of heart disorders. ([Chapter 9.6](#))

Coronary angiogram (KOR-ŏ-nā-rē AN-jee-ō-gram): A procedure that uses X-ray imaging to see the heart's blood vessels. ([Chapter 9.7](#))

Coronary artery bypass (KOR-ŏ-nā-rē AR-těr-ē bī-pās): A type of surgery that improves blood flow to the heart. ([Chapter 9.7](#))

Coronary artery bypass graft surgery (KOR-ŏ-nā-rē AR-těr-ē bī-pās graft Sŭr-jěr-ē) (CABG): A surgical procedure used in coronary artery disease where blood flow is rerouted around a blocked artery. ([Chapter 9.6](#))

Coronary artery disease (KOR-ŏ-nā-rē AR-těr-ē dī-ZĒZ) (CAD): A condition where plaque buildup occurs in the coronary arteries, leading to reduced blood flow to the heart muscle. ([Chapter 9.6](#))

Deep vein thrombosis (dēp vān THROM-bō-sīs) (DVT): A blood clot in a deep vein, usually in the legs, which can be life-threatening if it dislodges and travels to the lungs. ([Chapter 9.6](#))

Defibrillator (dē-FIB-rī-lā-tŏr): A device used to deliver an electric shock to the heart to restore a normal rhythm. ([Chapter 9.6](#))

Diaphoresis (dī-ă-fŏ-RĒ-sīs): Excessive sweating, commonly associated with some cardiovascular events like a myocardial infarction. ([Chapter 9.6](#))

Diastole (dī-AS-tŏ-lē): The phase of the cardiac cycle when the heart muscles relax and the chambers fill with blood. ([Chapter 9.5](#))

Echocardiogram (ek-ŏ-KAR-dē-ō-gram): A sonographic imaging test that uses sound waves to produce images of the heart. ([Chapter 9.7](#))

Edema (e-DĒ-mă): Swelling caused by excess fluid trapped in the body's tissues, often occurring in the legs and ankles. ([Chapter 9.6](#))

Electrocardiogram (ē-lĕk-trō-KĀR-dē-ō-grām) (EKG or ECG): A test that measures the electrical activity of the heartbeat to show abnormalities in the heart rhythm and structure. ([Chapter 9.6](#), [Chapter 9.7](#))

Endovenous laser ablation (ĕn'-dŏ-vē'-nŭs lā'-zŏr ăb-lā'-shŭn): A minimally

invasive procedure used to treat varicose veins using laser energy. ([Chapter 9.6](#))

Heart block (härt blök): A condition where the electrical signals in the heart are partially or completely blocked. ([Chapter 9.6](#))

Heart failure (HART FĀL-yŭr) (HF): A condition where the heart can't pump blood efficiently to meet the body's needs, leading to symptoms like shortness of breath and edema. ([Chapter 9.6](#))

Heart rate (HART RĀT) (HR): The number of heartbeats per minute, with normal resting HR for an adult being 60–100 bpm. ([Chapter 9.5](#))

Heart transplant (härt trāns'-plānt): A surgical procedure to replace a diseased and nonfunctioning heart with a healthy heart from a donor. ([Chapter 9.7](#))

Holter monitor (HOL-těr MON-ĭ-tör): A portable device worn to continuously monitor the heart's rhythms and electrical activity. ([Chapter 9.7](#))

Hypertension (hī-pěr-TEN-shŏn) (HTN): Elevated blood pressure, typically defined as greater than 120/80 mm Hg in adults. ([Chapter 9.5](#), [Chapter 9.6](#))

Hypotension (hī-pō-TEN-shŏn): Abnormally low blood pressure. ([Chapter 9.5](#))

Implantable cardioverter defibrillator (ĭm-plānt'-ă-bŭl kār'dē-ō-vŭr'-tör dē-fĭb'-rĭ-lā-tör) (ICD): A device implanted in the chest to monitor heart rhythms and provide appropriate electrical therapy to correct arrhythmias. ([Chapter 9.6](#))

Inferior vena cava (VĒ-nă KĀ-vă): A large vein that carries deoxygenated blood from the lower body to the heart. ([Chapter 9.4](#))

Intravenous (ĭn-tră-VĒ-nŭs) (IV): Pertaining to within a vein, often referring to the administration of medications or fluids. ([Chapter 9.4](#), [Chapter 9.7](#))

Ischemia (ĭs-KEE-mē-ă): A condition where blood flow and oxygen are restricted or reduced in a part of the body, often due to narrowed or blocked arteries. ([Chapter 9.6](#))

Murmur (MUR-mŭr): A sound heard during heartbeat that may be a normal or an abnormal finding, often caused by turbulent blood flow. ([Chapter 9.6](#))

Myocardial infarction (mī-ŏ-kar'dē-ăl in-FARK-shŏn) (MI): Commonly known as a heart attack, caused by blockage of blood flow to the heart tissue resulting in death of cardiac muscle cells. ([Chapter 9.4](#), [Chapter 9.6](#))

Normal sinus rhythm (Sĭ-nŭs RITH-ŭm) (NSR): The regular, natural rhythm of the heart, characterized by coordinated electrical activity. ([Chapter 9.6](#))

Occlude (ŏ-KLOOD): To block or close a blood vessel or passage. ([Chapter 9.5](#))

Palpitations (pal-pĭ-TĀ-shŏnz): A sensation where an individual feels that their heart is racing, pounding, fluttering, or skipping a beat. ([Chapter 9.6](#))

Patent ductus arteriosus (PĀ-tĕnt DŮK-tŭs ār-tēr'-ē-ō-sŭs): A congenital heart defect where the ductus arteriosus fails to close after birth, allowing blood to flow between the aorta and pulmonary artery. ([Chapter 9.6](#))

Patent foramen ovale (PĀ-tĕnt fŏ-rā'-mĕn ō-vā'-lē): A congenital heart defect where a hole in the septum between the heart's atria does not close at birth. ([Chapter 9.6](#))

Percutaneous transluminal coronary angioplasty (pĕr-kyū-TĀ-nē-ŭs trāns-LOO-mĭ-nāl KOR-ŏ-nā-rē AN-jee-ō-plas-tē) (PTCA): A procedure to open up blocked coronary arteries, allowing blood to circulate unobstructed to the heart muscle. ([Chapter 9.7](#))

Perfusion (pĕr-FŪ-zhŏn): The passage of blood through the blood vessels to supply organs and tissues. ([Chapter 9.5](#))

Pericardiocentesis (per-ĭ-kar-dē-ō-sen-TĒ-sĭs): A procedure to remove fluid from the sac surrounding the heart. ([Chapter 9.7](#))

Peripheral artery disease (pĕr-IF-ēr-āl AR-tēr-ē dĭ-ZĒZ) (PAD): A condition characterized by narrowed arteries in the peripheral parts of the body, often leading to pain and muscle cramps. ([Chapter 9.6](#))

Phlebectomy (flĕ-BĚK-tŏ-mē): A surgical procedure to remove varicose veins. ([Chapter 9.6](#))

Pulse (PULS): The rhythmic expansion and recoil of arteries resulting from heart contraction; can be felt over arteries close to the body's surface. ([Chapter 9.5](#))

Regurgitation (rē-gŭr'-jĭ-tā'-shŭn): The backward flow of blood through a heart valve, indicating that the valve isn't closing properly. ([Chapter 9.6](#))

Sclerotherapy (sklĕr-ō-THER-ă-pē): A procedure used to treat varicose veins and spider veins by injecting a solution directly into the vein. ([Chapter 9.6](#))

Single-photon emission computerized tomography scan (sĭng'-gŭl fŏ'-tŏn ē-mĭsh'-ŭn kŏm-pyū'-tə-rĭzd tŏ-mŏg'-rə-fē skăn) (SPECT): A type of nuclear

medicine scan that provides detailed images of internal organs, including the heart. ([Chapter 9.7](#))

Sphygmomanometer (sfīg-mō-măn-ŎM-ět-ěr): An instrument used to measure blood pressure, commonly referred to as a blood pressure cuff. ([Chapter 9.5](#), [Chapter 9.6](#))

Stenosis (stě-NŌ-sīs): The abnormal narrowing of a passage in the body, such as a blood vessel or a heart valve. ([Chapter 9.6](#))

Stethoscope (STETH-ŏ-skōp): An instrument used to listen to heart and lung sounds, referred to as auscultation. ([Chapter 9.4](#))

Superior vena cava (VĒ-nă KĀ-vă): A large vein that carries deoxygenated blood from the upper body to the heart. ([Chapter 9.4](#))

Syncope (SING-kŏ-pē): A temporary loss of consciousness or fainting, often related to insufficient blood flow to the brain. ([Chapter 9.6](#))

Systole (SIS-tŏ-lē): The phase of the cardiac cycle in which the ventricles contract and eject blood. ([Chapter 9.5](#))

Tachycardia (tak-ē-KAR-dē-ă): A condition where the heart rate is faster than normal, over 100 bpm in adults. ([Chapter 9.5](#), [Chapter 9.6](#))

Tetralogy of Fallot (tět'ră-lŏ-jē ōf fă-LŌ): A serious congenital heart condition that includes four heart defects, leading to mixed blood flow and reduced oxygenation. ([Chapter 9.6](#))

Thrombolysis (thrŏm-BOL-ĭ-sīs): A treatment to dissolve dangerous clots in blood vessels, improve blood flow, and prevent damage to tissues and organs. ([Chapter 9.6](#))

Transesophageal echocardiogram (trăn-sē-sŏf-ă-JĒ-ăl ek-ŏ-KAR-dē-ŏ-gram): An imaging test that uses sound waves to create detailed pictures of the heart via the esophagus. ([Chapter 9.7](#))

Valve replacement (vălv rē-plās'-mĕnt): A surgical procedure to replace one or more of the heart's valves with either an artificial or a biological valve. ([Chapter 9.7](#))

Valvular heart disease (văl'-vyū-lăř hărt dĩ-zēz'): A condition in which one or more of the heart's valves do not function properly, affecting blood flow within the heart. ([Chapter 9.6](#))

Valvuloplasty (val-VŪ-lŏ-plas-tē): A procedure to repair a narrowed heart valve. ([Chapter 9.7](#))

Varicose veins (VAR-i-kōs VĀNZ): Enlarged, swollen, and twisting veins, often appearing blue or dark purple as a result of faulty valves in the veins. ([Chapter 9.6](#))

Veins (VĀNZ): Blood vessels that return blood to the heart, including the inferior vena cava and superior vena cava. ([Chapter 9.4](#))

Ventricular fibrillation (ven-TRĪK-yū-lăř fĭb-rĭ-LĀ-shŏn) (V Fib): A life-threatening heart rhythm where the ventricles quiver, instead of contracting, resulting in no cardiac output. ([Chapter 9.6](#))

Ventricular septal defect (ven-TRĪK-yū-lăř SĚP-tăł dĭ-FĚKT): A congenital heart defect where an opening exists in the septum between the left and right ventricles. ([Chapter 9.6](#))

Ventricular tachycardia (ven-TRĪK-yū-lăř tak-ĭ-KAR-dē-ă) (V Tach): A life-threatening rapid heart rhythm that originates from the ventricles. ([Chapter 9.6](#))

Venules (VEN-yoolz): Small veins that receive blood from capillaries and transport it to larger veins. ([Chapter 9.4](#))

PART X

CHAPTER 10 BLOOD TERMINOLOGY

10.1 Blood Introduction

Learning Objectives

- Apply the rules of medical language to build, analyze, spell, pronounce, abbreviate, and define terms as they relate to the blood
- Identify meanings of key word components of the blood
- Categorize diagnostic, therapeutic, procedural, or anatomic terms related to the blood
- Use terms related to the blood
- Use terms related to the diseases and disorders of the blood

Introduction


Hematology (hěm-ă-TÖL-ō-jē) is the study of blood, blood components, and blood-forming organs and their impact on an individual's health and well-being. The hematology system consists of the blood, the bone marrow, and accessory organs, including the spleen and the liver. Blood components consist of erythrocytes (red blood cells), leukocytes (white blood cells), thrombocytes (platelets), and clotting factors.

In the “Cardiovascular System Terminology” chapter, we learned how the heart serves as a pump to transport blood throughout the body via a network of arteries and veins. This chapter will discuss how components in the blood carry oxygen. The chapter will also discuss how the blood components participate in the immune response and how they help stop bleeding by forming a clot when there is an injury. Immune system function will be

further discussed in the “[Lymphatic & Immune Systems Terminology](#)” chapter.

This chapter will review common word components related to the hematology system to assist learners in analyzing, building, and defining medical terms. Other terms, whose definitions cannot be easily built from word components, will be described in context based on the anatomy and physiology of the hematology system and common diseases and disorders. Medical specialists, diagnostic tests, and procedures related to the hematology system will also be discussed.

View the following YouTube video¹ overview about blood:

 [Blood, Part 1 – True Blood: Crash Course Anatomy & Physiology #29](#)

1. CrashCourse. (2015, August 3). *Blood, Part 1 – True blood: Crash Course Anatomy & Physiology #29* [Video]. YouTube. All rights reserved.
<https://youtu.be/HQWlcSp9SIs?si=bCZ164OINAy4ESqc>

10.2 Word Components Related to Blood

This section will describe common word components related to the hematology system. These word components help build definitions for many medical terms. Other common prefixes are described in [Chapter 1.3](#), and common suffixes are described in [Chapter 1.5](#).

PREFIXES RELATED TO THE HEMATOLOGY SYSTEM

- **a-**: Absence of, without
- **endo-**: Within, in
- **epi-**: On, upon, over
- **hyper-**: Above, excessive
- **hypo-**: Below, deficient
- **inter-**: Between
- **pan-**: All, total
- **peri-**: Surrounding, around
- **poly-**: Many, much

WORD ROOTS WITH A COMBINING VOWEL RELATED TO THE HEMATOLOGY SYSTEM

- **chrom/o**: Color
- **coagul/o**: Clotting
- **cyt/o**: Cell
- **eosin/o**: Red, dawn, rosy
- **erythr/o**: Red
- **fibrin/o**: Fibrin
- **hem/o**: Blood
- **hemat/o**: Blood
- **hepat/o**: Liver
- **is/o**: Same, equal
- **isch/o**: Deficiency, blockage
- **leuk/o**: White
- **lymph/o**: Lymph, lymph tissue
- **mon/o**: One, single
- **myel/o**: Bone marrow, spinal cord
- **neutr/o**: Neutral; neither base nor acid
- **phag/o**: Eat, swallow
- **phleb/o**: Vein
- **plasm/o**: Plasma
- **poikil/o**: Varied, irregular
- **therm/o**: Heat
- **thromb/o**: Clot
- **splen/o**: Spleen
- **ven/o**: Vein

SUFFIXES RELATED TO THE HEMATOLOGY

SYSTEM

- **-ac:** Pertaining to
- **-apheresis:** Removal, carrying away
- **-ar:** Pertaining to
- **-blast:** Immature cell, embryonic
- **-centesis:** Surgical puncture to aspirate fluid
- **-cyte:** Cell
- **-cytosis:** Abnormal condition of cells (increase in cells)
- **-ectomy:** Excision, surgical removal
- **-emia:** In the blood
- **-genic:** Producing, originating, causing
- **-globin:** Protein
- **-ia:** Condition of, diseased state, abnormal state
- **-ic:** Pertaining to
- **-ism:** State of
- **-itis:** Inflammation
- **-logist:** Specialist who studies and treats
- **-logy:** Study of
- **-lysis:** Loosening, dissolution, separating
- **-megaly:** Enlarged, enlargement
- **-oid:** Resembling
- **-oma:** Tumor
- **-osis:** Abnormal condition
- **-ous:** Pertaining to
- **-pathy:** Disease
- **-penia:** Abnormal reduction in number
- **-pexy:** Surgical fixation, suspension
- **-phage:** Eat, swallow
- **-plasty:** Surgical repair
- **-poiesis:** Formation
- **-rrhage** or **-rrhagia:** Excessive flow
- **-stasis:** Stop, stopping, controlling

- **-tomy:** Cut into, incision
- **-us:** No meaning

10.3 Examples of Blood Terms Easily Defined By Their Word Components

Here are examples of common medical terms related to the hematology system that can be easily defined by breaking the terms into their word components.

Hematologist

1. Break down the medical term into word components:
Hemat/o/logist
2. Label the word components: **Hemat** = WR; **o** = CV; **logist** = S
3. Define the word components: **Hemat** = blood; **logist** = specialist who studies and treats
4. Create a final definition of the medical term: **A specialist who studies and treats diseases of the blood**

Hemostasis

1. Break down the medical term into word components:
Hem/o/stasis
2. Label the word components: **Hem** = WR; **o** = CV; **stasis** = S

3. Define the word components: **Hem** = blood; **stasis** = stopping
4. Create a final definition of the medical term: **Stopping blood (bleeding)**

Leukocytopenia

1. Break down the medical term into word components:
Leuk/o/cyt/o/penia
2. Label the word components: **Leuk** = WR; **o** = CV; **cyt** = WR; **o** = CV; **penia** = S
3. Define the word components: **Leuk** = white (blood cell); **cyt** = cell; **penia** = abnormal reduction in number
4. Create a final definition of the medical term: **Abnormal reduction of white blood cells**



Interactive Learning Activity: Practice defining and pronouncing terms related to blood by breaking them into word parts.



An interactive HSP element has been excluded from this version of the text. You can view it online here:

<https://wtcs.pressbooks.pub/medterm/?p=4383#h5p-177>

▶ You can also print these flashcard activities as a [Chapter 10](#)

▶ [Student Companion Worksheet](#) and check your answers with this [Answer Key](#).

10.4 Anatomy of the Hematology System

The hematology system consists of the blood and the bone marrow that create the cellular elements of the blood, as well as accessory organs, including the spleen and the liver.

BLOOD

Blood is made of formed elements (cells) and plasma. The formed elements include **erythrocytes** (ě-r-ĭ-thrō-sĭtz), **leukocytes** (LOO-kō-sĭtz), and **thrombocytes** (THRŌM-bō-sĭtz), all suspended in a liquid called plasma. In diagnostic reports, erythrocytes are referred to as red blood cells (RBCs), leukocytes are referred to as white blood cells (WBCs), and thrombocytes are referred to as platelets.

When a blood sample is taken from a patient and sent to the laboratory for analysis, the sample is centrifuged to separate the components of blood from one another so they can be measured. As the heaviest elements in blood, red blood cells (RBCs) settle at the very bottom of the tube. RBCs make up about 45% of the volume of the blood, measured in a blood test called hematocrit. **Hematocrit** (hē-MAT-ō-krit) (**HCT**) is the ratio of the volume of red blood cells to the total volume of blood. The normal hematocrit for men is 40 to 54%, and for women it is 36 to 48%.¹

1. Billett, H. H. (1990). Hemoglobin and hematocrit. In Walker, H. K., Hall, W. D., & Hurst, J. W. (Eds), *Clinical Methods: The history, physical, and laboratory*

Above the RBC layer in a centrifuged sample is a layer of white blood cells (WBCs) and platelets, which together make up less than 1% of the sample of whole blood. Above this buffy layer is **plasma** (PLAZ-mă), the liquid part of blood. Plasma is a pale, straw-colored fluid that constitutes 55% of a blood sample. Plasma is mostly water with dissolved proteins, including albumin, immunoglobulins, and clotting factors. It also contains nutrients, electrolytes, and cellular wastes. Plasma suspends RBCs, WBCs, and platelets, enabling them to circulate throughout the body within the cardiovascular system.² See Figure 10.1³ for an illustration of the composition of blood in a blood sample.

examinations (3rd ed., Chapter 151). Butterworths.

<https://www.ncbi.nlm.nih.gov/books/NBK259/>

2. This work is a derivative of *Anatomy & Physiology* by [OpenStax](#) and is licensed under [CC BY 4.0](#). Access for free at <https://openstax.org/details/books/anatomy-and-physiology-2e>
3. “1913_ABO_Blood_Groups.jpg” by [Alan Sved](#) is licensed under [CC BY-SA 4.0](#).

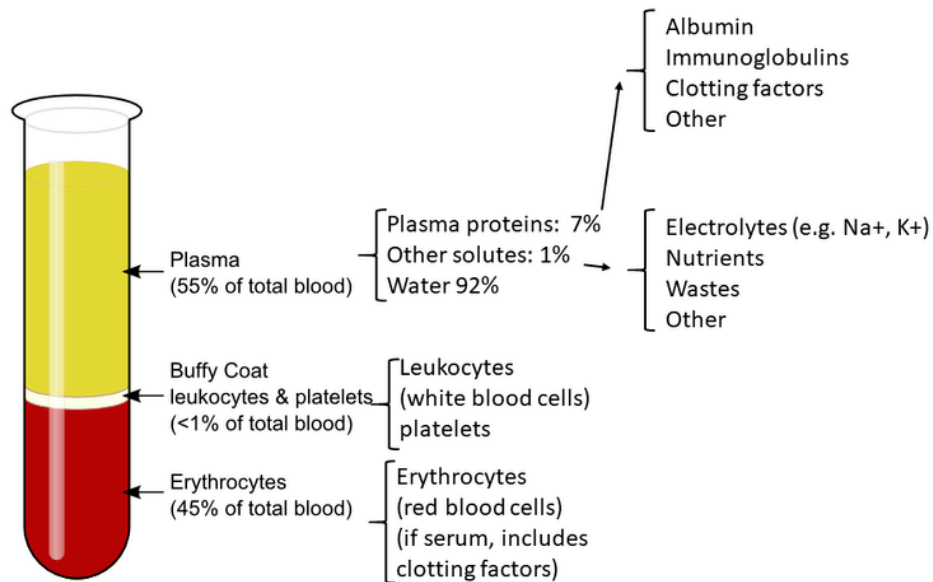


Figure 10.1 Composition of a Blood Sample

Phlebotomy (flĕ-BOT-ŏ-mĕ) refers to the opening or puncture of a vein in order to withdraw a blood sample for analysis. **Hemolysis** (hĕ-MOL-ĭ-sĭs) refers to the breaking down of red blood cells due to the mishandling of blood samples during routine blood collection and transport.

Bone Marrow

Formation of the formed elements of the blood takes place primarily in the red bone marrow. **Bone marrow** (bŏn MĀR-ŏ) is the soft tissue inside bones that produces red blood cells (RBC), white blood cells (WBC), and platelets. Red bone marrow is primarily located in flat bones such as the sternum, skull, and pelvis.⁴

4. This work is a derivative of [Anatomy and Physiology](#) by [OpenStax](#) licensed

In the red bone marrow, stem cells are undifferentiated and have the remarkable capacity to become any type of cell. As these stem cells differentiate, they require specific growth factors for specialization. For example, **erythropoietin** (ĕr-ĭ-thrō-poi-Ē-tin) (**EPO**) is a hormone that stimulates the production of erythrocytes (red blood cells) that is produced by the kidneys.⁵ During a stem cell transplant, donated healthy stem cells are provided to a patient and, if successful, take over production of their blood cells in their bone marrow. Read more about stem cell transplants in the [“Medical Specialists, Diagnostic Testing, and Procedures Related to Blood.”](#)

Red Blood Cells

Red blood cells (rĕd blŭd sĕls) (**RBCs**) transport oxygen and carbon dioxide between tissues and the lungs. RBCs are packed with **hemoglobin** (HĒM-ō-glō-bin) (**Hgb**), a protein molecule that carries oxygen. For this reason, deficiency in RBCs results in symptoms related to decreased oxygenation of the body's tissues and organs.⁶ See Figure 10.2⁷ for an illustration of RBCs containing hemoglobin that carries oxygen molecules.

under [CC BY 4.0](#). Access for free at <https://openstax.org/books/anatomy-and-physiology/pages/1-introduction>

5. This work is a derivative of Anatomy & Physiology by [OpenStax](#) and is licensed under [CC BY 4.0](#). Access for free at <https://openstax.org/details/books/anatomy-and-physiology-2e>
6. This work is a derivative of Anatomy & Physiology by [OpenStax](#) and is licensed under [CC BY 4.0](#). Access for free at <https://openstax.org/details/books/anatomy-and-physiology-2e>
7. [“Figure_39_04_01.jpg”](#) by CNX OpenStax is licensed under [CC BY 4.0](#)

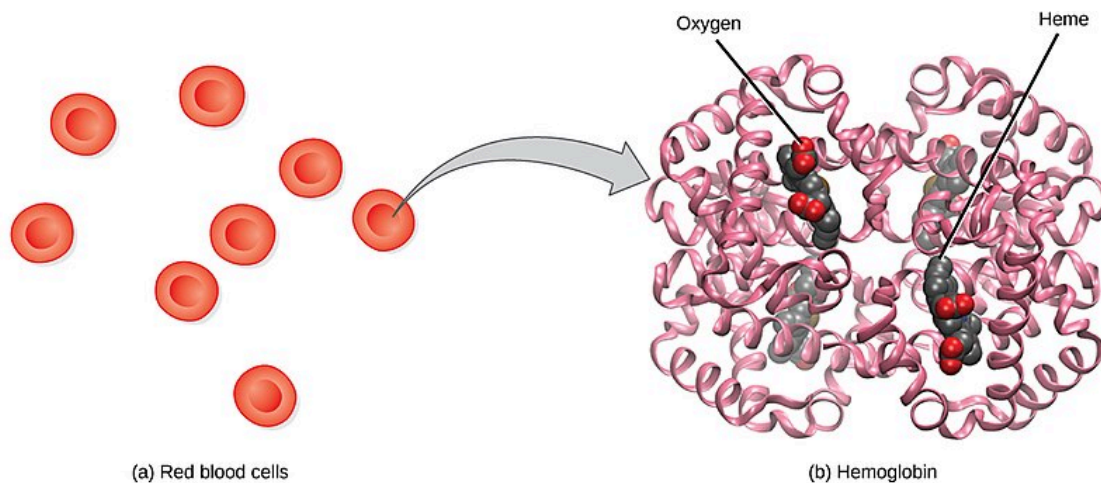


Figure 10.2 Red Blood Cells

Production of RBCs in the red bone marrow occurs at the staggering rate of more than 2 million cells per second. For this production to occur, raw materials, including iron, folic acid, and B12, must be present in adequate amounts. RBCs live only 120 days on average and must be continually replaced.⁸

Old RBCs and hemoglobin are broken down by white blood cells in a process called phagocytosis. When hemoglobin breaks down, a yellow substance called **bilirubin** (bil-ĭ-ROO-bin) is released. If the body cannot adequately metabolize bilirubin, a symptomatic yellow discoloration called jaundice occurs in the skin, mucus membranes, and eyes.⁹

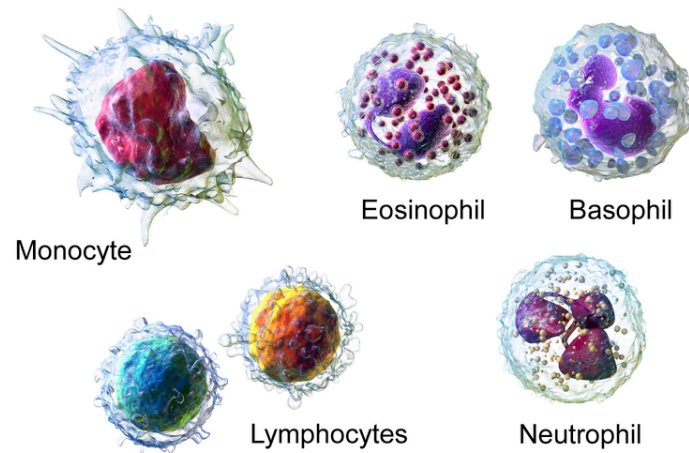
White Blood Cells

White blood cells (wīt blūd sēls) (**WBCs**), also called leukocytes, provide

8. This work is a derivative of [Anatomy and Physiology](#) by [OpenStax](#) licensed under [CC BY 4.0](#). Access for free at <https://openstax.org/books/anatomy-and-physiology/pages/1-introduction>

9. This work is a derivative of [StatPearls](#) by Kalakonda, Jenkins, & John and is licensed under [CC BY 4.0](#)

immune functions and defenses against disease. WBCs protect the body against invading microorganisms, as well as its own cells that have mutated DNA, and they also clean up cellular debris. There are five main types of WBCs called **neutrophils** (NŪ-trō-filz), **lymphocytes** (LĪM-fō-sītz), **monocytes** (MON-ō-sītz), **eosinophils** (ē-ō-SIN-ō-filz), and **basophils** (BAS-ō-filz).¹⁰ See Figure 10.3¹¹ for an illustration of these types of WBCs.



White Blood Cells

Figure 10.3 Types of White Blood Cells

Table 10.4 summarizes the main functions of the different types of WBCs.

10. This work is a derivative of Anatomy & Physiology by [OpenStax](https://openstax.org/details/books/anatomy-and-physiology-2e) and is licensed under [CC BY 4.0](https://creativecommons.org/licenses/by/4.0/). Access for free at <https://openstax.org/details/books/anatomy-and-physiology-2e>
11. “[Blausen_0909_WhiteBloodCells.png](#)” by Blausen.com staff (2014). “[Medical gallery of Blausen Medical 2014.](#)” *WikiJournal of Medicine* is licensed under [CC BY 3.0](https://creativecommons.org/licenses/by/3.0/)

Table 10.4. Types of WBCs and Functions¹²

Type of WBC	Percentages in Total WBC Count	Function
Neutrophils	40 -70%	Engulf and destroy bacteria during acute bacterial infections and inflammation.
Lymphocytes	20-45%	Important role in adaptive immunity with the production of antibodies.
Monocytes	2-10%	Transformed into macrophages in acute infections to clear debris and pathogens.
Eosinophils	1-6%	Defend against parasites and cause allergic reactions by releasing histamine and other chemicals.
Basophils	0.5-1%	Release histamine and other inflammatory mediators during an allergic reaction.

Platelets

Platelets (PLĀT-lītz), also called thrombocytes, help form a clot when there is bleeding. Platelets serve a critical function in **hemostasis** (hē-mō-STĀ-sīs), the process by which the body seals a broken blood vessel and prevents further blood loss. During hemostasis, platelets become activated and create a

12. American Society of Hematology. (n.d.). *Blood basics*.

<https://www.hematology.org/education/patients/blood-basics>

platelet plug.¹³ See Figure 10.4¹⁴ for an illustration of platelets and activated platelets. Hemostasis and blood clot formation are further discussed in the [“Physiology of the Hematology System.”](#)

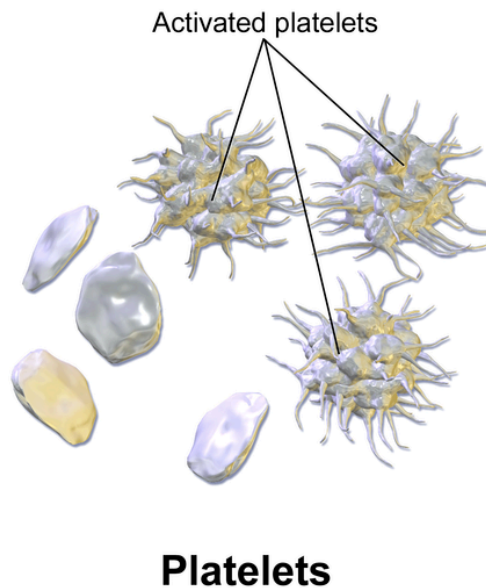


Figure 10.4 Platelets and Activated Platelets

¹³. This work is a derivative of Anatomy & Physiology by [OpenStax](#) and is licensed under [CC BY 4.0](#). Access for free at <https://openstax.org/details/books/anatomy-and-physiology-2e>

¹⁴. “[Blausen_0740_Platelets.png](#)” by Blausen.com staff (2014). “[Medical gallery of Blausen Medical 2014.](#)” *WikiJournal of Medicine* is licensed under [CC BY 3.0](#)

ACCESSORY ORGANS

The spleen and liver are accessory organs for blood production and clotting regulation.

Spleen

The **spleen** (splēn) produces and stores WBCs, filters and stores RBCs and platelets, and plays a role in the filtration and destruction of old RBCs. There are two types of tissue in the spleen: white pulp and red pulp. White pulp, the lymphatic tissue of the spleen, produces some WBCs, although most WBCs are produced in the red bone marrow. Red pulp serves as a storage site for RBCs and platelets. The spleen also filters antigens and plays a role in the destruction of old RBCs and the breakdown of hemoglobin.¹⁵ See Figure 10.5¹⁶ for an illustration of the location of the spleen.

15. This work is a derivative of [StatPearls](#) by Kapila, Wehrle, & Tuma and is licensed under [CC BY 4.0](#)

16. “[Diagram showing the position of the spleen CRUK_417.svg](#)” by [Cancer Research UK uploader](#) is licensed under [CC BY-SA 4.0](#)

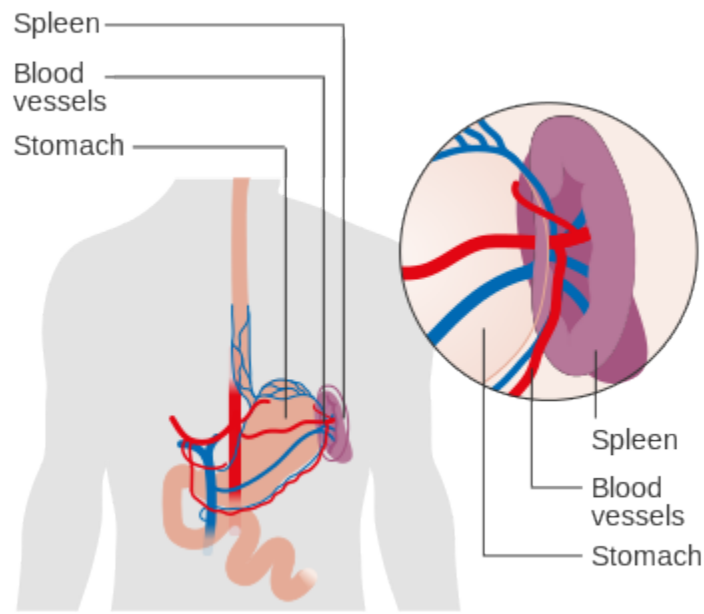


Figure 10.5 Spleen

Because the spleen serves as a reservoir for blood, injury to the spleen can result in excessive, life-threatening bleeding called **hemorrhage** (HEM-ŏ-rāj). For this reason, patients who have experienced blunt abdominal trauma undergo rapid diagnostic testing to check for and rapidly treat splenic damage and prevent hemorrhage.

Enlargement of the spleen, called **splenomegaly** (sple-nō-MĒG-ă-lē), can occur due to a variety of reasons, such as systemic infection, sickle cell disease, or cancer. Patients who undergo **splenectomy** (splē-NEK-tŏ-mē), the removal of the spleen, experience reduced immune function and have an increased risk of infection.¹⁷

¹⁷. This work is a derivative of [StatPearls](#) by Kapila, Wehrle, & Tuma and is licensed under [CC BY 4.0](#)

Liver

The **liver** (LIV-ěr) serves as a storage site for blood and blood cells. It also produces prothrombin and other clotting factors. See Figure 10.6¹⁸ for an illustration of the location of the liver.

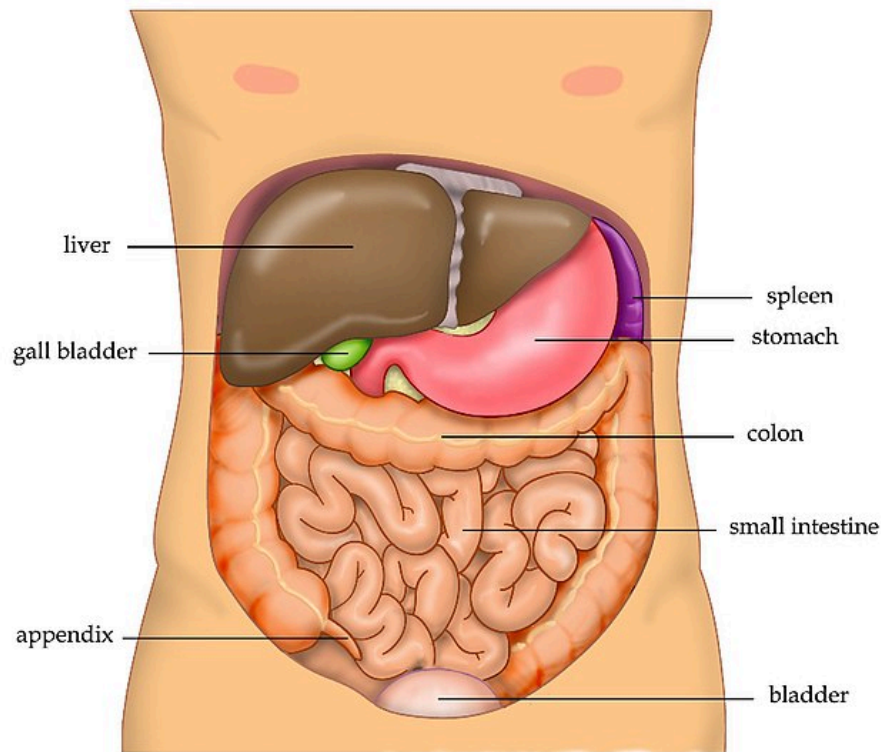


Figure 10.6 Liver

The liver also plays a significant role in the breakdown of hemoglobin. The liver receives bilirubin from the breakdown of RBCs, where it undergoes a chemical change called conjugation so it can be filtered and excreted by the kidneys. If the liver becomes impaired and cannot adequately metabolize

18. "[Anatomy_Abdomen_Tiesworks.jpg](#)" by [Tvanbr](#) is licensed in the [Public Domain](#).

bilirubin, jaundice occurs.¹⁹ **Jaundice** (JAWN-dis) refers to yellowish discoloration of the skin and eyes.

Enlargement of the liver is called **hepatomegaly** (hep-a-tō-MĒG-ă-lē). Hepatomegaly can be caused by liver disease, cancer, and excess alcohol intake.

BLOOD TYPES

There are four blood types called A, B, AB, and O. These blood types are genetically determined for every individual. Each type is determined by the presence or absence of specific antigens called “A” or “B” on the individual’s red blood cells.²⁰

Based on the presence or lack of A or B antigens on an individual’s red blood cells, antibodies are present in their blood that recognize these antigens as foreign and stimulate their immune response. For example, an individual with Type A blood has an A antigen on their RBC but has antibodies to the B antigen in their blood. For this reason, if an individual requires a blood transfusion, it is vital for the donated blood to be compatible with their blood type or a life-threatening reaction will occur.²¹ A **blood transfusion** (blūd tran-SFŪ-zhǒn) is a procedure that enables the transfer of

19. This work is a derivative of [StatPearls](#) by Kalra, Yetiskul, Wehrle, & Tuma and is licensed under [CC BY 4.0](#)

20. This work is a derivative of [Anatomy and Physiology](#) by [OpenStax](#) licensed under [CC BY 4.0](#). Access for free at <https://openstax.org/books/anatomy-and-physiology/pages/1-introduction>

21. This work is a derivative of [Anatomy and Physiology](#) by [OpenStax](#) licensed under [CC BY 4.0](#). Access for free at <https://openstax.org/books/anatomy-and-physiology/pages/1-introduction>

blood products from one person to another. Figure 10.7²² shows the different blood types and associated antigens and antibodies, as well as their compatible blood types.

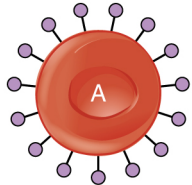
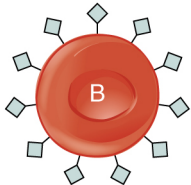
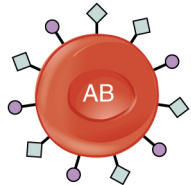







	Blood Type			
	A	B	AB	O
Red Blood Cell Type				
Antibodies in Plasma	 Anti-B	 Anti-A	None	 Anti-A and Anti-B
Antigens in Red blood Cell	 A antigen	 B antigen	 A and B antigens	None
Blood Types Compatible in an Emergency	A, O	B, O	A, B, AB, O (AB ⁺ is the universal recipient)	O (O is the universal donor)

Figure 10.7 Blood Types

Rh Blood Group

In addition to the A, B, AB, or O blood type, individuals may have another antigen on their red blood cells called **Rh factor** (Ār āch FAK-tör). Individuals who have the antigen on their RBCs are described as **Rh positive** (Ār-āch

22. “1913_ABO_Blood_Groups.jpg” by OpenStax College is licensed under [CC BY 3.0](#)

PŌZ-ĭ-tĭv) (**Rh+**), and those who lack the antigen are described as **Rh negative** (Ār-āch NĚG-ă-tĭv) (**Rh-**). When identifying a patient's blood type, the Rh factor is designated by adding the word positive or negative to the ABO type. For example, A positive (A+) means A blood type with the Rh antigen present, and AB negative (AB-) means AB blood type without the Rh antigen. Individuals receiving blood transfusions must receive donated blood that matches their Rh type, or a serious, life-threatening reaction will occur.²³

During pregnancy, the fetus can be significantly affected if the mother has a different Rh factor. If an Rh- mother conceives a Rh+ baby, her Rh antibodies can cross the placenta and destroy the fetal RBCs. This condition is known as **hemolytic disease of the newborn** (hē-mō-LĭT-ik dĩ-zēz əv thə NŪ-bôrn) and can be so severe that without treatment the fetus may die in the womb or shortly after birth. A medication known as **RhoGAM** (RŌ-găm) can temporarily prevent the development of Rh antibodies in an Rh- mother, thereby averting this potentially serious disease for the fetus if it is Rh+. RhoGAM is administered to Rh- mothers during weeks 26–28 of pregnancy and within 72 hours following birth.²⁴

23. This work is a derivative of Anatomy & Physiology by [OpenStax](#) and is licensed under [CC BY 4.0](#). Access for free at <https://openstax.org/details/books/anatomy-and-physiology-2e>

24. This work is a derivative of Anatomy & Physiology by [OpenStax](#) and is licensed under [CC BY 4.0](#). Access for free at <https://openstax.org/details/books/anatomy-and-physiology-2e>

10.5 Physiology of the Hematology System

FUNCTIONS OF BLOOD

The primary functions of blood are the transportation of oxygen, carbon dioxide, nutrients, and hormones, as well as moving cellular wastes so they can be eliminated from the body. Other functions of blood include thermoregulation, defense against infection, and hemostasis.¹

Transportation

The blood transports oxygen, carbon dioxide, nutrients, electrolytes, and hormones. Oxygen from the air you breathe diffuses into the blood in the lungs and then moves to the heart where it is pumped out to the tissues of the body. From the tissues, blood picks up carbon dioxide and moves it to the lungs for removal by exhalation.

Nutrients from the foods you eat are absorbed in the digestive tract. Most of these travel in the bloodstream to the liver, where they are metabolized and released back into the bloodstream for delivery to body cells. Various waste products are also picked up from the cells in the blood and then transported to the kidneys and liver for excretion from the body in the form of urine or bile.

Finally, endocrine glands scattered throughout the body release hormones

1. This work is a derivative of Anatomy & Physiology by [OpenStax](https://openstax.org/details/books/anatomy-and-physiology-2e) and is licensed under [CC BY 4.0](https://creativecommons.org/licenses/by/4.0/). Access for free at <https://openstax.org/details/books/anatomy-and-physiology-2e>

into the bloodstream, where they are transported to distant target cells they affect.

Thermoregulation

Body temperature is regulated via a negative-feedback loop referred to as thermoregulation. For example, if you exercise on a hot day, your rising core body temperature triggers several mechanisms, including the increased transportation of blood from your core to the surface of your body, which is typically cooler. As blood passes through the vessels of the skin, heat is dissipated to the environment, and the blood returning to your core is cooler. In contrast, on a cold day, blood is diverted away from the skin to maintain a warm core. In extreme cold, if the extremities are not protected adequately, this process can result in frostbite.

Defense Against Infection

Many types of WBCs protect the body from infection by microorganisms that enter the body. Other WBCs seek out and destroy internal threats, such as cells with mutated DNA that could multiply to become cancerous. Read more about the function of WBCs in the “[Lymphatic and Immune Systems Terminology](#)” chapter.

Hemostasis

When damage occurs to blood vessels that results in bleeding, platelets and clotting factors form a clot to stop the bleeding, referred to as **hemostasis** (hē-mō-STĀ-sīs). There are three steps to the hemostasis process: vascular spasm called vasoconstriction, the formation of a platelet plug, and blood clotting called **coagulation** (kō-ag-yū-LĀ-shōn). Failure of any of these steps will result in hemorrhage. Figure 10.8² summarizes the steps of hemostasis.

2. “[1909_Blood_Clotting.jpg](#)” by OpenStax College is licensed under [CC BY 3.0](#)

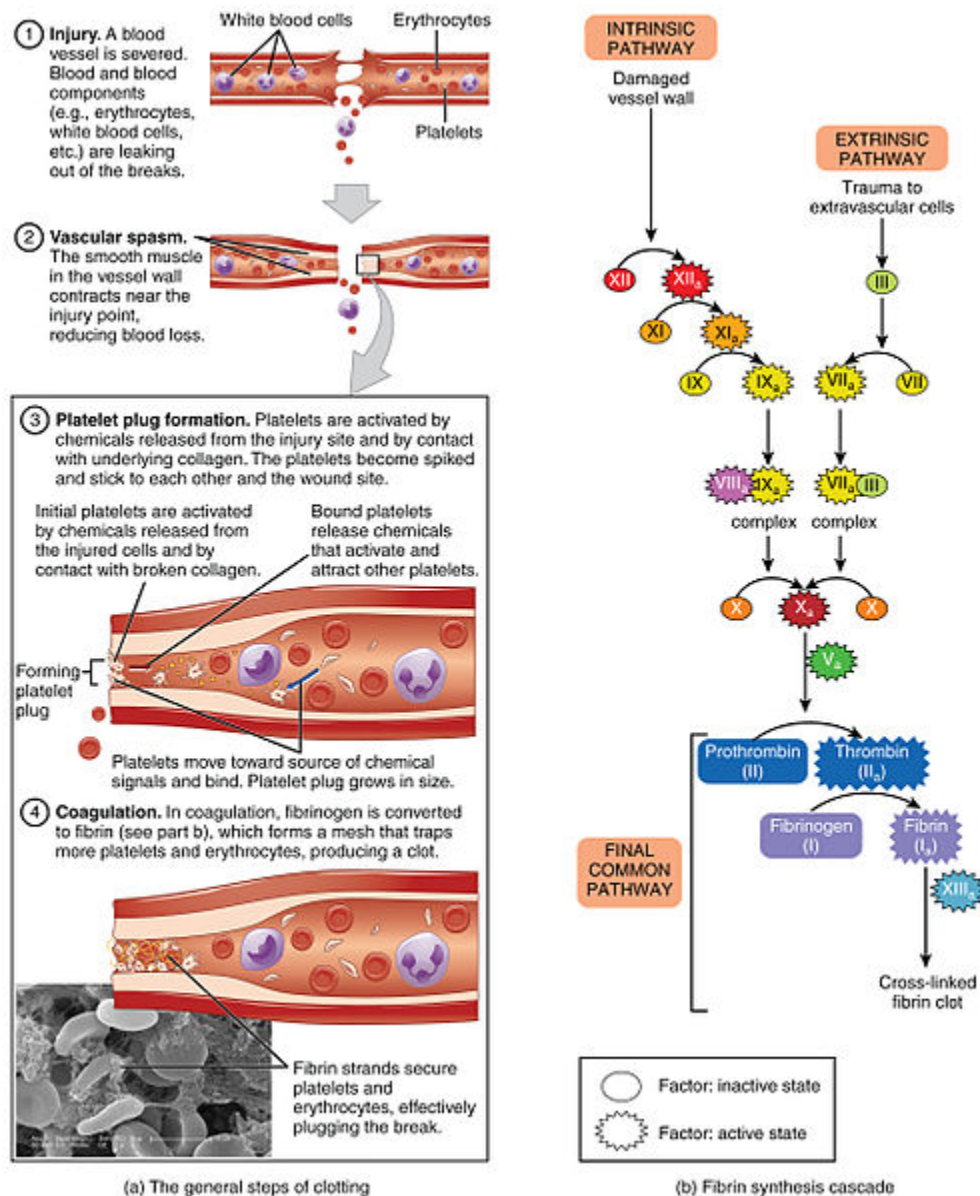


Figure 10.8 Hemostasis

During hemostasis, a protein called **fibrin** (FĪ-brin) is produced to form a blood clot.

Fibrinolysis (fī-brĭ-NŌL-ĭ-sĭs) is the process in which a clot is degraded in a healing vessel. An **anticoagulant** (an-tĭ-kō-AG-yū-lănt) is a substance or medication that prevents coagulation. Examples of commonly prescribed anticoagulant medications are warfarin and heparin.

Three commonly performed blood tests related to blood clotting are **prothrombin time** (PRŌ-thrŏm-bĭn tĭm) (**PT**), **international normalized ratio**

(ĩn-tě̃r-NASH-ũ-năl NÔR-mă-lĩzd RĀ-shiō) (**INR**), and **partial thromboplastin time** (păr-shăl thrŏm-bō-PLAS-tĩn tĩm) (**PTT**). PT measures the time it takes for plasma to clot. INR is a standardized measurement of PT, so a normal reference range can be used for all individuals. PTT measures a specific group of clotting factors. These tests may be performed to diagnose clotting disorders or monitor patients who are receiving anticoagulants.³

3. MedlinePlus [Internet]. Bethesda (MD): National Library of Medicine (US); [updated 2022, Sep. 21]. Prothrombin time test and INR (PT/INR); [cited 2023, Nov. 5]. <https://medlineplus.gov/lab-tests/prothrombin-time-test-and-inr-ptinr/>

10.6 Diseases and Disorders of the Blood

Anemia (ā-NEĒ-mē-ă) is a blood disorder in which there is a deficiency of red cells and/or hemoglobin. Anemia is diagnosed when a blood test shows a hemoglobin value of less than 13.5 gm/dL in a man or less than 12.0 gm/dL in a woman. The lack of RBCs and hemoglobin causes a decreased amount of oxygen to be delivered to body tissues, resulting in commonly occurring symptoms of fatigue, weakness, shortness of breath, palpitations, and pale skin. See Figure 10.9¹ for an illustration of common symptoms of anemia.

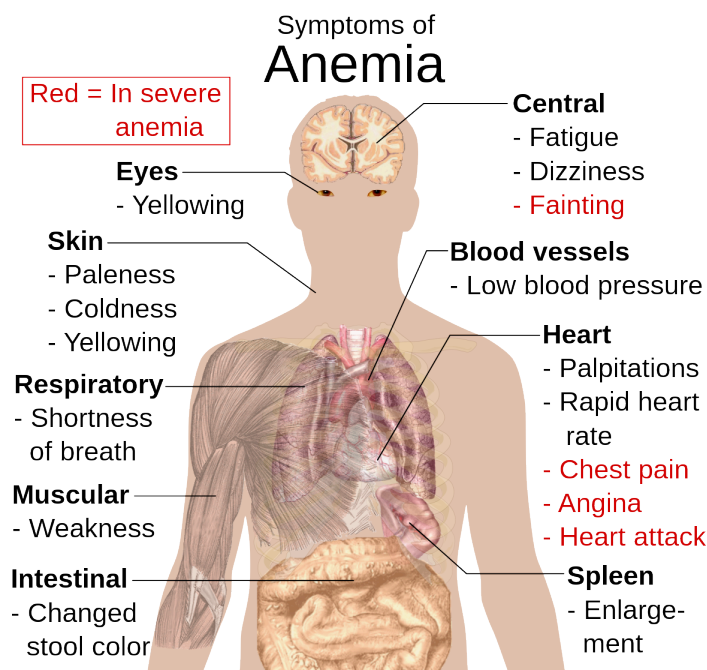


Figure 10.9 Anemia Symptoms

1. "Symptoms_of_anemia.svg.png" by Mikael Häggström is licensed in the Public Domain

There are three basic causes of anemia: blood loss, decreased RBC production, and excessive destruction of RBCs. In addition to these causes, various diseases and cancers can also cause anemia.²

Anemia from Blood Loss

Anemia from blood loss can result from excessive bleeding from wounds or other lesions, such as ulcers and gastrointestinal cancer. Excessive menstruation and blood loss during childbirth can also cause this type of anemia.

Faulty or Decreased RBC Production

Iron deficiency anemia (īrŏn dē-Fĭ-shĕn-sē ā-NĒ-mē-ă) is the most common type of anemia. It is caused by a lack of dietary iron needed for the sufficient production of hemoglobin.

Sickle cell anemia (SĭK-l sĕl ā-NĒ-mē-ă) is genetic disorder that causes red blood cells to assume a sickle (i.e., crescent) shape that can block blood flow and cause serious problems in organs throughout the body. See Figure 10.10³ for an image of a sickled red blood cell.

2. American Society of Hematology. (n.d.). *Anemia*. <https://www.hematology.org/education/patients/anemia>

3. “[Eritrociti.jpg](#)” by EM Unit, UCL Medical School, Royal Free Campus, Wellcome Images is licensed under [CC BY 4.0](#)

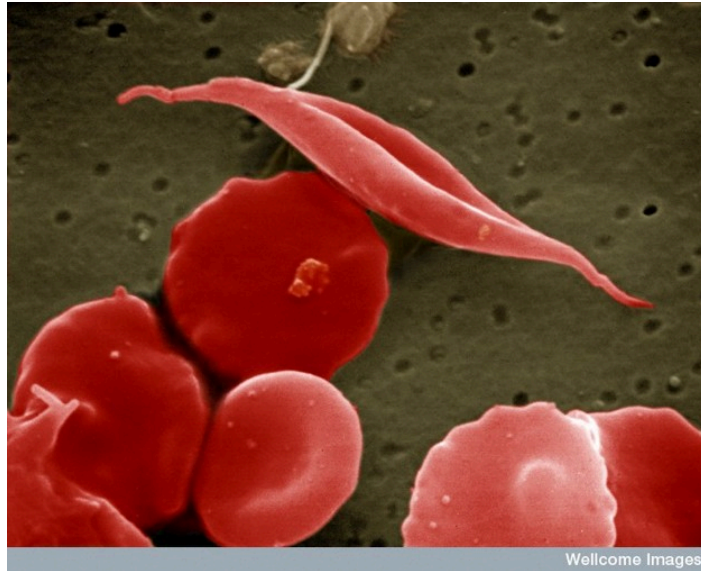

Figure 10.10 Sickled Red Blood Cell in Sickle Cell Anemia

Aplastic anemia (ā-PLAS-tĭk ā-NĒ-mē-ă) is a bone marrow condition causing an insufficient production of RBCs. This condition can be inherited, or it can be caused by radiation, medication, chemotherapy, or infection.

Other Types of Anemia

Megaloblastic anemia (mě-gŭh-lō-plă-stĭk ā-NĒ-mē-ă) involves a deficiency of vitamin B12 and/or folate, often due to inadequate dietary intake.

Pernicious anemia (pĕr-nĭsh-ē-ŭs ā-NĒ-mē-ă) is caused by poor absorption of vitamin B12 in the gastrointestinal tract. **Thalassemia** (thal-ă-SĒM-ē-ă) is an inherited condition typically occurring in individuals from the Middle East, the Mediterranean, Africa, and Southeast Asia in which maturation of the RBCs does not proceed normally. **Pancytopenia** (pan-sĭ-tō-PĒN-ē-ă) is reduction of all types of blood components, including red and white blood cells and platelets.⁴

4. This work is a derivative of Anatomy & Physiology by [OpenStax](#) and is licensed

HEMATOMA

A **hematoma** (hēm-ă-TŌ-mă) is a collection (or pooling) of blood outside the blood vessel caused by an injury. Trauma is the primary cause of a hematoma. Trauma can be the result of a car accident, fall, broken bones, gunshot wound, or head injury. People with bleeding disorders or those taking anticoagulant medication are at higher risk for developing hematomas from injuries. Symptoms of a hematoma include redness, warmth, swelling, inflammation, and pain and require medical treatment.⁵

Hematomas differ from bruises. A bruise, also known as a **contusion** (kon-TU-zhun), occurs when the small veins and capillaries under the skin break, releasing blood into the surrounding tissue. Bruises are dark blue or purple tender patches that appear on the skin within a few hours after injury.⁶

HEMOPHILIA

Hemophilia (hē-mō-FĒL-ē-ă) is a genetic disorder in which blood doesn't clot normally due to deficient or abnormal clotting factors. Patients with

under CC BY 4.0. Access for free at <https://openstax.org/details/books/anatomy-and-physiology-2e>

5. MercyHealth. (n.d.). *Bruise or hematoma*. <https://www.mercy.com/health-care-services/primary-care-family-medicine/conditions/bruise-hematoma>

6. MercyHealth. (n.d.). *Bruise or hematoma*. <https://www.mercy.com/health-care-services/primary-care-family-medicine/conditions/bruise-hematoma>

hemophilia can bleed excessively and hemorrhage from even minor internal and external injuries.⁷

HEMORRHAGE

Hemorrhage (HEM-ŏ-rāj) is excessive bleeding that cannot be controlled by hemostasis. A hemorrhage is a medical emergency.

LEUKEMIA

Leukemia (lū-KĒM-ē-ă) is cancer of the bone marrow, the body's blood-forming tissues. It includes an abundance of nonfunctional leukocytes (i.e., white blood cells), reducing the individual's ability to fight off infection.⁸ Leukemia is diagnosed with a bone marrow biopsy. Treatment may include chemotherapy and a bone marrow/stem cell transplant.

7. This work is a derivative of Anatomy & Physiology by [OpenStax](#) and is licensed under [CC BY 4.0](#). Access for free at <https://openstax.org/details/books/anatomy-and-physiology-2e>

8. This work is a derivative of Anatomy & Physiology by [OpenStax](#) and is licensed under [CC BY 4.0](#). Access for free at <https://openstax.org/details/books/anatomy-and-physiology-2e>

LEUKOCYTOSIS

Leukocytosis (lū-kō-sī-TŌ-sīs) is excessive leukocyte (white blood cell) production. Although leukocyte counts are high, the cells themselves are often nonfunctional, leaving the individual at increased risk for infection.⁹

LEUKOPENIA

Leukopenia (lū-kō-PĒN-ē-ă) is a condition in which too few leukocytes (white blood cells) are produced, which impact the individual's ability to fight off disease.¹⁰

LYMPHOMA

Lymphoma (lim-FŌ-mă) is a type of cancer in which masses of malignant lymphocytes (white blood cells) collect in lymph nodes, the spleen, the liver, and other tissues. As in leukemia, the malignant leukocytes do not function properly, and the patient is vulnerable to infection. Two main types of lymphoma are Hodgkin lymphoma and non-Hodgkin lymphoma. Hodgkin

9. This work is a derivative of Anatomy & Physiology by [OpenStax](#) and is licensed under [CC BY 4.0](#). Access for free at <https://openstax.org/details/books/anatomy-and-physiology-2e>

10. This work is a derivative of Anatomy & Physiology by [OpenStax](#) and is licensed under [CC BY 4.0](#). Access for free at <https://openstax.org/details/books/anatomy-and-physiology-2e>

lymphoma progresses slowly and responds well to treatment if found early. Non-Hodgkin lymphoma can progress quickly and may require aggressive treatment. Symptoms of lymphoma include swollen lymph nodes, fever, drenching night sweats, weight loss, and fatigue. Treatment may include chemotherapy, radiation therapy, and immunotherapy.¹¹

POLYCYTHEMIA

Polycythemia (pol-ē-sī-THĒM-ē-ă) refers to an elevated RBC count. A mild form of polycythemia is normal for people living at high altitudes because their bodies create a greater number of red blood cells to carry oxygen due to decreased pressure of oxygen at high altitudes. Some elite athletes even train at high elevations specifically to induce this phenomenon. However, a bone marrow disease called **polycythemia vera** (pol-ē-sī-THĒM-ē-ă vee-ruh) causes an excessive production of immature RBCs and other blood components, increasing the viscosity of blood. **Viscosity** (vīs-KOS-ĭ-tē) refers to the state of being thick, sticky, and easily coagulable.¹²

11. Medline Plus. (2023). *Hodgkin lymphoma*. <https://medlineplus.gov/hodgkinlymphoma.html>

12. This work is a derivative of Anatomy & Physiology by OpenStax and is licensed under CC BY 4.0. Access for free at <https://openstax.org/details/books/anatomy-and-physiology-2e>

THROMBOSIS, THROMBUS, AND EMBOLUS

Thrombosis (thrŏm-BŌ-sīs) is the formation of a thrombus. A **thrombus** (THROM-būs) is a collection of platelets, red blood cells, and white blood cells trapped within a mass of fibrin strands, commonly referred to as a “blood clot.” While the formation of a clot is a normal step in hemostasis, the development of a thrombus can cause decreased blood flow in a blood vessel or a life-threatening obstruction of a blood vessel in the heart or brain.¹³

When a portion of a thrombus breaks free from the vessel wall and travels through the bloodstream, it is referred to as an **embolus** (ĒM-bŏ-lūs). An embolus that is carried through the bloodstream can be large enough to block a vessel critical to a major organ. When it becomes trapped, an embolus is called an **embolism** (ĒM-bŏ-līzm). In the heart, brain, or lungs, an embolism can cause a life-threatening heart attack, stroke, or pulmonary embolism.¹⁴

Thrombolysis (thrŏm-BŎL-ī-sīs) refers to the dissolution of a clot. Medications like tissue plasminogen activator (tPA), commonly referred to as “clot busters,” are used to dissolve severe clots causing heart attacks, strokes, or pulmonary embolism.

13. This work is a derivative of Anatomy & Physiology by [OpenStax](https://openstax.org/details/books/anatomy-and-physiology-2e) and is licensed under [CC BY 4.0](https://creativecommons.org/licenses/by/4.0/). Access for free at <https://openstax.org/details/books/anatomy-and-physiology-2e>

14. This work is a derivative of Anatomy & Physiology by [OpenStax](https://openstax.org/details/books/anatomy-and-physiology-2e) and is licensed under [CC BY 4.0](https://creativecommons.org/licenses/by/4.0/). Access for free at <https://openstax.org/details/books/anatomy-and-physiology-2e>

THROMBOCYTOSIS

Thrombocytosis (thrŏm-bō-sī-TŌ-sīs) refers to an abnormally high number of platelets (thrombocytes) in the blood, which can cause thrombosis.

THROMBOCYTOPENIA

Thrombocytopenia (thrŏm-bō-sī-tō-PĒN-ē-ă) refers to an insufficient number of platelets, causing ineffective blood clotting and the potential for excessive bleeding.¹⁵ Common symptoms of thrombocytopenia include bleeding gums, blood in the urine or stool, or petechiae and purpura. Petechiae and purpura are red or purple spots on the skin caused by microscope hemorrhages that do not turn lighter in color when pressure is applied. See Figure 10.11¹⁶ for an image of petechiae and purpura.

15. This work is a derivative of Anatomy & Physiology by [OpenStax](#) and is licensed under [CC BY 4.0](#). Access for free at <https://openstax.org/details/books/anatomy-and-physiology-2e>

16. “[Purpura.jpg](#)” by [User:Hektor](#) is licensed under [CC BY-SA 3.0](#)

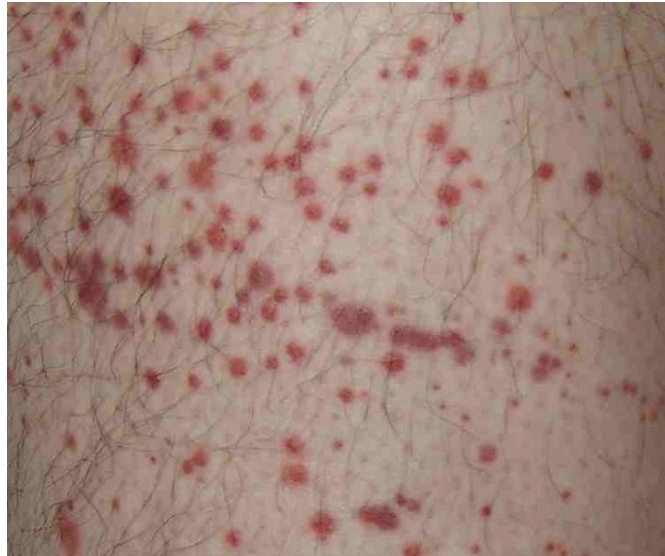

Figure 10.11 Petechiae and Purpura

10.7 Medical Specialists, Diagnostic Testing, and Procedures Related to Blood

MEDICAL SPECIALISTS

Hematologist

A **hematologist** (hē-mā-TŌL-ō-jist) is a physician who specializes in diagnosing and treating blood disorders.

- ▶ To learn more about a career as a hematologist, visit the [American Medical Association's specialty profile on hematology.](#)

Phlebotomist

A **phlebotomist** (flě-BOT-ō-mist) is medical professional trained to withdraw blood or perform blood transfusions. After the blood is collected, it is analyzed by a medical laboratory technician.

- ▶ Read more about a career as a phlebotomist at Cleveland Clinic's web page titled [Phlebotomist](#).

Medical Laboratory Technologist/Scientist/Assistant

Medical laboratories employ a variety of individuals in technical positions. Specialized positions are as follows:

- **Medical technologist** (Měd-ĩ-căl Těk-nŏl-ŏ-jist) **(MT)**: A medical professional who tests and analyzes blood, other body fluids, and tissue samples.
- **Medical laboratory scientists** (Měd-ĩ-căl LĂB-ŏr-ă-tŏr-ē Sĩ-ĚN-tĩsts) **(MLS)**: A medical professional who performs complex analyses of tissue, blood, and other body fluids.
- **Medical laboratory assistants** (Měd-ĩ-căl LĂB-ŏr-ă-tŏr-ē ă-Sĩs-tănts) **(MLA)**: A medical professional who assists in receiving, preparing, testing, and processing specimen samples.

- ▶ Read more information about these careers at the American Society for Medical Laboratory Science's web page called [What is a Medical Laboratory Professional?](#)

DIAGNOSTIC TESTING AND PROCEDURES

Apheresis

In traditional blood donation, a unit of whole blood is taken from a donor and sent to a laboratory, where it is separated into its four components: red blood cells, white blood cells, platelets, and plasma. The components are stored and administered to patients who need blood products transfused after surgery, after a severe injury/trauma, or to treat a severe disease or hematological condition. In contrast, during **apheresis** (ăf-ě-RĒ-sīs), a specific component is removed from a donor's blood, and the remaining components are returned to the donor while they are still connected to the machine.¹

Donor apheresis takes longer than a whole blood donation but is easy and painless and has many benefits. For example, an apheresis double red-cell donation (called erythropheresis) separates red blood cells and returns the remaining “non-targeted” plasma and platelets to the volunteer donor. This allows for the collection of twice as many red blood cells from one donation as they would in a whole-blood donation. As another example, a platelet apheresis donation can provide as many platelets as those obtained in four to six whole-blood donations.² See Figure 10.12³ for an image of an erythropheresis machine.

1. Yale Medicine. (n.d.). *Apheresis*. <https://www.yalemedicine.org/conditions/apheresis>
2. Yale Medicine. (n.d.). *Apheresis*. <https://www.yalemedicine.org/conditions/apheresis>
3. “Fenwal Erythropheresis machine for plasmapheresis.jpg” by Elwood P. Dowd is licensed under [CC BY-SA 4.0](https://creativecommons.org/licenses/by-sa/4.0/)

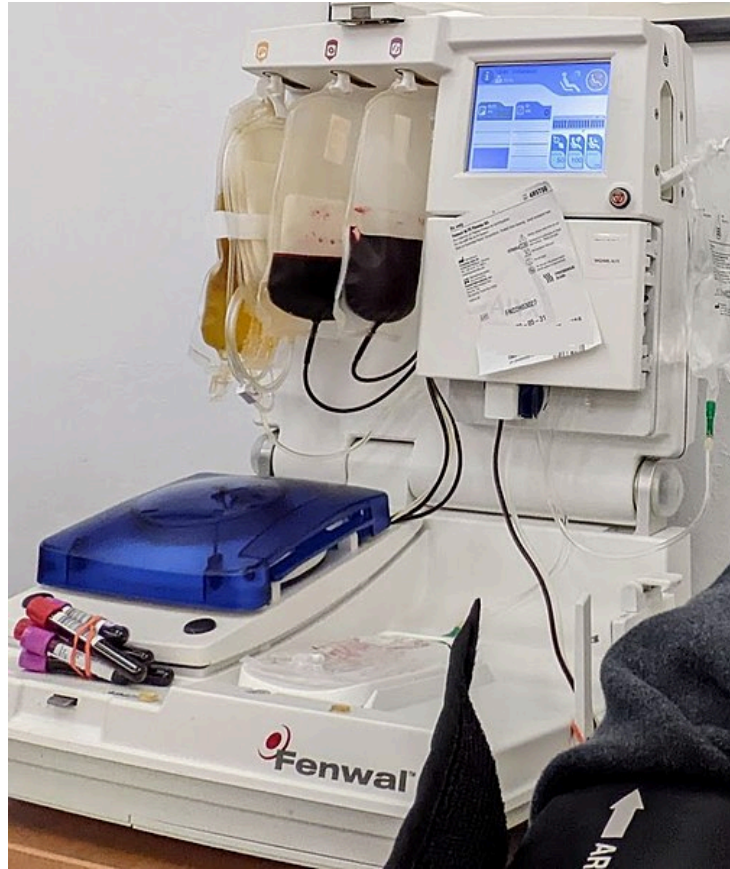

Figure 10.12 Erythropheresis Machine

Blood Product Transfusion

A **blood product** (blŭd prah-DUHKT) is any therapeutic substance derived from human blood. Types of blood products include whole blood, packed red blood cells (PRBCs), individual factor concentrates, fresh frozen plasma (FFP), platelet concentrates, and cryoprecipitate (i.e., plasma rich in proteins). Transfusion of blood products is a common procedure with nearly 16 million blood components transfused each year in the United States.⁴ Nurses

4. American Red Cross. (n.d.). *Importance of the blood supply*. <https://www.redcrossblood.org/donate-blood/how-to-donate/how-blood-donations-help/blood-needs-blood->

typically provide blood transfusions after they are prescribed by a health care provider.

In severe cases of symptomatic, severe anemia (i.e., dyspnea or chest pain) or hemoglobin levels less than 7 g/dL, transfusions of red blood cells are prescribed to rapidly increase hemoglobin levels. See Figure 10.13⁵ for an illustration of a bag of red blood cells. Note the blood type (i.e., A, B, AB, or O) and the Rh factor positive or negative) are indicated on the label to compare with the patient's lab results. Health care agencies have strict safety procedures that nurses and other health care personnel follow when providing a blood transfusion to prevent the administration of incompatible blood to a patient.

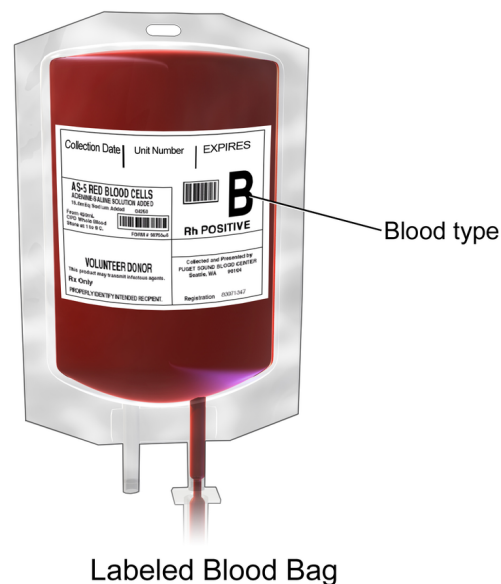


Figure 10.13 Labeled Bag of Red Blood Cells

[supply.html#:~:text=Facts%20About%20Blood%20Needs&text=Approximately%2029%2C000%20units%20of%20red,each%20year%20in%20the%20U.S](#)

5. “[Blausen_0086_Blood_Bag.png](#)” by Blausen.com staff (2014) at “[Medical gallery of Blausen Medical 2014.](#)” *WikiJournal of Medicine* is licensed under [CC BY 3.0](#)

Bone Marrow Aspiration and Biopsy

Bone marrow aspiration (BŌn MǎR-rōw ă-spĭ-RĀ-shŏn) involves the extraction of a small sample of liquid bone marrow from the center of a patient's bone. Common sites for bone marrow aspiration include the pelvic bone and sternum. The procedure is typically performed after local anesthesia is administered, and then the provider inserts a needle into the bone marrow space and draws out a liquid sample. The aspiration allows for laboratory analysis of the cellular components of the bone marrow (i.e., red blood cells, white blood cells, and platelets). Bone marrow aspiration is helpful for determining the presence of severe blood disorders, such as leukemia, and is also used to monitor disease progression or treatment effectiveness.⁶

Bone marrow biopsy (BŌn MǎR-rōw Bĭ-ŏp-sē) involves obtaining a small core of bone and marrow tissue from the bone marrow space. The procedure is often performed in conjunction with bone marrow aspiration.

See Figure 10.14⁷ for an illustration of a bone marrow biopsy.

6. A.D.A.M. Medical Encyclopedia [Internet]. Atlanta (GA): A.D.A.M., Inc.; c1997-2023. Bone marrow aspiration; [reviewed 2022, Apr 9; cited 2023, Nov 5]. <https://medlineplus.gov/ency/article/003658.htm>

7. “[Blausen_0097_BoneMarrowBiopsy.png](#)” by [Blausen Medical Communications, Inc.](#) is licensed under [CC BY 3.0](#)

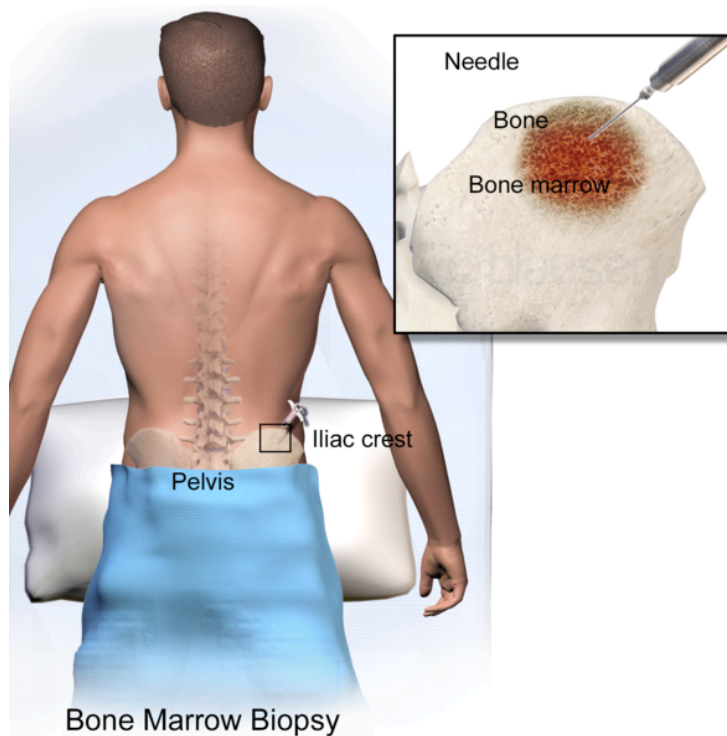


Figure 10.14 Bone Marrow Biopsy

In contrast to the bone marrow aspiration procedure, the provider uses a larger needle during bone marrow biopsy to remove a cylindrical section of both the bone and marrow. See Figure 10.15⁸ for an image of a bone marrow biopsy needle. Bone marrow biopsy provides a comprehensive evaluation of the bone marrow, allowing for a closer assessment of the bone marrow's cellular density, structure, and the presence of any abnormal or diseased cells. It helps diagnose a wider range of conditions, including non-hematological disorders like metastatic cancers and immune diseases that may infiltrate the bone marrow.⁹

8. [“Multi_Purpose_Bone_Marrow_Biopsy_Needle.jpg”](#) by [Thirteen Of Clubs](#) from Minneapolis is licensed under [CC BY-SA 2.0](#)

9. A.D.A.M. Medical Encyclopedia [Internet]. Atlanta (GA): A.D.A.M., Inc.;



Figure 10.15 Bone Marrow Biopsy Needle

Bone Marrow Transplant/Stem Cell Transplant

Bone marrow transplant (BŌn MÄR-rōw TRÄNS-plänt), also called **stem cell transplant** (STĚM Sěl TRÄNS-plänt), is a potentially curative treatment for severe hematological diseases like sickle cell disease, as well as cancer like leukemia. It typically involves the administration of chemotherapy to destroy the patient's existing bone marrow and then replacing the bone marrow with healthy stem cells donated from a compatible donor. If successful, transplantation can be curative and result in the patient's bone marrow taking over the production of healthy red blood cells, white blood cells, and platelets. However, patients undergoing this procedure with donated stem

c1997-2023. Bone marrow biopsy; [reviewed 2022, Apr 9; cited 2023, Nov 5].
<https://medlineplus.gov/ency/article/003934.htm>

cells must take immunosuppressive medication for the remainder of their lives.¹⁰

Complete Blood Count

A **complete blood count** (kõm-PLĒT BLŮD kownt) (**CBC**) is a blood test performed in a laboratory that provides a comprehensive assessment of various blood components, including RBCs, WBCs, platelets, hematocrit (HCT), and hemoglobin (Hgb). These parameters help evaluate the overall health of the hematological system and can indicate anemia, infection, or other blood disorders. A **CBC with differential** (CBC wĭth Dĭf-ě-REN-shǎl) includes an additional measurement of the different types of white blood cells (i.e., neutrophils, lymphocytes, monocytes, eosinophils, and basophils). See Figure 10.16¹¹ for an illustration of CBC with differential test results indicated behind a tube of drawn blood.

10. National Cancer Institute. (2023, October 5). *Stem cell transplants in cancer treatment*. National Institutes of Health. <https://www.cancer.gov/about-cancer/treatment/types/stem-cell-transplant>

11. “[Complete blood count and differential.jpg](#)” by SpicyMilkBoy is licensed under [CC BY-SA 4.0](#)

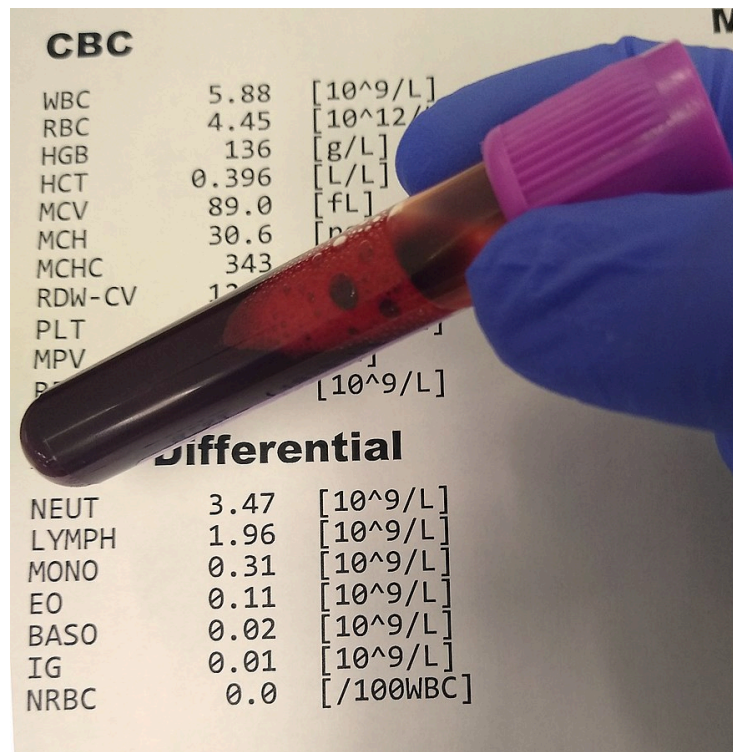


Figure 10.16 CBC With Differential Test Results

10.8 Blood Learning Activities

Interactive Learning Activity: Study medical terms related to the blood that are discussed in this chapter using these flashcards.



An interactive H5P element has been excluded from this version of the text. You can view it online here:

<https://wtcs.pressbooks.pub/medterm/?p=368#h5p-184>

Interactive Learning Activity: Review terms related to the blood.



An interactive H5P element has been excluded from this version of the text. You can view it online here:

<https://wtcs.pressbooks.pub/medterm/?p=368#h5p-59>



Interactive Learning Activity: Practice identifying and defining word parts for terms discussed in this chapter.



An interactive H5P element has been excluded from this version

of the text. You can view it online here:

<https://wtcs.pressbooks.pub/medterm/?p=368#h5p-201>

- ▶ You can also print this as a [Chapter 10 Practice Worksheet](#) and check your answers with this [Answer Key PDF](#).

10.9 Glossary

Anemia (ā-NĒ-mē-ă): A blood disorder characterized by a deficiency of red blood cells and/or hemoglobin, leading to decreased oxygen delivery to body tissues and symptoms like fatigue, weakness, shortness of breath, and pale skin. ([Chapter 10.6](#))

Anticoagulant (ăn-tī-kō-AG-yū-lănt): A substance or medication that prevents or reduces coagulation of blood, thereby prolonging the clotting time. ([Chapter 10.5](#))

Apheresis (ăf-ě-RĒ-sīs): A procedure where a specific component of blood is removed from a donor, and the remaining components are returned to the donor. ([Chapter 10.7](#))

Aplastic anemia (ā-PLAS-tĭk ā-NĒ-mē-ă): A bone marrow condition causing insufficient production of red blood cells. ([Chapter 10.6](#))

Basophils (bā-sō-fĭls): The least common type of white blood cell, playing a role in inflammatory responses, particularly those involving allergic reactions. ([Chapter 10.4](#))

Bilirubin (bĭl-ĭ-rōō-bĭn): A yellow compound that occurs in the normal catabolic pathway that breaks down heme in vertebrates. High levels in the bloodstream can lead to jaundice. ([Chapter 10.4](#))

Blood product (blŭd prah-DUHKT): Components of blood, such as red blood cells, white blood cells, platelets, and plasma, used for transfusions. ([Chapter 10.7](#))

Blood transfusion (blŭd tran-SFŪ-zhŏn): A procedure that enables the transfer of blood products from one person to another. ([Chapter 10.4](#))

Bone marrow (bŏn MAR-ŏ): The soft, spongy tissue found inside bones, responsible for the production of blood cells. ([Chapter 10.4](#))

Bone marrow aspiration (BŌn MĂR-rŏw ă-spĭ-RĂ-shŏn): The extraction of a small sample of liquid bone marrow for laboratory analysis to diagnose severe blood disorders like leukemia. ([Chapter 10.7](#))

Bone marrow biopsy (BŌn MĂR-rŏw Bĭ-ŏp-sē): Obtaining a core of bone

and marrow tissue for examining the bone marrow space, often performed with bone marrow aspiration. ([Chapter 10.7](#))

Bone marrow transplant (BŌn MĀR-rōw TRĀNS-plānt): A treatment for severe hematological diseases or cancers like leukemia, involving the replacement of a patient's bone marrow with healthy stem cells from a donor. ([Chapter 10.7](#))

CBC with differential (CBC wĭth Dĭf-ě-REN-shǎl): A CBC test that includes an additional measurement of the different types of white blood cells, such as neutrophils, lymphocytes, monocytes, eosinophils, and basophils. ([Chapter 10.7](#))

Coagulation (kō-ag-yū-LĀ-shǒn): The process of blood clotting, an essential part of hemostasis, involving the transformation of blood from a liquid to a gel to stop bleeding. ([Chapter 10.5](#))

Complete blood count (kǒm-PLĒT BLŮD kownt) (CBC): A blood test that provides a comprehensive assessment of various blood components, including red and white blood cells, platelets, hematocrit, and hemoglobin. ([Chapter 10.7](#))

Contusion (kon-TU-zhun): A bruise that occurs when small veins and capillaries under the skin break, releasing blood into the surrounding tissue. ([Chapter 10.6](#))

Embolism (ĒM-bǒ-lĭzm): A condition where an embolus becomes trapped in a blood vessel, potentially causing a heart attack, stroke, or pulmonary embolism. ([Chapter 10.6](#))

Embolus (ĒM-bǒ-lŭs): A piece of a thrombus that has broken free and travels through the bloodstream, potentially causing blockage in blood vessels of major organs. ([Chapter 10.6](#))

Eosinophils (ē-ō-sĭn-ō-fĭls): White blood cells involved in the response to allergic reactions, asthma, and infection with parasites. ([Chapter 10.4](#))

Erythrocytes (ě-rĭth-rō-sĭts): Red blood cells, which are responsible for carrying oxygen from the lungs to the body's tissues and carbon dioxide as a waste product, away from the tissues and back to the lungs. ([Chapter 10.4](#))

Erythropoietin (ě-rĭth-rō-poi-Ē-tĭn) (EPO): A hormone produced by the kidneys that promotes the formation of red blood cells by the bone marrow. ([Chapter 10.4](#))

Fibrin (FĪ-brin): A fibrous protein formed during blood clotting, essential for the formation of a stable blood clot. ([Chapter 10.5](#))

Fibrinolysis (fī-brī-NŌL-ĭ-sĭs): The process that breaks down fibrin in blood clots, playing a crucial role in preventing blood clots from growing and becoming problematic. ([Chapter 10.5](#))

Hematocrit (hē-măt-ō-křit) (HCT): A blood test that measures the percentage of the volume of whole blood that is made up of red blood cells. ([Chapter 10.4](#))

Hematologist (hē-mā-TŌL-ō-jist): A physician who specializes in the diagnosis and treatment of blood disorders. ([Chapter 10.7](#))

Hematology (hēm-ă-TŌL-ō-jē): The study of blood, blood components, and blood-forming organs, focusing on their role in health and disease. ([Chapter 10.1](#))

Hematoma (hēm-ă-TŌ-mă): A collection or pooling of blood outside the blood vessel caused by an injury. ([Chapter 10.6](#))

Hemoglobin (hē-mō-glō-bĭn) (Hgb): A protein in red blood cells that carries oxygen from the lungs to the rest of the body and returns carbon dioxide from the body to the lungs. ([Chapter 10.4](#))

Hemolysis (hē-MOL-ĭ-sĭs): The destruction or breakdown of red blood cells, leading to the release of hemoglobin into the surrounding fluid. ([Chapter 10.4](#))

Hemolytic disease of the newborn (hē-mō-LĪT-ik dĩ-zēz əv thə NŪ-bôrn): A condition occurring when an Rh-negative mother's immune system attacks Rh positive fetal red blood cells, potentially leading to fetal death without treatment. ([Chapter 10.4](#))

Hemophilia (hē-mō-FĒL-ē-ă): A genetic disorder in which blood doesn't clot normally due to deficient or abnormal clotting factors. ([Chapter 10.6](#))

Hemorrhage (HEM-ŏ-rāj): Excessive bleeding that cannot be controlled by hemostasis and is considered a medical emergency. ([Chapter 10.4](#), [Chapter 10.6](#))

Hemostasis (hē-mō-STĀ-sĭs): The process of blood clot formation at the site of vessel injury. It involves three steps: vascular spasm, formation of a platelet plug, and blood clotting (coagulation). ([Chapter 10.4](#), [Chapter 10.5](#))

Hepatomegaly (hep-ăt-ō-MĚG-ă-lē): Enlargement of the liver, which can be caused by liver disease, cancer, and excess alcohol intake. ([Chapter 10.4](#))

International normalized ratio (ĩn-těr-NASH-ũ-năl NÔR-mă-lĩzd RĂ-shiō) (INR): A calculation based on the PT used to ensure test results from different labs are comparable; it's particularly important for patients on anticoagulant medication like warfarin. ([Chapter 10.5](#))

Iron deficiency anemia (ĩrŃn dē-Fĩ-shěn-sē ā-NĒ-mē-ă): The most common type of anemia, caused by a lack of dietary iron needed for sufficient production of hemoglobin. ([Chapter 10.6](#))

Jaundice (JAWN-dis): A yellowish discoloration of the skin and eyes, usually caused by impaired liver function that affects the metabolism of bilirubin. ([Chapter 10.4](#))

Leukemia (lũ-KĒM-ē-ă): Cancer of the bone marrow and the body's blood-forming tissues, characterized by an abundance of nonfunctional leukocytes (white blood cells). ([Chapter 10.6](#))

Leukocytes (lũ-kō-sĩts): White blood cells, which are part of the immune system and help the body to fight infection and other diseases. ([Chapter 10.4](#))

Leukocytosis (lũ-kō-sĩ-TŌ-sĩs): Excessive leukocyte (white blood cell) production, often with nonfunctional cells, leading to increased risk of infection. ([Chapter 10.6](#))

Leukopenia (lũ-kō-PĒN-ē-ă): A condition where too few leukocytes (white blood cells) are produced, impacting the individual's ability to fight off disease. ([Chapter 10.6](#))

Liver (LIV-ěr): A vital organ that plays multiple roles in digestion, metabolism, and hemostasis, including the production of bile and the storage of blood and blood cells. ([Chapter 10.4](#))

Lymphocytes (lĩm-fō-sĩts): A subtype of white blood cells found in the lymphatic system, playing a large role in the immune response. ([Chapter 10.4](#))

Lymphoma (lĩm-FŌ-mă): A type of cancer where masses of malignant lymphocytes (white blood cells) collect in lymph nodes, the spleen, the liver, and other tissues. ([Chapter 10.6](#))

Medical laboratory assistants (měd-ĩ-căl LĂB-Ńr-ă-tŃr-ē ă-Sĩs-tănts) (MLA): Professionals who assist in preparing, testing, and processing specimen samples. ([Chapter 10.7](#))

Medical laboratory scientists (měd-ĩ-căl LĂB-Ńr-ă-tŃr-ē Sĩ-ĒN-tĩsts) (MLS):

Professionals who perform complex analyses of tissue, blood, and other body fluids. ([Chapter 10.7](#))

Medical technologist (měd-ĭ-căl Těk-nŏl-ŏ-jist) (MT): A medical professional who tests and analyzes blood, other body fluids, and tissue samples. ([Chapter 10.7](#))

Megaloblastic anemia (mě-gŭh-lŏ-plă-stĭk ā-NĒ-mē-ă): Involves a deficiency of vitamin B12 and/or folate, often due to inadequate dietary intake. ([Chapter 10.6](#))

Monocytes (mŏn-ŏ-sĭts): A type of white blood cell that engulfs and digests cellular debris, foreign substances, microbes, and cancer cells. ([Chapter 10.4](#))

Neutrophils (nŭ-trŏ-fĭls): A type of white blood cell that helps heal damaged tissues and resolve infections. ([Chapter 10.4](#))

Pancytopenia (păn-sĭ-tŏ-PĒ-nē-ă): A reduction of all types of blood components including red and white blood cells, and platelets. ([Chapter 10.6](#))

Partial thromboplastin time (păr-shăl thrŏm-bŏ-PLAS-tĭn tĭm) (PTT): A blood test that measures a specific group of clotting factors and is used to diagnose clotting disorders or monitor patients on anticoagulants. ([Chapter 10.5](#))

Pernicious anemia (pěr-nĭsh-ē-ŭs ā-NĒ-mē-ă): Caused by poor absorption of vitamin B12 in the gastrointestinal tract. ([Chapter 10.6](#))

Phlebotomist (flě-BOT-ŏ-mist): A medical professional trained to withdraw blood or perform blood transfusions. ([Chapter 10.7](#))

Phlebotomy (flě-BOT-ŏ-mē): The practice of drawing blood from a vein, typically for laboratory testing or blood donation. ([Chapter 10.4](#))

Plasma (plăz-mă): The liquid component of blood in which the blood cells and other components are suspended. It plays a vital role in maintaining blood pressure and regulating body temperature. ([Chapter 10.4](#))

Platelets (PLĀT-lĭts): Also known as thrombocytes, these are small, colorless cell fragments in the blood whose main function is to react to bleeding from blood vessel injury by clumping, thereby initiating a blood clot. ([Chapter 10.4](#))

Polycythemia (pol-ē-sĭ-THĒM-ē-ă): Refers to an elevated red blood cell count, which can be a normal response to living at high altitudes. ([Chapter 10.6](#))

Polycythemia vera (pol-ē-sĭ-THĒM-ē-ă vee-ruh): A bone marrow disease

causing excessive production of immature red blood cells and other blood components, increasing blood viscosity. ([Chapter 10.6](#))

Prothrombin time (PRŌ-thrŏm-bĭn tĭm) (PT): A blood test that measures how long it takes blood to clot, used to check for bleeding problems or the effects of anticoagulants. ([Chapter 10.5](#))

Red blood cells (rĕd blŭd sĕls) (RBCs): Cells in the blood that carry oxygen from the lungs to the rest of the body and return carbon dioxide from the body to the lungs for exhalation. ([Chapter 10.4](#))

Rh factor (Ār āch FAK-tŏr): An antigen found on red blood cells; individuals can be Rh positive (Rh+) if they have the antigen or Rh negative (Rh-) if they lack it. ([Chapter 10.4](#))

Rh negative (Ār-āch NĚG-ă-tĭv) (Rh-): Individuals who lack the Rh factor antigen on their red blood cells. ([Chapter 10.4](#))

RhoGAM (RŌ-gām): A medication administered to Rh negative mothers during pregnancy and after birth to prevent the development of Rh antibodies, thereby averting hemolytic disease of the newborn in Rh positive fetuses. ([Chapter 10.4](#))

Rh positive (Ār-āch PŌZ-ĭ-tĭv) (Rh+): Individuals who have the Rh factor antigen present on their red blood cells. ([Chapter 10.4](#))

Sickle cell anemia (SĪK-l sĕl ā-NĚ-mē-ă): A genetic disorder that causes red blood cells to assume a sickle shape, which can block blood flow and cause serious problems in organs throughout the body. ([Chapter 10.6](#))

Spleen (splĕn): An organ that serves as a storage site for red blood cells (RBCs) and platelets, filters antigens, and plays a role in the destruction of old RBCs and the breakdown of hemoglobin. ([Chapter 10.4](#))

Splenectomy (splĕ-NEK-tŏ-mē): Surgical removal of the spleen, which can lead to reduced immune function and an increased risk of infection. ([Chapter 10.4](#))

Splenomegaly (splĕ-nŏ-MĚG-ă-lĕ): Enlargement of the spleen, which can occur due to various reasons such as systemic infection, sickle cell disease, or cancer. ([Chapter 10.4](#))

Stem cell transplant (STĚM Sĕl TRĀNS-plănt): Another term for bone marrow transplant, involving the replacement of diseased bone marrow with healthy stem cells. ([Chapter 10.7](#))

Thalassemia (thal-ă- SĒM-ē-ă): An inherited condition typically occurring in individuals from specific regions, characterized by abnormal maturation of red blood cells. ([Chapter 10.6](#))

Thrombocytes (thrōm-bō-sītz): Also known as platelets, these are blood cells responsible for blood clotting. ([Chapter 10.4](#))

Thrombocytopenia (thrōm-bō-sī-tō-PĒ-nē-ă): A condition where there is an insufficient number of platelets, leading to ineffective blood clotting and potential for excessive bleeding. ([Chapter 10.6](#))

Thrombocytosis (thrōm-bō-sī-TŌ-sīs): A condition characterized by an abnormally high number of platelets in the blood, which can lead to thrombosis. ([Chapter 10.6](#))

Thrombolysis (thrōm-BŎL-ī-sīs): The process of dissolving a blood clot, often achieved with medications like tissue plasminogen activator (tPA). ([Chapter 10.6](#))

Thrombosis (thrōm-BŎ-sīs): The formation of a thrombus, a blood clot, within a blood vessel, potentially causing obstruction of blood flow. ([Chapter 10.6](#))

Thrombus (THROM-būs): A blood clot composed of platelets, red and white blood cells, and fibrin strands, potentially leading to decreased blood flow or life-threatening obstruction in blood vessels. ([Chapter 10.6](#))

Viscosity (vīs-KOS-ī-tē): Refers to the state of being thick, sticky, and easily coagulable, as seen in conditions like polycythemia vera. ([Chapter 10.6](#))

White blood cells (wīt blūd sēls) (WBCs): Cells of the immune system involved in protecting the body against both infectious disease and foreign invaders. ([Chapter 10.4](#))

PART XI

CHAPTER 11 LYMPHATIC & IMMUNE SYSTEMS TERMINOLOGY

11.1 Lymphatic & Immune Systems Introduction

Learning Objectives


- Apply the rules of medical language to build, analyze, spell, pronounce, abbreviate, and define terms as they relate to the lymphatic and immune systems
- Identify meanings of key word components of the lymphatic and immune systems
- Categorize diagnostic, therapeutic, procedural, or anatomic terms related to the lymphatic and immune systems
- Use terms related to the lymphatic and immune systems
- Use terms related to the diseases and disorders of the lymphatic and immune systems

Introduction to the Lymphatic and Immune Systems

The lymphatic system is a network of organs, lymph nodes, lymph ducts, and lymph vessels that produce and transport lymph from tissue spaces to the bloodstream. The lymphatic system is a major part of the body's immune system.¹

1. A.D.A.M. Medical Encyclopedia [Internet]. Atlanta (GA): A.D.A.M., Inc.;

This chapter will review common word components related to the lymphatic and immune systems to assist learners in analyzing, building, and defining medical terms. Other terms, whose definitions cannot be easily built from word components, will be described in context based on the anatomy and physiology of the lymphatic and immune systems and common diseases and disorders. Because the lymphatic system shares organs with a number of other body systems, the disorders discussed near the end of this chapter mainly focus on disorders of the immune system. Medical specialists, diagnostic tests, and procedures related to the lymphatic and immune systems will also be discussed.

View the following YouTube video² for an overview of the
 lymphatic system: [Lymphatic System: Crash Course A&P #44](#)

c1997-2023. Lymph system; [reviewed 2022, Jul 25; cited 2023, Nov 5].
<https://medlineplus.gov/ency/article/002247.htm>

2. CrashCourse. (2015, November 30). *Lymphatic system: Crash Course A&P #44* [Video]. YouTube. All rights reserved.
<https://www.youtube.com/watch?v=l7orwMgTQ5I&feature=youtu.be>

11.2 Word Components Related to the Lymphatic and Immune Systems

This section will describe common word components related to the lymphatic and immune systems. These word components help build definitions for many medical terms. Other common prefixes are described in [Chapter 1.3](#), and common suffixes are described in [Chapter 1.5](#).

PREFIXES RELATED TO THE LYMPHATIC AND IMMUNE SYSTEMS

- **a-**: Absence of, without
- **an-**: Absence of, without
- **ana-**: Up, upward or back, backward
- **brady-**: Slow
- **inter-**: Between
- **pan-**: All

WORD ROOTS RELATED TO THE LYMPHATIC AND IMMUNE SYSTEMS

- **aden/o**: Gland

- **immun/o**: Immune, immunity
- **lymph/o**: Lymph, lymph tissue
- **lymphaden/o**: Lymph gland, lymph node
- **myel/o**: Bone marrow, spinal cord
- **phag/o**: To eat
- **splen/o**: Spleen
- **thym/o**: Thymus gland
- **tox/o**: Poison

SUFFIXES RELATED TO THE LYMPHATIC AND IMMUNE SYSTEMS

- **-ac**: One affected with
- **-apheresis**: Withdrawal or removal
- **-cyte**: Cell
- **-ectomy**: Excision, cut out
- **-itis**: Inflammation
- **-logist**: Specialist who studies and treats
- **-logy**: Study of
- **-megaly**: Enlarged, enlargement
- **-oid**: Resembling
- **-oma**: Tumor, swelling
- **-osis**: Abnormal condition
- **-pathy**: Disease
- **-penia**: Decrease, deficiency
- **-poiesis**: Formation, production
- **-rrhaphy**: Suturing

11.3 Examples of Lymphatic and Immune Systems Terms Easily Defined By Their Word Parts

Here are examples of common medical terms related to the lymphatic and immune systems that can be easily defined by breaking the terms into their word components.

Immunologist

1. Break down the medical term into word components:
Immun/o/logist
2. Label the word components: **Immun** = WR; **o** = CV; **logist** = S
3. Define the word components: **Immun** = immune system; **logist** = specialist who studies and treats
4. Create a final definition of the medical term: **A specialist who studies and treats immune system disorders**

Splenectomy

1. Break down the medical term into word components:

Splen/ectomy

2. Label the word components: **Splen** = WR; **ectomy** = S
3. Define the word components: **Splen** = spleen; **ectomy** = cut out
4. Create a final definition of the medical term: **Surgical removal of the spleen**

Lymphadenopathy

1. Break down the medical term into word components:
Lymphaden/o/pathy
2. Label the word components: **Lymphaden** = WR; **o** = CV; **pathy** = S
3. Define the word components: **Lymphaden** = lymph node; **pathy** = disease
4. Create a final definition of the medical term: **Disease of a lymph node (i.e., swelling of a lymph node due to infection)**



Interactive Learning Activity: Practice pronouncing and defining medical terms related to the lymphatic and immune systems by breaking them down into word parts.



An interactive H5P element has been excluded from this version of the text. You can view it online here:

<https://wtcs.pressbooks.pub/medterm/?p=4771#h5p-179>

- ▶ You can also print these flashcard activities as a [Chapter 11 Student Companion Worksheet](#) and check your answers with this [Answer Key](#).

11.4 Anatomy of the Lymphatic and Immune Systems

ANATOMY OF THE LYMPHATIC AND IMMUNE SYSTEMS

The **lymphatic system** (lĭmf-ă-TĭK sĭs-tŭm) is the system of vessels, cells, and organs that transports fluid called lymph to the bloodstream and also filters pathogens from the blood. The **immune system** (ĭ-MŪN SĭS-tĕm) is the complex collection of cells and organs that destroys or neutralizes pathogens that would otherwise cause infection, disease, or death. The lymphatic system, for most people, is associated with the immune system to such a degree that the two systems are virtually indistinguishable.¹

Lymph Vessels

Lymph capillaries are interlaced in **interstitial space** (in-tĕr-STISH-ăł spās), the space between individual cells in the tissues. Interstitial fluid enters the lymphatic capillaries and becomes lymph. **Lymph** (limf) is a clear-to-white fluid that transports immune system cells, as well as dietary lipids and fat-

1. This work is a derivative of Open Stax Anatomy and Physiology 2e at <https://openstax.org/books/anatomy-and-physiology-2e/pages/21-1-anatomy-of-the-lymphatic-and-immune-systems>

soluble vitamins absorbed in the small intestine called **chyle** (kīl).² See Figure 11.1³ for an image of lymph capillaries.

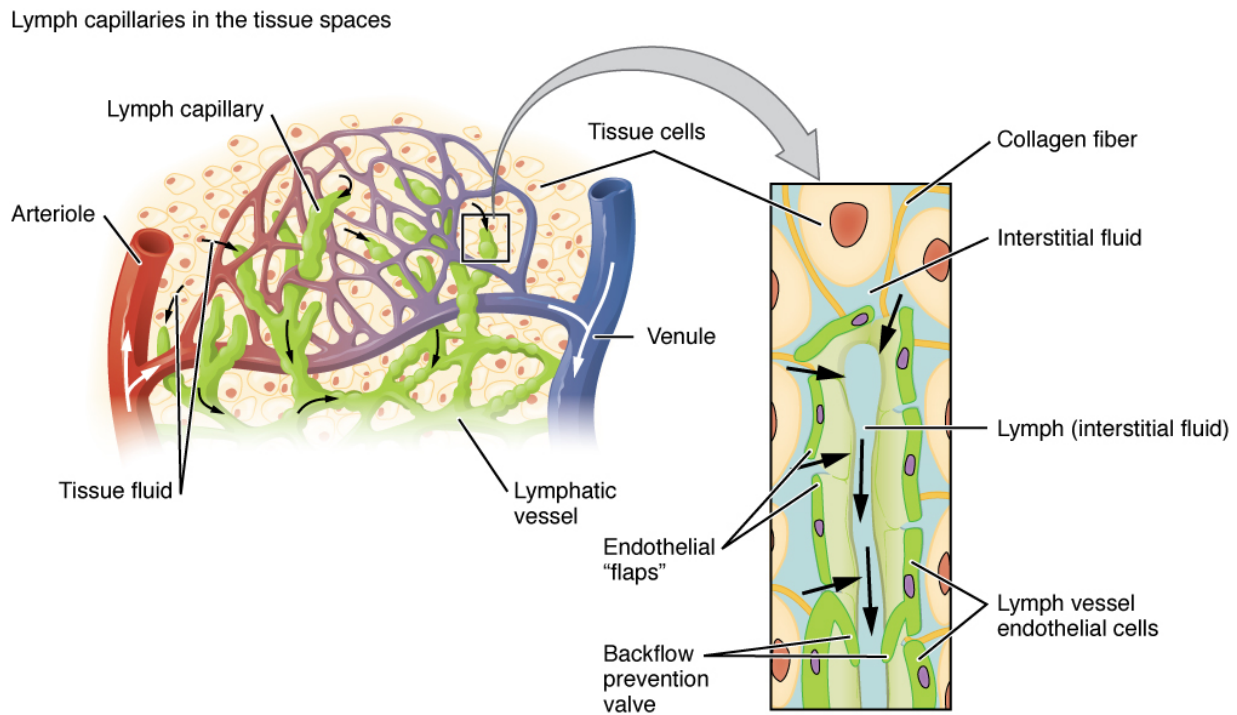


Figure 11.1 Lymph Capillaries

Lymph capillaries empty into larger lymphatic vessels that become larger and larger until they ultimately empty into the bloodstream at the left and right subclavian veins.

2. This work is a derivative of *Anatomy and Physiology* by OpenStax licensed under CC BY 4.0. Access for free at <https://openstax.org/books/anatomy-and-physiology/pages/1-introduction>
3. “2202_Lymphatic_Capillaries.jpg” by OpenStax College is licensed under CC BY 3.0

Lymph Nodes

Immune system cells not only use lymphatic vessels to make their way from interstitial space into the circulation, but also use lymph nodes as major staging areas for the development of critical immune responses. **Afferent lymphatic vessels** (AF-ě-rěnt lim-FAT-ik VES-ěls) are vessels that lead into a lymph node, and **efferent lymphatic vessels** (EF-ě-rěnt lim-FAT-ik VES-ěls) are vessels that lead out of a lymph node.⁴

Lymph nodes (limf nōdz) are small, bean-shaped organs located throughout the lymphatic system. Lymph nodes store immune system cells (B cells and T cells) that help the body fight infection and also filter the lymph fluid to remove foreign material such as bacteria and cancer cells. Lymph nodes are also the sites of adaptive immune responses that are discussed in the “[Physiology of the Lymphatic and Immune Systems](#).”

Lymph travels through the lymph nodes near the groin, armpits, neck, chest, and abdomen. Humans have about 500–600 lymph nodes throughout the body.⁵ See Figure 11.2⁶ for an illustration of lymph vessels and nodes.

4. This work is a derivative of [Anatomy and Physiology](#) by [OpenStax](#) licensed under [CC BY 4.0](#). Access for free at <https://openstax.org/books/anatomy-and-physiology/pages/1-introduction>
5. This work is a derivative of [Anatomy and Physiology](#) by [OpenStax](#) licensed under [CC BY 4.0](#). Access for free at <https://openstax.org/books/anatomy-and-physiology/pages/1-introduction>
6. “lymphaticimage-972×1024.jpg” by J. Gordon Betts, et al. is licensed under [CC BY 4.0](#). Access for free at <https://openstax.org/books/anatomy-and-physiology/pages/1-introduction>

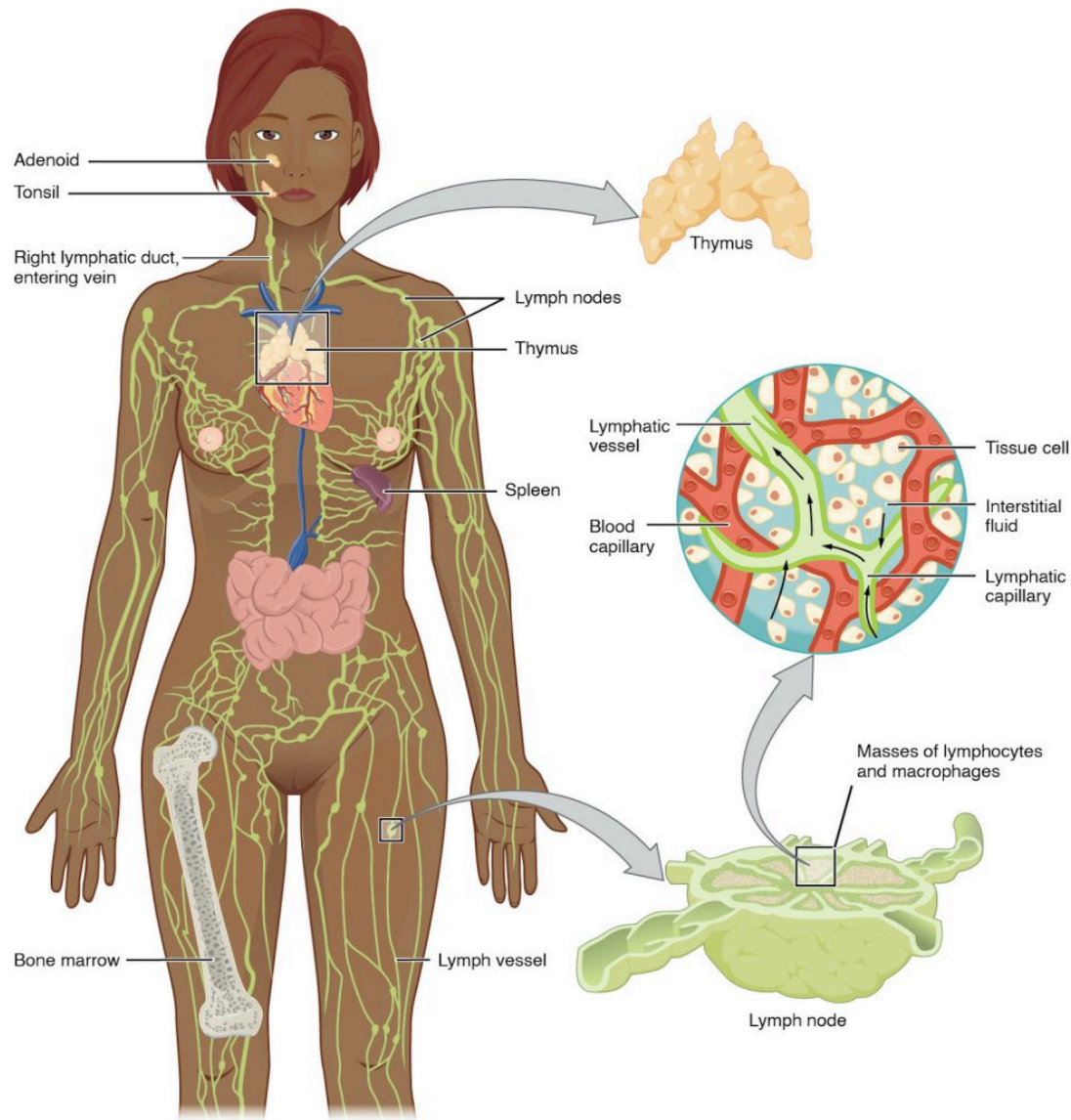


Figure 11.2 Anatomy of the Lymphatic System

A major distinction between the lymphatic and cardiovascular systems is that lymph is not actively pumped by the heart but is forced through the vessels by the contraction of skeletal muscles during body movements and breathing. One-way valves in lymphatic vessels keep the lymph moving toward the heart.⁷

When the lymphatic system is damaged in some way, such as by being blocked by cancer cells or destroyed by injury, lymph “backs up” from the lymph vessels into interstitial spaces. This inappropriate accumulation of fluid, referred to as **lymphedema** (limf-e-DẼ-ma), can cause serious medical consequences.

Primary Lymphoid Organs: Bone Marrow and Thymus

The primary lymphoid organs are the bone marrow and thymus gland. The lymphoid organs are where lymphocytes mature, proliferate, and are selected to attack pathogens.

A **lymphocyte** (lim-fa- SĪT) is a type of white blood cell that fights infection. There are two main types of lymphocytes: B cells and T cells. **B cells** (B sĕls) produce antibodies that are used to attack invading bacteria, viruses, and toxins. **T cells** (T sĕls) destroy the body’s own cells that have been taken over by viruses or become cancerous.⁸

Recall that all blood cells, including lymphocytes, are formed in the red bone marrow. The B cell undergoes nearly all of its development in the bone marrow, whereas the immature T cell, called a thymocyte, leaves the bone marrow and matures in the thymus gland. The **thymus gland** (THĪ-mŭs gland) is an organ found in the space between the sternum and the aorta of the heart (refer to Figure 11.2).⁹

under [CC BY 4.0](https://openstax.org/books/anatomy-and-physiology/pages/1-introduction). Access for free at <https://openstax.org/books/anatomy-and-physiology/pages/1-introduction>

8. National Human Genome Research Institute. (2023, November 6). *Lymphocyte*. <https://www.genome.gov/genetics-glossary/Lymphocyte>
9. This work is a derivative of *Anatomy and Physiology* by OpenStax licensed under [CC BY 4.0](https://openstax.org/books/anatomy-and-physiology/pages/1-introduction). Access for free at <https://openstax.org/books/anatomy-and-physiology/pages/1-introduction>

Secondary Lymphoid Organs

Lymphocytes develop and mature in the primary lymphoid organs, but they mount immune responses from the secondary lymphoid organs. Secondary lymphoid organs include the spleen, tonsils, and lymph nodes.¹⁰

Spleen

The **spleen** (splēn) is sometimes called the “filter of the blood.” As discussed in the “[Anatomy of the Hematology System](#)” in the “Blood Terminology” chapter, the spleen stores and filters red blood cells and also produces white blood cells and antibodies to fight infection.

Tonsils

The **tonsils** (TON-sĭls) are lymphoid nodules located along the inner surface of the pharynx (throat) and are important in developing immunity to oral pathogens. There are five tonsils, including the pharyngeal tonsil (also called the adenoid) located behind the nasal cavity in the nasopharynx, two palatine tonsils located at the back of the mouth in the oropharynx, and two lingual tonsils attached to the tongue. See Figure 11.3¹¹ for an illustration of the palatine tonsils. Swelling or enlargement of the tonsils is an indication of an active immune response to infection. A major function of tonsils is to help children’s bodies recognize, destroy, and develop immunity to common environmental pathogens so that they will be protected in their later lives. However, tonsils are often removed for individuals who have recurring throat

10. This work is a derivative of [Anatomy and Physiology](#) by [OpenStax](#) licensed under [CC BY 4.0](#). Access for free at <https://openstax.org/books/anatomy-and-physiology/pages/1-introduction>

11. “[Throat_with_Tonsils_0011J.jpeg](#)” by [Klem](#) is licensed under [CC BY 3.0](#)

infections because swollen tonsils can interfere with breathing and/or swallowing.¹²

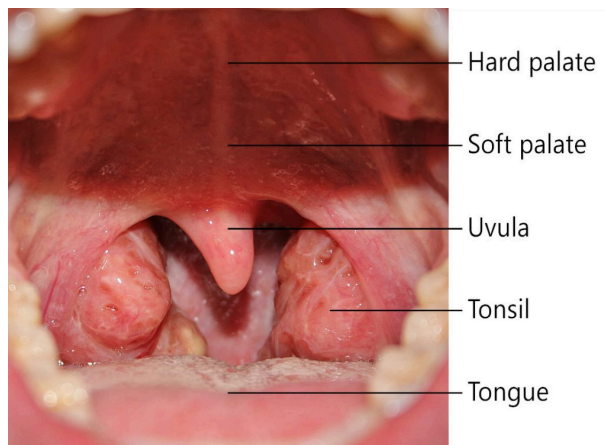


Figure 11.3 Location of the Palatine Tonsils

¹². This work is a derivative of [Anatomy and Physiology](https://openstax.org/books/anatomy-and-physiology/pages/1-introduction) by [OpenStax](https://openstax.org/books/anatomy-and-physiology/pages/1-introduction) licensed under [CC BY 4.0](https://creativecommons.org/licenses/by/4.0/). Access for free at <https://openstax.org/books/anatomy-and-physiology/pages/1-introduction>

11.5 Physiology of the Lymphatic and Immune Systems

IMMUNE RESPONSE

There are two basic processes in which the human body defends against microorganisms that cause infection, referred to as a nonspecific, innate immune response and a specific, adaptive immune response.

Innate Immune Response

The nonspecific, **innate immune response** (ĭn-NĀT i-MŪN ri-SPONS) refers to defenses that target invading pathogens in a nonspecific manner. It is called “innate” because it is present from the moment we are born. **Pathogens** (PĀTH-ō-jĕnz) refer to bacteria, viruses, or other microorganisms that can cause infection and disease. The innate immune response includes physical barriers, inflammation, and fever.¹

Physical Barriers

Physical barriers are the body’s basic defenses against infection. These physical barriers are also referred to as the body’s first line of defense. They include intact skin and mucous membranes, as well as mucus and enzymes,

¹. This work is a derivative of [Health Alterations](#) by [Open RN](#) and is licensed under [CC BY 4.0](#)

that physically destroy and/or remove pathogens and debris from areas of the body where they might cause harm or infection. Other examples of physical barriers include tears, acidity in the urine and reproductive tracts, and sebum (the protective oil secreted through hair follicles onto the skin).²

Internal Defenses

Internal defenses are also referred to as the body's second line of defense. These work to protect the body if a pathogen gets past the physical barriers and into the body. Examples of internal defenses include phagocytosis, inflammatory response, and fever.³

PHAGOCYTOSIS

Phagocytosis (făg-ō-sī-TŌ-sīs) refers to the process of cells engulfing and destroying pathogens (i.e., “cells eating”). Monocytes are a type of white blood cell that are macrophages (big eaters). Macrophages “eat up” damaged cells, pathogens, and debris. Another type of white blood cell called neutrophils are also called phagocytes, but as they “clean up,” they become toxic and die,

2. This work is a derivative of [Anatomy and Physiology](#) by [OpenStax](#) licensed under [CC BY 4.0](#). Access for free at <https://openstax.org/books/anatomy-and-physiology/pages/1-introduction>
3. This work is a derivative of [Anatomy and Physiology](#) by [OpenStax](#) licensed under [CC BY 4.0](#). Access for free at <https://openstax.org/books/anatomy-and-physiology/pages/1-introduction>

creating pus. Neutrophils are typically the first cells on site to a new infection.⁴ See Figure 11.4⁵ for an image of phagocytosis.

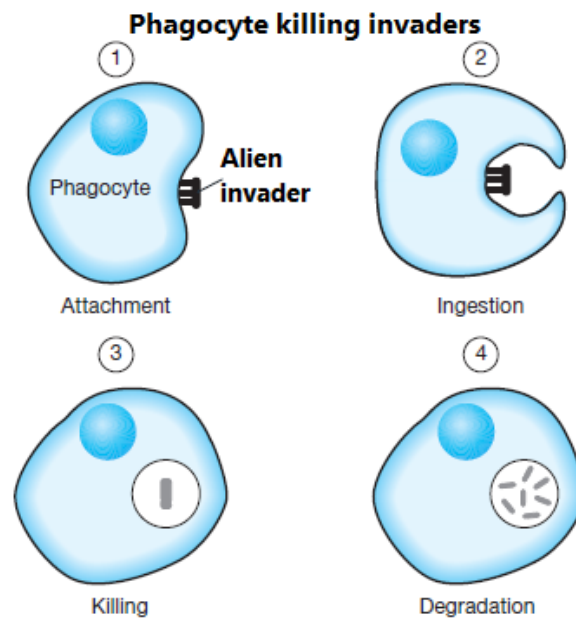


Figure 11.4 Phagocytosis

INFLAMMATORY RESPONSE

Inflammation (in-flă-MĀ-shŏn) is characterized by heat, redness, pain, and swelling. Although inflammation is often perceived as a negative consequence of injury or disease, it is an important process that recruits immune defenses to eliminate pathogens, remove damaged and dead cells, and initiate repair mechanisms.⁶

4. A.D.A.M. Medical Encyclopedia [Internet]. Atlanta (GA): A.D.A.M., Inc.; c1997-2023. Immune response; [reviewed 2022, Jan 23; cited 2023, Nov 7]. <https://medlineplus.gov/ency/article/000821.htm>

5. "phagocytes.png" by [zzzi zeth](#) is licensed in the Public Domain.

6. This work is a derivative of [Anatomy and Physiology](#) by [OpenStax](#) licensed

During the **inflammatory response** (ĩn-FLĂM-ă-tör-ē ri-SPONS), the damaged cells release chemicals, including **histamine** (HIS-tă-mēn). These chemicals cause redness, heat, and increased permeability of blood vessels so fluid leaks into tissues, causing swelling. These chemicals also attract phagocytes and lymphocytes.⁷ See Figure 11.5⁸ for an image of inflammation.

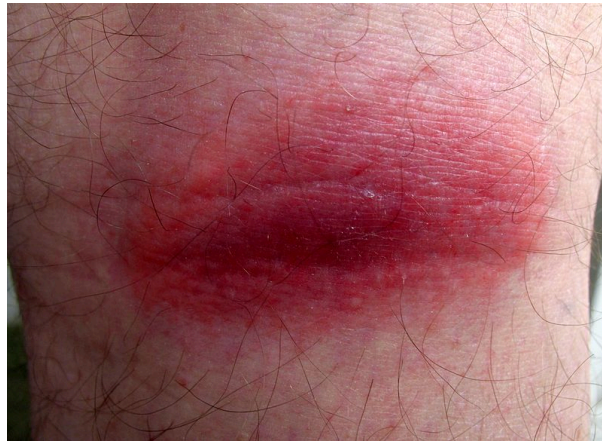

Figure 11.5 Inflammation

FEVER


Fever (FĒ-vör), also referred to as pyrexia, is part of the inflammatory response that extends beyond the site of infection and affects the entire body, resulting in an overall increase in body temperature. Health care providers generally consider a fever to be 100.4°F (38°C) or higher. Fever enhances the innate

under [CC BY 4.0](https://openstax.org/books/anatomy-and-physiology/pages/1-introduction). Access for free at <https://openstax.org/books/anatomy-and-physiology/pages/1-introduction>

7. This work is a derivative of [Anatomy and Physiology](https://openstax.org/books/anatomy-and-physiology/pages/1-introduction) by [OpenStax](https://openstax.org/books/anatomy-and-physiology/pages/1-introduction) licensed under [CC BY 4.0](https://openstax.org/books/anatomy-and-physiology/pages/1-introduction). Access for free at <https://openstax.org/books/anatomy-and-physiology/pages/1-introduction>

8. [“Tickbite_Inflammation_2482a.jpg”](#) by [Túrelío](#) is licensed under [CC BY-SA 3.0-de](#)

immune response by stimulating white blood cells to kill pathogens. The rise in body temperature also inhibits the growth of many pathogens.⁹

View the following supplementary YouTube video¹⁰ on
 nonspecific innate immunity: [Immune System, Part 1: Crash Course Anatomy & Physiology #45](#)

Adaptive Immune Response

The **adaptive immune response** (ă-dăp-tīv ĭ-mūn rĭ-spōns) is activated when the nonspecific, innate immune response is insufficient to control an infection. The adaptive immune response requires the body's exposure to a pathogen to recognize it as a threat in order for it to respond. Exposure can be through direct contact or via immunization. After the adaptive immune system has been exposed to a pathogen, it develops memory cells to recognize this pathogen in the future and quickly mount a defense.¹¹

A **lymphocyte** (LIM-fō-sīt), a specific type of white blood cell, plays a key role

9. This work is a derivative of [Anatomy and Physiology](#) by [OpenStax](#) licensed under [CC BY 4.0](#). Access for free at <https://openstax.org/books/anatomy-and-physiology/pages/1-introduction>

10. CrashCourse. (2015, December 8). *Immune system, Part 1: Crash Course Anatomy & Physiology #45* [Video]. YouTube. All rights reserved. https://youtu.be/GIJK3dwCWCw?si=YFX4Rpb4U8a_dyPS

11. This work is a derivative of [Health Alterations](#) by [Open RN](#) and is licensed under [CC BY 4.0](#)

in the adaptive immune response. There are two main groups of lymphocytes called B cells and T cells, both of which are formed in **bone marrow** (bōn MAR-ō). B cells mature in the bone marrow, and T cells mature in the thymus, the rationale for being called “B” cells and “T” cells. B cells are involved in humoral immunity (i.e., immune functions in the blood and other fluids in the body), and T cells are involved in cell-mediated defenses (i.e., fighting invaders within cells).¹²

HUMORAL IMMUNITY: B CELLS


Humoral immunity (HYŌŌ-mōr-äl ĭ-mū-nĭ-tē) refers to the function of B cells and their production of antibodies. B cells originate and develop in the bone marrow and then migrate in body fluids through the lymph nodes, spleen, and blood to seek out and destroy pathogens in the interstitial spaces. B cells make plasma cells that produce Y-shaped proteins called **antibodies** (ANT-i-bod-ēz) that destroy pathogens based on their antigens. **Antigens** (ĀN-tĭ-jĕnz) are markers that tell the immune system whether something in the body is harmful or not. Antigens are found on viruses, bacteria, cancer cells, and even normal cells of the body. Each antigen has a unique shape that the immune system reads like a nametag to know whether or not it belongs in that person’s body. Antibodies are very specific to the antigens they recognize and destroy. They fit onto the antigen like a key to a lock.¹³

When a B cell finds an abnormal cell with an antigen that it has antibodies for, it binds to it and responds by cloning itself into many B cells and differentiating into plasma cells, which release thousands of antibodies per second to attack the pathogen. Some B cells become memory B cells that are

12. This work is a derivative of *Anatomy and Physiology* by OpenStax licensed under CC BY 4.0. Access for free at <https://openstax.org/books/anatomy-and-physiology/pages/1-introduction>

13. Cleveland Clinic. (2022, August 16). *Antigen*. <https://my.clevelandclinic.org/health/diseases/24067-antigen>

involved in immunological memory to ensure a stronger and faster antibody response if the body is exposed to the same antigen in the future.

View the following supplementary YouTube video¹⁴ on
 adaptive immunity: [Immune System, Part 2: Crash Course Anatomy & Physiology #46](https://youtu.be/2DFN4IBZ3rI?feature=shared)

Passive Immunity

Passive immunity (PĀS-iv im-Ū-nīt-ē) is a type of immunity obtained by receiving antibodies produced by someone else. For example, infants have passive immunity because they are born with antibodies they received through the placenta from their mother. However, these antibodies are unable to create effector cells or memory cells, so it won't remember an antigen if it gets infected again. These antibodies disappear between 6 and 12 months of age. Breast milk also contains antibodies, so babies who are breastfed have passive immunity for a longer period of time.¹⁵

Passive immunization can also be transferred via an injection of antibodies formed by another person or animal. There are five classes of antibodies comprised of the following immunoglobulins: IgG, IgM, IgA, IgD, and IgE. Immunoglobulins provide immediate protection against an antigen, but do not provide long-lasting protection. For example, Hepatitis B Immune

14. CrashCourse. (2015, December 8). *Immune system, Part 2: Crash Course Anatomy & Physiology #46* [Video]. YouTube. All rights reserved. <https://youtu.be/2DFN4IBZ3rI?feature=shared>

15. A.D.A.M. Medical Encyclopedia [Internet]. Atlanta (GA): A.D.A.M., Inc.; c1997-2023. Immune response; [reviewed 2022, Jan 23; cited 2023, Nov 7]. <https://medlineplus.gov/ency/article/000821.htm>

Globulin (HBIG) is administered to individuals who have been exposed to hepatitis B as passive immunization to help fight the infection.¹⁶

CELL-MEDIATED RESPONSE: T CELLS

When nonspecific, innate immunity and humoral immunity are not effective in defending against pathogens or abnormal cells, the body responds with a **cell-mediated response** (Sĕl-mĕd-ē-āt-ed rĭ-spŏns) using lymphocyte T cells to destroy the abnormal cells. There are two major types of T cells called helper T cells and killer T cells¹⁷:

- Helper T cells use chemical messengers to activate the adaptive immune response. They stimulate B cells to make antibodies and help develop the killer T cells.
- Killer T cells, also called natural killer (NK) cells or cytotoxic cells, directly kill cells that have been invaded by a virus or are otherwise abnormal. They also clone themselves into many effector T cells and create memory T cells for immunological memory of the antigen.

See Figure 11.6¹⁸ for a comparison of the function of B cells and cytotoxic T cells. The purple cell is an invading virus. The B cells release antibodies to fight the virus and protect the body's cells from being invaded by the virus. The

16. A.D.A.M. Medical Encyclopedia [Internet]. Atlanta (GA): A.D.A.M., Inc.; c1997-2023. Immune response. <https://medlineplus.gov/ency/article/000821.htm>

17. This work is a derivative of *Anatomy and Physiology* by OpenStax licensed under CC BY 4.0. Access for free at <https://openstax.org/books/anatomy-and-physiology/pages/1-introduction>

18. “General Effector Mechanisms of B and T Cells.png” by מרתה כסלו is licensed under CC BY-SA 4.0

cytotoxic T cells recognize body cells that have been infected by the virus and destroy them.

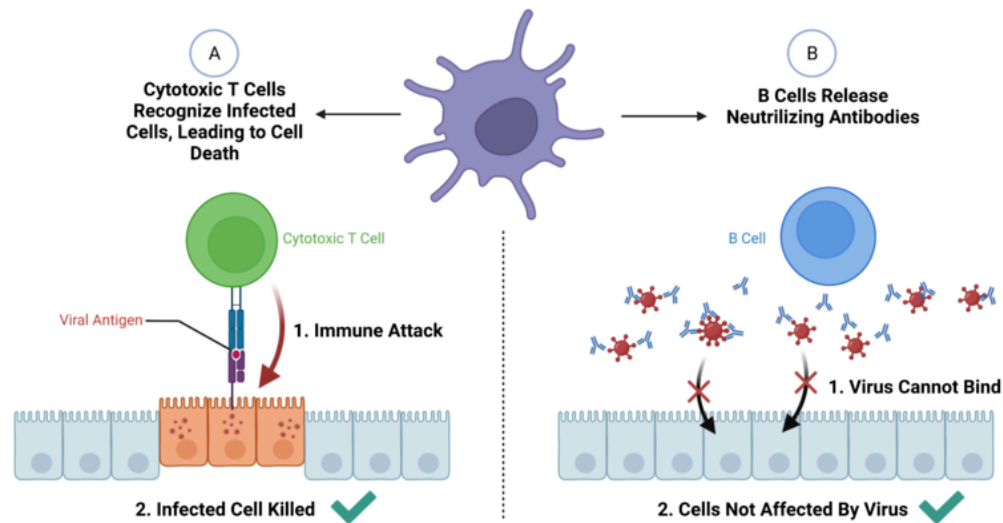


Figure 11.6 Functions of Cytotoxic T Cells and B Cells

Chemical messaging occurs during the immune response and includes cytokines. **Cytokines** (Sĭ-tō-kīnz) are proteins secreted by cells that act as chemical messengers in immune responses. When a pathogen enters the body, the first immune cell to notice the pathogen is like the conductor of an orchestra. That cell directs all the other immune cells by creating and sending out messages (cytokines) to the rest of the organs or cells in the body to respond to and initiate inflammation.¹⁹

See Figure 11.7²⁰ for an illustration of innate immunity and specific adaptive

19. This work is a derivative of *Anatomy and Physiology* by OpenStax licensed under CC BY 4.0. Access for free at <https://openstax.org/books/anatomy-and-physiology/pages/1-introduction>

20. “2211 Cooperation Between Innate and Immune Responses.jpg” by OpenStax is licensed under CC BY 3.0

immunity using an example of a pathogen entering the body through the nose.

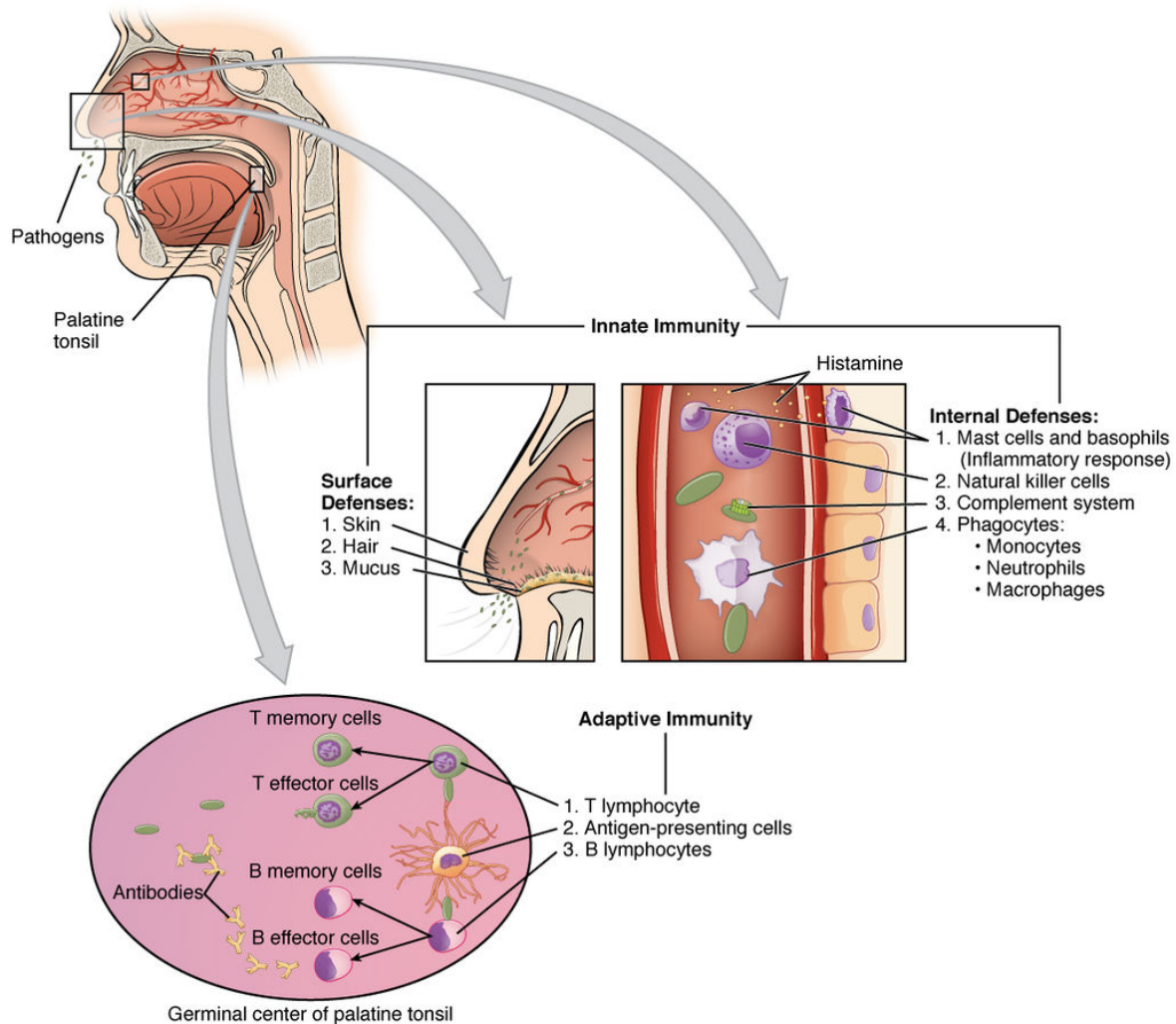


Figure 11.7 Innate Immunity and Specific Adaptive Immunity



View the following YouTube video²¹ on cell-mediated

21. CrashCourse. (2015, December 21). *Immune system, Part 3: Crash*



immune response: [Immune System, Part 3: Crash Course Anatomy & Physiology #47](#)

IMMUNOLOGICAL MEMORY

Immunological memory (im-yŭ-NOL-ŏ-jē- kăl MEM-ŏ-rē) refers to the ability of the adaptive immune response to mount a stronger and faster immune response upon reexposure to a pathogen. Memory B and T cells for each specific pathogen are created that provide long-term protection from reinfection with that pathogen. On reexposure, these memory cells facilitate an efficient and quick immune response. For example, when an individual recovers from chicken pox, the body develops a memory of the varicella-zoster virus that will specifically protect it from reinfection if exposed to the virus again.²²

Acquired immunity refers to immunity that develops with exposure to various antigens as an individual's immune system builds a defense. However, pathogens can mutate and change the shape of their antigens so the

Course Anatomy & Physiology #47 [Video]. YouTube. All rights reserved.
https://youtu.be/rd2cf5hValM?si=sd_XWq6Mn2Sm_Kt1

22. This work is a derivative of [Nursing Fundamentals](#) by [Open RN](#) and is licensed under [CC BY 4.0](#)

immune system can no longer recognize or defend against it.²³ For example, influenza viruses mutate frequently, requiring annual influenza vaccination.

IMMUNIZATION

Immunization (ĩm-yū-nĩ-zā-shŏn)²⁴ is a method to trigger an individual's acquired immune response and prevent future disease. A vaccine is an agent administered by injection, orally, or by nasal spray that provides active acquired immunity to a particular infectious disease. Small doses of a viral antigen are given to activate immunological memory. Memory cells allow the body to react quickly if exposed to the recognized antigen and efficiently defend against the virus.²⁴

STRESS AND THE IMMUNE SYSTEM

Hormones released during the stress response (also known as the “fight or flight” response by the sympathetic nervous system) include epinephrine, cortisol, and corticosteroids. These hormones suppress T cell immune response, which can result in a weakened immune system. Additionally, long-term stress is associated with an increase in stress-related diseases like hypertension and coronary artery disease.²⁵

23. Cleveland Clinic. (2022, August 16). *Antigen*. <https://my.clevelandclinic.org/health/diseases/24067-antigen>

24. A.D.A.M. Medical Encyclopedia [Internet]. Atlanta (GA): A.D.A.M., Inc.; c1997-2023. Immune response; [reviewed 2022, Jan 23; cited 2023, Nov 7]. <https://medlineplus.gov/ency/article/000821.htm>

25. This work is a derivative of Anatomy & Physiology by [OpenStax](#) and is licensed

THE IMMUNE RESPONSE AND CANCER

There are three stages of the immune response to many malignancies²⁶ :

- **Elimination** (ĩ-lĩm-ĩ-nā-shŏn) occurs when the immune response first develops antibodies toward tumor-specific antigens and actively kills most cancer cells.
- **Equilibrium** (ē-kwĩ-lĩb-rē-ŭm) is the period that follows elimination when remaining cancer cells are held in check.
- **Escape** (ěs-kāp) from the immune response occurs because many cancers mutate and no longer express specific antigens for which the immune system responds.

under [CC BY 4.0](https://openstax.org/details/books/anatomy-and-physiology-2e). Access for free at <https://openstax.org/details/books/anatomy-and-physiology-2e>

26. This work is a derivative of Anatomy & Physiology by [OpenStax](https://openstax.org/details/books/anatomy-and-physiology-2e) and is licensed under [CC BY 4.0](https://openstax.org/details/books/anatomy-and-physiology-2e). Access for free at <https://openstax.org/details/books/anatomy-and-physiology-2e>

11.6 Diseases and Disorders of the Lymphatic and Immune System

Immune system disorders occur when the immune response is directed against normal body tissue or is excessive or deficient. For example, an **allergy** (AL-ĕr-jĕ) is an inflammatory response due to a hypersensitivity to a substance that most people's bodies perceive as harmless. Histamine released during the immune response is a primary cause of allergy and anaphylactic shock symptoms. **Autoimmune disease** (OT-ō-im-yŭn diz-ĒZ) is the inability of the body to distinguish its own cells from foreign invaders, producing antibodies that attack its own tissues. **Immunodeficiency** (ĭm-yŭ-nō-dĕ-FISH-ĕn-sĕ) results from a failure or absence of lymphocytes and phagocytes. Immunodeficiencies can be either primary or secondary.¹ These conditions are further discussed in the following subsections.

HYPERSENSITIVITY REACTIONS

The body's immune responses are essential defense mechanisms designed to protect us against threats, including infections and cancer. However, an individual's immune system can have an exaggerated immune response triggered by exposure to a specific antigen, referred to as a **hypersensitivity**

1. This work is a derivative of Health Alterations by [Open RN](#) and is licensed under [CC BY 4.0](#)

(hī-pěr-sĕn-sĭ-TĭV-ĭ-tē) reaction. This kind of exaggerated reaction can damage normal tissues and cause a range of health issues.²

Allergic (AL-ĕr-jĭk) responses are specific types of hypersensitivity reactions that arise when the immune system reacts to allergens. **Allergens** (AL-ĕr-jĕnz) are substances that are generally harmless to most individuals. Common allergens include pollen, dust mites, pet dander, certain foods, and insect venom. When a person with allergies encounters these allergens, their immune system goes into overdrive, releasing histamines and other inflammatory molecules that trigger symptoms such as itching, sneezing, wheezing, hives, or anaphylaxis.

Anaphylaxis (ăn-ă-fĭ-LĂK-sĭs) is a severe, potentially life-threatening allergic reaction that can cause bronchoconstriction and swelling of the throat, leading to obstruction of the airway, as well as decreased cardiac output that can lead to shock. Recognition of early symptoms and signs of anaphylaxis and prompt intervention are crucial. Treatment typically involves the administration of epinephrine to counteract the systemic effects of anaphylaxis and stabilize the patient's condition.³

See Table 11.6 for a summary of hypersensitivity reactions, examples, and treatments.

Table 11.6. Hypersensitivity Reactions⁴

2. This work is a derivative of [Health Alterations](#) by [Open RN](#) and is licensed under [CC BY 4.0](#)
3. This work is a derivative of [Health Alterations](#) by [Open RN](#) and is licensed under [CC BY 4.0](#)
4. This work is a derivative of [Health Alterations](#) by [Open RN](#) and is licensed under [CC BY 4.0](#)

Hypersensitivity Type	Description	Mechanism	Examples	Treatments
Type 1 Hypersensitivity (Immediate)	Rapid and excessive immune responses to harmless antigens (allergens) that lead to allergic reactions.	Upon initial exposure, sensitization occurs with production of IgE antibodies against the allergen. Upon subsequent exposure, the allergen binds to IgE antibodies, triggering the release of inflammatory mediators like histamine.	Inhaled allergens (pollens, animal dander), ingested allergens (foods, drugs), injected allergens (bee venom, drugs), contacted allergens (latex, environmental proteins); anaphylactic reactions can occur.	Antihistamines for allergic symptoms; corticosteroids for severe allergic reactions; epinephrine for anaphylactic reactions.
Type 2 Hypersensitivity (Cytotoxic)	Antibodies target antigens on cell surfaces, leading to the destruction or dysfunction of the affected cells.	Antibodies (IgG, IgM) bind to antigens on cell surfaces, triggering immune-mediated destruction through complement activation or antibody-dependent cell-mediated cytotoxicity.	Incompatible blood transfusion reactions and hemolytic disease of newborn (when Rh+ newborns are born to Rh- mothers who have existing antibodies to Rh+ blood).	Administer compatible blood product transfusions and plasmapheresis, as indicated.
Type 3 Hypersensitivity (Immune Complex)	Immune complexes formed between antibodies and antigens deposit in various tissues, leading to localized inflammation.	Immune complexes attract neutrophils, causing inflammation and tissue damage at the site of deposition.	Systemic lupus erythematosus and rheumatoid arthritis.	Anti-inflammatory medications.

Type 4 Hypersensitivity (Delayed)	Cell-mediated immune responses, mediated by T cells, cause inflammation and tissue damage.	Sensitized T cells recognize antigens and release cytokines that recruit inflammatory cells and induce tissue damage.	Contact dermatitis, tuberculin skin test reactions, and graft rejection.	Corticosteroids for severe reactions.
--	--	---	--	---------------------------------------

Autoimmune Reactions

Autoimmune reactions (ō-tō-ĭ-mūn rē-ăk-shŏns) refer to actions within the body where one's own immune system initiates a response against the body's own healthy cells, tissues, or organs. When the body's immune system is functioning correctly, the body can recognize bacteria, viruses, or any abnormal invader. In autoimmune reactions, the body cannot always distinguish its own healthy cells and begins to target immune actions inappropriately against itself.⁵

Graft Reactions

The transplantation of tissues to replace diseased organs is an important medical therapy used for a variety of diseases and disorders. Adaptive immune responses are major barriers to successful transplantation. **Graft** (grăft) refers to transplanted donated tissue or organs.

Graft rejection (grăft rĭ-jĕk-shŏn) is caused by the patient's adaptive immune response to antigens on the donated graft that are interpreted as "foreign." To help prevent graft rejection, tissue typing (i.e., matching) of the organ donor and the person receiving the organ is performed. The more similar the antigens are between the donor and recipient, the less likely that the organ will be rejected. Recipients of donated grafts must typically take immunosuppressive medications for their lifetime to prevent their immune system from attacking the transplanted tissue.

5. This work is a derivative of [Health Alterations](#) by [Open RN](#) and is licensed under [CC BY 4.0](#)

An opposite type of graft reaction can occur in donated bone marrow transplants called graft-versus-host disease (GVHD). Recall that “graft” refers to transplanted donated tissue or organs, and “host” refers to the tissues of the recipient. During GVHD, the transplanted bone marrow cells mount an immune response against the recipient’s tissues. GVHD occurs because the bone marrow cells being transplanted contain lymphocytes. Because the recipient’s bone marrow and adaptive immune response were destroyed with chemotherapy before receiving the bone marrow transplant, they cannot defend themselves against the attack. Patients undergoing bone marrow transplants receive preventative treatment with immunosuppressive medications for several months after the surgery to prevent GVHD. If GVHD does occur, the patient is treated with increased levels of immunosuppressive medications, as well as corticosteroids.

CANCER

Cancer (KĀN-sŏr) refers to abnormal cells that overgrow and have the ability to invade and harm tissues. **Malignant** (mă-lĭg-nănt) cells differ from benign cells in that malignant cells exhibit uncontrolled growth and rapidly divide, subsequently invading and causing damage to normal functioning cells. Some cancers also disrupt **apoptosis** (ap-ŏp-TŌ-sĭs), programmed cell death to regulate cell population. Malignant cells also have the potential to metastasize, or spread, to different parts of the body. **Benign** (bĭ-nĭn) cells grow and divide in a more controlled manner, remaining localized to a certain area.

Malignant cells are the most dangerous due to their ability to metastasize. When cells **metastasize** (mě-tăs-tă-sĭz), they spread through the blood or lymphatic system. The spread of cancer cells and their rapid replication and invasion in other areas of the body complicate medical treatment, making it

more difficult to rid the body of these abnormal invasive cells.⁶ See Figure 11.8⁷ for an illustration comparing benign and malignant tumors.

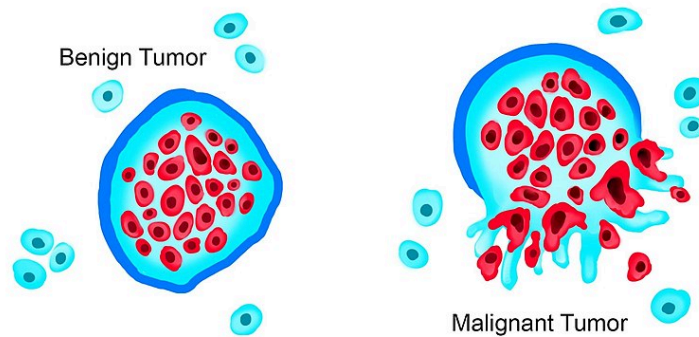


Figure 11.8 Benign and Malignant Tumors

The distinction between benign and malignant growths is also reflected in the associated medical interventions and prognosis. Benign growth is typically managed through close monitoring and/or minimal surgical interventions. For example, a benign tumor may be surgically removed with no further medical treatment required. However, malignant growths require prompt, targeted medical interventions to prevent progression and metastasis of cancer to other areas of the body.⁸

6. This work is a derivative of [Health Alterations](#) by [Open RN](#) and is licensed under [CC BY 4.0](#)

7. [“Tumor_Types_MTK.jpg”](#) by WolfpackBME is licensed under [CC BY-SA 4.0](#)

8. This work is a derivative of [Health Alterations](#) by [Open RN](#) and is licensed under [CC BY 4.0](#)

Metastasis

Metastasis of cancer cells can occur in different parts of the body. See Figure 11.9⁹ for an illustration of metastasis of a primary tumor.

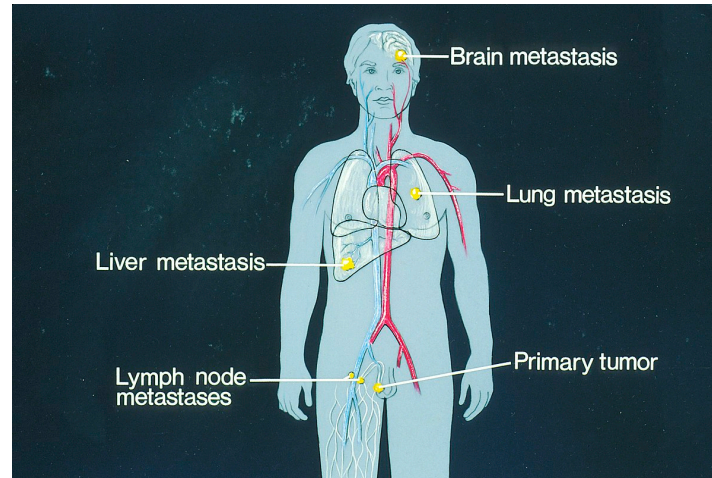


Figure 11.9 Metastasis

Common sites of metastasis include the following areas¹⁰:

- **Lungs** (lŭngz): The lungs are a frequent site of metastasis because they receive a large volume of blood from the body's circulation. Cancer cells circulating in the bloodstream can easily lodge in the small blood vessels of the lungs, leading to secondary tumor formation.
- **Liver** (lĭv-ĕr): The liver plays a significant role in blood filtration, making it another common site for metastasis.
- **Bones** (bŏnz): Many cancers, such as breast, lung, and prostate cancer,

9. "[Sites_of_potential_metastases_illustration.jpg](#)" by unknown author, via [National Cancer Institute](#) is licensed in the [Public Domain](#).

10. This work is a derivative of [Health Alterations](#) by [Open RN](#) and is licensed under [CC BY 4.0](#)

have a tendency to metastasize to the bones.

- **Brain** (brān): Cancer cells can reach the brain through the bloodstream.
- **Lymph Nodes** (limf nōdz): Lymph nodes play a role in filtering lymph. Tumors located in close proximity to the lymph nodes, especially breast, gastrointestinal, urological, gynecological, and some skin cancers, are more likely to spread through the lymphatic system.
- **Small and Large Intestines** (smôl ănd lărj in-TĚS-tĭnz): The small and large intestines, including the colon and rectum, are susceptible to metastasis, particularly in colorectal cancer. Cancer cells from the colon can also spread to nearby lymph nodes and to the liver.
- **Adrenal Glands** (ă-DRĒ-năl glăndz): The adrenal glands that sit atop the kidneys can be affected by metastatic cancer. The adrenal glands have a rich blood supply, making them potential targets for cancer cells circulating in the bloodstream.
- **Skin** (skĭn): Melanoma, a type of skin cancer, has a propensity to spread to other parts of the body, including distant skin sites and internal organs.
- **Ovaries** (Ō-vă-rēz): In women, ovarian metastasis can occur from cancers that have spread through the bloodstream or lymphatic system. Breast, colorectal, and stomach cancers are examples of cancers that can metastasize to the ovaries.
- **Kidneys** (KĭD-nēz): Kidney metastasis can occur when cancer cells from other parts of the body reach the kidneys through the bloodstream. The kidneys filter the blood, making them a potential site for cancer cells to become trapped.

Cancer-Causing Viruses

Some cancers are caused by viruses, such as liver cancer caused by the hepatitis B virus and cervical cancer caused by the **human papilloma virus** (hū-măn pă-pĭ-LŌ-mă vī-rŭs) (**HPV**). Both of these viruses have vaccines available to prevent disease, so vaccination can also help prevent cancer by stimulating the immune response. **Kaposi's sarcoma** (kă-PO-sēz sār-KŌ-mă), caused by the herpes virus, is an example of cancer caused by a virus that is

almost never observed in individuals with strong immune systems. See Figure 11.10¹¹ for an image of Kaposi's sarcoma.

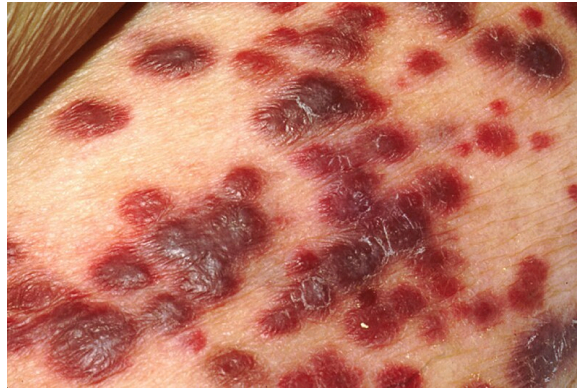

Figure 11.10 Kaposi's Sarcoma

IMMUNODEFICIENCIES

Immunodeficiency (im-yŭ-nō-dě-FISH-ĕn-sē) refers to inadequate immune response caused by immune system dysfunction. Someone who has an impaired or weakened immune system is referred to as **immunocompromised** (im-yū-nō-KŎM-prō-mīzd).

Inherited immunodeficiencies arise from genetic mutations that affect specific components of the immune response. Individuals can also acquire immunodeficiencies, such as acquired immunodeficiency syndrome (AIDS) caused by the human immunodeficiency virus (HIV).¹²

11. "[Kaposi's Sarcoma Lesions.jpg](#)" by OpenStax College is licensed under [CC BY-SA 3.0](#)

12. This work is a derivative of Anatomy & Physiology by [OpenStax](#) and is licensed under [CC BY 4.0](#). Access for free at <https://openstax.org/details/books/anatomy-and-physiology-2e>

Inherited Immunodeficiencies

While many inherited immunodeficiencies exist, the most serious is **severe combined immunodeficiency disease** (sē-vēr kōm-BĪND ĭm-yū-nō-dě-FISH-ĕn-sē dĩ-zēz) (**SCID**). This complex disease is caused by many different genetic defects that result in impaired B cell and T cell functioning of the adaptive immune response. Children with this disease usually die of opportunistic infections within their first year of life unless they receive a bone marrow transplant. **Opportunistic infection** (ōp-ōr-tū-NĪS-tĭk ĭn-FĚK-shōn) are infections that occur more often or are more severe in people with weakened immune systems than in people with healthy immune systems. An example of an opportunistic infection is pneumonia caused by *Candida*, a type of yeast.¹³

Acquired Immunodeficiency

The **human immunodeficiency virus** (hū-măn ĭm-yū-nō-dě-FISH-ĕn-sē vī-rŭs) (**HIV**) can completely wipe out the functioning of an individual's immune system if it progresses to **acquired immunodeficiency syndrome** (ādz āk-wīrd ĭm-yū-nō-dě-FISH-ĕn-sē sĭn-drōm) (**AIDS**). HIV is transmitted through semen, vaginal fluids, and blood. The presence of detectable anti-HIV antibodies in a person's blood indicates a positive HIV test, referred to as **seroconversion** (sē-rō-kōn-VĚR-zhōn).¹⁴

After seroconversion, the amount of HIV circulating in the blood drops and stays at a low level for several years. During this time, the levels of **CD4 T cells** (sē-dē fōr tē sĕlz), helper T cells, decline steadily, until at some point, the

13. This work is a derivative of Anatomy & Physiology by [OpenStax](#) and is licensed under [CC BY 4.0](#). Access for free at <https://openstax.org/details/books/anatomy-and-physiology-2e>

14. This work is a derivative of Anatomy & Physiology by [OpenStax](#) and is licensed under [CC BY 4.0](#). Access for free at <https://openstax.org/details/books/anatomy-and-physiology-2e>

immune response is so weak that opportunistic diseases develop and eventually result in death. Treatment of HIV consists of drugs that target proteins necessary for viral replication but are absent from normal human cells. By targeting the virus itself and sparing the cells, this approach has been successful in significantly prolonging the lives of HIV-positive individuals.¹⁵

LYMPHOMA

Lymphoma (lĭm-FŌ-mă) is cancer that originates from the lymphatic system. There are two main types of lymphoma called Hodgkin lymphoma and non-Hodgkin lymphoma.

In **Hodgkin lymphoma** (HŎJ-kĭn lim-FŌ-mă), lymphocytes grow out of control, causing swollen lymph nodes and growths throughout the body. Treatments for Hodgkin lymphoma include chemotherapy, radiation therapy, targeted therapy (i.e., drugs or other substances that attack specific cancer cells with less harm to normal cells), and cancer immunotherapy. Hodgkin lymphoma can usually be cured if it is found and treated early.¹⁶

Non-Hodgkin lymphoma (nŏn-HŎJ-kĭn lim-FŌ-mă) (**NHL**) is a diverse group of blood cancers that includes all types of lymphoma except Hodgkin's lymphomas. NHL is much less predictable than Hodgkin lymphoma and is

15. This work is a derivative of Anatomy & Physiology by [OpenStax](#) and is licensed under [CC BY 4.0](#). Access for free at <https://openstax.org/details/books/anatomy-and-physiology-2e>

16. MedlinePlus [Internet]. Bethesda (MD): National Library of Medicine (US); [updated 2022, Apr. 4]. Hodgkin lymphoma; [cited 2023, Nov. 7]. <https://medlineplus.gov/hodgkinlymphoma.html>

more likely to metastasize. The prognosis depends on the type of white blood cell, the stage of the cancer, and the treatment options.¹⁷

17. National Cancer Institute. (2023, May 18). *Non-Hodgkin lymphoma treatment (PDQ) – Health professional version*. National Institutes of Health.
<https://www.cancer.gov/types/lymphoma/hp/adult-nhl-treatment-pdq>

11.7 Medical Specialists, Diagnostic Testing, and Procedures Related to the Lymphatic and Immune Systems

MEDICAL SPECIALISTS

Immunology (im-yŭ-NOL-ŏ-jē) is the study of disorders of the immune system. An **immunologist** (im-ŭ-NŎL-ŏ-jĭst) is a physician who specializes in the study and treatment of immune system disorders.

An **allergist** (AL-ĕr-jĭst) is a physician who specializes in the study and treatment of allergies.

- ▶ Read more about careers in allergy and immunology on the [American Academy of Allergy Asthma and Immunology's Careers web page](#).

DIAGNOSTIC TESTING

Lymph Node Biopsy

During a lymph node biopsy, lymph node tissue is removed for examination under a microscope by a pathologist to diagnose medical conditions like infection or cancer. There are different types of lymph node biopsies, including the following¹:

- **Needle biopsy** (NĒ-dīl BĪ-öp-sē): After applying local anesthesia, a radiologist inserts a needle into a lymph node using ultrasound or CT scan to find the node.
- **Laparoscopic lymph node biopsy** (lăp-ăr-ö-SKÖ-pĭk limf nōd BĪ-öp-sē): After the patient is placed under general anesthesia, a small tube with a light and camera is inserted through a small incision. One or more other incisions will also be made for the insertion of tools to locate and remove the lymph node.
- **Open lymph node biopsy** (Ō-pĕn limf nōd BĪ-öp-sē): Surgery is performed to remove all or part of a lymph node, typically performed if the lymph node is large enough to be felt on physical exam.
- **Sentinel lymph node biopsy** (SĔN-tĭ-nĕl limf nōd BĪ-öp-sē): For some cancers, a sentinel lymph node biopsy is performed to find the best lymph nodes to biopsy. A tiny amount of a radioactive tracer or dye is injected in the area of the tumor. The tracer or dye flows into the nearest lymph nodes, the first lymph nodes to which a cancer may spread. These lymph nodes, called the sentinel nodes, are removed and analyzed.

Skin Testing for Allergies

Skin testing for allergies is performed by an immunologist or allergist to

1. Medline Plus. (2022). *Lymph node biopsy*. <https://medlineplus.gov/ency/article/003933.htm>

identify allergens in Type I hypersensitivity. In skin testing, allergen extracts are injected into the patient's epidermal layer of the skin. The development of a wheal at the site of injection indicates a positive result. Based on the test results, individuals should avoid allergens that trigger a Type I hypersensitivity reaction. See Figure 11.11² for an image of allergy testing with wheals indicating positive responses to an allergen.

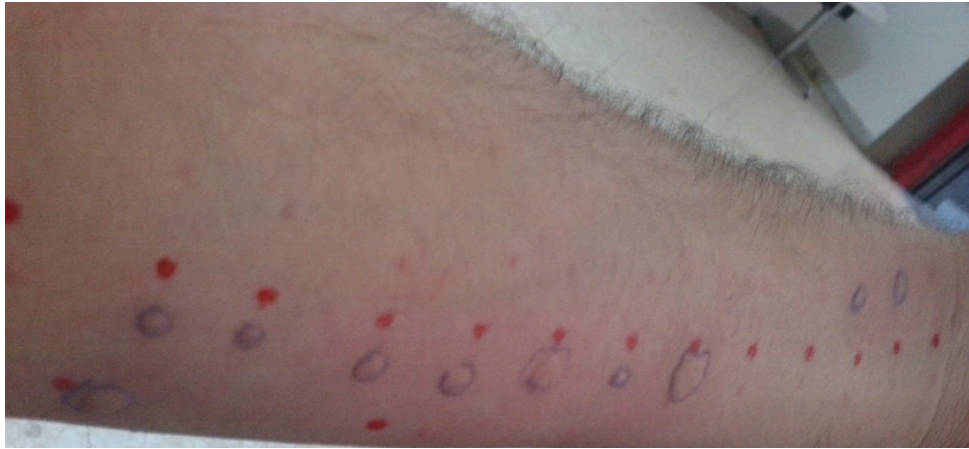

Figure 11.11 Allergy Testing

Tissue Typing

Tissue typing (TĪSH-ū tī-pĭng) ensures that an organ from a donor will be compatible with its recipient. The process starts with identifying the unique **human leukocyte antigens** (hyū-măn lū-kō-sīt ĀN-tĭ-jĕnz) (**HLAs**) for the organ donor and recipient, either from blood or tissue. HLAs are an important part of the immune system's response to foreign substances and act as a barcode to distinguish “self” from “non-self” — the latter resulting in rejection of the transplanted organ.³

2. “[Another_allergy_skin_testing.jpg](#)” by [Ismael Olea](#) is licensed under [CC BY 4.0](#)

3. Brunk-Young, J. (2021, April 30). *What is tissue typing for transplant?* The Ohio

To date, more than 35,000 variations of the HLA protein have been identified. This makes it extremely difficult to find HLA-matched donors for transplant recipients. Half of a person's antigens are inherited from their mother and half from their father, so the more similar the antigen patterns are from two people, the more likely it is that those people are related. Identical twins have the same pattern, and brothers and sisters have a 1-in-4 chance of having an identical match.⁴

PROCEDURES RELATED TO THE LYMPHATIC AND IMMUNE SYSTEM

Splenectomy

Splenectomy (splĕ-NĔK-tŏ-mĕ) refers to surgical removal of a diseased or damaged spleen. Because of the important role the spleen plays in the immune system, individuals who have had a splenectomy are at increased risk of infection for the remainder of their lives.

Tonsillectomy

The tonsils help protect against infections. However, abnormally large tonsils may be removed if they contribute to recurrent cases of **tonsillitis** (tŏn-sĭl-ĭ-tĭs) or breathing problems, especially at night. During a **tonsillectomy** (tŏn-sĭl-ĔK-tŏ-mĕ), the patient is placed under general anesthesia and the tonsils are

State University Wexner Medical Center. <https://wexnermedical.osu.edu/blog/tissue-typing>

4. Brunk-Young, J. (2021, April 30). *What is tissue typing for transplant?* The Ohio State University Wexner Medical Center. <https://wexnermedical.osu.edu/blog/tissue-typing>

removed by a surgeon. The adenoid, located behind the nasal cavity, may also be removed during this surgery and is referred to as an **adenoidectomy** (ăd-ě-noid-ĔK-tŏ-mē).⁵

5. Medline Plus. (2023). *Tonsillectomy*. <https://medlineplus.gov/ency/article/003013.htm>

11.8 Lymphatic and Immune System Learning Activities

Interactive Learning Activity: Practice labelling the parts of the lymphatic system using this drag and drop activity.



An interactive H5P element has been excluded from this version of the text. You can view it online here:

<https://wtcs.pressbooks.pub/medterm/?p=4761#h5p-212>

Interactive Learning Activity: Study medical terms related to the lymphatic and immune system that are discussed in this chapter using these flashcards.



An interactive H5P element has been excluded from this version of the text. You can view it online here:

<https://wtcs.pressbooks.pub/medterm/?p=4761#h5p-185>

Interactive Learning Activity: Test your knowledge on concepts related to the immune system.



An interactive H5P element has been excluded from this version of the text. You can view it online here:

<https://wtcs.pressbooks.pub/medterm/?p=4761#h5p-19>

Interactive Learning Activity: Using the sample documentation provided, drag the terms on the right to their appropriate spaces within the documentation.



An interactive H5P element has been excluded from this version of the text. You can view it online here:

<https://wtcs.pressbooks.pub/medterm/?p=4761#h5p-16>

Interactive Learning Activity: Using the sample documentation provided, drag the terms on the right to their appropriate spaces within the documentation.



An interactive H5P element has been excluded from this version of the text. You can view it online here:

<https://wtcs.pressbooks.pub/medterm/?p=4761#h5p-17>

Interactive Learning Activity: Using the sample documentation provided, drag the terms on the right to their appropriate spaces within the documentation.



An interactive H5P element has been excluded from this version of the text. You can view it online here:

<https://wtcs.pressbooks.pub/medterm/?p=4761#h5p-18>



Interactive Learning Activity: Practice identifying and defining word parts for terms discussed in this chapter.



An interactive H5P element has been excluded from this version of the text. You can view it online here:

<https://wtcs.pressbooks.pub/medterm/?p=4761#h5p-202>

- ▶ You can also print this as a [Chapter 11 Practice Worksheet](#) and check your answers with this [Answer Key PDF](#).

11.9 Glossary

Acquired immunodeficiency syndrome (ādz āk-wīrd ĩm-yū-nō-dě-FISH-ěn-sē sĭn-drōm) (AIDS): A disease caused by HIV leading to a significant weakening of the immune system. ([Chapter 11.6](#))

Adaptive immune response (ă-dăp-tĭv ĩ-mūn rĭ-spōns): It is activated when the innate immune response is insufficient to control an infection. It requires exposure to a pathogen to recognize it as a threat, leading to the development of memory cells for future defense. ([Chapter 11.5](#))

Adenoidectomy (ăd-ě-noid-ĖK-tō-mē): The surgical removal of the adenoid, which is located behind the nasal cavity, often performed along with a tonsillectomy. ([Chapter 11.7](#))

Allergens (AL-ěr-jěnz): Substances that are usually harmless but can cause allergic responses in some people. Common allergens include pollen, dust mites, pet dander, certain foods, and insect venom. ([Chapter 11.6](#))

Allergist (AL-ěr-jĭst): A physician specializing in the study and treatment of allergies. ([Chapter 11.7](#))

Allergy (AL-ěr-jē): An inflammatory response due to hypersensitivity to a substance that most people's bodies perceive as harmless, such as pollen or certain foods. Histamine release during the immune response is a primary cause of allergy symptoms. ([Chapter 11.6](#))

Anaphylaxis (ăn-ă-fĭ-LĀK-sĭs): A severe, potentially life-threatening allergic reaction. Treatment often involves epinephrine administration. ([Chapter 11.6](#))

Antibodies (ANT-i-bod-ēz): Proteins that are very specific to the antigens they recognize and destroy, fitting onto the antigen like a key to a lock. ([Chapter 11.5](#))

Antigens (ĂN-tĭ-jěnz): Markers that tell the immune system whether something in the body is harmful or not, found on viruses, bacteria, cancer cells, and even normal cells of the body. ([Chapter 11.5](#))

Apoptosis (ap-ōp-TŌ-sĭs): Programmed cell death that is disrupted in some cancers, allowing malignant cells to avoid natural cell death and continue uncontrolled growth. ([Chapter 11.6](#))

Autoimmune disease (OT-ō-im-yūn diz-ĒZ): The inability of the body to distinguish its own cells from foreign invaders, resulting in the production of antibodies that attack its own tissues. ([Chapter 11.6](#))

Autoimmune reactions (ō-tō-ī-mūn rē-āk-shōns): Responses within the body where the immune system mistakenly initiates a response against the body's own healthy cells, tissues, or organs, failing to distinguish them from harmful invaders. ([Chapter 11.6](#))

B cells (B sēlz): A type of lymphocyte that plays a significant role in the humoral immune response. ([Chapter 11.4](#))

Benign (bī-nīn): Cells that overgrow and divide in a controlled manner, remaining localized to a certain area. They are less dangerous compared to malignant cells because they do not metastasize. ([Chapter 11.6](#))

Bone marrow (bōn MAR-ō): The primary lymphoid organ where B cells and T cells mature and are selected to attack pathogens. All blood cells, including lymphocytes, are formed in the red bone marrow. ([Chapter 11.5](#))

Cancer (KĀN-sōr): Abnormal cells that overgrow and have the ability to invade and harm tissues. Malignant cells differ from benign cells in that they exhibit uncontrolled growth and have the potential to metastasize. ([Chapter 11.6](#))

CD4 T cells (sē-dē fōr tē sēlz): Helper T cells whose levels decline steadily in HIV-positive individuals, leading to weakened immune response. ([Chapter 11.6](#))

Cell-mediated response (Sēl-mēd-ē-āt-ed rī-spōns): An immune response that involves T cells destroying abnormal cells when nonspecific innate immunity and humoral immunity are not effective. ([Chapter 11.5](#))

Chyle (kīl): A milky bodily fluid consisting of lymph and emulsified fats, absorbed from the intestines during digestion. ([Chapter 11.4](#))

Cytokines (Sī-tō-kīnz): Proteins secreted by cells that act as chemical messengers in immune responses, directing immune cells to respond to and initiate inflammation. ([Chapter 11.5](#))

Equilibrium (ē-kwī-līb-rē-ŭm): In a medical context, it often refers to a state of balance or stability, particularly in physiological or biochemical processes. ([Chapter 11.5](#))

Fever (FĒ-vōr): A part of the inflammatory response that results in an overall

increase in body temperature, enhancing the innate immune response by stimulating white blood cells to kill pathogens. ([Chapter 11.5](#))

Graft (grăft): Transplanted tissue or organ. ([Chapter 11.6](#))

Graft rejection (grăft rǐ-jěk-shǒn): A complication after graft surgery caused by the recipient's immune response to antigens on the donated graft. ([Chapter 11.6](#))

Histamine (HIS-tǎ-mēn): A chemical released during the inflammatory response, causing increased permeability of blood vessels, redness, heat, and swelling. ([Chapter 11.5](#))

Hodgkin lymphoma (HÖJ-kǐn lim-FŌ-mǎ): Cancer originating from the lymphatic system, characterized by out-of-control growth of lymphocytes, causing swollen lymph nodes and growths throughout the body. ([Chapter 11.6](#))

Human immunodeficiency virus (hū-mǎn ĭm-yū-nō-dě-FISH-ě̃n-sē vī-rŭs) (HIV): A virus that can lead to acquired immunodeficiency syndrome (AIDS) and severely impair the immune system. ([Chapter 11.6](#))

Human leukocyte antigens (hyū-mǎn lū-kō-sīt ĀN-tǐ-jěnz) (HLAs): Proteins that are part of the immune system's response to foreign substances and help distinguish "self" from "non-self." ([Chapter 11.7](#))

Human papilloma virus (hū-mǎn pǎ-pǐ-LŌ-mǎ vī-rŭs) (HPV): A virus that can cause cervical cancer, with vaccines available for prevention. ([Chapter 11.6](#))

Humoral immunity (HYŌŌ-mǒr-ǎl ĭ-mū-nǐ-tē): Part of the immune response that refers to the function of B cells and their production of antibodies that target antigens. ([Chapter 11.5](#))

Hypersensitivity (hī-pěr-sě̃n-sǐ-TĪV-ĭ-tē): An exaggerated immune response triggered by exposure to a specific antigen, which can damage normal tissues and cause a range of health issues. ([Chapter 11.6](#))

Immune system (ĭ-MŪN SĪS-tēm): A complex collection of cells and organs that destroys or neutralizes pathogens, preventing infection, disease, or death. ([Chapter 11.4](#))

Immunization (ĭm-yū-nǐ-zā-shǒn): A method to trigger an individual's acquired immune response and prevent future disease, often through the administration of a vaccine. ([Chapter 11.5](#))

Immunocompromised (ĩm-yũ-nō-KŎM-prō-mĩzd): Someone with an impaired or weakened immune system. ([Chapter 11.6](#))

Immunodeficiency (ĩm-yũ-nō-dě-FISH-ěn-sē): Inadequate immune response due to immune system dysfunction. ([Chapter 11.6](#))

Immunological memory (ĩm-yũ-NOL-ŏ-jē- kǎl MEM-ŏ-rē): The adaptive immune response's ability to mount a stronger and faster response upon reexposure to a pathogen, with memory B and T cells providing long-term protection. ([Chapter 11.5](#))

Immunologist (ĩm-yũ-NŎL-ŏ-jĩst): A physician who specializes in the diagnosis and treatment of immune system disorders. ([Chapter 11.7](#))

Immunology (ĩm-yũ-NŎL-ŏ-jē): The study of disorders of the immune system. ([Chapter 11.7](#))

Inflammation (ĩn-flǎ-MĀ-shŏn): A localized physical condition in which part of the body becomes reddened, swollen, hot, and often painful, especially as a reaction to injury or infection. ([Chapter 11.5](#))

Inflammatory response (ĩn-FLĀM-ǎ-tŏr-ē ri-SPONS): A biological response to harmful stimuli, such as pathogens or damaged cells, characterized by redness, swelling, heat, and pain. ([Chapter 11.5](#))

Innate immune response (ĩn-NĀT i-MŪN ri-SPONS): A nonspecific defense mechanism that begins immediately or within hours of an antigen's appearance in the body. ([Chapter 11.5](#))

Interstitial space (ĩn-těr-STISH-ǎl spās): The space between individual cells in the tissues. ([Chapter 11.4](#))

Kaposi's sarcoma (kǎ-PO-sēz sār-KŎ-mǎ): A cancer caused by the herpes virus, typically observed in individuals with weakened immune systems. ([Chapter 11.6](#))

Laparoscopic lymph node biopsy (lǎp-ǎr-ŏ-SKŎ-pĩk limf nŏd Bĩ-ŏp-sē): A minimally invasive procedure performed under general anesthesia, where a small tube with a light and camera is used to remove lymph node tissue. ([Chapter 11.7](#))

Lymph (lĩmf): A clear-to-white fluid that transports immune system cells, dietary lipids, and fat-soluble vitamins absorbed in the small intestine. ([Chapter 11.4](#))

Lymphatic system (lĩmf-ǎ-TĩK sĩs-tũm): A network of organs, lymph nodes,

lymph ducts, and lymph vessels that produce and transport lymph from tissue spaces to the bloodstream and is a major part of the body's immune system. ([Chapter 11.4](#))

Lymphedema (limf-e-DĒ-ma): Inappropriate accumulation of fluid in interstitial spaces, often caused by damage to the lymphatic system. ([Chapter 11.4](#))

Lymph nodes (limf nōdz): Small bean-shaped organs located throughout the lymphatic system that store immune system cells and filter lymph fluid to remove foreign material. ([Chapter 11.4](#), [Chapter 11.6](#))

Lymphocyte (LIM-fō-sīt): A type of white blood cell in the vertebrate immune system. ([Chapter 11.4](#), [Chapter 11.5](#))

Lymphoma (līm-FŌ-mă): Cancer that originates from the lymphatic system. ([Chapter 11.6](#))

Malignant (mă-līg-nănt): Malignant cells exhibit uncontrolled growth and rapidly divide, subsequently invading and causing damage to normal functioning cells. ([Chapter 11.6](#))

Metastasize (mě-tăs-tă-sīz): The spread of malignant cells through the blood or lymphatic system and invasion in other areas of the body. ([Chapter 11.6](#))

Needle biopsy (NĒ-dīl BĪ-ōp-sē): A procedure where a needle is inserted into a lymph node, typically under local anesthesia and guided by ultrasound or CT scan, for tissue examination. ([Chapter 11.7](#))

Non-Hodgkin lymphoma (nōn-HŎJ-kīn lim-FŌ-mă) (NHL): A diverse group of blood cancers that includes all types of lymphoma except Hodgkin's lymphomas, less predictable than Hodgkin lymphoma, and more likely to metastasize. ([Chapter 11.6](#))

Open lymph node biopsy (Ō-pěn limf nōd BĪ-ōp-sē): A surgical procedure to remove all or part of a lymph node, usually performed if the lymph node is large enough to be felt on physical exam. ([Chapter 11.7](#))

Opportunistic infection (ōp-ōr-tū-NĪS-tīk ĭn-FĚK-shŏn): Infections that occur more often or are more severe in people with weakened immune systems. ([Chapter 11.6](#))

Passive immunity (PĀS-iv im-Ū-nīt-ē): A type of immunity obtained by receiving antibodies produced by someone else, such as through the

placenta from the mother to the infant or via injection of antibodies. ([Chapter 11.5](#))

Pathogens (PĀTH-ō-jěnz): Bacteria, viruses, or other microorganisms that can cause infection and disease. ([Chapter 11.5](#))

Phagocytosis (făg-ō-sī-TŌ-sīs): The process by which a cell uses its plasma membrane to engulf a large particle, forming an internal compartment known as a phagosome. ([Chapter 11.5](#))

Sentinel lymph node biopsy (SĚN-tĩ-nělimf nōd BĪ-ōp-sē): A procedure used to find the best lymph nodes to biopsy, involving the injection of a radioactive tracer or dye near the tumor. ([Chapter 11.7](#))

Seroconversion (sē-rō-kōn-VĚR-zhōn): The presence of detectable anti-HIV antibodies in a person's blood, indicating a positive HIV test. ([Chapter 11.6](#))

Severe combined immunodeficiency disease (sē-vēr kōm-BĪND ĩm-yū-nō-dě-FISH-ěn-sē dĩ-zēz) (SCID): A serious disease caused by genetic defects leading to impaired B cell and T cell functioning. ([Chapter 11.6](#))

Spleen (splēn): An organ in the upper far left part of the abdomen, to the left of the stomach, which filters blood and is involved in immune response. ([Chapter 11.4](#))

Splenectomy (splě-NĚK-tō-mē): The surgical removal of a diseased or damaged spleen. Individuals who have had a splenectomy are at increased risk of infection for the remainder of their lives due to the spleen's role in the immune system. ([Chapter 11.7](#))

T cells (T sěls): A type of lymphocyte involved in cell-mediated immunity. ([Chapter 11.4](#))

Thymus gland (THĪ-mūs gland): A specialized primary lymphoid organ of the immune system where T cells mature. ([Chapter 11.4](#))

Tissue typing (TĪSH-ū tī-pǐng): A process to ensure organ compatibility between a donor and recipient, involving the identification of unique human leukocyte antigens (HLAs). ([Chapter 11.7](#))

Tonsillectomy (tōn-sīl-ĚK-tō-mē): The surgical removal of the tonsils, often performed to address recurrent cases of tonsillitis or breathing issues. ([Chapter 11.7](#))

Tonsillitis (tōn-sīl-Ī-tīs): Inflammation of the tonsils, often due to infection. ([Chapter 11.7](#))

Tonsils (TŎN-sĭls): A pair of soft tissue masses located at the rear of the throat, part of the immune system. ([Chapter 11.4](#))

PART XII

CHAPTER 12 DIGESTIVE SYSTEM TERMINOLOGY

12.1 Digestive System Introduction

Learning Objectives


- Apply the rules of medical language to build, analyze, spell, pronounce, abbreviate, and define terms as they relate to the digestive system
- Identify meanings of key word components of the digestive system
- Categorize diagnostic, therapeutic, procedural, or anatomic terms related to the digestive system
- Use terms related to the digestive system
- Use terms related to the diseases and disorders of the digestive system

Introduction to the Digestive System

The function of the digestive system is to break down the foods you eat, release their nutrients, and absorb those nutrients into the body. The digestive system is continually at work, yet people seldom appreciate the complex tasks it performs until something malfunctions. Consider what happens when you eat an apple. You enjoy the apple's taste as you chew it, but in the hours that follow, unless something goes amiss and you get a stomachache, you don't notice your digestive system is working. You may be working, studying, or sleeping, having forgotten all about the apple, but your

stomach and intestines are busy digesting it. By the time any waste material is excreted, the body has absorbed all the nutrients it can use from the apple. In short, whether you pay attention or not, the organs of the digestive system perform their specific functions, allowing you to use the food you eat to provide energy for your daily activities.¹

This chapter will review common word components related to the digestive system to assist learners in analyzing, building, and defining medical terms. Other terms, whose definitions cannot be easily built from word components, will be described in context based on the anatomy and physiology of the digestive system and common diseases and disorders. Medical specialists, diagnostic tests, and procedures related to the digestive system will also be discussed.

View a supplementary YouTube video² overview of the
 digestive system from TED-Ed: [How your digestive system works – Emma Bryce](https://youtu.be/Og5xAdC8EUI)

1. This work is a derivative of Anatomy & Physiology by [OpenStax](https://openstax.org/details/books/anatomy-and-physiology-2e) and is licensed under [CC BY 4.0](https://creativecommons.org/licenses/by/4.0/). Access for free at <https://openstax.org/details/books/anatomy-and-physiology-2e>
2. TED-Ed. (2017, December 14). *How your digestive system works – Emma Bryce* [Video]. YouTube. All rights reserved. <https://youtu.be/Og5xAdC8EUI?si=883ROcHlXHlj9NE3>

12.2 Word Components Related to the Digestive System

This section will describe common word components related to the digestive system. These word components help build definitions for many medical terms. Other common prefixes are described in [Chapter 1.3](#), and common suffixes are described in [Chapter 1.5](#).

COMMON PREFIXES RELATED TO THE DIGESTIVE SYSTEM

- **dys-**: Painful, abnormal, difficult, labored
- **endo-**: Within, in
- **hemi-**: Half
- **sub-**: Under, below

COMMON WORD ROOTS WITH A COMBINING VOWEL RELATED TO THE DIGESTIVE SYSTEM

- **abdomin/o**: Abdomen, abdominal

- **an/o**: Anus
- **antr/o**: Antrum
- **append/o**: Appendix
- **appendic/o**: Appendix
- **cec/o**: Cecum
- **celi/o**: Abdomen, abdominal cavity
- **cheil/o**: Lip
- **chol/e**: Gall, bile
- **cholangi/o**: Bile duct
- **choledoch/o**: Common bile duct
- **col/o**: Colon
- **colon/o**: Colon
- **diverticul/o**: Diverticulum
- **duoden/o**: Duodenum
- **enter/o**: Intestine
- **esophag/o**: Esophagus
- **gastr/o**: Stomach
- **gingiv/o**: Gum
- **gloss/o**: Tongue
- **hepat/o**: Liver
- **herni/o**: Hernia, protrusion of an organ through a membrane or cavity wall
- **ile/o**: Ileum
- **jejun/o**: Jejunum
- **lapar/o**: Abdomen, abdominal cavity
- **lingu/o**: Tongue
- **or/o**: Mouth
- **palat/o**: Palate
- **pancreat/o**: Pancreas
- **peritone/o**: Peritoneum
- **polyp/o**: Polyp, small growth
- **proct/o**: Rectum
- **pylor/o**: Pylorus, pyloric sphincter
- **rect/o**: Rectum
- **sial/o**: Saliva, salivary gland

- **sigmoid/o**: Sigmoid colon
- **steat/o**: Fat
- **stomat/o**: Mouth
- **uvul/o**: Uvula
- **xer/o**: Dryness

COMMON SUFFIXES RELATED TO THE DIGESTIVE SYSTEM

- **-ac**: Pertaining to
- **-al**: Pertaining to
- **-cele**: Hernia, protrusion
- **-centesis**: Surgical puncture to aspirate fluid
- **-eal**: Pertaining to
- **-ectomy**: Excision
- **-gram**: The record, radiographic image
- **-graph**: Instrument used to record
- **-graphy**: Process of recording
- **-ia**: Condition of, diseased state, abnormal state
- **-iasis**: Condition
- **-ic**: Pertaining to
- **-itis**: Inflammation
- **-lith**: Stone
- **-logist**: Specialist who studies and treats
- **-logy**: Study of
- **-malacia**: Softening
- **-megaly**: Enlargement
- **-oma**: Tumor
- **-osis**: Abnormal condition
- **-pathy**: Disease
- **-pepsia**: Digestion

- **-phagia:** Eating or swallowing
- **-plasty:** Surgical repair
- **-ptosis:** Prolapse, drooping
- **-rrhaphy:** Suturing, repairing
- **-rrhea:** Flow, discharge
- **-scope:** Instrument used for visualization
- **-scopy:** Process of viewing, visualization
- **-stomy:** Creation of an artificial opening
- **-tomy:** Incision, cut into

12.3 Examples of Digestive Terms Easily Defined By Their Word Components

Here are examples of common medical terms related to the digestive system that can be easily defined by breaking the terms into their word components.

Dysphagia

1. Break down the medical term into word components:
Dys/phagia
2. Label the word components: **Dys** = P; **phagia** = S
3. Define the word components: **Dys** = difficult, abnormal, or painful; **phagia** = swallowing or eating
4. Create a final definition of the medical term: **Difficulty swallowing**

Gastritis

1. Break down the medical term into word components:
Gastr/itis
2. Label the word components: **Gastr** = WR; **itis** = S
3. Define the word components: **Gastr** = stomach; **itis** = inflammation

4. Create a final definition of the medical term:
Inflammation of the stomach

Hepatomegaly

1. Break down the medical term into word components:
Hepat/o/megaly
2. Label the word components: **Hepat** = WR; **o** = CV; **megaly** = S
3. Define the word components: **Hepat** = liver; **megaly** = enlarged
4. Create a final definition of the medical term: **Enlarged liver**



Interactive Learning Activity: Practice defining and pronouncing digestive system medical terms by breaking them down into word parts.



An interactive H5P element has been excluded from this version of the text. You can view it online here:

<https://wtcs.pressbooks.pub/medterm/?p=4319#h5p-108>

- ▶ You can also print these flashcard activities as a [Chapter 12 Student Companion Worksheet](#) and check your answers with this [Answer Key](#).

12.4 Anatomy of the Digestive System

Digestion (dī-JĔS-tĭon) is the process by which food is broken down into absorbable units. This section will provide an overview of the anatomy of the digestive system, including the mouth, tongue, salivary glands, pharynx, esophagus, stomach, small intestine, and large intestine, as well as the accessory organs of the liver, pancreas, and gallbladder. See Figure 12.1¹ for an illustration of digestive system organs.

1. "abe85277d60c52f85be133e1b5ddc40aea009e1c.jpg" by J. Gordon Betts, et al. is licensed under CC BY 4.0. Access for free at <https://openstax.org/books/anatomy-and-physiology-2e/pages/23-1-overview-of-the-digestive-system>

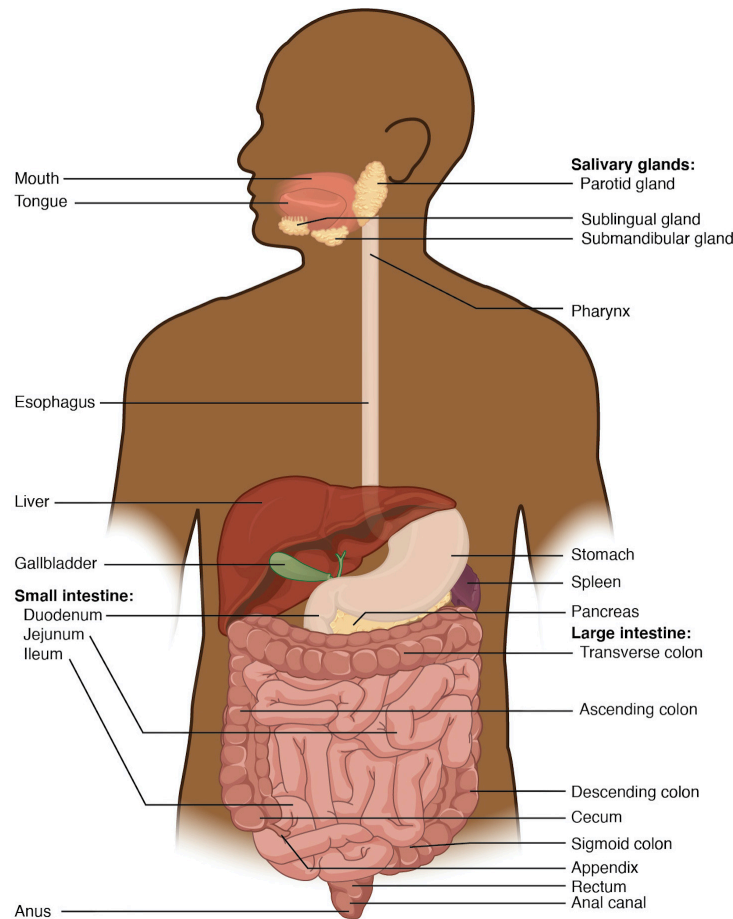


Figure 12.1 Digestive System

The **peritoneum** (pĕr-ĭ-tō-NĒ-ŭm) is the serous membrane lining the cavity of the abdomen and covering the abdominal organs. **Peritonitis** (per-ĭt-ŏ-NĪT-ĭs) refers to inflammation of the peritoneum. Read more about peritonitis in the [“Diseases and Disorders of the Digestive System”](#) section.

MOUTH

The mouth, cheeks, tongue, and palate form the **oral cavity** (ŌR-ăl KAV-ĭ-tē).

See Figure 12.2² for an illustration of the oral cavity. If you run your tongue along the roof of your mouth, you'll notice the roof of the mouth has an arch called a **hard palate** (HARD PAL-āt). The anterior region of the palate serves as a septum (i.e., wall) between the oral and nasal cavities, as well as a rigid shelf against which the tongue can push food when swallowing. The hard palate ends in the posterior oral cavity where the tissue becomes fleshier. This part of the palate, known as the **soft palate** (SOFT PAL-āt), is composed mainly of skeletal muscle that can be manipulated for actions like swallowing or singing.³

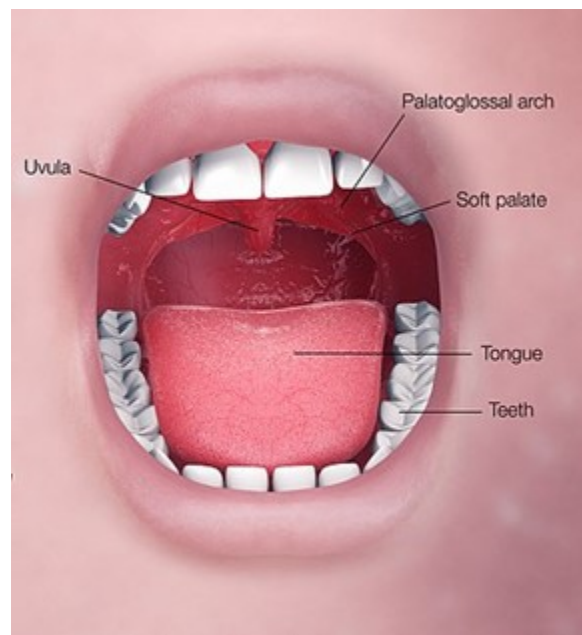


Figure 12.2 Oral Cavity

A fleshy extension of tissue called the **uvula** (YŪ-vyū-lă) drops down from the

2. This image is a derivative of “[3D_Medical_Animation_Oral_Cavity.jpg](https://www.scientificanimations.com)” by <https://www.scientificanimations.com> and is licensed under [CC BY-SA 4.0](https://creativecommons.org/licenses/by-sa/4.0/)
3. This work is a derivative of [Anatomy and Physiology](https://openstax.org/books/anatomy-and-physiology/pages/1-introduction) by [OpenStax](https://openstax.org/books/anatomy-and-physiology/pages/1-introduction) licensed under [CC BY 4.0](https://creativecommons.org/licenses/by/4.0/). Access for free at <https://openstax.org/books/anatomy-and-physiology/pages/1-introduction>

center of the soft palate. When swallowing, the soft palate and uvula move upward, helping to keep foods and liquid from entering the nasal cavity and respiratory tract.⁴

Two muscular folds extend downward from the soft palate on either side of the uvula. Between these two folds are the palatine tonsils, clusters of lymphoid tissue involved in the immune system. The lingual tonsils are located at the base of the tongue.⁵

Stomatitis (stō-mă-TĪT-īs) refers to inflammation of the mouth. **Xerostomia** (zēr-ō-STŌ-mē-ă) refers to the condition of a dry mouth. **Uvulitis** (ū-vyŭ-LĪT-īs) refers to inflammation of the uvula. **Gingivitis** (jin-jĭ-VĪT-īs) refers to inflammation of the gums.

TONGUE

The **tongue** (TUNG) facilitates ingestion, digestion, sensation (of taste, texture, and temperature of food), swallowing, and vocalization. It has a mucous membrane covering and is composed of skeletal muscles that facilitate eating, swallowing, and speaking. The top and sides of the tongue are studded with papillae and taste buds to facilitate sensation. Lingual glands secrete mucus and a watery fluid that contains the enzyme lipase, which

4. This work is a derivative of [Anatomy and Physiology](https://openstax.org/books/anatomy-and-physiology/pages/1-introduction) by [OpenStax](https://openstax.org/books/anatomy-and-physiology/pages/1-introduction) licensed under [CC BY 4.0](https://creativecommons.org/licenses/by/4.0/). Access for free at <https://openstax.org/books/anatomy-and-physiology/pages/1-introduction>
5. This work is a derivative of [Anatomy and Physiology](https://openstax.org/books/anatomy-and-physiology/pages/1-introduction) by [OpenStax](https://openstax.org/books/anatomy-and-physiology/pages/1-introduction) licensed under [CC BY 4.0](https://creativecommons.org/licenses/by/4.0/). Access for free at <https://openstax.org/books/anatomy-and-physiology/pages/1-introduction>

becomes active in the acidic environment of the stomach.⁶ See Figure 12.3⁷ for an illustration of the tongue and its papillae.

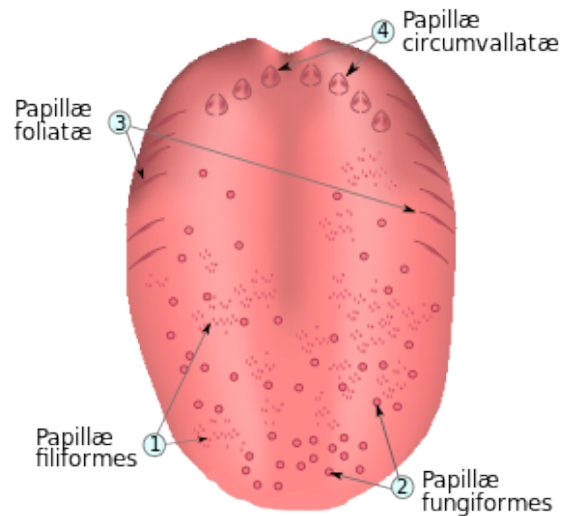


Figure 12.3 Tongue

Glossitis (glo-SĪT-ĭs) refers to inflammation of the tongue. **Sublingual** (sŭb-LING-gwăĭ) means “pertaining to under the tongue” and is also a route of medication administration.

6. This work is a derivative of *Anatomy and Physiology* by OpenStax licensed under CC BY 4.0. Access for free at <https://openstax.org/books/anatomy-and-physiology/pages/1-introduction>

7. “[Papillae on tongue.svg](#)” is a derivative work by Kjell ANDRÉ licensed under CC BY-SA 3.0

SALIVARY GLANDS

Salivary (SĂL-ĭ-văr-ē) glands are housed within the mucous membranes of the mouth and are constantly secreting saliva into the oral cavity to keep the mouth moist. Saliva secretion increases when eating or even thinking about eating food. Saliva contains an enzyme called salivary amylase, which starts the breakdown of carbohydrates in the mouth. There are six salivary glands that secrete into the oral cavity – two parotid glands located in the cheeks anterior to the ears, two sublingual salivary glands located beneath the tongue, and two submandibular salivary glands located just beneath the mandible.⁸ See Figure 12.4⁹ for an illustration of the salivary glands.

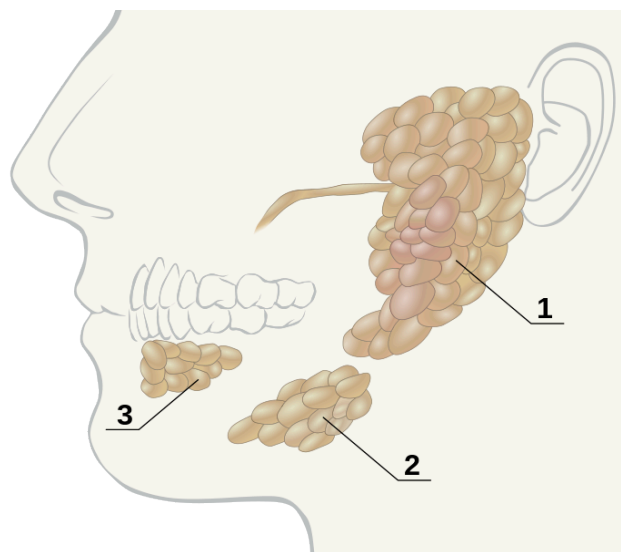


Figure 12.4 Salivary Glands 1) Parotid gland, 2) Submandibular gland, 3) Sublingual gland

8. This work is a derivative of Anatomy and Physiology by OpenStax licensed under CC BY 4.0. Access for free at <https://openstax.org/books/anatomy-and-physiology/pages/1-introduction>
9. “Salivary glands numbered.svg” by Goran tek-en, following request by and knowledge from Tom (LT) is licensed under CC BY-SA 4.0

PHARYNX

The **pharynx** (FAR-inks), commonly called the throat, is a muscular tube lined with a mucous membrane that runs from the posterior oral and nasal cavities to the esophagus and the larynx.¹⁰ See Figure 12.5¹¹ for an illustration of the pharynx.

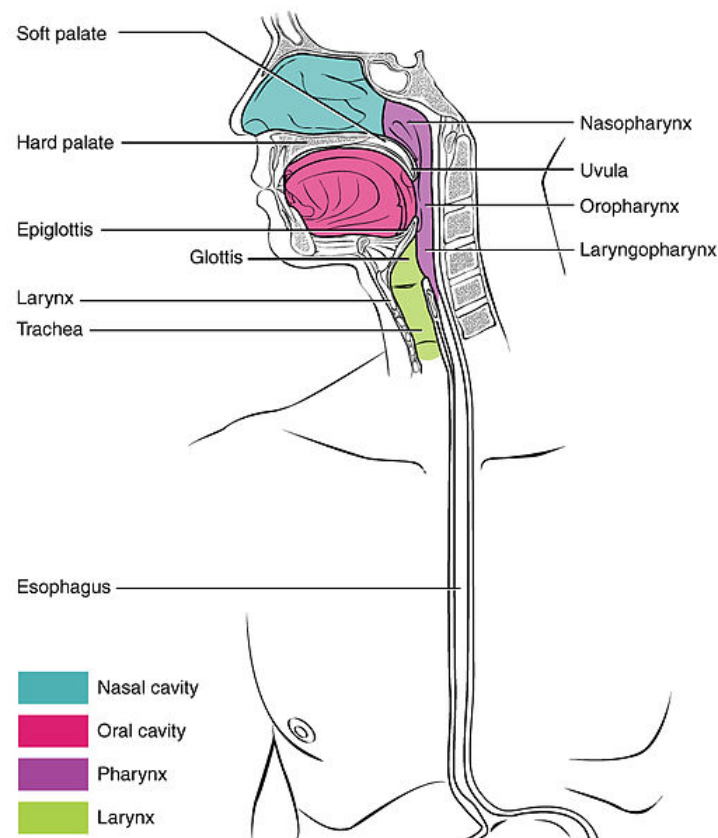


Figure 12.5 Pharynx

10. This work is a derivative of [Anatomy and Physiology](#) by [OpenStax](#) licensed under [CC BY 4.0](#). Access for free at <https://openstax.org/books/anatomy-and-physiology/pages/1-introduction>

11. "[2411_Pharynx.jpg](#)" by OpenStax College is licensed under [CC BY 3.0](#)

The pharynx has three subdivisions. The superior section, the nasopharynx, is involved only in breathing and speech. The other two subdivisions, the oropharynx and the laryngopharynx, are used for both functions of breathing and digestion. The oropharynx begins inferior to the nasopharynx and continues to the laryngopharynx. In the laryngopharynx, the inferior border of the laryngopharynx connects to the esophagus, whereas the anterior portion connects to the larynx.¹²

The pharynx is involved in both digestion and breathing. It receives air from the mouth and nasal cavities and food from the mouth. When food enters the pharynx, involuntary muscle contractions close a flap of tissue called the **epiglottis** (ěp-ĭ-GLŎT-ĭs) to prevent food from entering the trachea and to ensure it enters the esophagus. **Dysphagia** (dis-FĀj-ē-ă), also called aspiration, refers to difficulty swallowing that can result in food entering the respiratory tract.

ESOPHAGUS

The **esophagus** (ĭ-SOF-ă-gŭs) is a muscular tube that connects the laryngopharynx to the stomach. It is located posteriorly to the trachea and is approximately ten inches long. See Figure 12.6¹³ for an illustration of the esophagus. The upper esophageal sphincter is a muscular ring that controls the movement of food from the pharynx to the esophagus.¹⁴

12. This work is a derivative of [Anatomy and Physiology](#) by [OpenStax](#) licensed under [CC BY 4.0](#). Access for free at <https://openstax.org/books/anatomy-and-physiology/pages/1-introduction>

13. "[2412_The_Esophagus.jpg](#)" by OpenStax College is [CC BY 3.0](#)

14. This work is a derivative of [Anatomy and Physiology](#) by [OpenStax](#) licensed

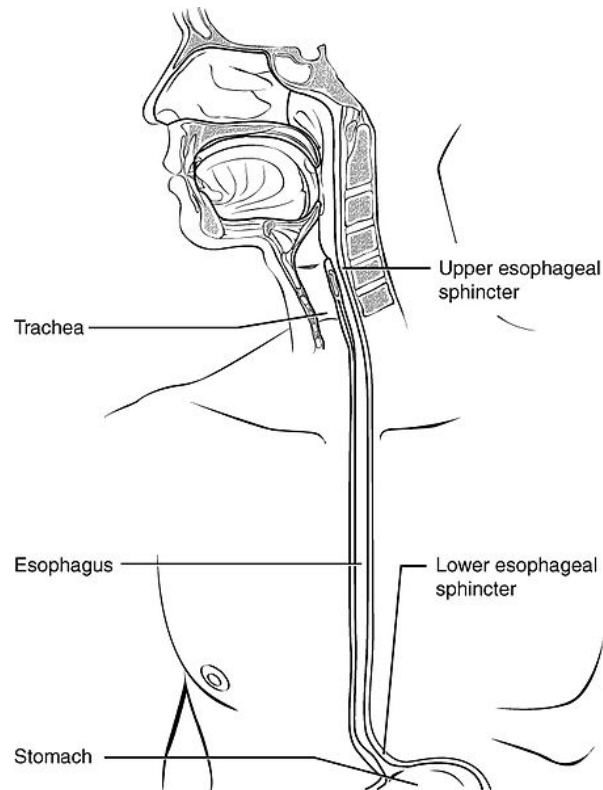


Figure 12.6 Esophagus

A series of wave-like muscle contractions called **peristalsis** (per-ĭ-STAL-sĭs) push food through the esophagus and into the stomach. Just before the opening to the stomach is another ring-shaped muscle called the **lower esophageal sphincter** (LOH-ĕr ĭ-SOF-ă-gĕ-al SFINGK-tĕr), also known as the cardiac sphincter. Recall that sphincters are muscles that surround tubes and serve as valves, closing the tube when the sphincters contract and opening it when they relax. This sphincter opens to let food pass into the stomach and closes to keep it from backing up into the esophagus.¹⁵

under [CC BY 4.0](https://openstax.org/books/anatomy-and-physiology/pages/1-introduction). Access for free at <https://openstax.org/books/anatomy-and-physiology/pages/1-introduction>

15. This work is a derivative of [Anatomy and Physiology](#) by [OpenStax](#) licensed

Esophageal varices (ě-sŏf-ă-JĚ-ăl VĀR-ĭ-sēz) refers to an abnormal condition of swollen veins in the lower part of the esophagus.

STOMACH

The **stomach** (STUM-ăk) is a sac-like organ where food is mixed with gastric juice. There are four main regions in the stomach: the cardia, fundus, body, and pylorus. The funnel-shaped pylorus connects the stomach to the duodenum, the first part of the small intestine. The **pyloric sphincter** (pĭ-LOR-ĭk SFINGK-těr) is located at this latter point of connection and controls stomach emptying into the small intestine.¹⁶ See Figure 12.7¹⁷ for an illustration of the stomach.

under [CC BY 4.0](https://openstax.org/books/anatomy-and-physiology/pages/1-introduction). Access for free at <https://openstax.org/books/anatomy-and-physiology/pages/1-introduction>

¹⁶. This work is a derivative of [Anatomy and Physiology](https://openstax.org/books/anatomy-and-physiology/pages/1-introduction) by [OpenStax](https://openstax.org/books/anatomy-and-physiology/pages/1-introduction) licensed under [CC BY 4.0](https://openstax.org/books/anatomy-and-physiology/pages/1-introduction). Access for free at <https://openstax.org/books/anatomy-and-physiology/pages/1-introduction>

¹⁷. “[2414_Stomach.jpg](#)” by OpenStax College is licensed under [CC BY 3.0](#)

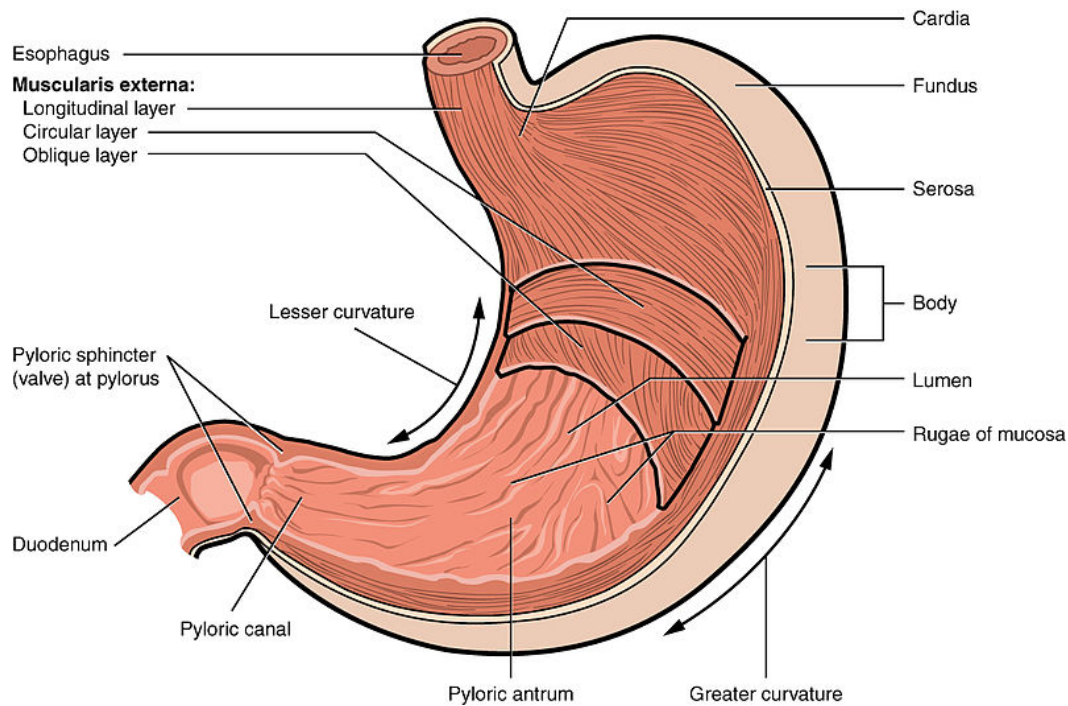


Figure 12.7 Stomach

The inner lining of the stomach is covered by a mucous membrane that secretes a protective coat of alkaline mucus. The mucous protects the stomach from corrosive stomach acid. Gastric glands lie under the surface of this lining and secrete a complex digestive fluid referred to as **gastric juice** (GAS-trīk JOOS).¹⁸

Cells in the stomach lining secrete digestive hormones, such as gastrin and pepsin, as well as **hydrochloric acid** (HĪ-drō-klōr-ĪK AS-id). The acidity stimulates digestive hormones and also kills most of the bacteria ingested with food. A common digestive disorder called **gastroesophageal reflux disease** (GAS-trō-ě-sōf-ă-JĒ-ăl REE-flŭks dĭ-ZĒZ) (**GERD**) is caused by

18. This work is a derivative of [Anatomy and Physiology](https://openstax.org/books/anatomy-and-physiology/pages/1-introduction) by [OpenStax](https://openstax.org/books/anatomy-and-physiology/pages/1-introduction) licensed under [CC BY 4.0](https://creativecommons.org/licenses/by/4.0/). Access for free at <https://openstax.org/books/anatomy-and-physiology/pages/1-introduction>

excessive hydrochloric acid that backs up into the lower esophagus.¹⁹ Read more information about this condition in the “[Diseases and Disorders of the Digestive System](#)” section.

The muscular walls of the stomach move food through the stomach and vigorously churn it, mechanically breaking it down into smaller particles.

SMALL INTESTINE

Partially digested food, called **chyme** (KĪM) is released from the stomach via the pyloric sphincter and enters the **small intestine** (SMOL IN-těs-tĭn), the part of the digestive tract where most of the digestion and absorption into the blood occurs. Approximately 90 percent of nutrients from food are absorbed through **villi** (VIL-ĭ), small fingerlike extensions on the inner surface of the small intestine. The small intestine is about ten feet long. Its name derives from its small diameter of about one inch, compared to the large intestine's diameter of about three inches.²⁰

The coiled tube of the small intestine is subdivided into three regions called the **duodenum** (dū-ō-DĒ-nŭm), **jejunum** (jĭ-JŪ-num), and **ileum** (ĭL-ē-ŭm). The ileum joins the cecum of the large intestine at the ileocecal valve. The **ileocecal valve** (ĭL-ē-ō-SĒ-kă VALV) controls the flow of chyme from the small

19. This work is a derivative of [Anatomy and Physiology](#) by [OpenStax](#) licensed under [CC BY 4.0](#). Access for free at <https://openstax.org/books/anatomy-and-physiology/pages/1-introduction>

20. This work is a derivative of [Anatomy and Physiology](#) by [OpenStax](#) licensed under [CC BY 4.0](#). Access for free at <https://openstax.org/books/anatomy-and-physiology/pages/1-introduction>

intestine to the large intestine.²¹ See Figure 12.8²² for an illustration of these regions.

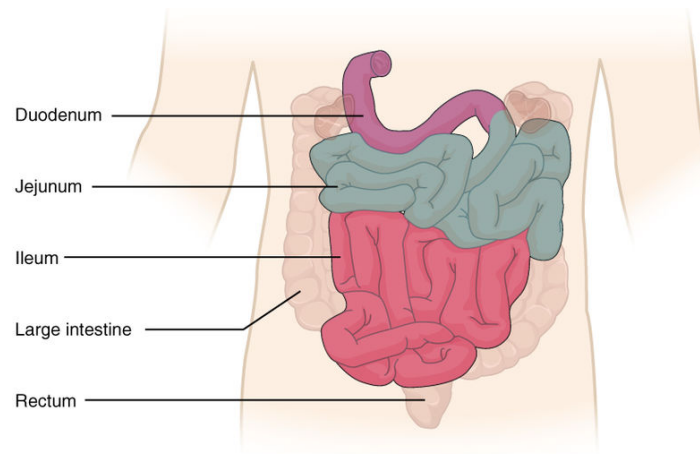


Figure 12.8 Small Intestine

LARGE INTESTINE

The **large intestine** (LARJ IN-tēs-tĭn) runs from the cecum to the anus. The primary functions of the large intestine are to finish absorption of nutrients and water, synthesize certain vitamins, and form and eliminate **feces** (FĒ-sēz), also called stool. The large intestine is about one half the length of the small intestine but is called large because its diameter is three inches, about twice the diameter of the small intestine. The large intestine is subdivided into four

21. This work is a derivative of [Anatomy and Physiology](#) by [OpenStax](#) licensed under [CC BY 4.0](#). Access for free at <https://openstax.org/books/anatomy-and-physiology/pages/1-introduction>
22. “[2417_Small_IntestineN.jpg](#)” by OpenStax College is licensed under [CC BY 3.0](#)

main regions: cecum, colon, rectum, and anal canal.²³ See Figure 12.9²⁴ for an illustration of the large intestine.

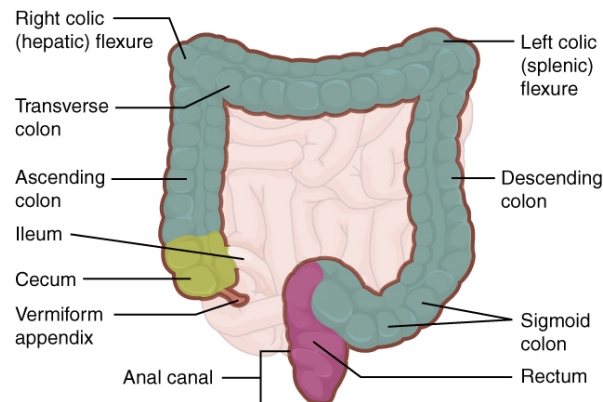


Figure 12.9 Large Intestine

Cecum

The **cecum** (SĒ-kŭm) is the initial part of the large intestine. It receives the contents of the small intestine and continues absorbing water and salts. The **appendix** (ă-PEN-diks) is a small pouch attached to the end of the cecum. Its twisted anatomy provides a haven for the accumulation and multiplication of intestinal bacteria that can lead to **appendicitis** (ă-pen-dĭ-SĪT-ĭs). An **appendectomy** (ap-ĕn-DEK-tŏ-mĕ) is the surgical removal of the appendix.²⁵

23. This work is a derivative of [Anatomy and Physiology](#) by [OpenStax](#) licensed under [CC BY 4.0](#). Access for free at <https://openstax.org/books/anatomy-and-physiology/pages/1-introduction>

24. “[2420_Large_Intestine.jpg](#)” by OpenStax College is licensed under [CC BY 3.0](#)

25. This work is a derivative of [Anatomy and Physiology](#) by [OpenStax](#) licensed

Colon

Food residue entering the colon travels up the **ascending colon** (ă-SEN-ding KŌ-lŏn) on the right side of a person's abdomen. At the inferior surface of the liver, the colon bends to become the **transverse colon** (trans-VURS KŌ-lŏn), where it travels across to the left side of their abdomen. From there, chyme passes through another bend inferior to the spleen and down the **descending colon** (dě-SEN-ding KŌ-lŏn), which runs down the left side of the posterior abdominal wall and becomes the S-shaped **sigmoid colon** (SIG-moyd KŌ-lŏn).²⁶

Rectum

The **rectum** (REK-tŭm) is the final eight inches of the large intestine. It has three folds called rectal valves that help separate **feces** (FĒ-sēz) from **flatus** (FLĀ-tŭs), commonly referred to as gas.²⁷

A **proctoscope** (PRŎK-tă-skōp) is an instrument used by a health care provider to view the rectum.

Anal Canal

The **anal** (ĀN-ăl) canal is about three inches long and opens to the exterior of the body at the **anus** (Ā-nŭs), the end of the digestive tract. The anal canal includes two sphincters. The internal anal sphincter is made of smooth

under [CC BY 4.0](https://openstax.org/books/anatomy-and-physiology/pages/1-introduction). Access for free at <https://openstax.org/books/anatomy-and-physiology/pages/1-introduction>

26. This work is a derivative of [Anatomy and Physiology](https://openstax.org/books/anatomy-and-physiology/pages/1-introduction) by [OpenStax](https://openstax.org/books/anatomy-and-physiology/pages/1-introduction) licensed under [CC BY 4.0](https://openstax.org/books/anatomy-and-physiology/pages/1-introduction). Access for free at <https://openstax.org/books/anatomy-and-physiology/pages/1-introduction>

27. This work is a derivative of [Anatomy and Physiology](https://openstax.org/books/anatomy-and-physiology/pages/1-introduction) by [OpenStax](https://openstax.org/books/anatomy-and-physiology/pages/1-introduction) licensed under [CC BY 4.0](https://openstax.org/books/anatomy-and-physiology/pages/1-introduction). Access for free at <https://openstax.org/books/anatomy-and-physiology/pages/1-introduction>

muscle, and its contractions are involuntary. The external anal sphincter is made of skeletal muscle, which is under voluntary control. Except when defecating, both sphincters usually remain closed.²⁸

A **hemorrhoid** (HEM-ō-royd) is a common but abnormal condition of a distended and swollen vein in the anus or rectum.

ACCESSORY ORGANS OF DIGESTION

Chemical digestion in the small intestine relies on the activities of three accessory digestive organs: the liver, pancreas, and gallbladder. See Figure 12.10²⁹ for an illustration of these digestive accessory organs. The digestive role of the liver is to produce bile and export it to the duodenum. The gallbladder stores, concentrates, and releases bile. The pancreas produces pancreatic juice, which contains digestive enzymes and bicarbonate ions, and delivers it to the duodenum.³⁰

- 28. This work is a derivative of [Anatomy and Physiology](#) by [OpenStax](#) licensed under [CC BY 4.0](#). Access for free at <https://openstax.org/books/anatomy-and-physiology/pages/1-introduction>
- 29. “[2422_Accessory_Organs.jpg](#)” by OpenStax College is licensed under [CC BY 3.0](#)
- 30. This work is a derivative of [Anatomy and Physiology](#) by [OpenStax](#) licensed under [CC BY 4.0](#). Access for free at <https://openstax.org/books/anatomy-and-physiology/pages/1-introduction>

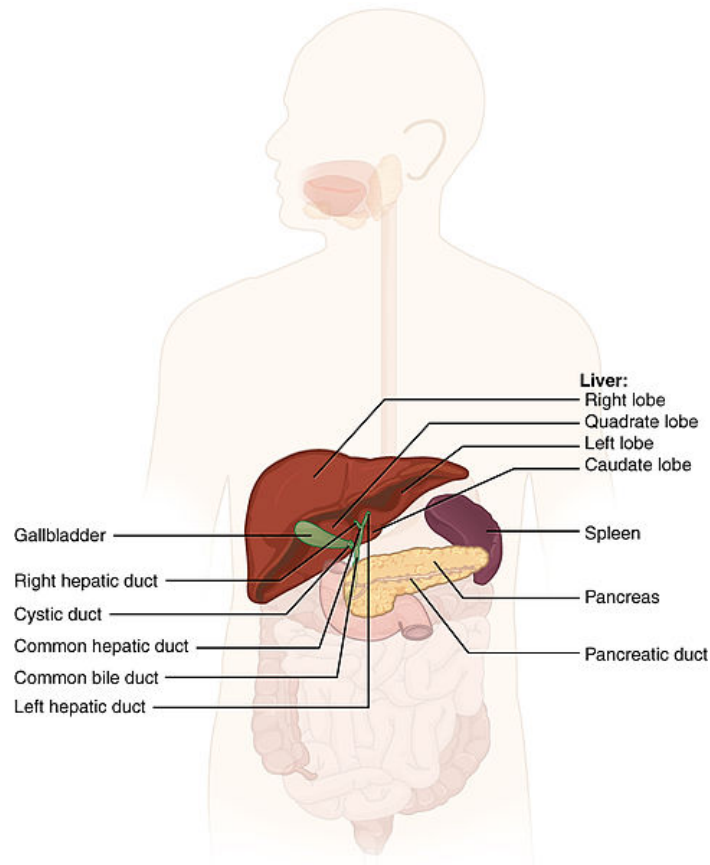


Figure 12.10 Accessory Organs of the Digestive System

Liver

The **liver** (LIV-ĕr) plays many roles in digestion, metabolism, and hemostasis. The liver lies inferior to the diaphragm in the right upper quadrant of the abdominal cavity. It is protected by the surrounding ribs. The liver is divided into two primary lobes, a large right lobe and a much smaller left lobe.

Hepatomegaly (hep-ăt-ō-MEG-ă-lĕ)³¹ refers to an enlarged liver.

The portal vein delivers nutrient-rich blood from the small intestine to the liver. The liver absorbs and/or metabolizes nutrients, toxins, and medications.

31. This work is a derivative of [Anatomy and Physiology](https://openstax.org/books/anatomy-and-physiology/pages/1-introduction) by OpenStax licensed under [CC BY 4.0](https://creativecommons.org/licenses/by/4.0/). Access for free at <https://openstax.org/books/anatomy-and-physiology/pages/1-introduction>

After the liver has broken down harmful substances, the by-products are excreted into the bile or blood. **Bile** (BĪL) is a digestive fluid produced and secreted by the liver. Bile enters the intestine and leaves the body in the form of feces. After the liver processes these substances in the blood, it releases the filtered blood through the hepatic vein that flows into the inferior vena cava. See Figure 12.11³² for an illustration of these structures related to the liver.³³

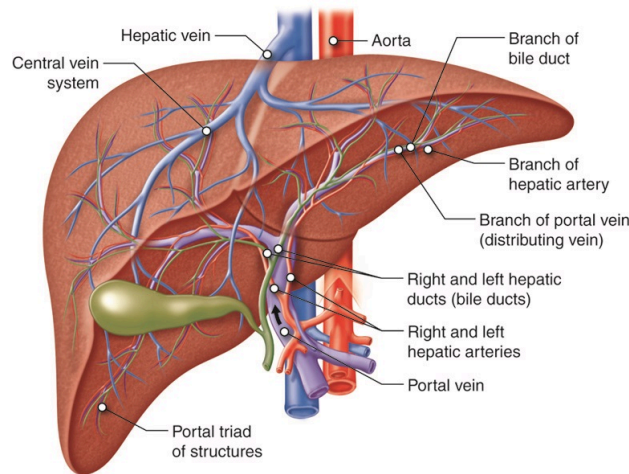


Figure 12.11 Structures Related to the Liver

Bilirubin (bil-ĭ-ROO-bin) is a yellowish pigment produced by the breakdown of red blood cells that is filtered out of the blood by the liver. If a person's liver

32. "[Cenveo – Drawing Liver anatomy and vascularisation – English labels](#)" by Cenveo is licensed under [CC BY 4.0](#)

33. This work is a derivative of [Anatomy and Physiology](#) by [OpenStax](#) licensed under [CC BY 4.0](#). Access for free at <https://openstax.org/books/anatomy-and-physiology/pages/1-introduction>

is not functioning properly, it cannot adequately filter out the bilirubin, causing yellowing of the skin and eyes referred to as **jaundice** (JAWN-dīs).³⁴

In some digestive diseases, bile does not enter the intestine, resulting in white stool with a high fat content because virtually no fats are broken down by the bile. **Steatorrhea** (stē-ăt-ō-RĒ-ă) refers to excessive fat excreted in the stool.³⁵

Pancreas

The soft, oblong, glandular **pancreas** (PAN-krē-ăs) lies transversely behind the stomach. Refer back to Figure 12.10 for an illustration of the location of the pancreas. The pancreas has two functions referred to as **exocrine** (ĖK-sŏ-krĭn), meaning secreting digestive enzymes, and **endocrine** (EN-dŏ-krĭn), meaning releasing hormones into the blood.³⁶

The exocrine portion of the pancreas produces many protein-digesting enzymes, pancreatic **amylase** (ĀM-ĭ-lās) that digests carbohydrates, and pancreatic **lipase** (Lĭ-pās) that digests fat. The pancreas delivers these enzymes to the duodenum through the pancreatic duct and into the common bile duct (carrying bile from both the liver and gallbladder). The endocrine function of the pancreas secretes the hormones insulin and

34. This work is a derivative of [Anatomy and Physiology](https://openstax.org/books/anatomy-and-physiology/pages/1-introduction) by [OpenStax](https://openstax.org/books/anatomy-and-physiology/pages/1-introduction) licensed under [CC BY 4.0](https://creativecommons.org/licenses/by/4.0/). Access for free at <https://openstax.org/books/anatomy-and-physiology/pages/1-introduction>

35. This work is a derivative of [Anatomy and Physiology](https://openstax.org/books/anatomy-and-physiology/pages/1-introduction) by [OpenStax](https://openstax.org/books/anatomy-and-physiology/pages/1-introduction) licensed under [CC BY 4.0](https://creativecommons.org/licenses/by/4.0/). Access for free at <https://openstax.org/books/anatomy-and-physiology/pages/1-introduction>

36. This work is a derivative of [Anatomy and Physiology](https://openstax.org/books/anatomy-and-physiology/pages/1-introduction) by [OpenStax](https://openstax.org/books/anatomy-and-physiology/pages/1-introduction) licensed under [CC BY 4.0](https://creativecommons.org/licenses/by/4.0/). Access for free at <https://openstax.org/books/anatomy-and-physiology/pages/1-introduction>

glucagon to regulate blood glucose levels.³⁷ See Figure 12.15³⁸ for an illustration of the pancreas.

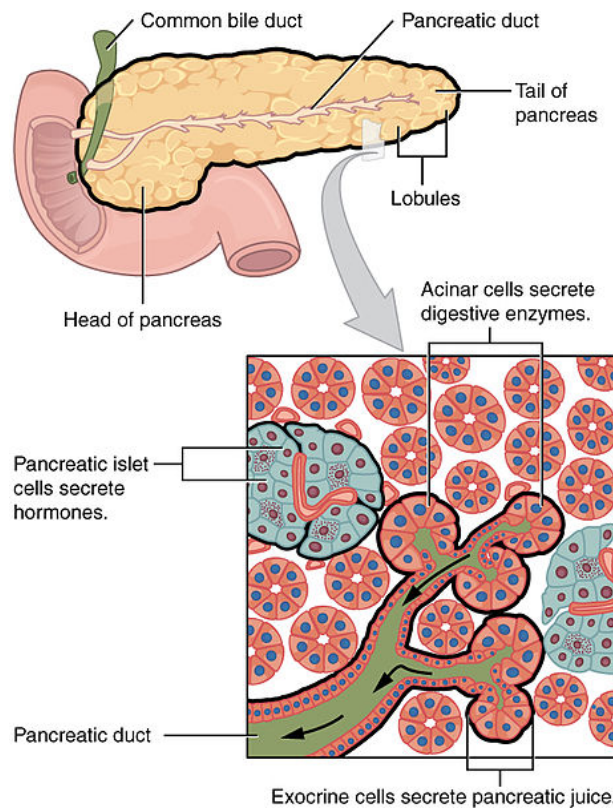


Figure 12.12 Pancreas

Gallbladder

The **gallbladder** (GAWL-blăd-ěr) is about 3-4 inches long and is nested in a shallow area underneath the right lobe of the liver. This muscular sac stores,

37. This work is a derivative of *Anatomy and Physiology* by OpenStax licensed under CC BY 4.0. Access for free at <https://openstax.org/books/anatomy-and-physiology/pages/1-introduction>

38. “2424_Exocrine_and_Endocrine_Pancreas.jpg” by OpenStax College is licensed under CC BY 3.0

concentrates, and releases bile into the duodenum via the common bile duct. Refer back to Figure 12.10 for an illustration of the location of the gallbladder.³⁹

Gallstones can form in the gallbladder, a condition called **cholelithiasis** (kō-li-lith-ī-ă-sīs). Inflammation of the gallbladder is referred to as **cholecystitis** (kōl-ě-sīs-Tī-tīs). Read more information about these conditions in the “[Diseases and Disorders of the Digestive System](#)” section.

39. This work is a derivative of [Anatomy and Physiology](#) by [OpenStax](#) licensed under [CC BY 4.0](#). Access for free at <https://openstax.org/books/anatomy-and-physiology/pages/1-introduction>

12.5 Physiology of the Digestive System

FUNCTIONS OF THE DIGESTIVE SYSTEM

The main functions of the digestive system are ingesting food, digesting food, absorbing nutrients, and eliminating waste products. See Table 12.5 for an overview of the functions of the organs of the digestive tract.

Table 12.5. Functions of the Digestive Organs¹

1. This work is a derivative of Anatomy & Physiology by [OpenStax](#) and is licensed under [CC BY 4.0](#). Access for free at <https://openstax.org/details/books/anatomy-and-physiology-2e>

Organ	Major Functions	Other Functions
Mouth	<ul style="list-style-type: none"> • Ingests food • Chews and mixes food • Begins chemical breakdown of carbohydrates • Moves food into the pharynx • Begins breakdown of lipids via lingual lipase 	<ul style="list-style-type: none"> • Moistens and dissolves food, allowing for taste • Cleans and lubricates the teeth and oral cavity • Promotes some antimicrobial activity
Pharynx	<ul style="list-style-type: none"> • Propels food from the oral cavity to the esophagus 	<ul style="list-style-type: none"> • Lubricates food and passageways
Esophagus	<ul style="list-style-type: none"> • Propels food to the stomach 	<ul style="list-style-type: none"> • Lubricates food and passageways
Stomach	<ul style="list-style-type: none"> • Mixes and churns food with gastric juices to form chyme • Begins chemical breakdown of proteins • Releases food into the duodenum as chyme • Absorbs some fat-soluble substances • Possesses antimicrobial functions 	<ul style="list-style-type: none"> • Stimulates protein-digesting enzymes • Secretes intrinsic factor required for vitamin B12 absorption in small intestine

Small Intestine	<ul style="list-style-type: none"> • Mixes chyme with digestive juices • Propels food at a rate slow enough for digestion and absorption • Absorbs breakdown products of carbohydrates, proteins, lipids, and nucleic acids, along with vitamins, minerals, and water • Performs physical digestion via segmentation 	<ul style="list-style-type: none"> • Provides optimal medium for enzymatic activity
Large Intestine	<ul style="list-style-type: none"> • Further breaks down food residues • Absorbs most residual water, electrolytes, and vitamins produced by enteric bacteria • Propels feces toward rectum • Eliminates feces 	<ul style="list-style-type: none"> • Temporarily stores concentrated food residue prior to defecation • Eases passage of feces through colon from mucus

Accessory Organs	<ul style="list-style-type: none"> • Liver: produces bile salts, which emulsify lipids, aiding their digestion and absorption • Gallbladder: stores, concentrates, and releases bile • Pancreas: produces digestive enzymes and bicarbonate 	<ul style="list-style-type: none"> • Help neutralize acidic chyme and provide optimal environment for enzymatic activity
-------------------------	--	---

DIGESTIVE PROCESSES

Digestive processes involve the interaction of several organs and occur gradually as food moves through the gastrointestinal tract. The processes of digestion include six activities: ingestion, propulsion, mechanical digestion, chemical digestion, absorption, and defecation.² See Figure 12.13³ for an illustration of digestive processes.

2. This work is a derivative of [Anatomy and Physiology](#) by [OpenStax](#) licensed under [CC BY 4.0](#). Access for free at <https://openstax.org/books/anatomy-and-physiology/pages/1-introduction>

3. “[2405_Digestive_Process.jpg](#)” by OpenStax College is licensed under [CC BY 3.0](#)

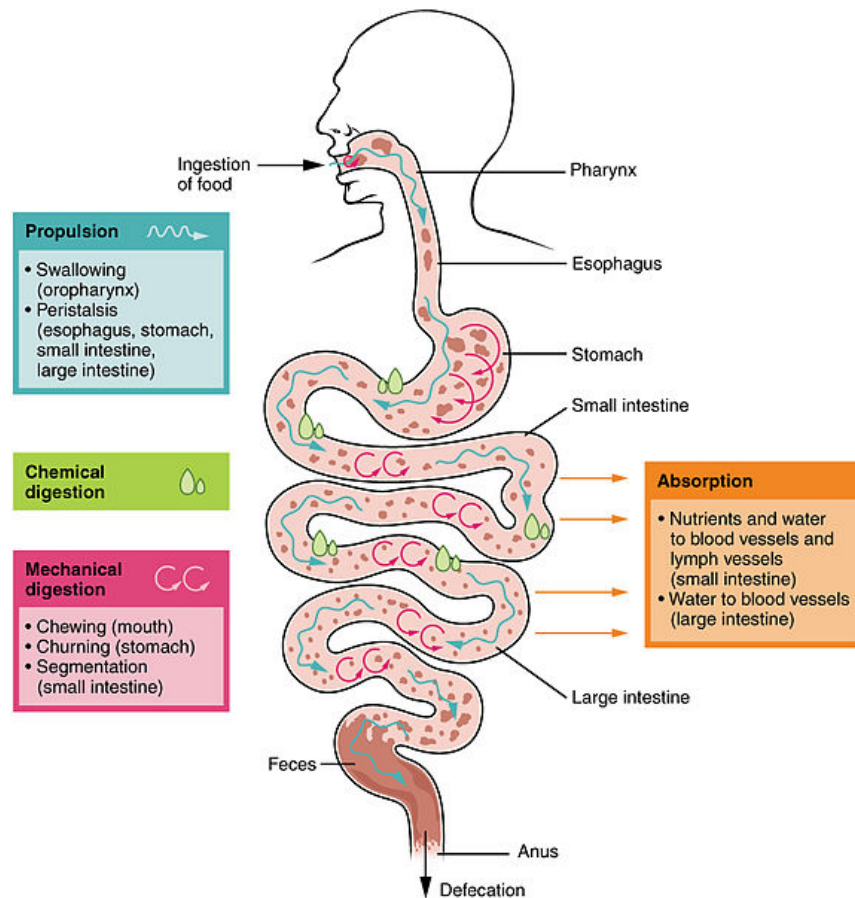


Figure 12.13 Digestive Processes

Ingestion

Ingestion refers to the intake of food through the mouth where it is chewed and mixed with saliva. Saliva contains enzymes that begin breaking down the carbohydrates and fats in the food. Chewing produces a soft mass of food called a **bolus** (BŌL-ŭs) that is an appropriate size for swallowing.⁴

4. This work is a derivative of [Anatomy and Physiology](https://openstax.org/books/anatomy-and-physiology/pages/1-introduction) by [OpenStax](https://openstax.org/books/anatomy-and-physiology/pages/1-introduction) licensed under [CC BY 4.0](https://creativecommons.org/licenses/by/4.0/). Access for free at <https://openstax.org/books/anatomy-and-physiology/pages/1-introduction>

Propulsion

Food leaves the mouth when the tongue and pharyngeal muscles propel it into the esophagus. This act of swallowing is an example of propulsion, which refers to the movement of food through the digestive tract. It includes both the voluntary process of swallowing and the involuntary process of **peristalsis** (per-ĭ-STAL-sĭs). Peristalsis consists of sequential, alternating waves of contraction and relaxation of smooth muscles, which act to propel food through the digestive tract. See Figure 12.14⁵ for an illustration of peristalsis. Peristaltic waves also play a role in mixing food with digestive juices. Peristalsis is so powerful that swallowed foods and liquids enter the stomach even if you are standing on your head.⁶

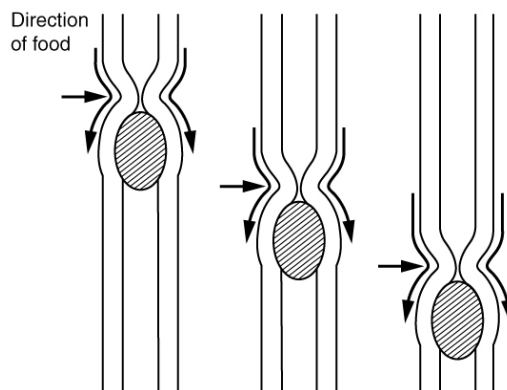


Figure 12.14 Peristalsis

Mechanical Digestion

Mechanical digestion is a physical process that does not change the chemical nature of the food but makes it smaller to increase its surface area and

5. "[2404_PeristalsisN.jpg](#)" by OpenStax College is licensed under [CC BY 3.0](#)
6. This work is a derivative of [Anatomy and Physiology](#) by [OpenStax](#) licensed under [CC BY 4.0](#). Access for free at <https://openstax.org/books/anatomy-and-physiology/pages/1-introduction>

mobility. Mechanical digestion starts with chewing and then progresses to mechanical churning of food in the stomach. In the stomach, the bolus of food further breaks apart with more surface area that is exposed to digestive juices of chemical digestion.⁷

Chemical Digestion

Chemical digestion begins in the mouth and is completed in the small intestine. Digestive secretions contain water, **enzymes** (EN-zīmz), acids, and salts that create an acidic “soup” that breaks down food molecules into their chemical building blocks. For example, proteins are broken down into **amino acids** (Ā-mē-nō AS-idz).⁸

Absorption

Nutrients (NŪ-trē-ěntz) are substances that provide nourishment to cells. After food molecules have been broken down during chemical digestion, nutrients enter the bloodstream through the process of **absorption** (ab-SORP-shŏn). Absorption takes place primarily in the small intestine.

Defecation

During **defecation** (děf-ě-KĀ-shŏn), the final step in digestion, undigested materials are expelled from the body as feces.⁹

7. This work is a derivative of [Anatomy and Physiology](https://openstax.org/books/anatomy-and-physiology/pages/1-introduction) by [OpenStax](https://openstax.org/books/anatomy-and-physiology/pages/1-introduction) licensed under [CC BY 4.0](https://creativecommons.org/licenses/by/4.0/). Access for free at <https://openstax.org/books/anatomy-and-physiology/pages/1-introduction>

8. This work is a derivative of [Anatomy and Physiology](https://openstax.org/books/anatomy-and-physiology/pages/1-introduction) by [OpenStax](https://openstax.org/books/anatomy-and-physiology/pages/1-introduction) licensed under [CC BY 4.0](https://creativecommons.org/licenses/by/4.0/). Access for free at <https://openstax.org/books/anatomy-and-physiology/pages/1-introduction>

9. This work is a derivative of [Anatomy and Physiology](https://openstax.org/books/anatomy-and-physiology/pages/1-introduction) by [OpenStax](https://openstax.org/books/anatomy-and-physiology/pages/1-introduction) licensed

ADDITIONAL TERMS RELATED TO THE DIGESTIVE SYSTEM

Additional common medical terms related to the digestive system include the following:

- **Adhesion** (ad-HĒ-zhŏn): Scar tissue from disease or previous surgery that binds anatomic surfaces to each other.
- **Ascites** (ă-SĪ-tēz): Abnormal fluid buildup in the abdominal cavity.
- **Dysentery** (DIS-ĕn-ter-ē): Inflammation of the intestine presenting with abdominal pain and bloody diarrhea.
- **Dyspepsia** (dĭs-PEP-sē-ă): Indigestion.
- **Emesis** (ĒM-ĕ-sĭs): Vomiting
- **Flatus** (FLĀ-tŭs): Gas in the GI tract.
- **Gastroenteritis** (GAS-trō-ĕn-tĕr-Ī-tĭs): Inflammation of the stomach and intestines.
- **Hernia** (HUR-nē-ă): Protrusion of an organ through a muscular wall.
- **Melena** (mě-LĒ-nă): Black, tarry feces that contains blood from the digestive tract.
- **Nausea** (NAW-zē-ă): The feeling of an urge to vomit.
- **NPO** (en-pee-ō): A commonly used medical abbreviation standing for “nothing by mouth,” meaning not to ingest food, fluids, or medications orally.
- **Obesity** (ō-BĒ-sĭ-tē): Increased proportion of fat cells, resulting in excessive body weight in proportion to height.
- **Palpate** (PAL-pāt): A physical examination technique where the examiner feels for texture, size, consistency, and location of organs with their hands.
- **Percutaneous endoscopic gastrostomy** (pŭr-kŭ-TĀ-nē-ŭs ĕn-DŎS-kŏ-pĭk

under [CC BY 4.0](https://openstax.org/books/anatomy-and-physiology/pages/1-introduction). Access for free at <https://openstax.org/books/anatomy-and-physiology/pages/1-introduction>

gās-TRŌS-tŏ-mē) (**PEG**): A surgical procedure that places a feeding tube into the stomach through the abdominal wall to administer nutrition when swallowing is impaired.

- **Probiotics** (prō-bī-OT-īks): Normally occurring bacteria that are beneficial for digestion.
- **Reflux** (RĒ-flŭks): Abnormal backward flow.
- **Visceral** (VĪS-ēr-ăl): Relating to the organs.
- **Vomiting** (VOM-ī-ting): Forceful ejection of stomach contents.

12.6 Diseases and Disorders of the Digestive System

Common diseases and disorders of the digestive system are discussed in this section.

CELIAC DISEASE

Celiac disease (SĒ-lē-ăk dĩ-ZĒZ) is a chronic digestive and autoimmune disease that damages the small intestine. It is triggered by eating foods containing gluten. Gluten is a protein found in foods containing wheat, barley, or rye. When a person with celiac disease eats gluten, an immune response is triggered to the gluten protein in the small intestine. Celiac disease can cause long-lasting digestive problems and prevent absorptions of nutrients. It is diagnosed with blood tests and biopsy taken during an upper GI endoscopy. Individuals with celiac disease must avoid gluten in their diets and often take dietary supplements.¹ Read more about upper GI endoscopy in the “[Medical Specialists, Diagnostic Testing, and Procedures Related to the Digestive System](#)” section.

1. National Institute of Diabetes and Digestive and Kidney Diseases. (n.d.). *Celiac disease*. National Institutes of Health. <https://www.niddk.nih.gov/health-information/digestive-diseases/celiac-disease>

CHOLECYSTITIS AND GALLSTONES

Cholecystitis (kō-lě-sis-TĪT-īs) is inflammation of the gallbladder. The gallbladder stores and distributes bile through the bile ducts. A **gallstone** (GAWL-stōn) is a piece of hardened bile residue that can form for a variety of reasons, including elevated cholesterol levels. When a gallstone gets stuck in a bile duct, it can cause bile to back up into the gallbladder, causing severe upper right abdominal pain and swelling, chest pain, back pain, nausea, vomiting, and fever. The condition of having gallstones is **cholelithiasis** (kō-li-lith-Ī-ă-sīs). See Figure 12.15² for an image of a gallstone in the gallbladder on an ultrasound. An inflamed gallbladder can be an urgent problem requiring immediate surgery or a slow response to long-term inflammation.³

2. “[Gallstone_in_neck_of_Gallbladder_on_CT.jpg](#)” by James Heilman, MD is licensed under [CC BY-SA 4.0](#)

3. Cleveland Clinic. (2023, September 21). *Cholecystitis*. <https://my.clevelandclinic.org/health/diseases/15265-gallbladder-swelling-inflammation-cholecystitis>

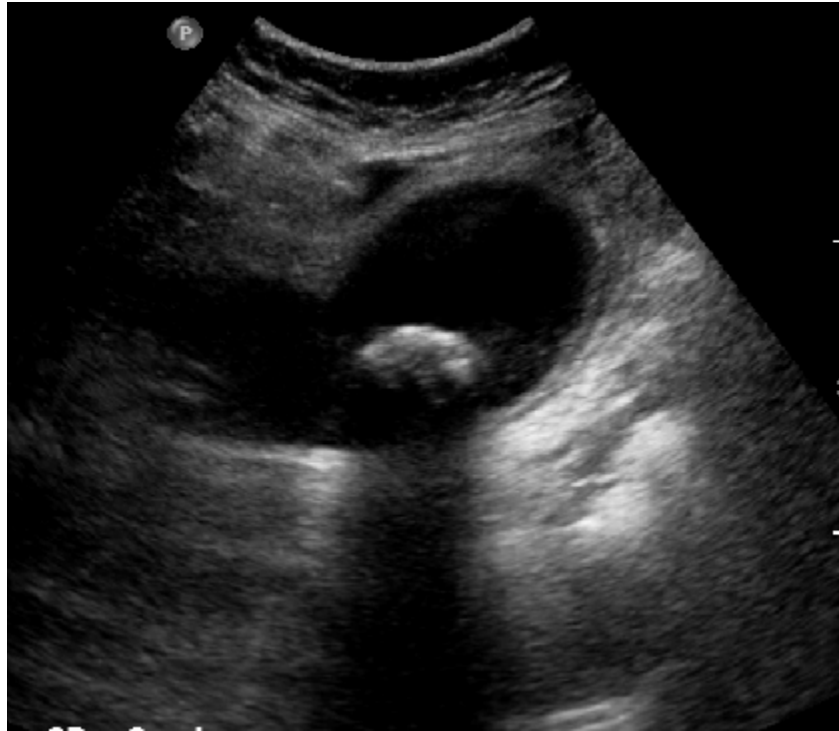

Figure 12.15 Gallstone in the Gallbladder on an Ultrasound

Cholecystitis is diagnosed with blood tests and an abdominal ultrasound. To remove gallstones, a procedure called an **endoscopic retrograde cholangiopancreatography** (en-dŏ-SKOP-ik rě-trŏ-grād kŏ-LAN-jě-ŏ-pan-krě-ă-TŎG-ră-fě) (**ERCP**) may be performed that combines an upper endoscopy with X-ray technology. The doctor visualizes the biliary system and then removes gallstones during an endoscopy to relieve immediate symptoms. **Cholecystectomy** (kŏ-lě-sis-TEK-tŏ-mě) refers to surgery to remove the gallbladder to prevent repeat episodes of gallbladder inflammation, typically performed with a **laparoscope** (LAP-ă-rŏ-skŏp), an instrument used to view the abdominal cavity.⁴

4. Cleveland Clinic. (2023, September 21). *Cholecystitis*.
<https://my.clevelandclinic.org/health/diseases/15265-gallbladder-swelling-inflammation-cholecystitis>

CIRRHOSIS

Cirrhosis (sĭr-RŌ-sĭs) is a serious, life-threatening condition where the liver becomes scarred and permanently damaged. The most common causes of cirrhosis are alcoholism and liver disease like hepatitis B or hepatitis C. Symptoms of cirrhosis may not appear until the liver is badly damaged and may include the following⁵:

- Fatigue and weakness
- Pruritis (itching of the skin)
- Poor appetite and weight loss without trying
- Nausea and vomiting
- Pain in the upper right side of the abdomen
- Easy bleeding and bruising
- **Ascites** (ă-SĪ-tēz), abdominal swelling due to fluid retention (See Figure 12.16⁶ for an image of ascites.)
- **Jaundice** (JAWN-dĭs), yellowed discoloration of the skin and eyes.

5. National Institute of Diabetes and Digestive and Kidney Diseases. (n.d.). *Cirrhosis*. National Institutes of Health. <https://www.niddk.nih.gov/health-information/liver-disease/cirrhosis>

6. “16650267836_edald47696_k.jpg” by John Campbell is licensed in the [Public Domain](#).

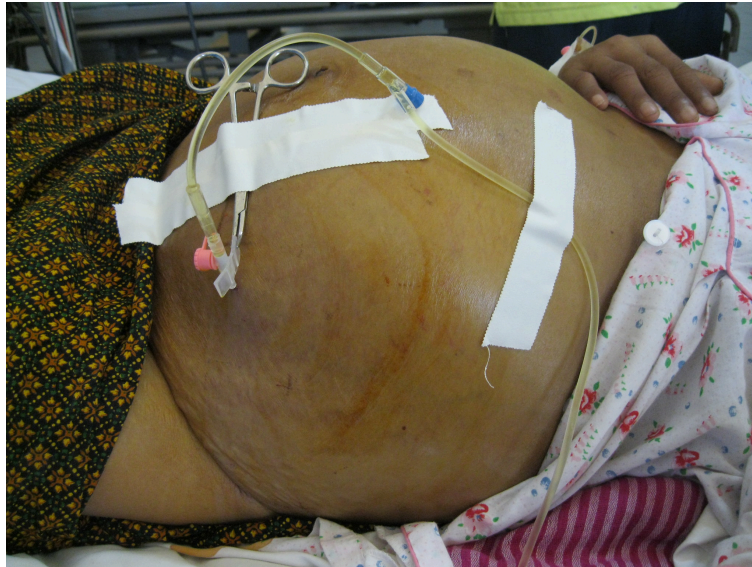

Figure 12.16 Ascites

Diagnostic testing for cirrhosis includes blood tests that evaluate liver function, liver ultrasound, CT scan, and liver biopsy. Treatment includes treating the cause of the cirrhosis, including treating infections and abstaining from alcohol.⁷

COLON CANCER

Colon cancer (KŌ-lŏn KAN-sĕr) is the third most common cancer diagnosed in people in the United States. It develops from polyps in the lining of the colon and typically affects people aged 50 years and older. Individuals can greatly reduce their risk for colon cancer by having regular screenings for

7. National Institute of Diabetes and Digestive and Kidney Diseases. (n.d.). *Cirrhosis*. National Institutes of Health. <https://www.niddk.nih.gov/health-information/liver-disease/cirrhosis>

polyps, including stool-based testing or a colonoscopy.⁸ Read more about these tests in the “[Medical Specialists, Diagnostic Testing, and Procedures Related to the Digestive System](#)” section.

Risk factors for colon cancer include a personal or family history of colon polyps or colon cancer and inflammatory bowel disease like Crohn’s disease and ulcerative colitis. Early symptoms of colon cancer include blood in the stool and persistent bowel changes like diarrhea and constipation. Colon cancer is diagnosed with biopsies taken during a colonoscopy.⁹

Depending on the severity of colon cancer, there are many types of surgeries that may be performed¹⁰:

- **Polypectomy** (pöl-ĭ-PĚK-tō-mē): Removal of polyps.
- **Partial colectomy** (pah-rshul kō-LEK-tō-mē), also called **colon resection surgery** (KŌ-lŏn rĭ-SĚK-shŭn SUR-jĕr-ē): The section of the colon containing the tumor is removed, and healthy colon sections are reattached in a procedure called **anastomosis** (ăn-ăs-tō-MŌ-sĭs).
- **Colon resection with colostomy** (KŌ-lŏn rĭ-SĚK-shŭn with kŏl-ŌS-tō-mē): The section of the colon that contains the tumor is removed, but healthy colon sections cannot be reattached, so a colostomy is performed. In a **colostomy** (kŏ-LOS-tō-mē), the colon is attached to an opening in the abdominal wall called a stoma. Instead of eliminating feces through the anus, it is collected in an external bag.
- **Radiofrequency ablation** (RĀ-dē-ō-FRĒ-kwĕn-sē ă-blā-shŭn): Heat is used during a procedure to destroy cancer cells.

8. Cleveland Clinic. (2022, November 14). *Colorectal (colon) cancer*.
<https://my.clevelandclinic.org/health/diseases/14501-colorectal-colon-cancer>

9. Cleveland Clinic. (2022, November 14). *Colorectal (colon) cancer*.
<https://my.clevelandclinic.org/health/diseases/14501-colorectal-colon-cancer>

10. Cleveland Clinic. (2022, November 14). *Colorectal (colon) cancer*.
<https://my.clevelandclinic.org/health/diseases/14501-colorectal-colon-cancer>

In addition to surgery, additional medical treatment may be required, such as chemotherapy or targeted therapy (treatment that targets the genes, proteins, and tissues that help colon cancer cells grow and multiply).¹¹

COLON POLYPS

Colon polyps (KŌ-lŏn PŎL-ĭps) are growths on the inner lining of the colon and rectum. See Figure 12.17¹² for an image of a colon polyp seen on colonoscopy. Most polyps are not cancerous, but some may develop into colon cancer over time. Anyone can develop colon polyps. Risk factors for developing colon polyps are age of 50 years or older, personal or family history of colon polyps or colon cancer, obesity, and smoking. People can greatly reduce their risk for colon cancer if polyps are removed in a procedure called a **polypectomy** (pŏl-ĭ-PĚK-tŏ-mē). Read more about these tests in the “[Medical Specialists, Diagnostic Testing, and Procedures Related to the Digestive System](#)” section.

11. Cleveland Clinic. (2022, November 14). *Colorectal (colon) cancer*.
<https://my.clevelandclinic.org/health/diseases/14501-colorectal-colon-cancer>

12. “600H0019.jpg” by [Vivat.iden](#) is licensed under [CC BY-SA 4.0](#)

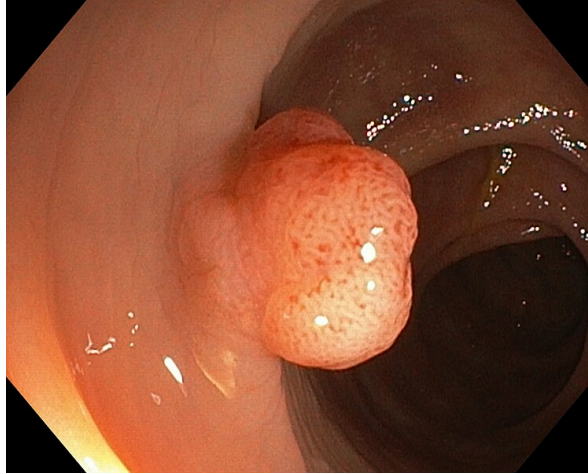


Figure 12.17 Colon Polyp

CROHN'S DISEASE AND ULCERATIVE COLITIS

Crohn's disease (krōnz diz-ĒZ) and **ulcerative colitis** (UL-sĕr-ă-tiv kō-LĪ-tĭs) are chronic inflammatory bowel diseases (IBD) that cause inflammation and ulcers in the digestive tract. See Figure 12.18¹³ for an image of ulcerative colitis on a colonoscopy, illustrating how the internal surface of the colon is blotchy and broken in places. Symptoms include abdominal pain, diarrhea, weight loss, and fatigue. These diseases are typically diagnosed with procedures like upper GI endoscopy, colonoscopy, and upper GI series.¹⁴ Read more about these procedures in the "[Medical Specialists, Diagnostic Testing, and Procedures Related to the Digestive System](#)" section.

13. "[UC_granularity.png](#)" by unknown author is licensed under [CC BY-SA 3.0](#)

14. National Institute of Diabetes and Digestive and Kidney Diseases. (n.d.). *Crohn's disease*. National Institutes of Health. <https://www.niddk.nih.gov/health-information/digestive-diseases/crohns-disease>

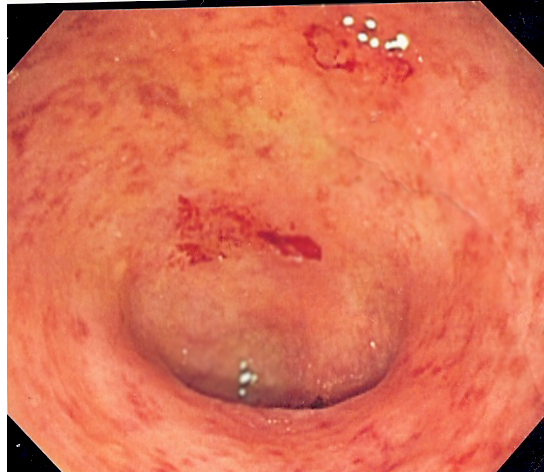


Figure 12.18 Ulcerative Colitis

Crohn's disease and ulcerative colitis are treated with medications, bowel rest, and surgery. No single treatment works for everyone with Crohn's disease. The goals of treatment are to decrease the inflammation in the intestines and prevent flare-ups of symptoms. Surgery may include **small bowel resection** (SMOL BOW-əl rī-SĚK-shŭn) or **large bowel resection** (LARJ BOW-əl rī-SĚK-shŭn), where part of the bowel is removed. In severe cases, **proctocolectomy** (prŏk-tō-kō-LEK-tŏ-mē) is performed where the entire colon and rectum are removed. An **ileostomy** (IL-ē-OS-tŏ-mē) is created, where part of the ileum is brought through an artificial opening in the abdomen called a **stoma** (STŌ-mă). A removable external collection pouch, called an **ostomy appliance** (ŎS-tŏ-mē ä-PLĪ-ăns), connects to the stoma and collects stool instead of it passing through the anus.¹⁵ See Figure 12.19¹⁶ for an illustration of an ileostomy and a stoma.

15. National Institute of Diabetes and Digestive and Kidney Diseases. (n.d.). *Crohn's disease*. National Institutes of Health. <https://www.niddk.nih.gov/health-information/digestive-diseases/crohns-disease>

16. "Ileostomy.png" by [BruceBlaus](#) is licensed under [CC BY-SA 4.0](#)

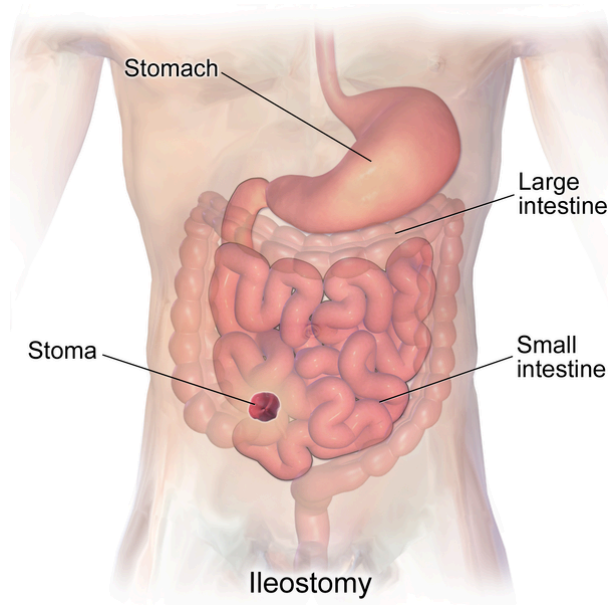


Figure 12.19 Ileostomy and Stoma

DIVERTICULOSIS AND DIVERTICULITIS

Diverticula (dī-věr-TIK-yū-lă) are small, bulging pouches that form in the lower part of the large intestine (colon). Diverticula are common, especially after age 40, and seldom cause problems. The presence of diverticula is known as **diverticulosis** (dī-věr-tik-yŭ-LŌ-sīs). See Figure 12.20¹⁷ for an illustration of diverticulosis. If one or more of the pouches become inflamed or infected, this condition is called **diverticulitis** (dī-věr-tik-yŭ-LĪT-īs). Diverticulitis can cause severe abdominal pain, fever, nausea, and a change in bowel habits. Diverticulitis is diagnosed with a CT scan, which can identify inflamed or infected pouches. Mild diverticulitis can be treated with rest, diet

¹⁷. “Sigmoid_diverticulum_(diagram).jpg” by Anpol42 is licensed under [CC BY-SA 4.0](#)

changes, and antibiotics. Severe or recurring diverticulitis may require bowel resection surgery.¹⁸

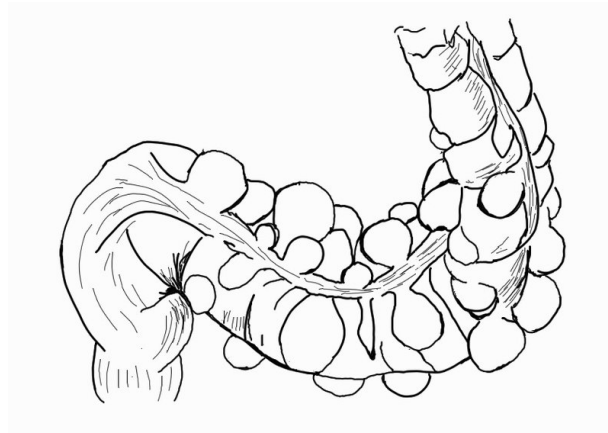


Figure 12.20 Diverticulosis

ESOPHAGEAL CANCER

Esophageal cancer (ĩ-sŏf-ă-JĚ-ăl KAN-sěr) starts in the tissues of the esophagus. Tumors caused by esophageal cancer may not cause noticeable symptoms until the cancer has spread. As the tumor grows, it starts to block the esophagus, and the person may have trouble swallowing or notice that it hurts to swallow. Esophageal cancer typically affects men who are age 60 or older and grows and spreads rapidly. Risk factors include tobacco use, alcohol use, obesity, chronic gastroesophageal reflux disease, and *Human papillomavirus (HPV)*. Diagnostic tests include an upper GI series or upper GI endoscopy with biopsy. An **esophagectomy** (ě-sŏf-ă-JĚK-tŏ-mě) is the most common treatment for early-stage esophageal cancer. It involves removing some or most of the esophagus and creating a new esophagus by pulling up

18. Mayo Clinic. (2022, April 19). *Diverticulitis*. <https://www.mayoclinic.org/diseases-conditions/diverticulitis/symptoms-causes/syc-20371758>

part of the stomach into the chest and neck. Chemotherapy, radiation, targeted therapy, and immunotherapy are also commonly prescribed treatments.¹⁹

GASTROESOPHAGEAL REFLUX DISEASE (GERD)

Gastroesophageal reflux disease (GAS-trō-ě-sōf-ă-JĒ-ăl REE-flŭks dĭ-ZĒZ) (**GERD**) occurs when stomach acid repeatedly flows back into the esophagus from the stomach. The acid irritates the lining of the esophagus and causes an ulcer. See Figure 12.21²⁰ for an illustration of GERD and backup of acid into the esophagus. GERD is typically diagnosed with a procedure called an upper GI endoscopy. Most people are able to manage the discomfort of GERD with lifestyle changes and medications.²¹ Read more about upper GI endoscopy in the “[Medical Specialists, Diagnostic Testing, and Procedures Related to the Digestive System](#)” section.

19. Cleveland Clinic. (2022, September 6). *Esophageal cancer*.
<https://my.clevelandclinic.org/health/diseases/6137-esophageal-cancer>
20. “[GastroEsophageal Reflux Disease \(GERD\).jpg](#)” by BruceBlaus is licensed under [CC BY-SA 4.0](#)
21. National Institute of Diabetes and Digestive and Kidney Diseases. (2020, July). *Diagnosis of GER & GERD*. National Institutes of Health.
<https://www.niddk.nih.gov/health-information/digestive-diseases/acid-reflux-ger-gerd-adults/diagnosis>

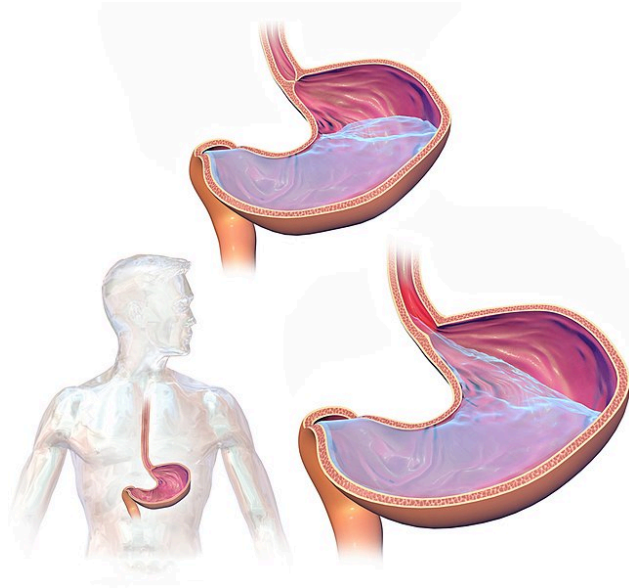


Figure 12.21 GERD

HEPATITIS

Hepatitis (hep-ă-TĪT-ĭs) is a general term used to describe inflammation of the liver. Liver inflammation can be caused by several viruses (such as hepatitis B and hepatitis C), drugs, excessive alcohol intake, genetic disorders, or by an overactive immune system that mistakenly attacks the liver, called autoimmune hepatitis. Symptoms include right upper quadrant abdominal pain, jaundice, light-colored stools, dark colored urine, fatigue, nausea, vomiting, and ascites (abdominal swelling due to fluid retention). See Figure 12.22²² for an image of jaundice. Hepatitis is diagnosed with blood tests, ultrasound of the liver, and liver biopsy. Treatment focuses on preventing further damage to the liver and cirrhosis.²³

22. “[Scleral_Icterus.jpg](#)” by [Sheila J. Toro](#) is licensed under [CC BY 4.0](#)

23. Johns Hopkins Medicine. (n.d.). *Hepatitis*. <https://www.hopkinsmedicine.org/health/conditions-and-diseases/hepatitis>

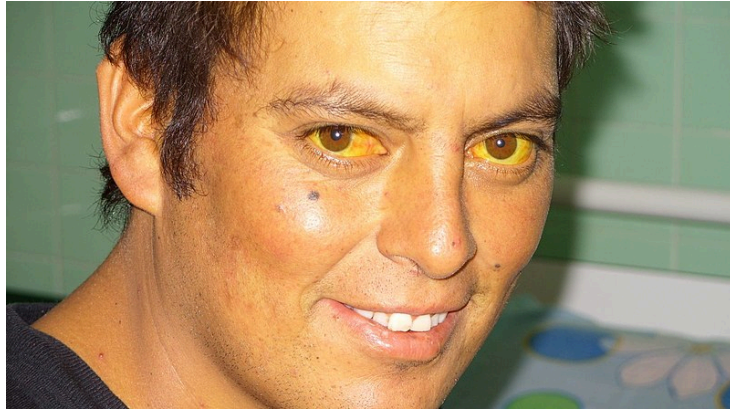

Figure 12.22 Jaundice

HERNIA

A hernia occurs when an organ or fatty tissue squeezes through a weak spot in a surrounding muscle or connective tissue. A **hiatal hernia** (hī-Ā-tāl HĔR-nē-ă) is a condition in which the upper part of the stomach bulges through an opening in the diaphragm. A large hiatal hernia can cause acid to back up into the esophagus, causing gastroesophageal reflux disorder (GERD). Medications usually resolve the GERD symptoms, but very large hiatal hernias may require surgery.²⁴

IRRITABLE BOWEL SYNDROME (IBS)

Irritable bowel syndrome (ĪR-ĭ-tă-bl BOWL SĪN-drōm) (**IBS**) is a group of

24. Mayo Clinic. (2021, February 23). *Hiatal hernia*. <https://www.mayoclinic.org/diseases-conditions/hiatal-hernia/symptoms-causes/syc-20373379>

symptoms that occur together, including repeated pain in the abdomen and changes in bowel movements, which may be diarrhea, constipation, or both. Individuals with IBS have these symptoms without any visible signs of damage or disease in the digestive tract. Health care providers diagnose IBS based on a medical history and physical exam. Diagnostic testing, like upper GI endoscopy and colonoscopy, may be performed to rule out other conditions. IBS is treated with diet changes.²⁵

PANCREATITIS

Pancreatitis (pan-krē-a-TĪT-īs) is inflammation of the pancreas. Pancreatitis can be an acute or chronic condition. Acute pancreatitis appears suddenly and lasts a short time. Chronic pancreatitis is a long-term condition, and the damage to the pancreas can get worse over time. Pancreatitis can be caused by blockage in the bile duct caused by gallstones, heavy alcohol use, diabetes, and pancreatic cancer. However, sometimes a cause is never found. Severe pancreatitis requires treatment in a hospital and can cause life-threatening complications.²⁶

25. National Institute of Diabetes and Digestive and Kidney Diseases. (n.d.). *Irritable bowel syndrome*. National Institutes of Health. <https://www.niddk.nih.gov/health-information/digestive-diseases/irritable-bowel-syndrome>

26. Mayo Clinic. (2023, September 23). *Pancreatitis*. <https://www.mayoclinic.org/diseases-conditions/pancreatitis/symptoms-causes/syc-20360227>

PEPTIC ULCER DISEASE

Peptic ulcer disease (PĚP-tĭk UL-sĕr dĭ-ZĚZ) (**PUD**) refers to ulcers in the stomach lining (gastric ulcers) or the duodenum (duodenal ulcers). See Figure 12.23²⁷ for an image of an ulcer on an upper endoscopy. PUD can cause complications such as bleeding, perforation, or blockage in the stomach or duodenum. A common symptom of PUD is pain in the upper part of the abdomen. Common causes of PUD are *Helicobacter pylori* (*H. pylori*) infection and use of nonsteroidal anti-inflammatory drugs (NSAIDs) like aspirin, ibuprofen, and naproxen.²⁸

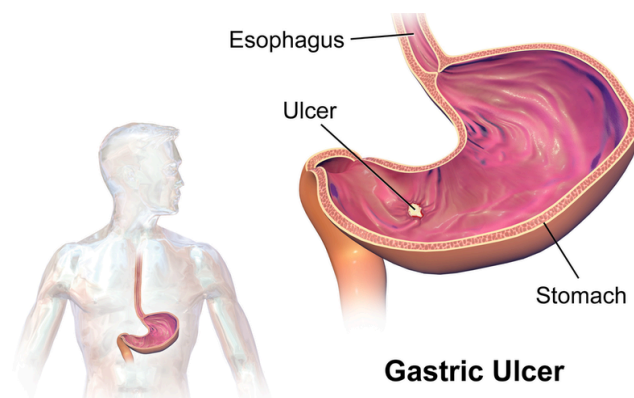


Figure 12.23 Gastric Ulcer

Common diagnostic tests for PUD include blood tests for *H. pylori*, a urea breath test, an upper GI endoscopy, or an upper GI series. In a **urea breath**

27. “Gastric_Ulcer.png” by BruceBlaus is licensed under CC BY-SA 4.0

28. National Institute of Diabetes and Digestive and Kidney Diseases. (n.d.). *Peptic ulcers (stomach and duodenal ulcers)*. National Institutes of Health. <https://www.niddk.nih.gov/health-information/digestive-diseases/peptic-ulcers-stomach-ulcers>

test (yöŏ-RĒ-ă brĕth tĕst), the patient swallows a capsule, liquid, or pudding that contains urea that is “labeled” with a special carbon atom. If *H. pylori* is present, the bacteria convert the urea into carbon dioxide. After a few minutes, the patient breathes into a container, exhaling carbon dioxide. The exhaled breath is evaluated by a medical lab technician. If the test detects the labeled carbon atoms, an *H. pylori* infection is confirmed.²⁹ Read more about upper GI endoscopy and upper GI series in the “[Medical Specialists, Diagnostic Testing, and Procedures Related to the Digestive System](#)” section.

PERITONITIS

Peritonitis (per-īt-ŏ-NĪT-īs) refers to inflammation of the peritoneum, the tissue that lines the inside of the abdominal cavity. It is typically caused by an infection or by leakage of body fluids from one of the abdominal organs (such as an inflamed appendix, intestine, pancreas, or gallbladder). Infection of the peritoneum is especially dangerous because it can impact the functioning of the abdominal organs and also transfer bacteria to the bloodstream where it can cause a life-threatening infection called sepsis. Health care providers treat peritonitis as an emergency because it can become severe very quickly. It is treated with intravenous antibiotics. Common symptoms of peritonitis are as follows³⁰:

- Mild to severe abdominal pain with sensitivity to touch

29. National Institute of Diabetes and Digestive and Kidney Diseases. (n.d.). *Peptic ulcers (stomach and duodenal ulcers)*. National Institutes of Health. <https://www.niddk.nih.gov/health-information/digestive-diseases/peptic-ulcers-stomach-ulcers>

30. Cleveland Clinic. (2022, November 2). *Peritonitis*. <https://my.clevelandclinic.org/health/diseases/17831-peritonitis>

- Swollen, distended abdomen
- **Paralytic ileus** (pă-r-ă-LĭT-ĭk Ī-lē-ŭs), which is when the bowels become temporarily paralyzed

12.7 Medical Specialists, Diagnostic Testing, and Procedures Related to the Digestive System

MEDICAL SPECIALISTS

Gastroenterology

Gastroenterology (găs-trō-ěn-těr-ŎL-ă-jē) is the study of the normal function and diseases of the esophagus, stomach, small intestine, colon and rectum, pancreas, gallbladder, bile ducts, and liver. A physician who specializes in the diagnosis and treatment of gastrointestinal disorders is known as a **gastroenterologist** (găs-trō-ěn-těr-ŎL-ŏ-jĭst).

A **colorectal surgeon** (kō-lō-REK-tăl SUR-jĕn) is a surgeon who specializes in conditions affecting the large intestine (i.e., colon, rectum, and anus.) A **proctologist** (prok-TOL-ŏ-jĭst) is a physician who specializes in the diagnosis and treatment of diseases of the rectum.

▶ To learn more about gastroenterology, visit the [American College of Gastroenterology web page](#).

DIAGNOSTIC TESTS

Barium Enema

A **barium enema** (BĀR-ē-ŭm EN-ĕ-mă) is a diagnostic procedure involving the use of a contrast material known as barium. Barium is a chalky material that appears white on X-ray and coats the inner wall of the large intestine for visualization. During the procedure, barium is administered into the rectum, along with air (that appears black on X-ray). Fluoroscopy is often used during a barium enema. During fluoroscopy, a continuous X-ray is passed through the large intestine and is transmitted to a monitor so the movement of the barium through the large intestine can be visualized as it is instilled through the rectum. After the procedure, if the barium isn't completely eliminated from the body, constipation or fecal impaction may occur.¹ See Figure 12.24² for an image of a barium enema showing herniation of the colon. The barium causes the colon to appear white on the left side of the image, and air in the colon causes it to appear black on the right side of the image.

1. Johns Hopkins Medicine. (n.d.). *Barium enema*.

<https://www.hopkinsmedicine.org/health/treatment-tests-and-therapies/barium-enema>

2. “[Colonic Herniation_08787.jpg](#)” by [Nevit Dilmen](#) (talk) is licensed under [CC BY-SA 3.0](#)

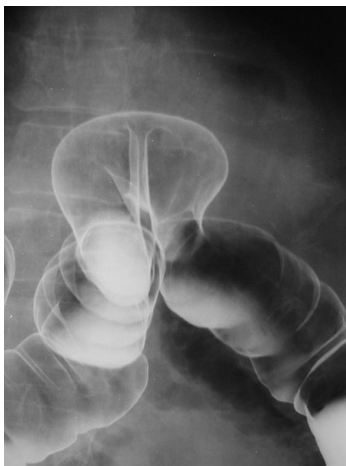


Figure 12.24 Barium Enema Showing Colon Herniation

Colonoscopy

A **colonoscopy** (köl-ŏn-OS-kŏ-pē) is a procedure that examines the inside of the large intestine, including the colon, rectum, and anus. A **sigmoidoscopy** (sig-moy-DOS-kŏ-pē) is a similar procedure but only examines the sigmoid colon. During both procedures, the physician uses an **endoscope** (EN-dŏ-skŏp), a flexible tube with a lighted camera on the end that is inserted into the anus and colon. Along the way, it sends pictures of the inside of the large intestine to a screen. The physician can take biopsies during these procedures and also remove polyps.³ See Figure 12.25⁴ for an illustration of a colonoscopy.

3. Cleveland Clinic. (2022, November 30). *Colonoscopy*.

<https://my.clevelandclinic.org/health/diagnostics/4949-colonoscopy>

4. “[Diagram showing a colonoscopy CRUK_060.svg](#)” by [Cancer Research UK](#). Wikimedia Commons is licensed under [CC BY-SA 4.0](#)

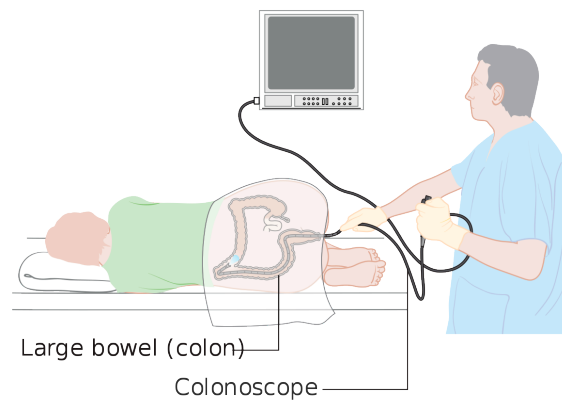


Figure 12.25 Colonoscopy

The American Cancer Society recommends routine colonoscopy screening for colon cancer for individuals of average risk starting at age 45.⁵ Colonoscopies are also used to diagnose medical conditions like inflammatory bowel disease or colon cancer.

Colonoscopy prep is very important to the success of the procedure. The health care provider provides detailed instructions to the patient to follow in the days leading up to the procedure. The purpose of these preparations is to make sure the large intestine is as clear as possible for visualization of the tissue. Typically, a low-fiber diet is followed for two or three days, followed by a clear liquid diet on the day before the procedure. The afternoon before the colonoscopy, a strong laxative is taken to purge the bowels.⁶

5. American Cancer Society. (2020, November 17). *American Cancer Society guideline for colorectal cancer screening*. <https://www.cancer.org/cancer/types/colon-rectal-cancer/detection-diagnosis-staging/acs-recommendations.html>

6. Cleveland Clinic. (2022, November 30). *Colonoscopy*. <https://my.clevelandclinic.org/health/diagnostics/4949-colonoscopy>

Upper GI Endoscopy

During an **upper GI endoscopy** (ŮP-ěr Jī ěn-DŎS-kŏ-pē en-DOS-kŏ-pē), also called an **esophagogastroduodenoscopy** (ē-sof-ă-gŏ-gas-trō-doo-ŏ-dē-NOS-kŏ-pē) (**EGD**), a doctor uses a flexible tube with a camera to see the lining of the upper gastrointestinal tract, including the esophagus, stomach, and duodenum. During upper GI endoscopy, biopsies may be taken by passing an instrument through the endoscope to take small pieces of tissue from the lining of the esophagus. A pathologist examines the tissue under a microscope.⁷ See Figure 12.26⁸ for an image of an upper GI endoscopy.

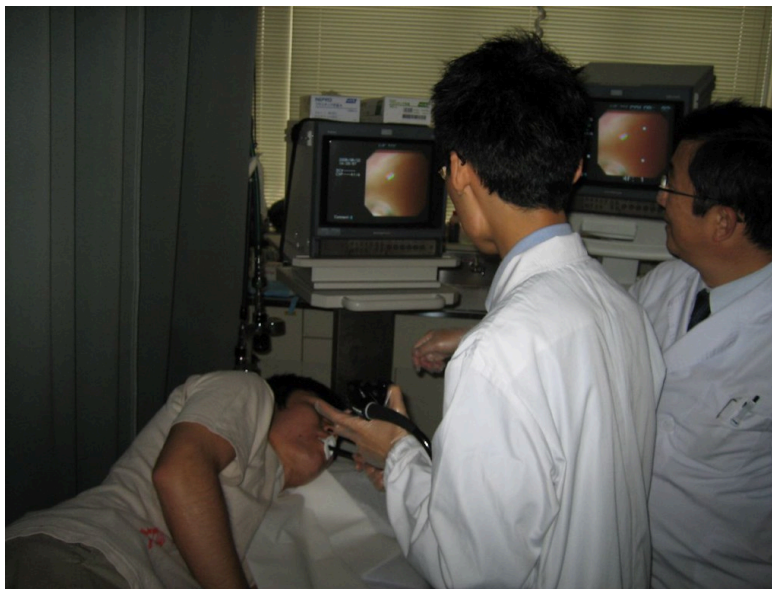

Figure 12.26 Upper GI Endoscopy

7. National Institute of Diabetes and Digestive and Kidney Diseases. (2020, July). *Diagnosis of GER & GERD*. National Institutes of Health. <https://www.niddk.nih.gov/health-information/digestive-diseases/acid-reflux-ger-gerd-adults/diagnosis>

8. “180619235_391dec588d_b.jpg” by Yuya Tamai is licensed under [CC BY 2.0](https://creativecommons.org/licenses/by/2.0/)

Upper GI Series

An **upper gastrointestinal series** (ŮP-ěr GAS-trō-in-TĚS-tĩ-năl SĪR-ēz) is an X-ray examination of the upper gastrointestinal (GI) tract. The esophagus, stomach, and duodenum are made visible on X-ray film by a liquid suspension that may be barium or a water-soluble contrast. If only the pharynx and esophagus are examined with barium, the procedure is called a **barium swallow** (BĀR-ē-ŭm SWŎL-ō). Fluoroscopy is often used during an upper GI series to allow the radiologist to visualize the movement of the barium through the esophagus, stomach, and duodenum as a person drinks. After the procedure, if barium is not completely eliminated from the body, constipation and fecal impaction can occur.⁹ See Figure 12.27¹⁰ for an image of an upper GI series that shows a hernia and an obstruction. The barium causes the stomach and esophagus to appear white.

9. Johns Hopkins Medicine. (n.d.). *Upper gastrointestinal series*.

<https://www.hopkinsmedicine.org/health/treatment-tests-and-therapies/upper-gastrointestinal-series>

10. “Radiology_0014_Nevit.jpg” by [Nevit Dilmen](#) (talk) is licensed under [CC BY-SA 3.0](#)

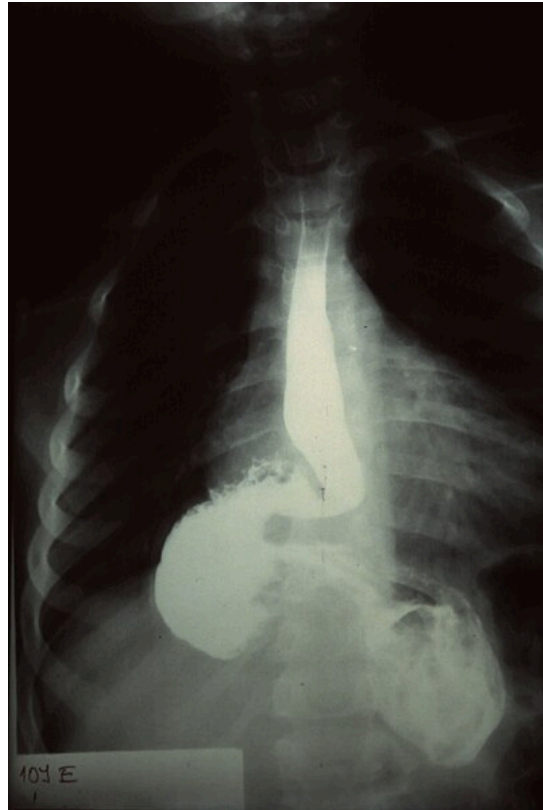


Figure 12.27 Upper GI Series Showing a Hernia and Obstruction

Stool-Based Tests

The U.S. Preventive Services Task Force recommends that adults aged 45 to 75 be screened for colorectal cancer. Several stool-based tests can be used to screen for polyps or colorectal cancer¹¹:

- **Fecal occult blood test** (FĒ-kāl ō-KULT blūd tĕst) (**FOBT**) or (**gFOBT**): Uses a chemical called guaiac to detect blood in the stool. For this test, the patient receives a test kit from their health care provider. At home, they

11. Centers for Disease Control and Prevention. (2023, February 23). *Colorectal cancer screening tests*. U.S. Department of Health & Human Services. https://www.cdc.gov/cancer/colorectal/basic_info/screening/tests.htm

use a small stick or brush to obtain a small amount of stool and place it on a card. The test kit is returned to a lab, where the stool sample is checked for the presence of blood.

- **Fecal immunochemical test** (FĒ-kāl im-yŭn-Ō-kēm-ĭ-kāl tĕst): Uses antibodies to detect blood in the stool.
- **Stool DNA test** (stōōl dē-ĕn-ā tĕst): Combines the fecal immunochemical test with a test that detects altered DNA in the stool. For this test, an entire bowel movement is collected and sent to a lab, where it is checked for altered DNA and the presence of blood.

If a stool test is positive, then a colonoscopy is scheduled for follow-up testing. See Figure 12.28¹² for an image of a stool specimen container.



Figure 12.28 Stool Specimen Container

12. “[Stool_specimen_container.jpg](#)” by [Whispyhistory](#) is licensed under [CC BY-SA 4.0](#)

Stool Culture

A **stool culture** (stōōl KUL-chŭr) is a test that detects and identifies bacteria that cause infections of the lower digestive tract. The test distinguishes between the types of bacteria that cause disease (pathogenic) and the types that are normally found in the digestive tract (normal flora). The test helps to determine if pathogenic bacteria are the cause of a person's gastrointestinal symptoms.¹³

13. Testing.com. (2021, November 9). *Stool culture*. <https://www.testing.com/tests/stool-culture>

12.8 Digestive System Learning Activities

Interactive Learning Activity: Label the parts of the digestive system.



An interactive H5P element has been excluded from this version of the text. You can view it online here:

<https://wtcs.pressbooks.pub/medterm/?p=518#h5p-110>

Interactive Learning Activity: Study digestive system medical terms discussed in this chapter using these flashcards.



An interactive H5P element has been excluded from this version of the text. You can view it online here:

<https://wtcs.pressbooks.pub/medterm/?p=518#h5p-186>

Interactive Learning Activity: Test yourself on these digestive related terms.



An interactive H5P element has been excluded from this version of the text. You can view it online here:

<https://wtcs.pressbooks.pub/medterm/?p=518#h5p-115>

Interactive Learning Activity: Test yourself on digestive system terms.



An interactive H5P element has been excluded from this version of the text. You can view it online here:

<https://wtcs.pressbooks.pub/medterm/?p=518#h5p-109>

Interactive Learning Activity: Using the sample documentation provided, drag the terms on the right to their appropriate spaces within the documentation.



An interactive H5P element has been excluded from this version of the text. You can view it online here:

<https://wtcs.pressbooks.pub/medterm/?p=518#h5p-113>

Interactive Learning Activity: Using the sample documentation provided, drag the terms on the right to their appropriate spaces within the documentation.



An interactive H5P element has been excluded from this version of the text. You can view it online here:

<https://wtcs.pressbooks.pub/medterm/?p=518#h5p-114>



Interactive Learning Activity: Practice identifying and defining word parts for terms discussed in this chapter.



An interactive H5P element has been excluded from this version of the text. You can view it online here:

<https://wtcs.pressbooks.pub/medterm/?p=518#h5p-203>

- ▶ You can also print this as a [Chapter 12 Practice Worksheet](#) and check your answers with this [Answer Key PDF](#).

12.9 Glossary

Absorption (ab-SORP-shŏn): The process in which nutrients enter the bloodstream after food molecules have been broken down during chemical digestion. ([Chapter 12.5](#))

Adhesion (ad-HĒ-zhŏn): Scar tissue from disease or previous surgery that binds anatomical surfaces to each other. ([Chapter 12.5](#))

Amino acids (Ā-mē-nō AS-idz): Molecules that combine to form proteins. ([Chapter 12.5](#))

Amylase (ĀM-ĭ-lās): An enzyme, produced chiefly in the pancreas and salivary glands, that converts starch and glycogen into simple sugars. ([Chapter 12.4](#))

Anal (ĀN-ăl): Pertaining to the anus, the opening at the end of the digestive tract from which feces exit the body. ([Chapter 12.4](#))

Anastomosis (ăn-ăs-tō-MŌ-sĭs): A surgical connection between two tubes, vessels, or ducts. ([Chapter 12.6](#))

Anus (Ā-nŭs): The opening at the end of the digestive tract where feces leave the body. ([Chapter 12.4](#))

Appendectomy (ap-ĕn-DEK-tŏ-mē): Surgical removal of the appendix. ([Chapter 12.4](#))

Appendicitis (ă-pen-dĭ-SĪT-ĭs): Inflammation of the appendix. ([Chapter 12.4](#))

Appendix (ă-PEN-dĭks): A tube-shaped sac attached to and opening into the lower end of the large intestine. ([Chapter 12.4](#))

Ascending colon (ă-SEN-dĭng KŌ-lŏn): The first part of the colon which travels upward on the right side of the abdomen. ([Chapter 12.4](#))

Ascites (ă-SĪ-tēz): Abnormal fluid buildup in the abdominal cavity, causing abdominal swelling, often due to liver disease or cancer. ([Chapter 12.5](#), [Chapter 12.6](#))

Barium enema (BĀR-ē-ŭm EN-ĕ-mă): An X-ray exam that can detect changes or abnormalities in the large intestine (colon). ([Chapter 12.7](#))

Barium swallow (BĀR-ē-ŭm SWŌL-ŏ): A test that checks for problems in the throat, esophagus, stomach, and small intestine. ([Chapter 12.7](#))

Bile (BĪL): A bitter, greenish-brown alkaline fluid that aids digestion, secreted by the liver and stored in the gallbladder. ([Chapter 12.4](#))

Bilirubin (bil-ĭ-ROO-bin): A yellowish pigment formed in the liver by the breakdown of red blood cells. ([Chapter 12.4](#))

Bolus (BŌL-ūs): A soft mass of food that is an appropriate size for swallowing. ([Chapter 12.5](#))

Cecum (SĒ-kŭm): The first section of the large intestine, into which the ileum opens. ([Chapter 12.4](#))

Celiac disease (SĒ-lē-āk dĭ-ZĒZ): A serious autoimmune disorder that can occur in genetically predisposed people where the ingestion of gluten leads to damage in the small intestine. ([Chapter 12.6](#))

Cholecystectomy (kō-lě-sis-TEK-tŏ-mē): Surgical removal of the gallbladder. ([Chapter 12.6](#))

Cholecystitis (kō-lě-sis-TĪT-ĭs): Inflammation of the gallbladder, often due to a gallstone blocking the cystic duct. ([Chapter 12.4](#), [Chapter 12.6](#))

Cholelithiasis (kō-li-lith-Ī-ă-sĭs): The formation of gallstones in the gallbladder. ([Chapter 12.4](#), [Chapter 12.6](#))

Chyme (KĪM): The pulpy acidic fluid that passes from the stomach to the small intestine, consisting of gastric juices and partly digested food. ([Chapter 12.4](#))

Cirrhosis (sĭr-RŌ-sĭs): A chronic disease of the liver marked by degeneration of cells, inflammation, and fibrous thickening of tissue. It is often caused by alcoholism or hepatitis. ([Chapter 12.6](#))

Colon cancer (KŌ-lŏn KAN-sĕr): A type of cancer that occurs in the colon or rectum, part of the large intestine, where malignant cells form in the tissues of the colon. ([Chapter 12.6](#))

Colon polyps (KŌ-lŏn PŌL-ĭps): Small clumps of cells that form on the lining of the colon, which can become cancerous over time. ([Chapter 12.6](#))

Colon resection surgery (KŌ-lŏn rĭ-SĔK-shŭn SUR-jĕr-ē): A surgical procedure to remove a section of the colon. ([Chapter 12.6](#))

Colon resection with colostomy (KŌ-lŏn rĭ-SĔK-shŭn wĭth kŏl-ŌS-tŏ-mē): A surgical procedure where part of the colon is removed and the remaining colon is brought to the abdominal surface. ([Chapter 12.6](#))

Colonoscopy (kŏl-ŏn-OS-kŏ-pē): A test that allows your doctor to look at

the inner lining of your large intestine (rectum and colon) using a thin, flexible tube called a colonoscope. ([Chapter 12.7](#))

Colorectal surgeon (kō-lō-REK-tāl SUR-jěn): A doctor who specializes in the surgical treatment of conditions of the colon, rectum, and anus. ([Chapter 12.7](#))

Colostomy (kō-LOS-tō-mē): A surgical procedure that brings one end of the large intestine out through the abdominal wall to carry stool out of the body. ([Chapter 12.6](#))

Crohn's disease (krōnz diz-ĒZ): A chronic inflammatory bowel disease that affects the lining of the digestive tract. ([Chapter 12.6](#))

Defecation (děf-ě-KĀ-shŏn): The final step in digestion when undigested materials are expelled from the body as feces. ([Chapter 12.5](#))

Descending colon (dě-SEN-ding KŌ-lŏn): The part of the colon that travels downward on the left side of the abdomen. ([Chapter 12.4](#))

Digestion (dī-JĒS-tion): The process by which food is broken down into absorbable units. ([Chapter 12.4](#))

Diverticula (dī-věr-TIK-yū-lă): Small, bulging pouches that can form in the lining of the digestive system. ([Chapter 12.6](#))

Diverticulitis (dī-věr-tik-yŭ-LĪT-īs): Inflammation or infection of one or more diverticula in the digestive tract. ([Chapter 12.6](#))

Diverticulosis (dī-věr-tik-yŭ-LŌ-sīs): The condition of having diverticula in the colon. ([Chapter 12.6](#))

Duodenum (dū-ō-DE-nŭm): The first section of the small intestine, immediately beyond the stomach, leading to the jejunum. ([Chapter 12.4](#))

Dysentery (DIS-ěn-ter-ē): An inflammatory disorder of the intestine, especially of the colon, that results in severe diarrhea containing blood and mucus in the feces with fever, abdominal pain, and rectal tenesmus. ([Chapter 12.5](#))

Dyspepsia (dīs-PEP-sē-ă): Indigestion or upset stomach, marked by epigastric pain, burning, and nausea. ([Chapter 12.5](#))

Dysphagia (dīs-FĀj-ē-ă): Difficulty or discomfort in swallowing. ([Chapter 12.4](#))

Emesis (ĚM-ě-sīs): The act of vomiting or ejecting stomach contents through the mouth. ([Chapter 12.5](#))

Endocrine (EN-dŏ-krīn): Relating to glands which secrete hormones or other products directly into the blood. ([Chapter 12.4](#))

Endoscope (EN-dŏ-skōp): An instrument used for visual examination of the interior of a hollow body organ. ([Chapter 12.7](#))

Endoscopic retrograde cholangiopancreatography (en-dŏ-SKOP-ik rě-trō-grād kō-LAN-jē-ō-pan-krē-ă-TŎG-ră-fē) (ERCP): A procedure used to diagnose and treat problems in the liver, gallbladder, bile ducts, and pancreas. ([Chapter 12.6](#))

Enzymes (EN-zīmz): Substances produced by a living organism that act as a catalyst to bring about a specific biochemical reaction. ([Chapter 12.5](#))

Epiglottis (ěp-ĭ-GLŎT-ĭs): A flap of cartilage at the root of the tongue, which is depressed during swallowing to cover the opening of the windpipe. ([Chapter 12.4](#))

Esophageal cancer (ĭ-sŏf-ă-JĒ-ăl KAN-sěr): A type of cancer that occurs in the esophagus, the long, hollow tube that runs from the throat to the stomach. ([Chapter 12.6](#))

Esophageal varices (ě-sŏf-ă-JĒ-ăl VĀR-ĭ-sēz): Abnormally swollen veins in the lower part of the esophagus, often associated with liver disease. ([Chapter 12.4](#))

Esophagectomy (ě-sŏf-ă-JĚK-tŏ-mē): A surgical procedure to remove part or all of the esophagus. ([Chapter 12.6](#))

Esophagogastroduodenoscopy (ē-sof-ă-gō-gas-trō-doo-ŏ-dē-NOS-kŏ-pē) (EGD): A diagnostic test to examine the lining of the esophagus, stomach, and first part of the small intestine. ([Chapter 12.7](#))

Esophagus (ĭ-SOF-ă-gŭs): The muscular tube that conveys food and liquids from the throat to the stomach. ([Chapter 12.4](#))

Exocrine (ĚK-sŏ-krīn): Pertaining to the secretion of a substance out through a duct. ([Chapter 12.4](#))

Fecal immunochemical test (FĒ-kăl im-yŭn-Ŏ-kēm-ĭ-kăl tĕst): A test that checks stool for tiny amounts of blood released by polyps or colorectal cancer. ([Chapter 12.7](#))

Fecal occult blood test (FĒ-kăl ŏ-KULT blŭd tĕst) (gFOBT): A test that checks stool samples for hidden (occult) blood using a chemical called guaiac. ([Chapter 12.7](#))

Feces (FĒ-sēz): Waste matter discharged from the bowels after food has been digested. ([Chapter 12.4](#))

Flatus (FLĀ-tūs): Gas in the gastrointestinal tract, expelled through the anus. ([Chapter 12.4](#), [Chapter 12.5](#))

Gallbladder (GAWL-blād-ěr): A small organ where bile is stored, before it is released into the small intestine. ([Chapter 12.4](#))

Gallstone (GAWL-stōn): A small, hard crystalline mass formed abnormally in the gallbladder or bile ducts from bile pigments, cholesterol, and calcium salts. ([Chapter 12.6](#))

Gastric juice (GAS-trīk JOOS): A digestive fluid secreted by the stomach, containing hydrochloric acid, pepsin, and other enzymes. ([Chapter 12.4](#))

Gastroenteritis (GAS-trō-ěn-těr-Ī-tīs): Inflammation of the stomach and intestines, typically resulting from bacterial toxins or viral infection and causing vomiting and diarrhea. ([Chapter 12.5](#))

Gastroenterologist (gās-trō-ěn-těr-ŌL-ō-jīst): A physician who specializes in the diagnosis and treatment of diseases of the digestive system. ([Chapter 12.7](#))

Gastroenterology (gās-trō-ěn-těr-ŌL-ă-jē): The study of the digestive system and its disorders. ([Chapter 12.7](#))

Gastroesophageal reflux disease (GAS-trō-ě-sōf-ă-JĒ-ăl REE-flŭks dĩ-ZĒZ) (GERD): A chronic condition where stomach acid or bile flows into the food pipe (esophagus) and irritates the lining. ([Chapter 12.4](#), [Chapter 12.6](#))

Gingivitis (jin-jī-VĪT-īs): Inflammation of the gums. ([Chapter 12.4](#))

Glossitis (glo-SĪT-īs): Inflammation of the tongue. ([Chapter 12.4](#))

Hard palate (HARD PAL-āt): The bony front part of the palate. ([Chapter 12.4](#))

Hemorrhoid (HEM-ō-royd): A swollen vein or group of veins in the region of the anus. ([Chapter 12.4](#))

Hepatitis (hep-ă-TĪT-īs): Inflammation of the liver, usually caused by a viral infection or liver toxins. ([Chapter 12.6](#))

Hepatomegaly (hep-ăt-ō-MEG-ă-lē): An enlarged liver. ([Chapter 12.4](#))

Hernia (HUR-nē-ă): A condition in which part of an organ is displaced and protrudes through the wall of the cavity containing it, often involving the intestine at a weak point in the abdominal wall. ([Chapter 12.5](#), [Chapter 12.6](#))

Hiatal hernia (hī-Ā-tăl HĒR-nē-ă): A type of hernia in which abdominal

organs (typically the stomach) slip through the diaphragm into the middle compartment of the chest. ([Chapter 12.6](#))

Hydrochloric acid (HĪ-drō-klōr-ĪK AS-id): A component of gastric juice that helps create the acidic environment in the stomach. ([Chapter 12.4](#))

Ileocecal valve (ĪL-ē-ō-SĒ-kāl VALV): A sphincter muscle valve that separates the small intestine and the large intestine. ([Chapter 12.4](#))

Ileostomy (IL-ē-OS-tō-mē): A surgical opening constructed by bringing the end of the small intestine (the ileum) out onto the surface of the skin. ([Chapter 12.6](#))

Ileum (ĪL-ē-ŭm): The third portion of the small intestine, between the jejunum and the cecum of the large intestine. ([Chapter 12.4](#))

Irritable bowel syndrome (ĪR-ĭ-tă-bl BOWL SĪN-drōm) (IBS): A common disorder affecting the large intestine, causing cramping, abdominal pain, bloating, gas, diarrhea, and constipation. ([Chapter 12.6](#))

Jaundice (JAWN-dīs): A medical condition with yellowing of the skin or whites of the eyes, arising from excess of the pigment bilirubin. ([Chapter 12.4](#), [Chapter 12.6](#))

Jejunum (jĭ-JŪ-num): The part of the small intestine between the duodenum and ileum. ([Chapter 12.4](#))

Laparoscope (LAP-ă-rō-skōp): A thin tube with a camera and light at the end, used for viewing the interior of the abdominal or pelvic cavities. ([Chapter 12.6](#))

Large bowel resection (LARJ BOW-ěl rĭ-SĚK-shŭn): Surgical removal of part of the large intestine. ([Chapter 12.6](#))

Large intestine (LARJ IN-tēs-tĭn): The last part of the digestive system, absorbing water and electrolytes, forming and storing feces. ([Chapter 12.4](#))

Lipase (LĪ-pās): An enzyme that catalyzes the hydrolysis of fats (lipids). ([Chapter 12.4](#))

Liver (LIV-ěr): A large lobed glandular organ in the abdomen, involved in many metabolic processes. ([Chapter 12.4](#))

Lower esophageal sphincter (LOH-ěr ĭ-SOF-ă-gě-al SFINGK-těr): A ring of muscle at the end of the esophagus where it meets the stomach, which acts as a valve to prevent the backflow of stomach contents. ([Chapter 12.4](#))

Melena (mě-LĚ-nǎ): Dark sticky feces containing partly digested blood, indicative of gastrointestinal bleeding. ([Chapter 12.5](#))

Nausea (NAW-zē-ǎ): A feeling of sickness with an inclination to vomit. ([Chapter 12.5](#))

NPO (en-pē-ō): A commonly used medical abbreviation for “nil per os,” the Latin phrase that means “nothing by mouth.” ([Chapter 12.5](#))

Nutrients (NŪ-trē-ěntz): Substances that provide nourishment to cells. ([Chapter 12.5](#))

Obesity (ō-BĚ-sī-tē): A medical condition in which excess body fat has accumulated to an extent that it may have a negative effect on health. ([Chapter 12.5](#))

Oral cavity (ŌR-ǎl KAV-ī-tē): The mouth area, encompassing the lips, cheeks, palate, and floor of the mouth. ([Chapter 12.4](#))

Ostomy appliance (ŎS-tō-mē ǎ-PLĪ-ǎns): A device used to collect waste from a surgically diverted biological system (such as a colostomy, ileostomy). ([Chapter 12.6](#))

Palpate (PAL-pāt): Examine (a part of the body) by touch, especially for medical purposes. ([Chapter 12.5](#))

Pancreas (PAN-krē-ǎs): A large gland behind the stomach which secretes digestive enzymes into the duodenum. ([Chapter 12.4](#))

Pancreatitis (pǎn-krē-a-TĪT-īs): Inflammation of the pancreas. ([Chapter 12.6](#))

Paralytic Ileus (pǎr-ǎ-LĪT-īk Ī-lē-ūs): A condition in which the intestine does not work properly and there is no movement of food or waste in the intestine. ([Chapter 12.6](#))

Partial colectomy (pǎr-shul kō-LEK-tō-mē): A surgical procedure to remove part of the colon and is used to treat or prevent diseases and conditions that affect the colon. ([Chapter 12.6](#))

Peptic ulcer disease (PĚP-tĭk UL-sěr dĩ-ZĚZ) (PUD): A condition where ulcers form on the lining of the stomach, lower esophagus, or small intestine, typically caused by inflammation due to H. pylori bacteria and the use of NSAIDs. ([Chapter 12.6](#))

Percutaneous endoscopic gastrostomy (pûr-kû-TĀ-nē-ūs ěn-DŎS-kŏ-pĭk gǎs-TRŎS-tō-mē) (PEG): A medical procedure in which a tube is passed into a

patient's stomach through the abdominal wall, most commonly to provide a means of feeding when oral intake is not adequate. ([Chapter 12.5](#))

Peristalsis (pěr-ĭ-STAL-sĭs): The involuntary constriction and relaxation of the muscles in the intestine or another canal, creating wave-like movements that push the contents forward. ([Chapter 12.4](#), [Chapter 12.5](#))

Peritoneum (pěr-ĭ-tō-NĒ-ŭm): A serous membrane lining the cavity of the abdomen and covering the abdominal organs. ([Chapter 12.4](#))

Peritonitis (pěr-ĭt-ŏ-NĪT-ĭs): Inflammation of the peritoneum, the tissue that lines the inner wall of the abdomen and covers and supports most of your abdominal organs. ([Chapter 12.4](#), [Chapter 12.6](#))

Pharynx (FAR-ĭnks): The muscular tube extending from the back of the nasal cavities and the mouth to the esophagus, known as the throat. ([Chapter 12.4](#))

Polypectomy (pŏl-ĭ-PĚK-tŏ-mĕ): Surgical removal of polyps from the colon or rectum. ([Chapter 12.6](#))

Probiotics (prŏ-bĭ-OT-ĭks): Live bacteria and yeasts that are good for your health, especially your digestive system. ([Chapter 12.5](#))

Proctocolectomy (prŏk-tŏ-kŏ-LEK-tŏ-mĕ): Surgical removal of the rectum and all or part of the colon. ([Chapter 12.6](#))

Proctologist (prŏk-TOL-ŏ-jĭst): A physician who specializes in diagnosing and treating disorders of the rectum and anus. ([Chapter 12.7](#))

Proctoscope (PRŎK-tă-skŏp): An instrument for examining the rectum. ([Chapter 12.4](#))

Pyloric sphincter (pĭ-LOR-ĭk SFINGK-tĕr): A ring of smooth muscle at the end of the stomach, regulating the flow of partially digested food into the small intestine. ([Chapter 12.4](#))

Radiofrequency ablation (RĀ-dē-ŏ-FRĒ-kwĕn-sē ă-blā-shŭn): A medical procedure in which part of the electrical conduction system of a tumor or other dysfunctional tissue is ablated using the heat generated from high-frequency alternating current. ([Chapter 12.6](#))

Rectum (REK-tŭm): The final section of the large intestine, terminating at the anus. ([Chapter 12.4](#))

Reflux (RĒ-flŭks): The backward flow of stomach contents into the esophagus or throat, causing heartburn or acid indigestion. ([Chapter 12.5](#))

Salivary (SĀL-ī-vār-ē): Related to or producing saliva. ([Chapter 12.4](#))

Sigmoid colon (SIG-moyd KŌ-lŏn): The S-shaped last part of the colon, leading into the rectum. ([Chapter 12.4](#))

Sigmoidoscopy (sig-moy-DOS-kŏ-pē): A medical examination of the sigmoid colon by means of a sigmoidoscope. ([Chapter 12.7](#))

Small bowel resection (SMOL BOW-ěl rĭ-SĚK-shŭn): Surgical removal of part of the small intestine. ([Chapter 12.6](#))

Small intestine (SMOL IN-tēs-tĭn): The part of the intestine where most of the digestion and absorption of food occurs, extending between the stomach and large intestine. ([Chapter 12.4](#))

Soft palate (SOFT PAL-āt): The fleshy, flexible part towards the back of the roof of the mouth. ([Chapter 12.4](#))

Steatorrhea (stē-ăt-ŏ-RĒ-ă): The excretion of abnormal quantities of fat with the feces. ([Chapter 12.4](#))

Stoma (STŌ-mă): An artificial opening made into a hollow organ, especially one on the surface of the body leading to the gut or trachea. ([Chapter 12.6](#))

Stomach (STUM-ăk): A sac-like organ of the digestive system that mixes food with gastric juices to begin the digestion of proteins. ([Chapter 12.4](#))

Stomatitis (stō-mă-TĪT-ĭs): Inflammation of the mouth and lips. ([Chapter 12.4](#))

Stool culture (stōŏl KUL-chŭr): A test to detect and identify bacteria that cause infections of the lower digestive tract. ([Chapter 12.7](#))

Stool DNA test (stool dē-ĕn-ā tĕst): A test that checks stool samples for certain DNA markers that cells from colorectal cancer or polyps shed into the stool. ([Chapter 12.7](#))

Sublingual (sŭb-LING-gwăł): Underneath the tongue. ([Chapter 12.4](#))

Tongue (TUNG): A muscular organ in the mouth, aiding in tasting, swallowing, and speaking. ([Chapter 12.4](#))

Transverse colon (trans-VURS KŌ-lŏn): The middle part of the colon which travels across the abdomen. ([Chapter 12.4](#))

Ulcerative colitis (UL-sĕr-ă-tiv kŏ-LĪ-tĭs): A chronic, inflammatory bowel disease that causes inflammation in the digestive tract, specifically in the lining of the large intestine (colon) and rectum. ([Chapter 12.6](#))

Upper gastrointestinal series (ŪP-ĕr GAS-trŏ-in-TĒS-tĭ-năł SĪR-ĕz): A series

of X-rays of the patient's esophagus, stomach, and small intestine. ([Chapter 12.7](#))

Upper GI endoscopy (ŮP-ěr Jī ěn-DŮS-kŏ-pē en-DOS-kŏ-pē): A procedure in which a thin scope with a light and camera at its tip is used to look inside the upper digestive tract — the esophagus, stomach, and the first part of the small intestine, called the duodenum. ([Chapter 12.7](#))

Urea breath test (yoo-RĒ-ă brĕth tĕst): A diagnostic test for *Helicobacter pylori* using a special form of urea. ([Chapter 12.6](#))

Uvula (YŮ-vyŭ-lă): A fleshy extension at the back of the soft palate that hangs above the throat. ([Chapter 12.4](#))

Uvulitis (ŭ-vyŭ-LĪT-ĭs): Inflammation of the uvula. ([Chapter 12.4](#))

Villi (VĪL-ĭ): Small, finger-like projections that protrude from the epithelial lining of the intestinal wall, increasing the surface area for absorption. ([Chapter 12.4](#))

Visceral (VĪS-ěr-ăl): Relating to the internal organs of the body, especially those in the abdomen. ([Chapter 12.5](#))

Vomiting (VOM-ĭ-ting): Ejecting matter from the stomach through the mouth. ([Chapter 12.5](#))

Xerostomia (zēr-ŏ-STŌ-mē-ă): Dry mouth, often due to a decrease in saliva production. ([Chapter 12.4](#))

PART XIII

CHAPTER 13 SKELETAL SYSTEM TERMINOLOGY

13.1 Introduction to the Skeletal System

Learning Objectives

- Apply the rules of medical language to build, analyze, spell, pronounce, abbreviate, and define terms as they relate to the skeletal system
- Identify meanings of key word components of the skeletal system
- Categorize diagnostic, therapeutic, procedural, or anatomic terms related to the skeletal system
- Use terms related to the skeletal system
- Use terms related to the diseases and disorders of the skeletal system

The skeletal system is composed of bones, cartilage, and ligaments. It performs several functions, including supporting the body, protecting internal organs, producing blood cells, and storing/releasing minerals.¹

This chapter will review common word components related to the skeletal

¹ This work is a derivative of Anatomy & Physiology by [OpenStax](https://openstax.org/details/books/anatomy-and-physiology-2e) and is licensed under [CC BY 4.0](https://creativecommons.org/licenses/by/4.0/). Access for free at <https://openstax.org/details/books/anatomy-and-physiology-2e>

system to assist learners in analyzing, building, and defining medical terms. Other terms, whose definitions cannot be easily built from word components, will be described in context based on the anatomy and physiology of the skeletal system and common diseases and disorders. Medical specialists, diagnostic tests, and procedures related to the skeletal system will also be discussed.

View a supplementary YouTube video² on the skeletal system: [The Skeletal System: Crash Course Anatomy & Physiology #19](https://www.youtube.com/watch?v=rDGqkMHPDqE)

2. CrashCourse. (2015, May 18). *The skeletal system: Crash Course Anatomy & Physiology #19* [Video]. YouTube. All rights reserved. <https://www.youtube.com/watch?v=rDGqkMHPDqE>

13.2 Word Components Related to the Skeletal System

This section will describe common word components related to the skeletal system. These word components help build definitions for many medical terms. Other common prefixes are described in [Chapter 1.3](#), and common suffixes are described in [Chapter 1.5](#).

PREFIXES RELATED TO THE SKELETAL SYSTEM

- **a-**: Absence of, without
- **ab-**: Away from
- **ad-**: Towards
- **brady-**: Slow
- **dys-**: Painful, difficult, abnormal, labored
- **hyper-**: Above, excessive
- **inter-**: Between
- **intra-**: Within, in
- **poly-**: Many, much
- **sub-**: Below, under
- **supra-**: Above
- **sym-**: Together, joined
- **syn-**: Together, joined

WORD ROOTS WITH A COMBINING VOWEL RELATED TO THE SKELETAL SYSTEM

- **ankyl/o**: Stiff, bent
- **aponeur/o**: Aponeurosis
- **arthr/o**: Joint
- **burs/o**: Bursa
- **carp/o**: Carpals, wrist
- **chondr/o**: Cartilage
- **clavic/o**: Clavicle, collarbone
- **clavicul/o**: Clavicle, collarbone
- **cost/o**: Ribs
- **crani/o**: Cranium
- **disk/o**: Intervertebral disk
- **femor/o**: Femur, upper leg bone
- **fibul/o**: Fibula, lower leg bone
- **humer/o**: Humerus, upper arm bone
- **ili/o**: Ilium
- **ischi/o**: Ischium
- **kines/o**: Movement, motion
- **kyph/o**: Increased convexity of the spine
- **lord/o**: Bent forward, increased concavity of the spine
- **lumb/o**: Loin, lumbar region of the spine
- **mandibul/o**: Mandible, lower jawbone
- **maxill/o**: Maxilla, upper jawbone
- **menisc/o**: Meniscus, crescent
- **myel/o**: Bone marrow, spinal cord
- **oste/o**: Bone
- **patell/o**: Patella, kneecap
- **pelv/i**: Pelvis, pelvic bone
- **petr/o**: Stone

- **phalang/o**: Bones of the finger and toes
- **pub/o**: Pubis
- **rachi/o**: Vertebral spine, vertebral column
- **radi/o**: Radius
- **sacr/o**: Sacrum
- **scapul/o**: Scapula, shoulder blade
- **scoli/o**: Crooked, curved
- **spondyl/o**: Vertebra, spine, vertebral column
- **stern/o**: Sternum, breastbone
- **synovi/o**: Synovia
- **tars/o**: Tarsals, ankle bones
- **ten/o**: Tendon
- **tend/o**: Tendon
- **tendin/o**: Tendon
- **tibi/o**: Tibia, lower leg bone
- **uln/o**: Ulna, lower arm bone
- **vertebr/o**: Vertebra, spine, vertebral column

SUFFIXES RELATED TO THE SKELETAL SYSTEM

- **-ad**: Towards
- **-al**: Pertaining to
- **-algia**: Pain
- **-ar**: Pertaining to
- **-asthenia**: Weakness
- **-blast**: Formative cell
- **-centesis**: Surgical puncture to aspirate fluid
- **-clasia**: Break
- **-clasis**: Break
- **-clast**: Break

- **-desis:** Surgical fixation, fusion
- **-ectomy:** Excision, surgical removal, cutting out
- **-gram:** The record, radiographic image
- **-graphy:** Process of recording, radiographic imaging
- **-ic:** Pertaining to
- **-itis:** Inflammation
- **-lysis:** Loosening, separating, dissolution
- **-malacia:** Softening
- **-oid:** Resembling
- **-oma:** Tumor
- **-osis:** Abnormal condition
- **-penia:** Abnormal reduction
- **-physis:** Growth
- **-plasty:** Surgical repair
- **-rrhaphy:** Suturing, repairing
- **-sarcoma:** Malignant tumor
- **-schisis:** Split, fissure
- **-scopy:** Process of viewing, visual examination
- **-tomy:** Incision, cut into
- **-trophy:** Nourishment, development

13.3 Examples of Skeletal Terms Easily Defined By Their Word Components

Here are examples of common medical terms related to the skeletal system that can be easily defined by breaking the terms into their word components.

Arthrocentesis

1. Break down the medical term into word components:
Arthr/o/centesis
2. Label the word components: **Arthr** = WR; **o** = CV; **centesis** = S
3. Define the word components: **Arthr** = joint; **centesis** = surgical puncture to aspirate fluid
4. Create a final definition of the medical term: **A surgical puncture to aspirate fluid from a joint**

Osteomyelitis

1. Break down the medical term into word components:
Oste/o/myel/itis
2. Label the word components: **Oste** = WR; **o** = CV; **myel** = WR; **itis** = S

3. Define the word components: **Oste** = bone; **myel** = bone marrow; **itis** = inflammation
4. Create a final definition of the medical term:
Inflammation of bone and bone marrow

Vertebroplasty

1. Break down the medical term into word components:
Vertebr/o/plasty
2. Label the word components: **Vertebr** = WR; **o** = CV; **plasty** = S
3. Define the word components: **Vertebr** = vertebral column; **plasty** = surgical repair
4. Create a final definition of the medical term: **Surgical repair of the vertebral column**



Interactive Learning Activity: Practice defining and pronouncing skeletal system medical terms by breaking them down into word parts.



An interactive H5P element has been excluded from this version of the text. You can view it online here:
<https://wtcs.pressbooks.pub/medterm/?p=4810#h5p-84>

▶ You can also print these flashcard activities as a [Chapter 13](#)

▶ [Student Companion Worksheet](#) and check your answers with this [Answer Key](#).

13.4 Anatomy of the Skeletal System

The skeleton system supports the body, facilitates movement with muscles, protects soft body parts, produces blood cells, and stores and releases calcium.¹ Muscles, movement and muscular disorders are discussed in the “[Muscular System Terminology](#)” chapter.

The skeletal system includes bones, joints, cartilages, and ligaments that support and give shape to the body. See Figure 13.1² for an illustration of the skeletal system. The skeletal system is subdivided into two major divisions called the axial skeleton and the appendicular skeleton. Each division is discussed in the following sections, along with related medical terms.

1. National Cancer Institute. (n.d.). *Introduction to the skeletal system*. National Institutes of Health. <https://training.seer.cancer.gov/anatomy/skeletal>
2. “[701_Axial_Skeleton-01.jpg](#)” by OpenStax College is licensed under [CC BY 3.0](#)

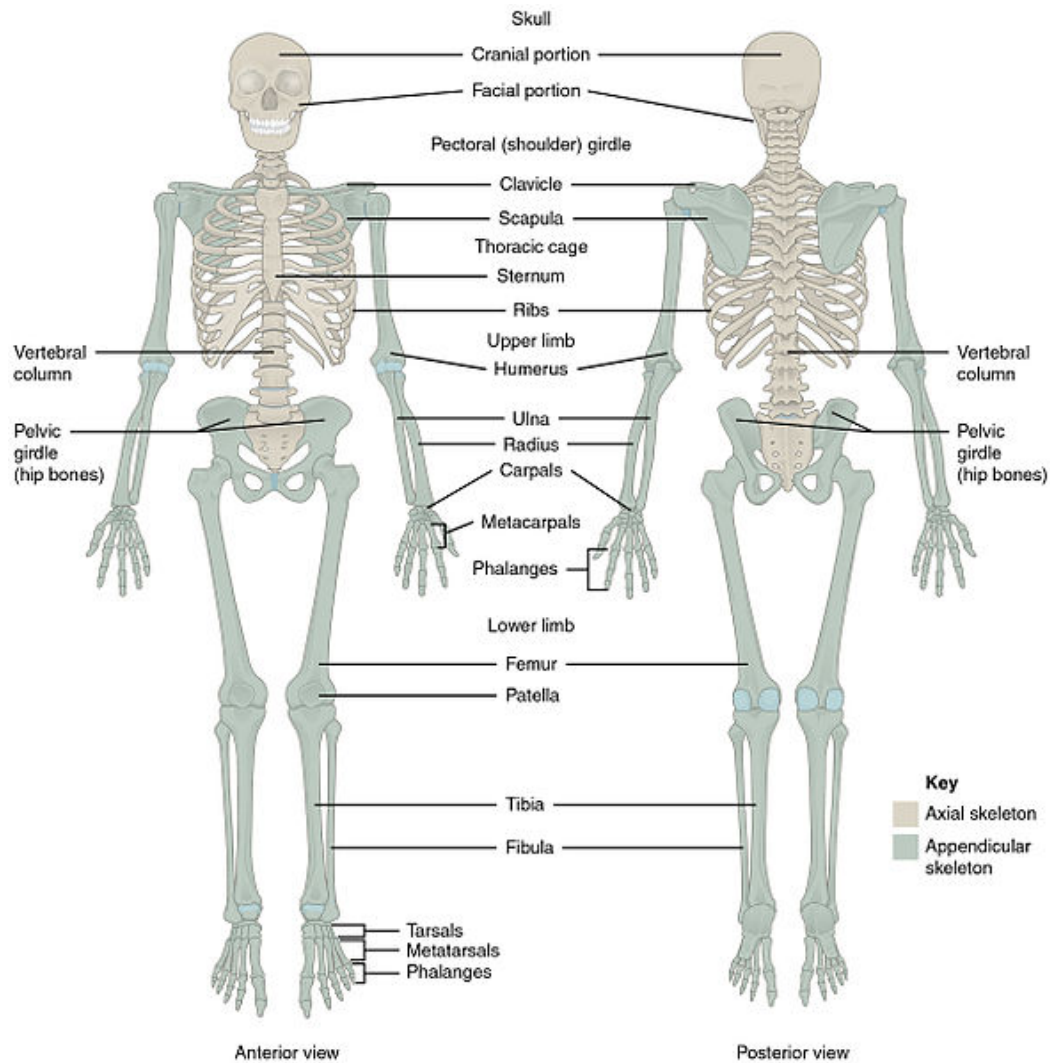


Figure 13.1 Axial and Appendicular Skeletal Systems

THE AXIAL SKELETON

The axial skeleton forms the central axis of the body and includes the bones of the head, neck, chest, and back. It serves to protect the brain, spinal cord, heart, and lungs. It also serves as the attachment site for muscles that move

the head, neck, back, shoulder, and hip joints. The axial skeleton includes the cranium, hyoid, vertebral column, and thoracic cage.³

Cranium

The **cranium** (KRĀ-nē-ŭm) is subdivided into the skull and the facial bones. It supports the face and protects the brain.⁴ See Figure 13.2⁵ for an illustration of the anterior bones of the skull and the face. A **craniotomy** (krā-nē-ŌT-ō-mē) refers to a surgical opening into the skull. A **cranioplasty** (KRĀ-nē-ō-plās-tē) refers to surgical repair of the cranium.

3. This work is a derivative of Anatomy & Physiology by [OpenStax](#) and is licensed under [CC BY 4.0](#). Access for free at <https://openstax.org/details/books/anatomy-and-physiology-2e>
4. This work is a derivative of [Anatomy and Physiology](#) by [OpenStax](#) licensed under [CC BY 4.0](#). Access for free at <https://openstax.org/books/anatomy-and-physiology/pages/1-introduction>
5. “704_Skull-01.jpg” by OpenStax College is licensed under [CC BY 3.0](#)

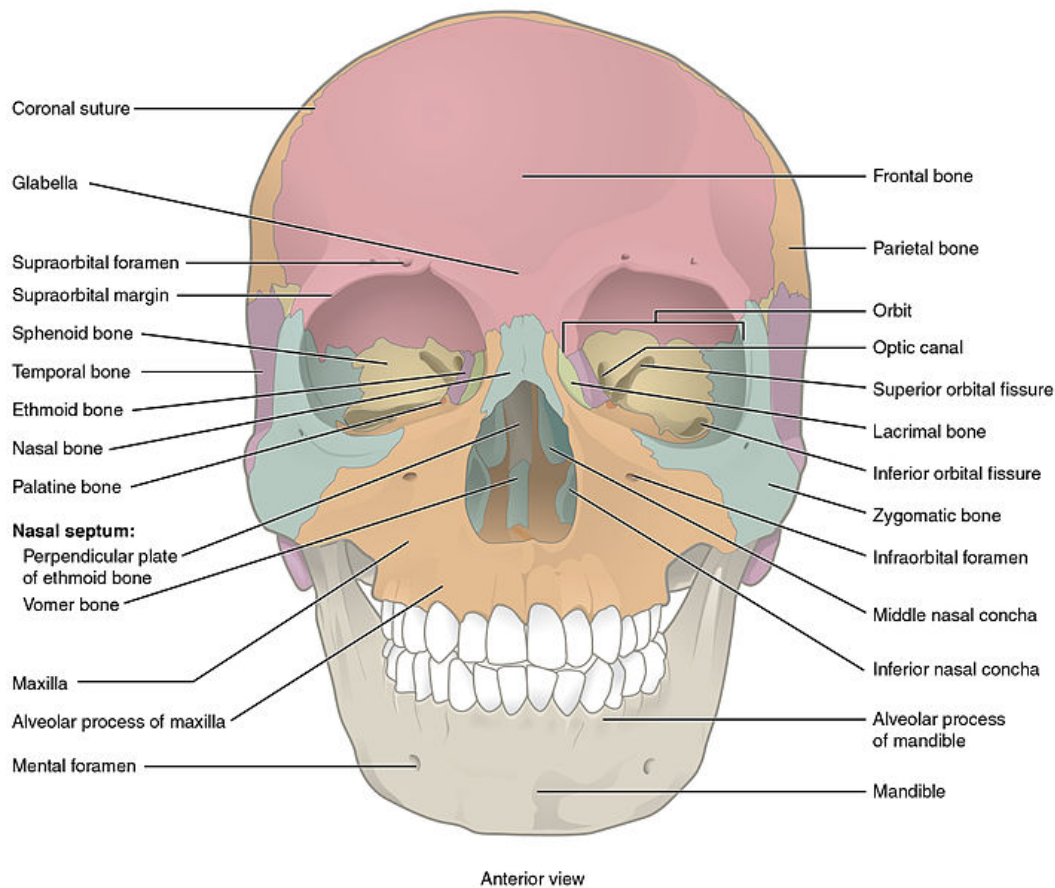


Figure 13.2 Bones of the Anterior Skull and Face

The major bones of the skull include the following⁶:

- **Frontal** (FRŮN-tăł): Forehead
- **Parietal** (pă-rĭ-ĖT-ăł): Upper lateral sides of the skull
- **Temporal** (TĖM-pō-răł): Lower lateral sides of the skull
- **Sphenoid** (SFĖ-noid): Posterior eye sockets and part of the base of the skull
- **Ethmoid** (ĖTH-moid): Part of the nose and base of the skull

6. This work is a derivative of [Anatomy and Physiology](https://openstax.org/books/anatomy-and-physiology/pages/1-introduction) by [OpenStax](https://openstax.org/books/anatomy-and-physiology/pages/1-introduction) licensed under [CC BY 4.0](https://creativecommons.org/licenses/by/4.0/). Access for free at <https://openstax.org/books/anatomy-and-physiology/pages/1-introduction>

- **Occipital** (ŏk-SĪP-ĭ-tăl): Posterior skull and base of the skull (See Figure 13.3⁷ for an image of the occipital bone.)

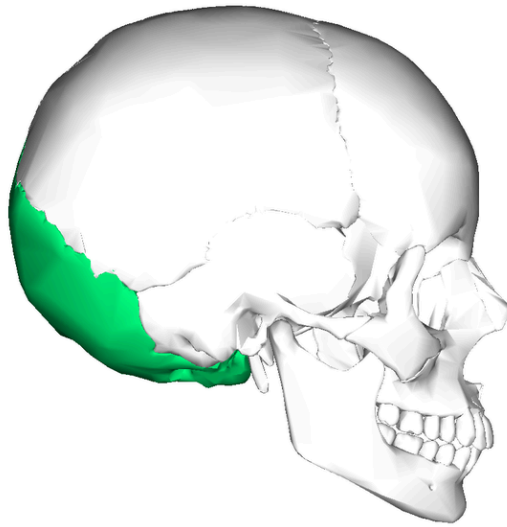


Figure 13.3 Occipital Bone

The facial bones form the upper and lower jaws, the nose, nasal cavity and nasal septum, and the orbit. The facial bones include 14 bones, with six paired bones and two unpaired bones. The paired bones are the maxillae, palatine, zygomatic, nasal, lacrimal, and inferior nasal conchae bones. The unpaired bones are the vomer and mandible bones⁸:

- **Zygomatic** (zī-gō-MĀT-ĭk): Pair of cheekbones
- **Maxillary** (MĀK-sĭ-lăr-ē): Upper jaw and hard palate

7. "[Occipital_bone_lateral.png](#)" by Anatomography is licensed under [CC BY-SA 2.1 Japan](#)

8. This work is a derivative of [Anatomy and Physiology](#) by [OpenStax](#) licensed under [CC BY 4.0](#). Access for free at <https://openstax.org/books/anatomy-and-physiology/pages/1-introduction>

- **Palatine** (PÄL-ă-tīn): Pair of L-shaped bones between the maxilla and sphenoid that form the hard palate, walls of the nasal cavity, and the orbital floor of the eye
- **Nasal** (NĀ-zăl): Pair of bones that form the bridge of the nose
- **Lacrima** (LĂK-rī-măl): Walls of the inner (medial) orbit (i.e., eye socket)
- **Inferior conchae** (ĪN-fēr-ē-ör KŌN-kē): Lower lateral walls of the nasal cavity
- **Vomer** (VŌ-mēr): Bone that separates the left and right nasal cavity
- **Mandible** (MĀN-dī-bŭl): Lower jawbone and only movable bone of the skull

The **temporomandibular joint** (tēm-pō-rō-MĀN-dī-bŭ-lăr) (**TMJ**) is a hinge joint between the temporal bone and the mandible that allows for the opening, closing, protrusion, retraction, and lateral movement of the lower jaw. Protrusion moves the mandible forward, and retraction pulls the mandible backward towards the neck.⁹

Hyoid

The **hyoid** (HĪ-oid) bone is an independent bone that does not contact any other bone and thus is not part of the skull. It is a small U-shaped bone located in the upper neck near the level of the inferior mandible, with the tips of the “U” pointing posteriorly. The hyoid serves as the base for the tongue above and is attached to the larynx and the pharynx below. Movements of the hyoid are coordinated with movements of the tongue, larynx, and pharynx

9. This work is a derivative of [Anatomy and Physiology](https://openstax.org/books/anatomy-and-physiology/pages/1-introduction) by OpenStax licensed under [CC BY 4.0](https://creativecommons.org/licenses/by/4.0/). Access for free at <https://openstax.org/books/anatomy-and-physiology/pages/1-introduction>

during swallowing and speaking.¹⁰ See Figure 13.4¹¹ for an illustration of the hyoid bone.

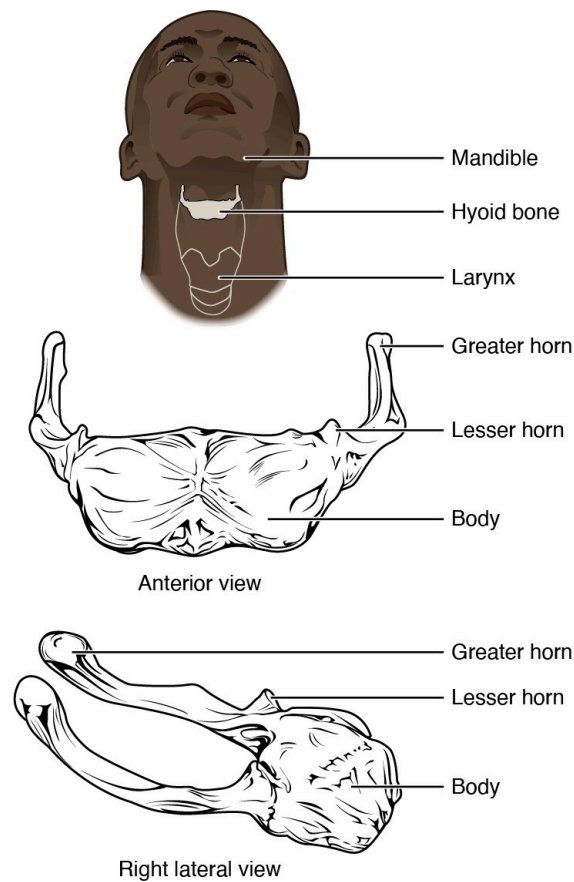


Figure 13.4 Hyoid

Vertebrae and Vertebral Column

The vertebral column consists of **vertebrae** (VŪR-tĭ-brā) that are separated by

¹⁰. This work is a derivative of *Anatomy and Physiology* by OpenStax licensed under CC BY 4.0. Access for free at <https://openstax.org/books/anatomy-and-physiology/pages/1-introduction>

¹¹. “Hyoid_bone_jpg” by Betts, et al. is licensed under CC BY 4.0. Access for free at <https://openstax.org/details/books/anatomy-and-physiology-2e>

intervertebral disks (ĭn-tĕr-VĔRT-ĕ-brĕl dĭskz). The spinal cord runs through the center of the vertebrae. See Figure 13.5¹² for an illustration of the parts of a vertebra. **Diskitis** (dĭs-KĪ-tĭs) refers to inflammation of an intervertebral disk. A **herniated disk** (hûr-nĕ-Ā-tĭd dĭsk) refers to a condition in which a disk protrudes beyond the normal confines of the vertebrae. **Spondylosis** (spŏn-dĭ-LŌ-sĭs) is a painful condition of the spine resulting from the degeneration of the intervertebral disks. A **discectomy** (dis-KEK-tŏ-mĕ) refers to excision of an intervertebral disk. A **laminectomy** (lăm-ĭ-NĚK-tŏ-mĕ) refers to excision of all or part of the lamina to ease pressure on the spinal cord or the nerve roots that may be caused by injury, herniated disk, narrowing of the spinal canal, or tumors. The lamina is the area of the vertebra where spinous and transverse processes connect.¹³

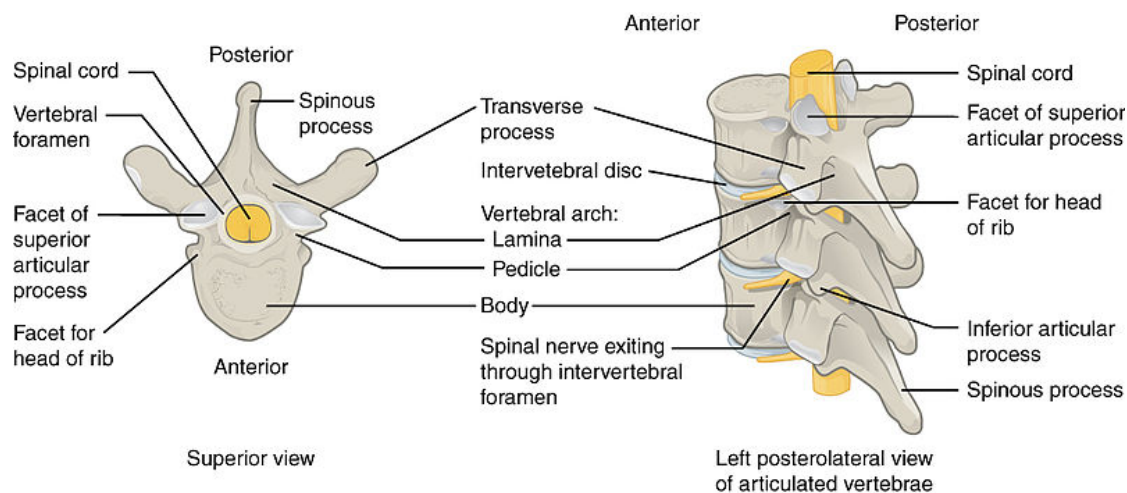


Figure 13.5 Vertebrae

Together, the vertebrae and intervertebral disks form the **vertebral column** (vŭr-TĒ-brăĭ KŌL-ŭm), also known as the spinal column. It is a flexible column

12. "718_Vertebra.jpg" by OpenStax College is licensed under [CC BY 3.0](#)

13. This work is a derivative of [Anatomy and Physiology](#) by [OpenStax](#) licensed under [CC BY 4.0](#). Access for free at <https://openstax.org/books/anatomy-and-physiology/pages/1-introduction>

that supports the head, neck, and body and allows for their movements. It also protects the spinal cord, which passes down the back through the vertebral foramen.¹⁴ View an illustration of the vertebral column in Figure 13.6.¹⁵

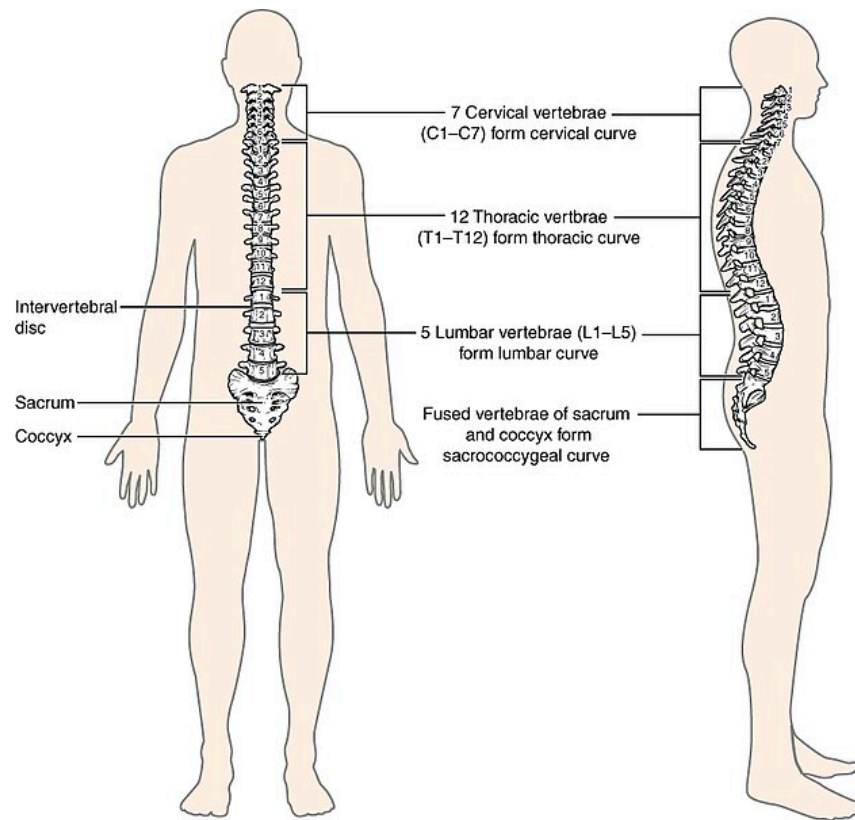


Figure 13.6 Vertebral Column

14. This work is a derivative of [Anatomy and Physiology](#) by [OpenStax](#) licensed under [CC BY 4.0](#). Access for free at <https://openstax.org/books/anatomy-and-physiology/pages/1-introduction>
15. “[715_Vertebral_Column.jpg](#)” by OpenStax College is licensed under [CC BY 3.0](#)

Vertebrae Regions

The vertebrae are divided into five regions called the cervical, thoracic, lumbar, sacrum, and coccyx¹⁶:

- **Cervical** (SŮR-vĩ-kăl): The first 7 vertebrae in the neck region, C1 to C7
- **Thoracic** (thō-RĀS-ĭk): The next 12 vertebrae that form the outward curvature of the spine, T1 to T12
- **Lumbar** (LŮM-bär): The next 5 vertebrae that form the inner curvature of spine, L1 to L5
- **Sacrum** (SĀ-krŭm): The triangular-shaped bone at the base of the spine, formed by the fusion of five sacral vertebrae, a process that does not begin until after the age of 20. See Figure 13.7¹⁷ for an illustration of the sacrum.
- **Coccyx** (KÖK-sĭks): The tailbone, formed by the fusion of four very small coccygeal vertebrae. See Figure 13.8¹⁸ for an illustration of the coccyx.

¹⁶. This work is a derivative of [Anatomy and Physiology](#) by [OpenStax](#) licensed under [CC BY 4.0](#). Access for free at <https://openstax.org/books/anatomy-and-physiology/pages/1-introduction>

¹⁷. “[Sacrum - anterior view02.png](#)” by BodyParts3D is made by DBCLS is licensed under [CC BY-SA 2.1 Japan](#)

¹⁸. “[Coccyx - anterior view01.png](#)” by BodyParts3D is made by DBCLS is licensed under [CC BY-SA 2.1 Japan](#)

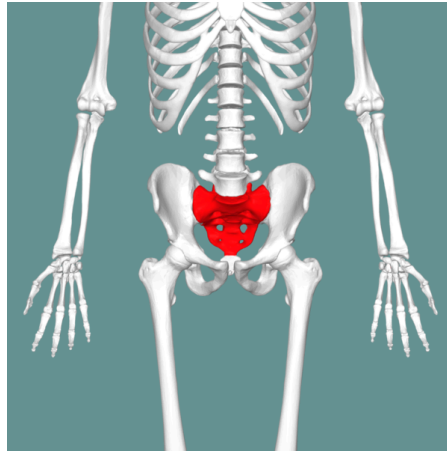


Figure 13.7 Sacrum

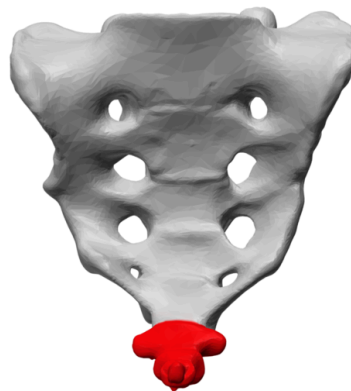


Figure 13.8 Coccyx

Vertebral Curvature

The vertebral column is normally curved, with two primary curvatures

(thoracic and sacrococcygeal curves) and two secondary curvatures (cervical and lumbar curves).¹⁹

Thoracic Cage

The thoracic cage, commonly known as the rib cage, forms the chest (thorax). It consists of the sternum and 12 pairs of ribs, along with their costal cartilages. The ribs are anchored posteriorly to the 12 thoracic vertebrae (T1–T12). See Figure 13.9²⁰ for an illustration of the thoracic cage. The thoracic cage protects the heart and lungs.²¹

19. This work is a derivative of [Anatomy and Physiology](#) by [OpenStax](#) licensed under [CC BY 4.0](#). Access for free at <https://openstax.org/books/anatomy-and-physiology/pages/1-introduction>
20. [“721_Rib_Cage.jpg”](#) by OpenStax College is licensed under [CC BY 3.0](#)
21. This work is a derivative of [Anatomy and Physiology](#) by [OpenStax](#) licensed under [CC BY 4.0](#). Access for free at <https://openstax.org/books/anatomy-and-physiology/pages/1-introduction>

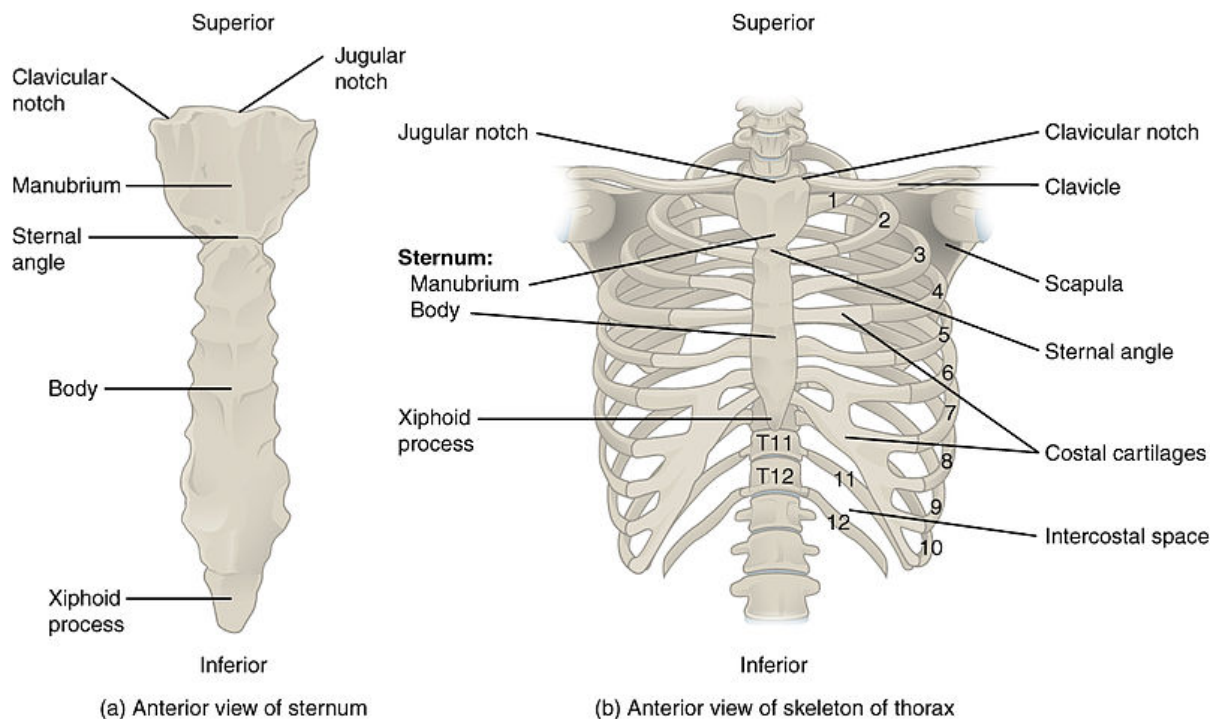


Figure 13.9 Thoracic Cage (a) sternum and (b) 12 pairs of ribs

The **sternum** (STŪR-nŭm), also known as the breastbone, is divided into three parts²²:

- **Manubrium** (mă-NŪ-brē-ŭm): The upper portion of the sternum
- **Body** (bŏd-ē): The middle portion of the sternum
- **Xiphoid process** (ZĪ-foïd PRŌ-sēs): The lower portion of the sternum made of cartilage

The 12 sets of ribs can be classified as true ribs, false ribs, and floating ribs²³:

22. This work is a derivative of [Anatomy and Physiology](#) by [OpenStax](#) licensed under [CC BY 4.0](#). Access for free at <https://openstax.org/books/anatomy-and-physiology/pages/1-introduction>

23. This work is a derivative of [Anatomy and Physiology](#) by [OpenStax](#) licensed

- **True ribs** (TRŌŌ řibz): Ribs 1-7 that are attached to the front of the sternum
- **False ribs** (FŌLS řibz): Ribs 8, 9, and 10 that are attached to the cartilage that joins the sternum
- **Floating ribs** (FLŌ-ă-třing řibz): Ribs 11 and 12 that are not attached to the front of the sternum

Intercostal (int-ěr-KOS-tăl) means between the ribs. In clinical practice, **intercostal retractions** (řin-těr-KŌS-tăl rē-trăk-SHŏnz) may be observed in individuals experiencing labored breathing, where the muscles pull in between the ribs.

THE APPENDICULAR SKELETON

The appendicular skeleton includes the upper and lower limbs, plus the bones that attach each limb to the axial skeleton.²⁴

Upper Limbs

The bones of the upper limbs include the bones of the arms, wrists, and hands. The shoulder attaches the upper limbs to the axial skeleton. See Figure

under [CC BY 4.0](https://openstax.org/books/anatomy-and-physiology/pages/1-introduction). Access for free at <https://openstax.org/books/anatomy-and-physiology/pages/1-introduction>

24. This work is a derivative of Anatomy & Physiology by [OpenStax](https://openstax.org/details/books/anatomy-and-physiology-2e) and is licensed under [CC BY 4.0](https://openstax.org/details/books/anatomy-and-physiology-2e). Access for free at <https://openstax.org/details/books/anatomy-and-physiology-2e>

13.10²⁵ for an illustration of the upper limbs and pectoral girdle, the bony support of the shoulder consisting of the clavicle and scapula.²⁶

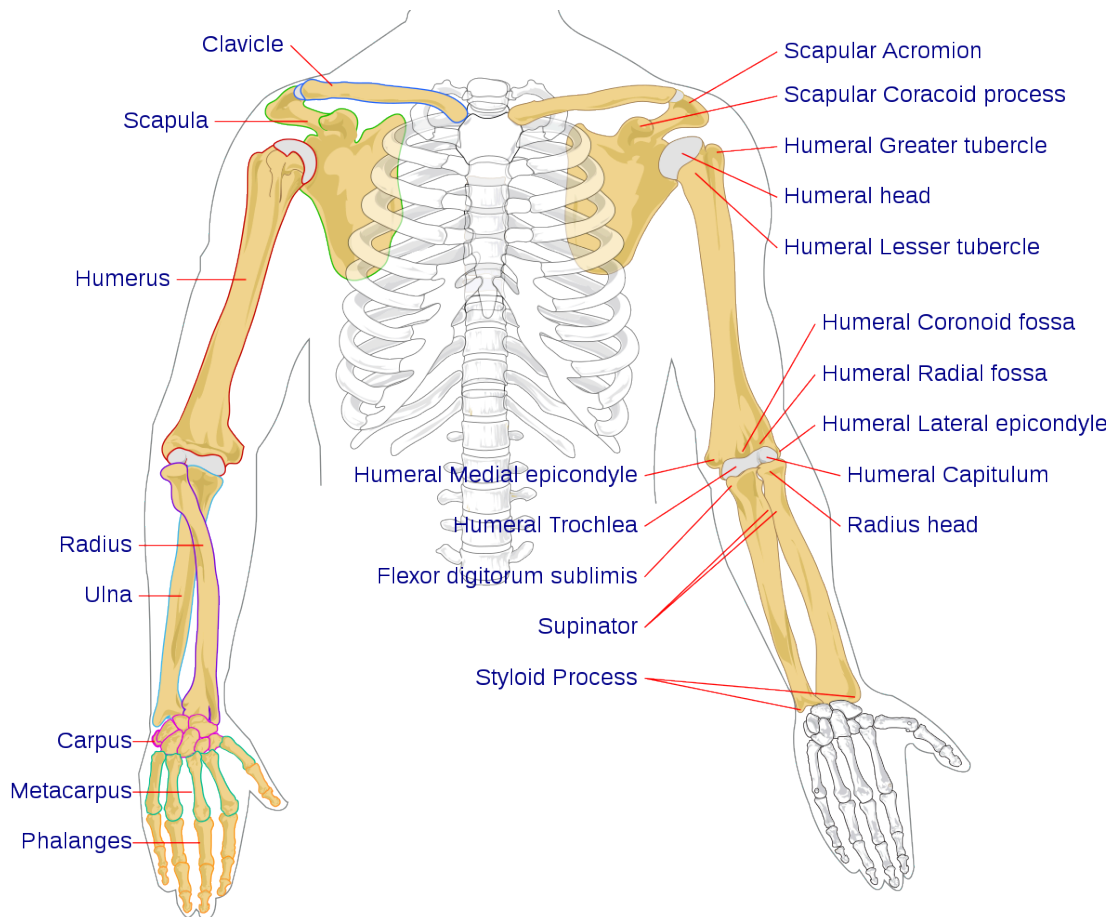


Figure 13.10 Upper Limbs and Shoulder

25. “[Human_arm_bones_diagram.svg](#)” by [LadyofHats](#) Mariana Ruiz Villarreal is licensed in the [Public Domain](#).

26. This work is a derivative of [Anatomy and Physiology](#) by [OpenStax](#) licensed under [CC BY 4.0](#). Access for free at <https://openstax.org/books/anatomy-and-physiology/pages/1-introduction>

Arms

There are three bones in each arm²⁷:

- **Humerus** (HYŌŌ-mēr-ŭs): Upper arm
- **Radius** (RĀ-dē-ŭs): The thumb side of the forearm
- **Ulna** (ŬL-nă): The fifth finger side of the forearm



View a YouTube video²⁸ from UCDenver Anatomy Lab:
[Radius & Ulna](#)

Wrists, Hands, and Fingers

See Figure 13.11²⁹ for an illustration of the bones of the wrist, hand, and fingers. The bones of the hand and wrist include the carpals, metacarpals, and phalanges³⁰:

27. This work is a derivative of [Anatomy and Physiology](#) by [OpenStax](#) licensed under [CC BY 4.0](#). Access for free at <https://openstax.org/books/anatomy-and-physiology/pages/1-introduction>
28. UCDenver Anatomy Lab 3244. (2013, August 31). *Radius & Ulna*. [Video]. YouTube. All rights reserved. <https://www.youtube.com/watch?v=ThmvWFvHOMl>
29. "[806_Hand_and_Wrist.jpg](#)" by OpenStax College is licensed under [CC BY 3.0](#)
30. This work is a derivative of [Anatomy and Physiology](#) by [OpenStax](#) licensed under [CC BY 4.0](#). Access for free at <https://openstax.org/books/anatomy-and-physiology/pages/1-introduction>

- **Carpals** (KÄR-pälz): Wrist bones
- **Metacarpals** (mět-ă-KÄR-pälz): Bones of the palm of hand
- **Phalanges** (fă-LÄN-jēz): Fingers (and toes)

A single finger is called a **phalanx** (FÄ-längks) and is composed of three bones called the distal phalanx, medial phalanx, and proximal phalanx. The exception is the thumb, which only has two bones, the distal and proximal.³¹

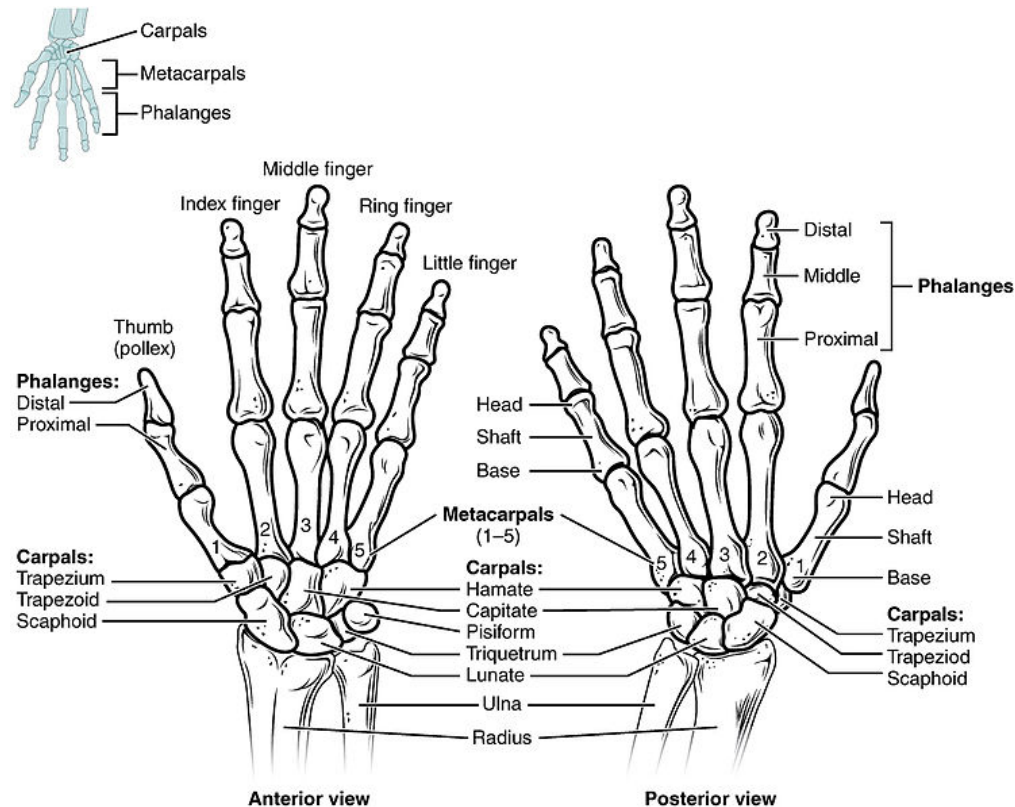


Figure 13.11 Hands, Wrist, and Fingers

31. This work is a derivative of [Anatomy and Physiology](#) by [OpenStax](#) licensed under [CC BY 4.0](#). Access for free at <https://openstax.org/books/anatomy-and-physiology/pages/1-introduction>

The Shoulder

Refer back to Figure 13.10 to view the bones of the shoulder that connect the arms to the axial skeleton to form the pectoral girdle and include the clavicle, scapula, and acromion³²:

- **Clavicle** (KLÄV-ĭ-kŭl): Connect the sternum to the scapula, also known as the collarbone
- **Scapula** (SKÄP-yŭ-lă): Shoulder blade
- **Acromion** (ă-KRŌ-mē-ŏn): An extension from the scapula that forms the bony tip of the shoulder

Together, the clavicle, acromion, and spine of the scapula form a V-shaped bony line that provides for the attachment of neck and back muscles that act on the shoulder, as well as muscles that pass across the shoulder joint to act on the arm.³³

Lower Limbs

The bones of the lower limb include bones of the leg and the feet. The hip attaches the lower limbs to the axial skeleton.

32. This work is a derivative of [Anatomy and Physiology](#) by [OpenStax](#) licensed under [CC BY 4.0](#). Access for free at <https://openstax.org/books/anatomy-and-physiology/pages/1-introduction>

33. This work is a derivative of [Anatomy and Physiology](#) by [OpenStax](#) licensed under [CC BY 4.0](#). Access for free at <https://openstax.org/books/anatomy-and-physiology/pages/1-introduction>

Leg

See Figure 13.12³⁴ for an illustration of the leg bones, including the femur, patella, tibia, and fibula³⁵:

- **Femur** (FĒ-mŭr): Thigh bone, the longest and strongest bone in the human body
- **Patella** (pă-TĚL-ă): Kneecap
- **Tibia** (TĬB-ē-ă): The medial bone and main weight-bearing bone of the lower leg, commonly called the shin. The distal end of the tibia forms the **medial malleolus** (MĒ -dē-ăl MĂL-ē-ŏ-lŭs), which forms the bony protrusion on the medial side of the ankle.
- **Fibula** (FĬB-yŭ-lă): The smaller, lateral bone of the lower leg. The distal end of the fibula forms the **lateral malleolus** (LĂT-ěr-ăl MĂL-ē-ŏ-lŭs), which forms the bony protrusion on the lateral side of the ankle.

34. “[Human_leg_bones_labeled.svg](#)” is a derivative work by [Jecowa](#) at [English Wikipedia](#) and is licensed in the [Public Domain](#).

35. This work is a derivative of [Anatomy and Physiology](#) by [OpenStax](#) licensed under [CC BY 4.0](#). Access for free at <https://openstax.org/books/anatomy-and-physiology/pages/1-introduction>

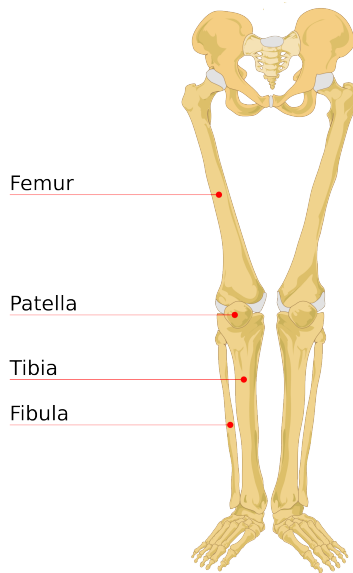


Figure 13.12 Leg Bones

Feet

See Figure 13.13³⁶ for an illustration of the bones of the ankles and feet. There are several foot bones, but the major bones include the tarsals, metatarsals, phalanges, and calcaneus³⁷:

- **Tarsals** (TÄR-sälz): Bones of the posterior half of the foot
- **Metatarsals** (mět-ă-TÄR-sälz): Bones of the anterior half of the foot
- **Phalanges** (fă-LÄN-jēz): Toes (and fingers). The **hallux** (HÄL-lüks) is the great toe.
- **Calcaneus** (käl-KÄ-nē-ūs): Heel bone

³⁶. "812_Bones_of_the_Foot.jpg" by OpenStax College is licensed under [CC BY 3.0](#)

³⁷. This work is a derivative of [Anatomy and Physiology](#) by [OpenStax](#) licensed under [CC BY 4.0](#). Access for free at <https://openstax.org/books/anatomy-and-physiology/pages/1-introduction>

Like the fingers, the toes are composed of three bones called the distal phalanx, medial phalanx, and proximal phalanx, with the exception of the great toe, which only has two bones, the distal and proximal.³⁸

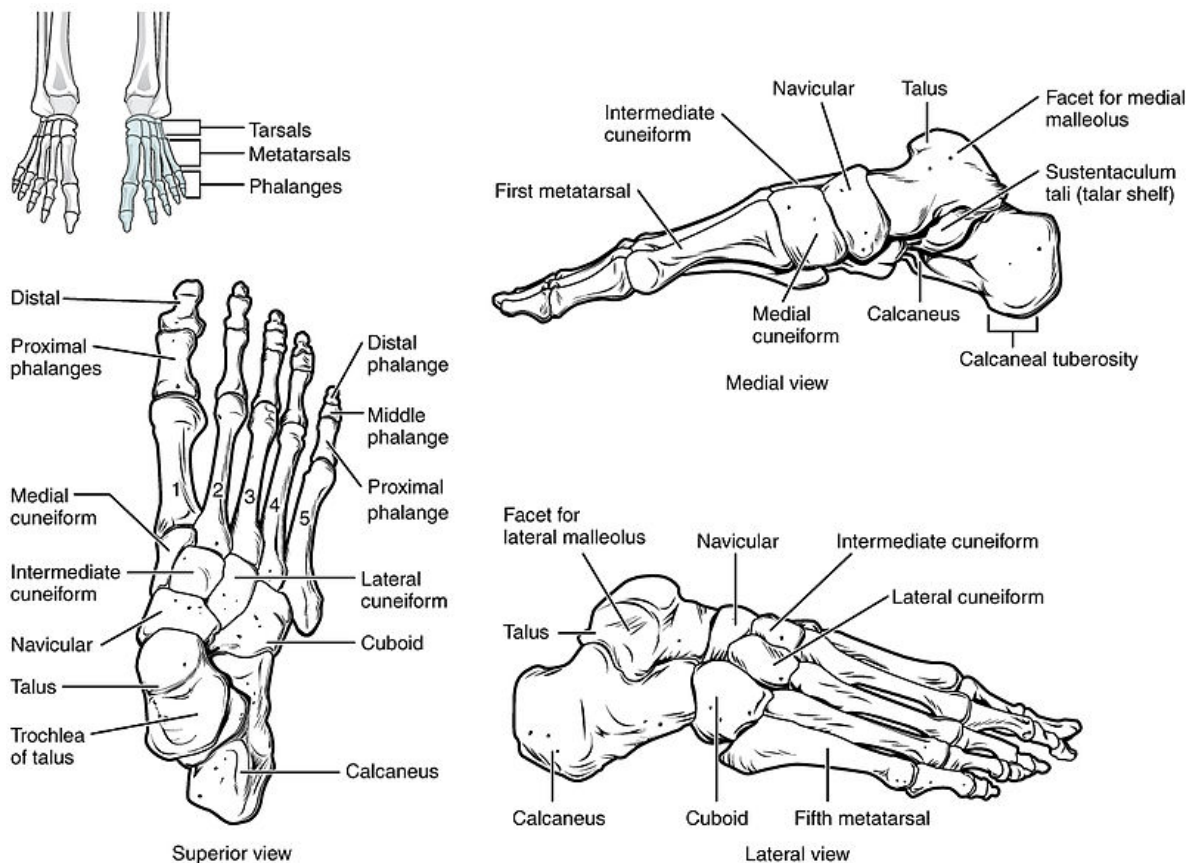


Figure 13.13 Bones of the Feet

The Hip

The hip serves as the attachment point for each lower limb at the **acetabulum** (ă-s-ě-TĂB-yŭ-lŭm), the large socket that holds the head of the femur. Each adult hip bone is formed by three separate pelvic bones, called

38. This work is a derivative of [Anatomy and Physiology](#) by [OpenStax](#) licensed under [CC BY 4.0](#). Access for free at <https://openstax.org/books/anatomy-and-physiology/pages/1-introduction>

the ilium, ischium, and pubis, that fuse together during the late teenage years.³⁹ See Figure 13.14⁴⁰ for an image of the hip and pelvis.

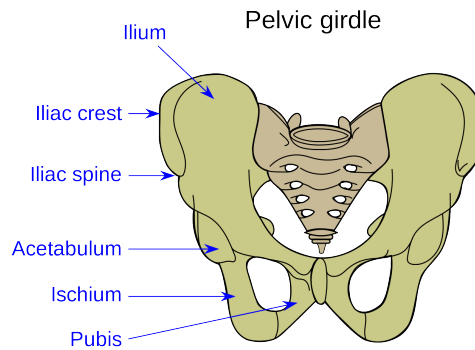


Figure 13.14 Hip and Pelvis

The **ilium** (ĪL-ē-ŭm) is the superior region that forms the largest part of the hip bone. It is attached to the sacrum at the sacroiliac joint. The **ischium** (ĪS-kē-ŭm) forms the posteroinferior region of each hip bone and supports the body when sitting. The **pubis** (PYŪ-bīs) forms the anterior portion of the hip bone. The pubis curves medially, where it joins to the pubis of the opposite hip bone at a specialized joint called the **pubic symphysis** (PYŪ-bīk SĪM-fī-sīs). The **pelvis** (PĔL-vīs) refers to the entire structure formed by the two hip bones,

39. This work is a derivative of *Anatomy and Physiology* by OpenStax licensed under CC BY 4.0. Access for free at <https://openstax.org/books/anatomy-and-physiology/pages/1-introduction>

40. “*Pelvic girdle illustration.svg*” by U.S. National Cancer Institute is licensed under CC BY-SA 4.0

the sacrum, and the coccyx.⁴¹ See Figure 13.15⁴² for an illustration of the parts of the pelvis.




Figure 13.15 Pelvis

The shape of the pelvis is different for males and females. In general, the bones of the male pelvis are thicker and heavier because they have adapted to support a male's typically heavier physical build. Because the female pelvis has adapted for childbirth, it is wider than the male pelvis. The shape and size of the pelvis can be used during forensic assessment to identify if skeletal

41. This work is a derivative of [Anatomy and Physiology](#) by [OpenStax](#) licensed under [CC BY 4.0](#). Access for free at <https://openstax.org/books/anatomy-and-physiology/pages/1-introduction>

42. "[807_Pelvis.jpg](#)" by OpenStax College is licensed under [CC BY 3.0](#)

remains are male or female.⁴³ See Figure 13.16⁴⁴ for a comparison of the female and male pelvis.

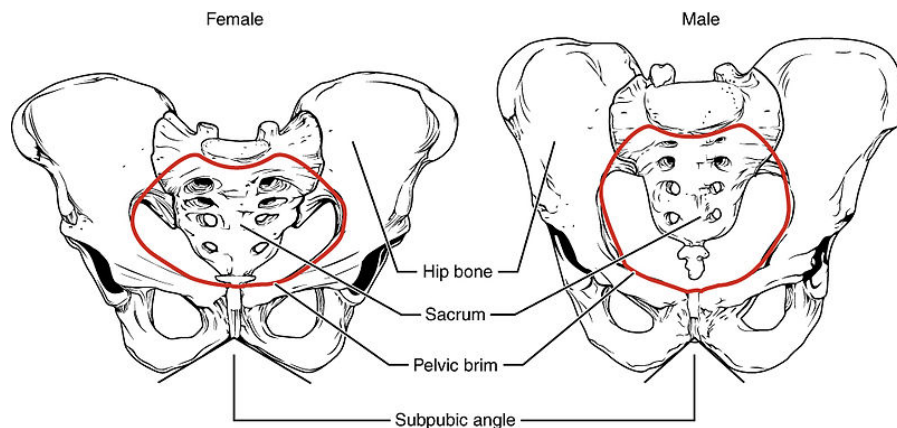


Figure 13.16 Comparison of Female and Male Pelvis

JOINTS

Joints (jōyntz), also called articulations, are places where two bones or bone and cartilage come together and form a connection. **Dislocation** (dīs-lō-KĀ-shŏn) refers to displacement of a bone from its normal position in a joint. Joints are categorized based on their form and amount of movement and are referred to as fibrous joints, cartilaginous joints, or synovial joints.⁴⁵

43. This work is a derivative of *Anatomy and Physiology* by OpenStax licensed under CC BY 4.0. Access for free at <https://openstax.org/books/anatomy-and-physiology/pages/1-introduction>

44. “809_Male_Female_Pelvic_Girdle.jpg” by OpenStax College is licensed under CC BY 3.0

45. This work is a derivative of *Anatomy and Physiology* by OpenStax licensed

Fibrous Joints, Ligaments, and Tendons

Fibrous joints (FĪ-brūs joints), also called synarthrosis or nonmoveable joints, occur when bones are attached by fibrous connective tissue. There are three types of fibrous joints: suture, gomphosis, and syndesmosis. A suture is the narrow fibrous joint found between most bones of the skull. A gomphosis is the narrow fibrous joint between the roots of a tooth and the bony socket in the jaw into which the tooth fits. A syndesmosis is a joint held together by a ligament, a type of connective tissue that connects bones.⁴⁶

Other fibrous connective tissues in the musculoskeletal system include ligaments and tendons. **Ligaments** (LĪG-ă-měnts) are narrow bands of fibrous connective tissue that connect a bone to a bone. A **tendon** (TĚN-dŏn) is a fibrous connective tissue that attaches muscle to bone.⁴⁷ See Figure 13.17⁴⁸ for an image that compares ligaments and tendons.

under [CC BY 4.0](https://openstax.org/books/anatomy-and-physiology/pages/1-introduction). Access for free at <https://openstax.org/books/anatomy-and-physiology/pages/1-introduction>

46. This work is a derivative of [Anatomy and Physiology](https://openstax.org/books/anatomy-and-physiology/pages/1-introduction) by [OpenStax](https://openstax.org/books/anatomy-and-physiology/pages/1-introduction) licensed under [CC BY 4.0](https://openstax.org/books/anatomy-and-physiology/pages/1-introduction). Access for free at <https://openstax.org/books/anatomy-and-physiology/pages/1-introduction>

47. This work is a derivative of [Anatomy and Physiology](https://openstax.org/books/anatomy-and-physiology/pages/1-introduction) by [OpenStax](https://openstax.org/books/anatomy-and-physiology/pages/1-introduction) licensed under [CC BY 4.0](https://openstax.org/books/anatomy-and-physiology/pages/1-introduction). Access for free at <https://openstax.org/books/anatomy-and-physiology/pages/1-introduction>

48. “tendon-lig.jpg” by unknown author is licensed under [CC BY-SA 4.0](https://pressbooks.ccconline.org/bio106). Access for free at <https://pressbooks.ccconline.org/bio106>

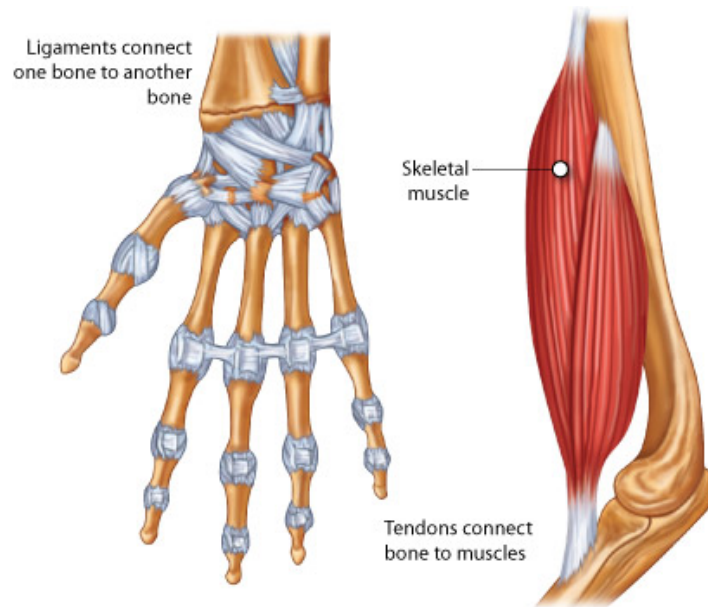


Figure 13.17 Comparison of Ligaments and Tendons

Cartilaginous Joints

Cartilaginous joints (kär-tĭ-LĀJ-ĭ-nŭs joints), also called amphiarthrosis or slightly moveable joints, occur when two bones are connected by **cartilage** (KĀR-tĭ-lĭj), a tough but flexible type of connective tissue. Examples of cartilaginous joints include the pubic synthesis and intervertebral disks.⁴⁹

Synovial Joints

Synovial joints (sĭ-NŌ-vē-ăl joints), also called diarthroses or fully movable joints, have a fluid-filled space where two bones come together, called a joint cavity. Because the bones in a synovial joint are not directly connected to each other with fibrous connective tissue or cartilage, they are able to move freely against each other, allowing for increased joint mobility. Synovial joints

49. This work is a derivative of [Anatomy and Physiology](https://openstax.org/books/anatomy-and-physiology/pages/1-introduction) by [OpenStax](https://openstax.org/books/anatomy-and-physiology/pages/1-introduction) licensed under [CC BY 4.0](https://creativecommons.org/licenses/by/4.0/). Access for free at <https://openstax.org/books/anatomy-and-physiology/pages/1-introduction>

are the most common type of joint in the body. A **synovial membrane** (sĭ-NŌ-vē-ăl MĚM-brān) is the lining or covering of synovial joints, and **synovial fluid** (sĭ-NŌ-vē-ăl FLŌŌ-id) is the lubricating fluid found between synovial joints. A **synovectomy** (sĭn-ō-VĚK-tō-mē) refers to excision of the synovial membrane.⁵⁰ See Figure 13.18⁵¹ for an illustration of a synovial joint.

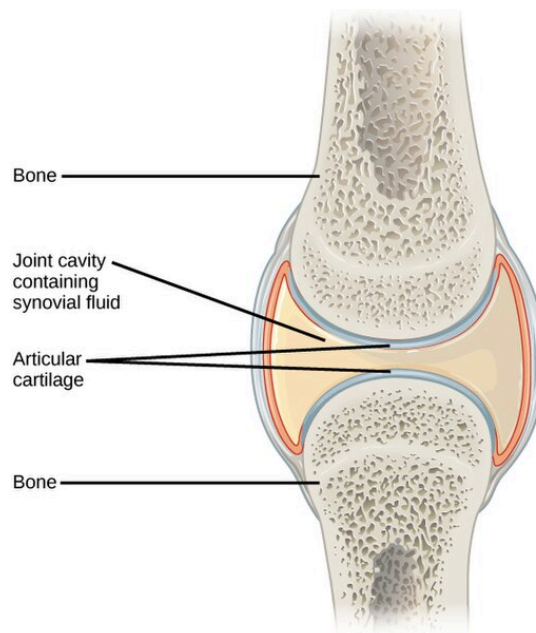


Figure 13.18 Synovial Joint

Types of Synovial Joints

Synovial joints are categorized based on the shapes of the articulating surfaces of the bones that form each joint. The six types of synovial joints are

50. This work is a derivative of [Anatomy and Physiology](#) by [OpenStax](#) licensed under [CC BY 4.0](#). Access for free at <https://openstax.org/books/anatomy-and-physiology/pages/1-introduction>

51. "[Figure_38_03_03.jpg](#)" by CNX OpenStax is licensed under [CC BY 4.0](#)

pivot, hinge, condyloid, saddle, plane, and ball-and-socket joints.⁵² See Figure 13.19⁵³ for an illustration of the various types of synovial joints.

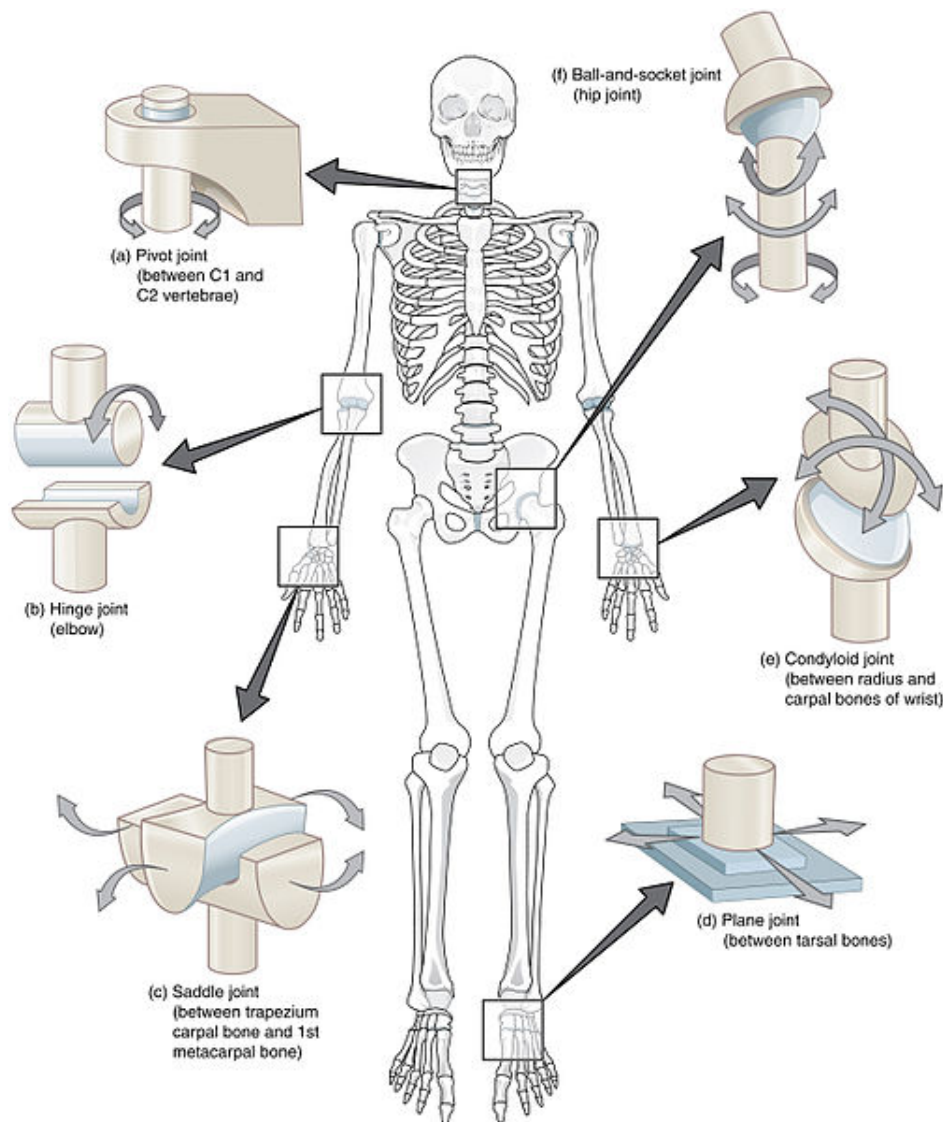


Figure 13.19 Types of Synovial Joints

52. This work is a derivative of *Anatomy and Physiology* by OpenStax licensed under CC BY 4.0. Access for free at <https://openstax.org/books/anatomy-and-physiology/pages/1-introduction>

53. “909 Types of Synovial Joints.jpg” by OpenStax College is licensed under CC BY 3.0

A few synovial joints of the body have a fibrocartilage structure located between the articulating bones called an articular disk or meniscus. **Articular disks** (är-TĪK-yŭ-lär dĭsk) are generally small and oval-shaped whereas a **meniscus** (mě-NĪS-kŭs) is larger and C-shaped. For example, the knee connects the femur (upper leg bone) to the tibia (one of the lower leg bones) with a piece of fibrous cartilage called the meniscus. **Meniscitis** (men-ĭ-SĪT-ĭs) refers to inflammation of the meniscus. A **meniscectomy** (měn-ĭ-SĚK-tō-mē) refers to excision of the meniscus.

In addition to the meniscus, the knee also contains ligaments, tendons, and additional cartilage. Ligaments in the knee include the **anterior cruciate ligament** (ăn-TĪR-ē-ör KRŪ-shē-āt LĪG-ă-měnt) (**ACL**), **lateral collateral ligament** (LĂT-ēr-ăl KŌL-ă-TĚR-ăl LĪG-ă-měnt) (**LCL**), **medial collateral ligament** (MĒ-dē-ăl KŌL-ă-TĚR-ăl LĪG-ă-měnt) (**MCL**), and **posterior cruciate ligament** (pŏs-TĪR-ē-ör KRŪ-shē-āt LĪG-ă-měnt) (**PCL**). See Figure 13.20⁵⁴ for an illustration of these structures in the knee joint.

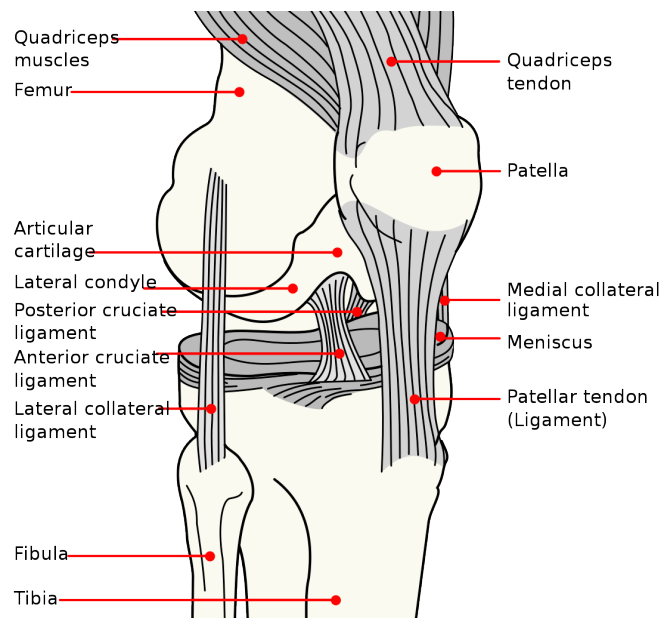


Figure 13.20 The Knee Joint Contains Ligaments, Tendons, Cartilage, and a Meniscus

54. “[Knee_diagram.svg](#)” by [Mysid](#) is licensed in the [Public Domain](#).

An additional structure located outside of a synovial joint is a bursa. A **bursa** (BŪR-să) is a thin connective tissue sac filled with lubricating fluid located in regions where skin, ligaments, muscles, or tendons rub against each other. Bursae are classified by their location. For example, a subcutaneous bursa is located between the skin and an underlying bone and allows skin to move smoothly over the bone.⁵⁵ Examples of a subcutaneous bursa are the suprapatellar bursa, prepatellar bursa, and infrapatellar bursa located in the knee, as seen in Figure 13.21.⁵⁶ **Bursitis** (bŭr-SĪ-tīs) refers to inflammation of a bursa, typically one in the knee, elbow, or shoulder. **Bursectomy** (bŭr-SĚK-tō-mē) refers to excision of a bursa.

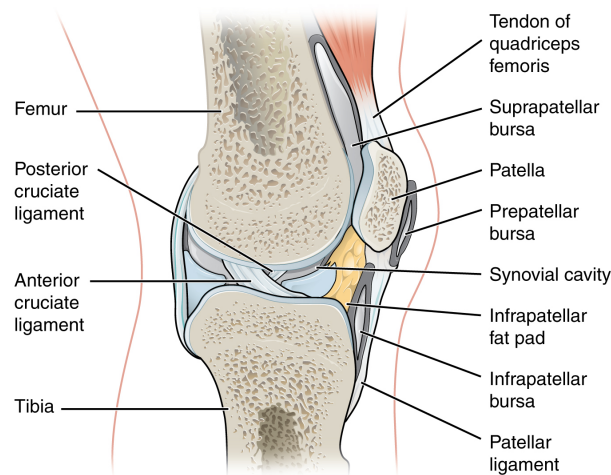


Figure 13.21 Bursa in the Knee

55. This work is a derivative of [Anatomy and Physiology](#) by [OpenStax](#) licensed under [CC BY 4.0](#). Access for free at <https://openstax.org/books/anatomy-and-physiology/pages/1-introduction>

56. “908_Bursa.jpg” by OpenStax College is licensed under [CC BY 3.0](#)



View a supplementary YouTube video⁵⁷ on joints: [Joints: Crash Course Anatomy & Physiology #20](#)

BONES

There are three types of cells related to the growth and breakdown of bone. **Osteoblasts** (OS-tē-ō-blastz) are bone-forming cells, and **osteocytes** (OS-tē-ō-sītz) are mature bone cells. The dynamic nature of bone means that new bone tissue is constantly being formed, and old, injured, or unnecessary bone is dissolved for repair or for calcium release. The cells responsible for bone breakdown are **osteoclasts** (ös-tē-ō-KLÄTZ). An equilibrium between osteoblasts and osteoclasts maintains healthy bone tissue.⁵⁸

Bones contain more **calcium** (KÄL-sē-ŭm) (**Ca+**) than any other organ. When blood calcium levels decrease below normal levels, calcium is released from the bones by the osteoclasts so there is an adequate supply for metabolic needs. In contrast, when blood calcium levels are increased, excess

57. CrashCourse. (2015, May 26). *Joints: Crash Course Anatomy & Physiology #20* [Video]. YouTube. All rights reserved.
<https://www.youtube.com/watch?v=DLxYDoN634c>

58. This work is a derivative of [Anatomy and Physiology](#) by [OpenStax](#) licensed under [CC BY 4.0](#). Access for free at <https://openstax.org/books/anatomy-and-physiology/pages/1-introduction>

calcium is stored in bone by the osteoblasts. This dynamic process of releasing and storing calcium goes on continuously.⁵⁹

The bones of the skeletal system are comprised of an inner spongy tissue referred to as bone marrow. There are two types of bone marrow called red and yellow. Red bone marrow produces the red blood cells, white blood cells, and platelets. Yellow bone marrow contains adipose tissue, which can serve as a source of energy. **Myeloma** (mī-ě-LŌ-mă)⁶⁰ is a type of cancer that forms in the bone marrow.

There are several medical terms related to bones:

- **Osteomalacia** (ös-tē-ō-mă-LĀ-sē-ă) refers to the softening of bone.
- **Osteomyelitis** (os-tē-ō-mī-ě-LĪT-īs) refers to the inflammation of bone and bone marrow.
- **Osteonecrosis** (os-tē-ō-ně-KRŌ-sīs) refers to bone death due to lack of adequate blood supply.
- **Osteosarcoma** (ös-tē-ō-săr-KŌ-mă) refers to a malignant tumor of bone.
- **Osteopenia** (os-tē-ō-PĒ-nē-ă) refers to abnormal reduction of bone mass.
- **Osteoporosis** (ös-tē-ō-pō-RŌ-sīs) refers to a medical condition in which bones become weak, brittle, and prone to fractures.

Read more information about osteopenia and osteoporosis in the “[Diseases and Disorders of the Skeletal System](#)” section.

59. This work is a derivative of [Anatomy and Physiology](#) by [OpenStax](#) licensed under [CC BY 4.0](#). Access for free at <https://openstax.org/books/anatomy-and-physiology/pages/1-introduction>

60. This work is a derivative of [Anatomy and Physiology](#) by [OpenStax](#) licensed under [CC BY 4.0](#). Access for free at <https://openstax.org/books/anatomy-and-physiology/pages/1-introduction>

Review additional information about bone marrow and the production of red blood cells, white blood cells, and platelets in the “[Anatomy of the Hematology System](#)” in the “Blood Terminology” chapter.

13.5 Physiology of the Skeletal System

The primary functions of the skeleton are to provide a rigid, internal structure that can support the weight of the body against the force of gravity, protect internal organs, and move the body with the help of muscles.¹

Synovial joints provide most of the movement of the body when bones and muscles work together at these joints. Movements created by synovial joints include flexion, extension, abduction, adduction, circumduction, and rotation.

Additional information about body movements is found in the “[Physiology of the Muscular System](#)” section of the “Muscular System Terminology chapter.

In addition to providing support and movements of the body, the skeleton has protective and storage functions. It protects the internal organs, including the brain, spinal cord, heart, lungs, and pelvic organs. The bones of the skeleton serve as the primary storage site for important minerals such as calcium and phosphate. Additionally, the bone marrow found within bones stores fat and houses the blood-cell producing tissue of the body.²

1. This work is a derivative of [Anatomy and Physiology](#) by [OpenStax](#) licensed under [CC BY 4.0](#). Access for free at <https://openstax.org/books/anatomy-and-physiology/pages/1-introduction>
2. This work is a derivative of [Anatomy and Physiology](#) by [OpenStax](#) licensed



View a supplementary YouTube video³ demonstrating movement at synovial joints:



One or more interactive elements has been excluded from this version of the text. You can view them online here: <https://wtcs.pressbooks.pub/medterm/?p=447#oembed-1>

under [CC BY 4.0](https://openstax.org/books/anatomy-and-physiology/pages/1-introduction). Access for free at <https://openstax.org/books/anatomy-and-physiology/pages/1-introduction>

3. RegisteredNurseRN. (2021, June 7). *Body movement terms anatomy / Body planes of motion / Synovial joint movement terminology* [Video]. YouTube. All rights reserved. Reused with permission.
<https://www.youtube.com/watch?v=KO4nUzO7xoo>

13.6 Diseases and Disorders of the Skeletal System

This section will discuss common diseases and disorders of the skeletal system.

ABNORMAL CURVATURES OF THE SPINE

The vertebral column normally has curvatures, but abnormal or excessive curvatures can develop due to diseases and disorders of the spine. Disorders associated with the curvature of the spine include scoliosis, kyphosis, and lordosis¹:

- **Scoliosis** (skō-lē-ō-sīs): Scoliosis is an abnormal, lateral curvature, accompanied by twisting of the vertebral column. See Figure 13.22a for an illustration of scoliosis. Scoliosis is the most common vertebral abnormality among girls. When present, scoliosis tends to worsen during adolescent growth spurts. A back brace may be recommended for growing children with scoliosis, and in severe cases, surgery may be required.
- **Kyphosis** (kī-FŌ-sīs): Kyphosis, commonly referred to as humpback, is an excessive posterior curvature of the thoracic region. This can develop when osteoporosis causes weakening and erosion of the anterior portions

¹ This work is a derivative of Anatomy & Physiology by [OpenStax](#) and is licensed under [CC BY 4.0](#). Access for free at <https://openstax.org/details/books/anatomy-and-physiology-2e>

of the upper thoracic vertebrae, resulting in their gradual collapse. See Figure 13.22b for an illustration of kyphosis.

- **Lordosis** (lor-DŌ-sīs): Lordosis, commonly referred to as swayback, is an excessive anterior curvature of the lumbar region and is most commonly associated with obesity or late pregnancy. See Figure 13.22c² for an illustration of lordosis. The accumulation of weight in the abdominal region results in an anterior shift in the line of gravity that carries the weight of the body. This causes an anterior tilt of the pelvis and a pronounced enhancement of the lumbar curve.

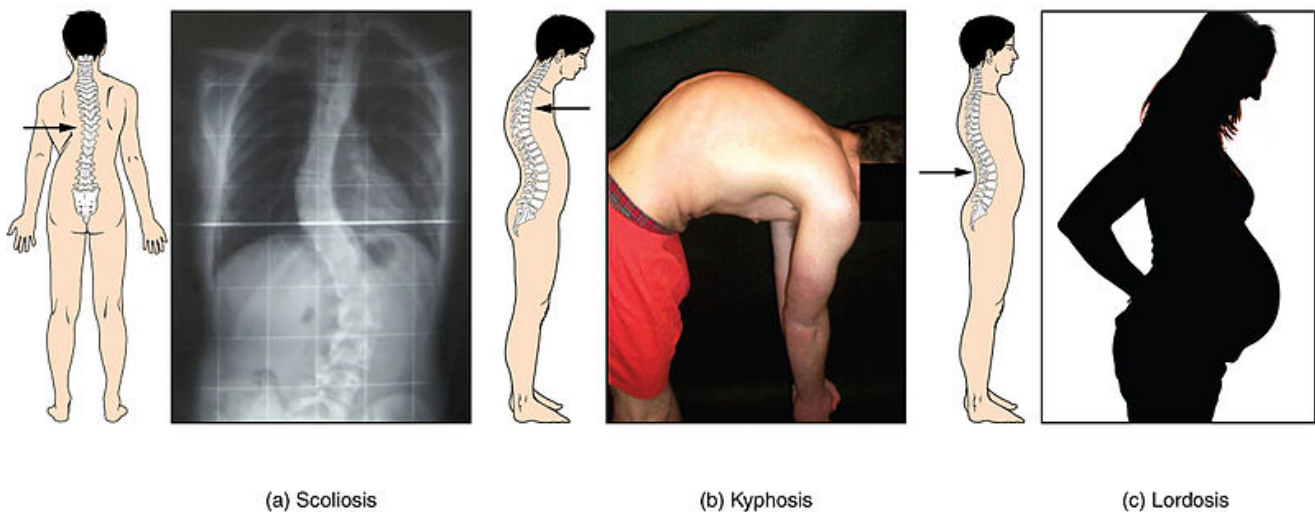


Figure 13.22 Abnormal Curvatures of the Vertebral Column. (a) Scoliosis (b) Kyphosis. (c) Lordosis

ARTHRITIS

Common types of **arthritis** (är-THRĪ-tīs) are osteoarthritis (OA), rheumatoid

2. “[717_Abnormal_Curves_of_Vertebral_Column.jpg](#)” by OpenStax College is licensed under [CC BY 3.0](#)

arthritis (RA), and gout. Read more about these conditions in the corresponding subsections.

BONE CANCER

There are three types of primary bone cancers: osteosarcoma, Ewing sarcoma, and chondrosarcoma. These are considered primary cancers because they originate in the bones. Osteosarcoma and Ewing sarcomas are cancers found in children, teenagers, and young adults. Ewing sarcoma is considered to be the more aggressive of the two cancers because it tends to metastasize quickly. Osteosarcoma is the most common type of bone cancer, and it begins in the tissues of growing bones. Chondrosarcoma develops in cells that produce cartilage and affects adults. Symptoms of bone cancer may include fatigue, unintended weight loss, bone pain, swelling, tenderness, and weakened bone leading to fractures. Diagnostic testing may include a bone scan, X-ray, CT scan, MRI, PET scan, and bone biopsies. Treatment is based on the type of cancer, the stage of the cancer, and the patient's overall health and preferences. For example, some bone cancers are treated with surgery; some are treated with surgery and chemotherapy; and others are treated with surgery, chemotherapy, and radiation therapy.³

CARPAL TUNNEL SYNDROME

Carpal tunnel syndrome is a disorder that occurs when the median nerve, which runs from the forearm into the palm of the hand, becomes pressed or

3. Mayo Clinic. (2023, May 11). *Bone cancer*. <https://www.mayoclinic.org/diseases-conditions/bone-cancer/symptoms-causes/syc-20350217>

squeezed at the wrist. Read more information about carpal tunnel syndrome in the “[Diseases and Disorders Related of the Nervous System](#).”

FRACTURE

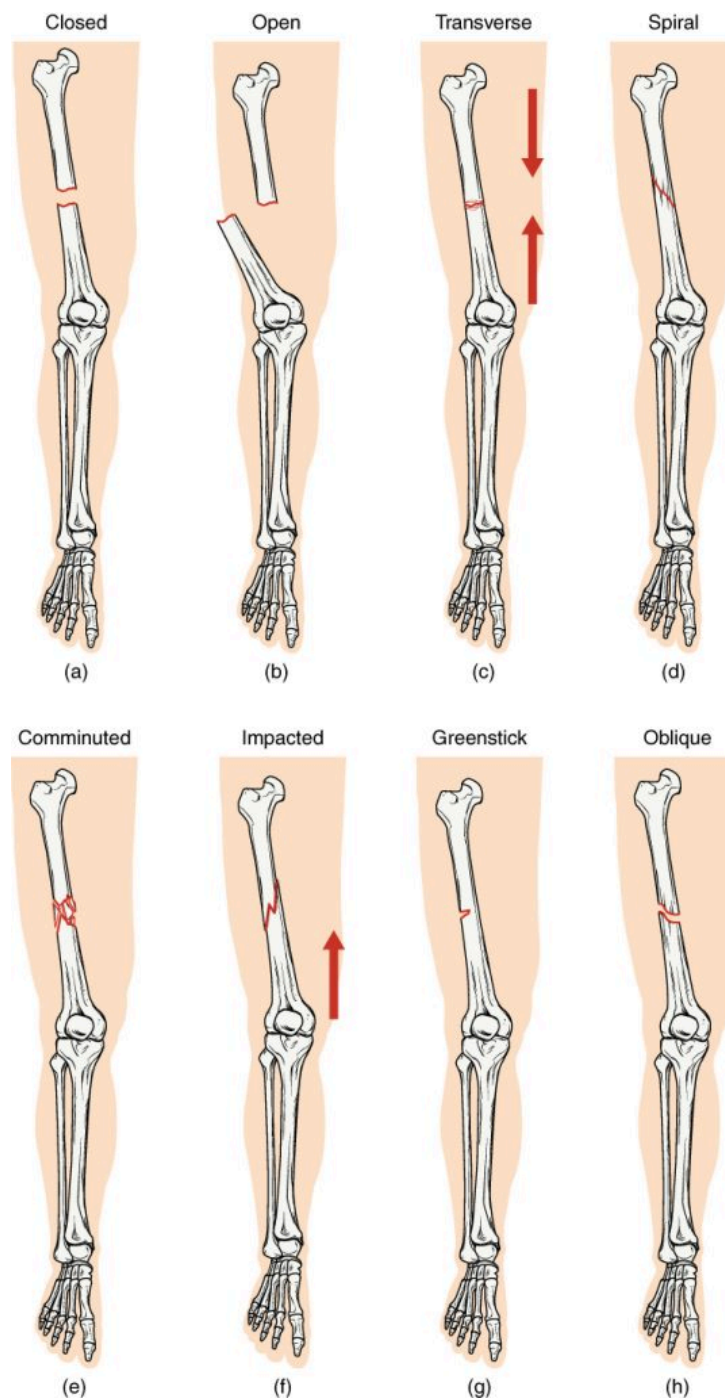
A **fracture** (FRÄK-chŭr) (**fx**) is a broken bone. It will heal automatically due to the action of osteoclasts and osteoblasts, but if the bone is not reset and aligned correctly, it will remain in a dislocated position. Fractures are classified by their complexity, location, and other features. Some fractures may be described using more than one term (e.g., an open transverse fracture) because it may have the features of more than one type. See Figure 13.23⁴ for an illustration of different types of fractures that include the following⁵:

- **Closed or simple** (klōzd ōr sĭm-pŭl frāk-chŭr): Bone is broken but does not protrude the skin
- **Open or compound** (ō-pĕn ōr kŏm-pound frāk-chŭr): Bone is broken and pierces through the skin
- **Transverse** (trăns-vûrs): Bone is broken straight across
- **Spiral** (spĭ-răl): Bone has twisted apart
- **Comminuted** (kŏm-ĭ-nŭ-tĕd): A bone is crushed into pieces
- **Impacted** (ĭm-păk-tĕd): One fragment of the bone is driven into the other, usually as a result of compression
- **Greenstick** (grĕn-stĭk): Bone is partially broken, a condition that occurs in children
- **Oblique** (ō-blĕk): Bone is broken at an angle

4. “[612_Types_of_Fractures.jpg](#)” by OpenStax College is licensed under [CC BY 4.0](#)

5. This work is a derivative of Anatomy & Physiology by [OpenStax](#) and is licensed under [CC BY 4.0](#). Access for free at <https://openstax.org/details/books/anatomy-and-physiology-2e>

- **Stress** (strěs): Small crack in a bone



13.23 Types of Fractures

GOUT

Gout (gowt) is a type of inflammatory arthritis that causes pain and swelling in the joints, usually as flares that last for one or two weeks and then resolve. Gout flares often begin in the big toe or a lower limb. Gout occurs when high levels of serum uric acid build up in the body, which can form needle-shaped crystals in and around the joint and cause inflammation. Uric acid is a waste product produced by the breakdown of purine, a type of molecule found in many foods we eat. Gout is diagnosed with blood tests for uric acid. It is commonly treated with medications like nonsteroidal anti-inflammatories (NSAIDs) and colchicine.⁶ See Figure 13.24⁷ for an illustration of gout.

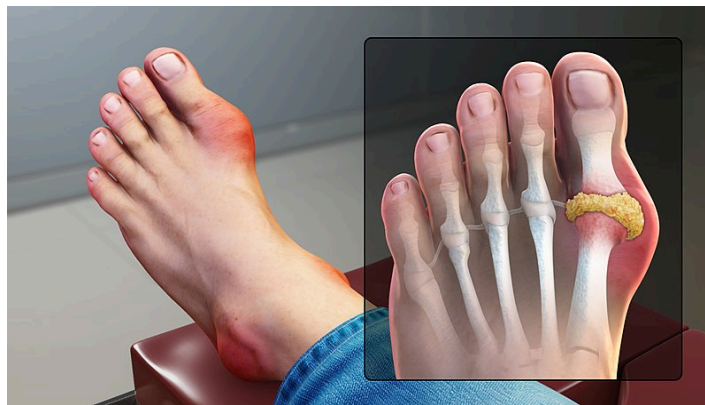

Figure 13.24 Gout

6. National Institute of Arthritis and Musculoskeletal and Skin Diseases. (2020, February). *Gout*. National Institutes of Health. <https://www.niams.nih.gov/health-topics/gout>

7. “Gout_Signs_and_Symptoms.jpg” by www.scientificanimations.com is licensed under [CC BY-SA 4.0](https://creativecommons.org/licenses/by-sa/4.0/)

LUPUS

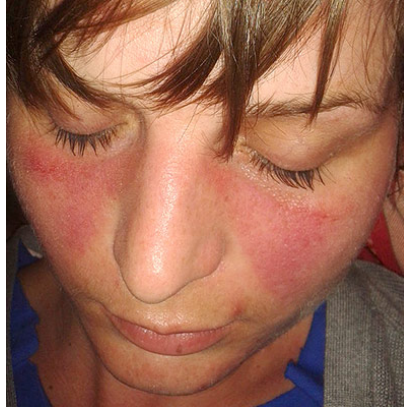Systemic lupus erythematosus (sīs-tēm-ĭk lū-pŭs ěr-ěth-ěm-ă-tō-sŭs), commonly referred to as **lupus** (lū-pŭs), is a chronic autoimmune disease that can affect many parts of the body. Lupus occurs when the immune system attacks its own tissues, causing inflammation and in some cases permanent tissue damage. Tissue damage can be widespread and affect the joints, skin, heart, lung, kidneys, blood cells, and brain.⁸

The symptoms of lupus vary from person to person. They can range from mild to severe, and they may come and go. Common symptoms can include arthritis, fatigue, and a classic rash that appears on the face across the nose and cheeks called a “butterfly rash.” See Figure 13.25⁹ for an image of a butterfly rash associated with lupus. No single test can be used to diagnose lupus, but a blood test called antinuclear antibodies (ANA) may be performed. There is no cure for lupus, but medications are prescribed to manage inflammation, and immunosuppressants may be used to curb the overactive immune system.¹⁰

8. National Institute of Arthritis and Musculoskeletal and Skin Diseases. (2022, October). *Systemic lupus erythematosus (lupus)*. National Institutes of Health. <https://www.niams.nih.gov/health-topics/lupus>

9. “Lupusfoto.jpg” by [Doktorinternet](#) is licensed under [CC BY-SA 4.0](#)

10. National Institute of Arthritis and Musculoskeletal and Skin Diseases. (2022, October). *Systemic lupus erythematosus (lupus)*. National Institutes of Health. <https://www.niams.nih.gov/health-topics/lupus>



*Figure 13.25 Butterfly
Rash on the Face
Associated With Lupus*

OSTEOARTHRITIS

Osteoarthritis (ös-tē-ō-är-THRĪ-tīs) is a degenerative joint disease in which the tissues in the joint break down over several years. It is the most common type of arthritis and frequently occurs as people age. People with osteoarthritis usually have joint pain or stiffness after rest or inactivity for a short period of time. The most commonly affected joints include the hands, knees, hips, neck, and lower back. See Figure 13.26¹¹ for an image of a person with osteoarthritis in their finger. Osteoarthritis affects each person differently. For some people, osteoarthritis is relatively mild and does not affect day-to-day activities. For others, it causes significant pain and disability.¹²

Crepitus (krěp-ĭ-tūs) describes a popping, clicking, or crackling sound when

11. "[Osteoarthritis_in_the_left_hand_index_finger.jpg](#)" by [Whoisjohngalt](#) is licensed under [CC BY-SA 4.0](#)

12. National Institute of Arthritis and Musculoskeletal and Skin Diseases. (2023, September). *Osteoarthritis*. National Institutes of Health. <https://www.niams.nih.gov/health-topics/osteoarthritis>

moving a joint that is associated with osteoarthritis. It typically reflects air movement in the joint and is harmless.¹³

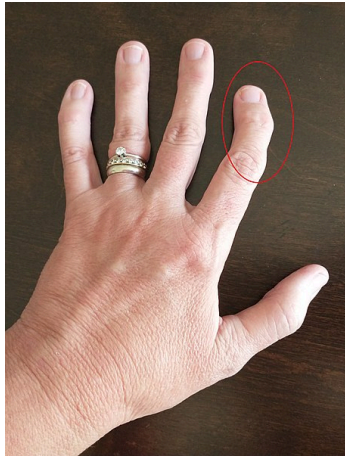

Figure 13.26
Osteoarthritis in the
Hand

Osteoarthritis is initially treated with lifestyle changes like exercise and weight management. Braces may be used to support the affected joints. Oral and topical pain relievers may be prescribed. If joint damage is severe, joint replacement surgery may be required.¹⁴

¹³. Drum, E. E., Kovats, A., Jones, M. D., Dennis, S., Naylor, J., Mills, K., & Thom, J. M. (2023). Creaky knees: Is there a reason for concern? A qualitative study of the perspectives of people with knee crepitus. *Musculoskeletal Care*, 21(4), 1114–1124. <https://doi.org/10.1002/msc.1793>

¹⁴. National Institute of Arthritis and Musculoskeletal and Skin Diseases. (2023, September). *Osteoarthritis*. National Institutes of Health. <https://www.niams.nih.gov/health-topics/osteoarthritis>

OSTEOMYELITIS

Osteomyelitis (ŏs-tē-ō-mī-ĕ-LĪT-ĭs) is an infection in a bone. Infections can reach a bone by traveling through the bloodstream or spreading from nearby tissue. Infections can also begin in the bone itself if an injury exposes the bone to bacteria. Smokers and people with chronic health conditions, such as diabetes or kidney failure, are at higher risk of developing osteomyelitis. People who have diabetes may develop osteomyelitis in their feet if they develop foot ulcers. Although once considered incurable, osteomyelitis can now be successfully treated with surgery and strong intravenous antibiotics.¹⁵

OSTEOPENIA AND OSTEOPOROSIS

Osteopenia (os-tē-ō-PĒ-nē-ă) is an abnormal reduction of bone mass that can lead to osteoporosis. **Osteoporosis** (ŏs-tē-ō-pō-RŌ-sĭs) is a condition where the bones become weak and brittle. Osteoporosis increases the risk of fractures and can also cause kyphosis as vertebrae gradually collapse. See Figure 13.27¹⁶ for an illustration of osteoporosis resulting in kyphosis. Osteoporosis is a “silent” disease because people typically do not have symptoms and do not know they have the disease until they break a bone. Osteoporosis is the major cause of fractures in postmenopausal women and in older men. Fractures due to osteoporosis can occur in any bone but happen most frequently in bones of the hip, vertebrae, and wrist.¹⁷ See Figure

15. Mayo Clinic. (2022, November 8). *Osteomyelitis*. <https://www.mayoclinic.org/diseases-conditions/osteomyelitis/symptoms-causes/syc-20375913>

16. “*Osteoporosis_Locations.png*” by [BruceBlau](#) is licensed under [CC BY-SA 4.0](#)

17. National Institute of Arthritis and Musculoskeletal and Skin Diseases. (2023,

13.27 for an illustration of osteoporosis compared to normal bone in the hip and spine.

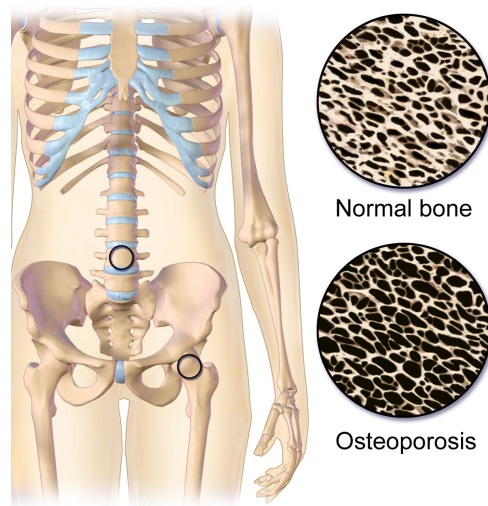


Figure 13.27 Osteoporosis in the Hip and Spine

The most common test for measuring bone mineral density is dual-energy X-ray absorptiometry (DEXA scan). Read more about this test in the “[Medical Specialists, Diagnostic Testing, and Procedures Related to the Skeletal System](#)” section of this chapter. Lifestyle changes like weight-bearing exercise and a nutritious diet rich in calcium and vitamin D can help prevent and treat osteoporosis. Medications that enhance bone density and strength are generally prescribed for people with osteoporosis.¹⁸

September). *Osteoarthritis*. National Institutes of Health.
<https://www.niams.nih.gov/health-topics/osteoarthritis>

18. National Institute of Arthritis and Musculoskeletal and Skin Diseases. (2023, September). *Osteoarthritis*. National Institutes of Health.
<https://www.niams.nih.gov/health-topics/osteoarthritis>

RHEUMATOID ARTHRITIS

Rheumatoid arthritis (rū-mă-toid är-thrī-tīs) (**RA**) is a chronic autoimmune disease that affects the joints. RA occurs in a symmetrical pattern, meaning that if one knee or hand has the condition, the other hand or knee is also affected. It can affect the joints in the wrists, hands, elbows, shoulders, feet, spine, knees, and jaw. RA causes pain, swelling, stiffness, deformity, and loss of function. See Figure 13.28¹⁹ for an illustration of rheumatoid arthritis in the hands causing a common “swan-like” deformity.²⁰

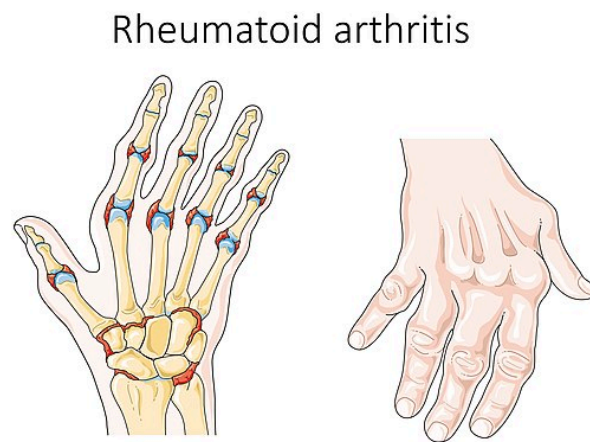


Figure 13.28 Rheumatoid Arthritis

Rheumatoid arthritis may be diagnosed with blood tests like rheumatoid

19. “[Rheumatoid_arthritis_-_Smart-Servier_\(cropped\).jpg](#)” by [Laboratoires Servier](#) is licensed under [CC BY-SA 3.0](#)

20. National Institute of Arthritis and Musculoskeletal and Skin Diseases. (2022, November). *Rheumatoid arthritis*. National Institutes of Health. <https://www.niams.nih.gov/health-topics/rheumatoid-arthritis>

factor or anti-CCP antibodies. It is treated with medications, physical and occupational therapy, and in some cases, joint repair or replacement.²¹

Rickets

Rickets (RĪK-īts) is a disease in children caused by extreme and prolonged vitamin D deficiency, characterized by softening and distortion of the bones. It typically results in a bow-legged appearance. See Figure 13.29²² for an image of children with rickets.



Figure 13.29 Rickets

21. National Institute of Arthritis and Musculoskeletal and Skin Diseases. (2022, November). *Rheumatoid arthritis*. National Institutes of Health. <https://www.niams.nih.gov/health-topics/rheumatoid-arthritis>
22. “[Photograph; three children with rickets Wellcome L0014375.jpg](#)” by unknown author from [Wellcome Collection Gallery](#) is licensed under [CC BY 4.0](#)

13.7 Medical Specialists, Diagnostic Testing, and Procedures Related to the Skeletal System

MEDICAL SPECIALISTS

Orthopedists and Orthopedic Surgeons

Orthopedics (or-thō-pē-dīks) is a branch of medicine that treats disorders and diseases related to the musculoskeletal system. **Orthopedists** (or-thō-pē-dīsts) are medical doctors who specialize in the prevention, diagnosis, treatment, and surgery of disorders and diseases related to the musculoskeletal system. Some orthopedists are generalists, whereas others specialize in certain areas of the body, such as the hip and knee, foot and ankle, shoulder and elbow, hand, or spine. Orthopedic surgeons perform surgery to repair a musculoskeletal injury or condition. They treat patients of all ages, from newborns to the elderly, and treat conditions such as fractures, sports injuries, joint replacements, and spinal deformities.¹

1. American Academy of Orthopaedic Surgeons. (n.d.). *Orthopaedic surgeons: Restoring mobility and keeping our nation in motion*. <https://www.aaos.org/about/what-is-an-orthopaedic-surgeon>

- ▶ For more details about orthopedists, see the [American Academy of Orthopaedic Surgeons' web page](#).

Rheumatologist

Rheumatology (rū-mă-tōl-ō-jē) is the study of inflammatory or infectious conditions of the joints and other parts of the musculoskeletal system.

Rheumatologists (rū-mă-tōl-ō-jists) are physicians who specialize in the diagnosis and treatment of musculoskeletal diseases and systemic autoimmune conditions, commonly referred to as rheumatic diseases. These diseases, such as rheumatoid arthritis, can potentially cause joint deformities.

- ▶ For more information, see the [American College of Rheumatology's web page called "What is a Rheumatologist?"](#)

Doctor of Osteopathy

Osteopathy (ōs-tē-OP-ă-thē) is a branch of medical practice that emphasizes the treatment of medical disorders through the manipulation and massage of the bones, joints, and muscles. A **Doctor of Osteopathic Medicine** (dōk-tōr ōf ōs-tē-ō-PĀTH-ĭk mēd-ĭ-sĭn) (**DO**) uses a whole-person approach to help prevent illness and injury. DOs look beyond symptoms to understand how lifestyle and environmental factors impact a person's well-being. They practice medicine according to science and technology, but also consider options to complement medications and surgery. As part of their education,

DOs receive special training in the musculoskeletal system, the body's interconnected system of nerves, muscles, and bones.²

- ▶ For more information, go to the American Osteopathic Association's [About Us web page](#).

Radiologist

A **radiologist** (RĀ-dē-ŏ-jĭst) is a physician who specializes in diagnosing and treating injuries and diseases using medical imaging (radiology) procedures such as X-rays, computed tomography (CT), magnetic resonance imaging (MRI), nuclear medicine, positron emission tomography (PET), and ultrasound. Diagnostic radiologists use a variety of imaging procedures to see inside the body and assess or diagnose the patient's condition. Interventional radiologists diagnose and treat patients using image-guided, minimally invasive techniques such as X-rays and MRI. They carefully guide instruments through tiny incisions in the body and deliver targeted treatments for conditions such as heart disease, stroke, cancer, and uterine fibroids. Radiation oncologists use radiation therapy to treat cancer.

- ▶ Read more information about radiologists on the American College of Radiology's web page [What is a Radiologist?](#)

Radiology Technologist

A **radiology technologist** (rā-dē-ŎL-ŏ-jē tĕk-nŎL-ŏ-jĭst), commonly called an

2. American Osteopathic Association. (n.d.). *About us*. <https://osteopathic.org/about/>

X-ray tech, is a health care professional who is specially trained to perform medical imaging like X-rays, CT scans, MRIs, and PET scans. To become a radiology technologist or MRI technologist, a person completes an associate degree and passes a certification exam.

- ▶ Read more information about the occupational outlook for radiology technologists on the U.S. Bureau of Labor Statistics' [Radiologic and MRI Technologists web page](#).

DIAGNOSTIC TESTING

Common diagnostic procedures related to the skeletal system are discussed in this section.

X-rays

X-rays (ěks-rāz) use a form of radiation that travels through the body and strikes an X-ray detector (such as radiographic film or a digital X-ray detector) on the other side of the patient, forming an image that represents the “shadows” of objects inside the body. Bones readily absorb X-rays and, therefore, produce high contrast on the X-ray detector. As a result, bony structures appear whiter than other tissues against the black background of a

radiograph. X-rays are used to detect bone fractures, tumors, and dental problems.³ See Figure 13.30⁴ for an image of a normal hip X-ray.

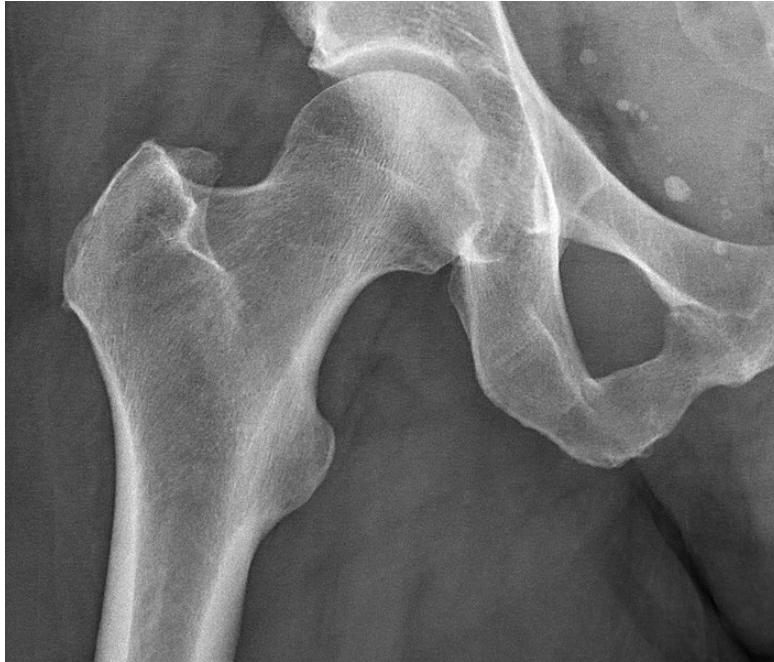

Figure 13.30 Normal Hip X-Ray

When used appropriately, the diagnostic benefits of X-ray scans significantly outweigh the risks. However, X-rays produce ionizing radiation, a form of radiation that has the potential to harm living tissue. This risk increases with the number of X-ray exposures added up over the lifetime of an individual. However, the risk of developing cancer from radiation exposure is generally

3. National Institute of Biomedical Imaging and Bioengineering. (2022, June). X-rays. National Institutes of Health. <https://www.nibib.nih.gov/science-education/science-topics/x-rays>
4. “X-ray of a normal hip.jpg” by Mikael Häggström, M.D. is licensed under [CC0](#), Public Domain

small. Children are more sensitive to ionizing radiation and have a long life expectancy, so machine settings can be adjusted according to the patient's age.⁵

Bone Mineral Density Testing

A **bone mineral density** (bōn mīn-ēr-āl dēn-sī-tē) is a test that measures calcium and other minerals in bone. Bones can become less dense as people age or if certain medical conditions occur. When too much bone is lost, osteopenia or osteoporosis can develop, causing bones to become weak and brittle and increasing the risk of fractures.⁶

The most common bone mineral density test is a central dual energy X-ray absorptiometry or also called a **DEXA scan** (DĚK-să skăn). DEXA scans use radiation to measure how much calcium and other minerals are in a specific area of the bone. Because the weakest bones that break most often due to osteoporosis are the hip and spine, DEXA scans typically measure bone mineral density in these bones.⁷ See Figure 13.31⁸ for an image of a DEXA scan.

5. National Institute of Biomedical Imaging and Bioengineering. (2022, June). X-rays. National Institutes of Health. <https://www.nibib.nih.gov/science-education/science-topics/x-rays>
6. National Institute of Arthritis and Musculoskeletal and Skin Diseases. (2023, May). *Bone mineral density tests: What the numbers mean*. National Institutes of Health. <https://www.niams.nih.gov/health-topics/bone-mineral-density-tests-what-numbers-mean>
7. National Institute of Arthritis and Musculoskeletal and Skin Diseases. (2023, May). *Bone mineral density tests: What the numbers mean*. National Institutes of Health. <https://www.niams.nih.gov/health-topics/bone-mineral-density-tests-what-numbers-mean>
8. “4371556142_3aeb50e381_b.jpg” by [ActiveSteve](#) is licensed under [CC BY-NC-ND 2.0](#)

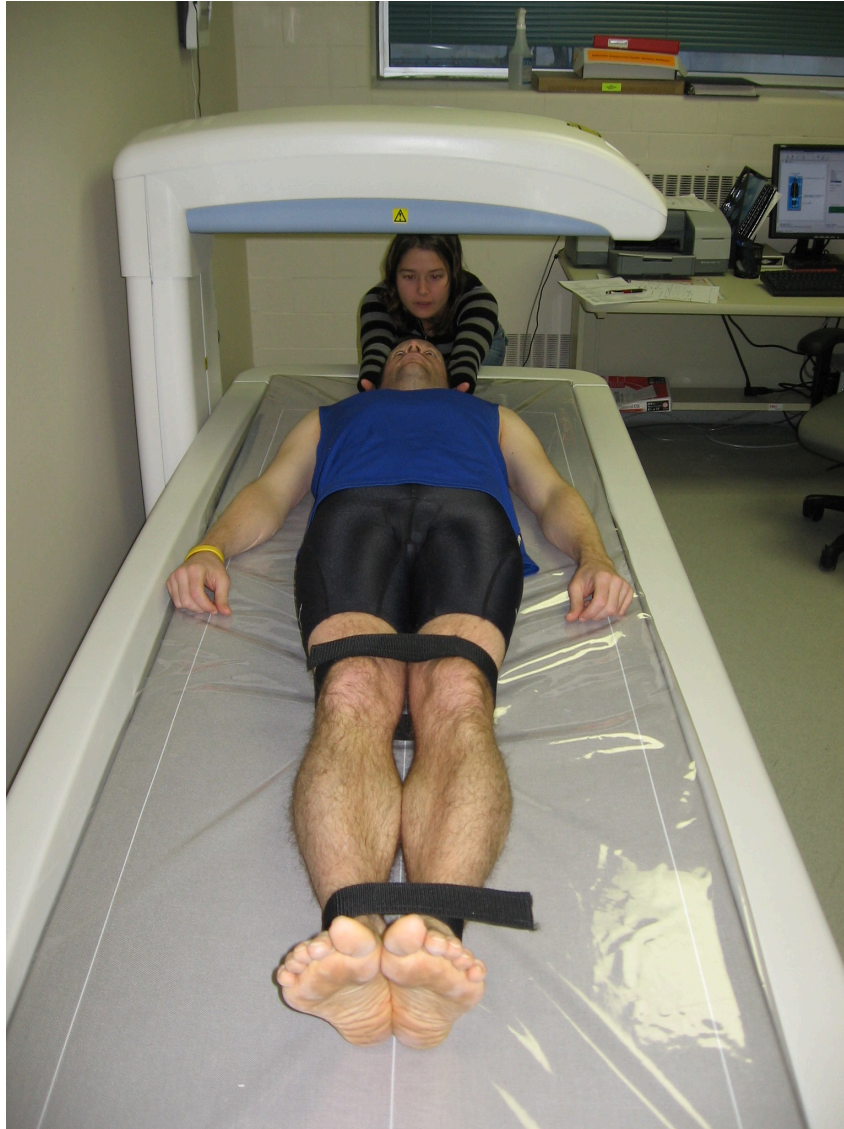

Figure 13.31 DEXA Scan

Postmenopausal women and men over age 50 receive bone mineral density test results as a “T-score.” A T-score is the difference between their bone mineral density and 0, which represents the bone mineral density of a healthy young adult. The lower the T-score, the higher the risk of bone fracture⁹:

9. National Institute of Arthritis and Musculoskeletal and Skin Diseases. (2023, May). *Bone mineral density tests: What the numbers mean*. National

- 1 or higher indicates the bone is healthy
- -1 to -2.5 indicates osteopenia
- -2.5 or lower indicates osteoporosis

PROCEDURES

Arthrocentesis

Arthrocentesis (ar-thrō-sen-TĒ-sīs) is a surgical puncture to aspirate fluid from a joint, such as the knee. It can help the health care provider find the cause of swollen, painful joints and can also provide symptom relief. After aspiration, the health care provider may inject medications into the joint to temporarily ease pain and inflammation.



View a supplementary YouTube video¹⁰ from Stanford EdTech on arthrocentesis: [Arthrocentesis – What to Expect](#)

Arthrodesis

Arthrodesis (ar-THROD-ě-sīs) is the surgical immobilization of a joint by fusion of the adjacent bones. This procedure is performed to relieve unrelenting pain in a joint that cannot be appropriately managed by

Institutes of Health. <https://www.niams.nih.gov/health-topics/bone-mineral-density-tests-what-numbers-mean>

10. Stanford EdTech. (2019, April 8). *Arthrocentesis – What to expect* [Video]. YouTube. All rights reserved. <https://www.youtube.com/watch?v=onbA5nPYKqU>

traditional treatments, physical therapy, splints, or pain medication. It is commonly performed on joints in the foot, ankle, spine, and wrist.¹¹

Arthroscopy

Arthroscopy (är-THRŌ-skō-pē) is a common procedure performed by orthopedic surgeons to view the inside of a joint to diagnose and/or to repair joint problems. The patient is given a local anesthetic, and the surgeon inserts an arthroscope through an incision in the skin. **Arthroplasty** (AR-thrŏ-plas-tē), surgical repair of a joint, may take place during the procedure.¹² See Figure 13.32¹³ for an illustration of a shoulder arthroscopy.

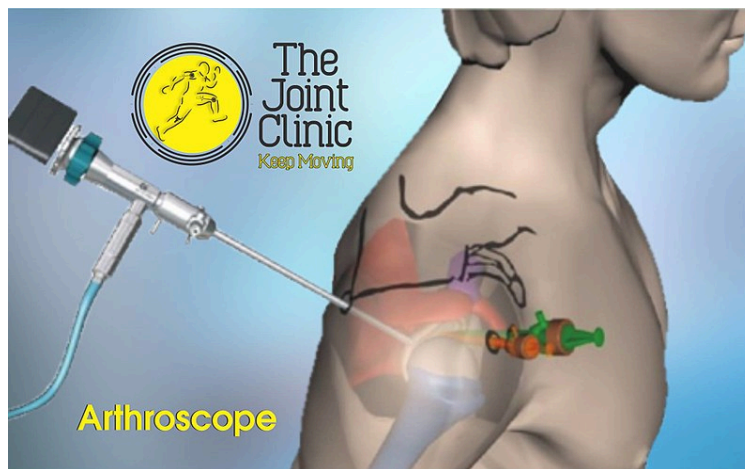


Figure 13.32 Shoulder Arthroscopy

11. This work is a derivative of [StatPearls](#) by Jimenez & Anand and is licensed under [CC BY 4.0](#)
12. Cleveland Clinic. (2021, June 23). *Arthrocentesis (joint aspiration)*. <https://my.clevelandclinic.org/health/treatments/14512-arthrocentesis-joint-aspiration>
13. “[Shoulder_Arthroscopy.jpg](#)” by [The Joint Clinic](#) is licensed under [CC BY-SA 4.0](#)

Below-the-Knee Amputation

A **below-the-knee amputation** (bĭ-lō-thē-nē ăm-pyū-TĀ-shŏn (**BKA**) is performed by an orthopedic surgeon who removes the foot, ankle, part of the tibia, fibula, and corresponding soft tissue structures. It is considered a life-saving procedure for patients who have decreased blood flow and/or infection of the lower extremity. It is typically performed due to trauma, severe peripheral arterial disease, and/or severe infection related to diabetes. After the procedure, the patient receives an artificial body part called a **prosthesis** (PRŌS-thē-sĭs) and participates in restorative care. Restorative care includes physical therapy and occupational therapy with the goal to achieve optimal functioning and independence in completing daily activities.¹⁴ See Figure 13.33¹⁵ for an image of a man with a leg prosthesis. Read more about physical therapy and occupational therapy in the “[Medical Specialists, Diagnostic Testing, and Procedures Related to the Muscular System](#)” in the “Muscular System Terminology” chapter.



Figure 13.33 Leg Prosthesis

- ¹⁴. This work is a derivative of [StatPearls](#) by Adams & Lakra and is licensed under [CC BY 4.0](#)
- ¹⁵. “[pexels-kampus-production-8346699.jpg](#)” by [Kampus Production](#) via [Pexels](#), is licensed under [CC0](#)

Joint Replacement Surgery

Arthroplasty (ÄR-thrō-plās-tē) refers to surgical repair or replacement of a joint. Common joint replacement surgeries include hip replacement, knee replacement, and shoulder replacement. See Figure 13.34¹⁶ for an illustration of joint replacement surgeries. During joint replacement surgery, an orthopedic surgeon removes the diseased parts of the joint and replaces them with new, artificial parts that mimic the function of the normal joint.

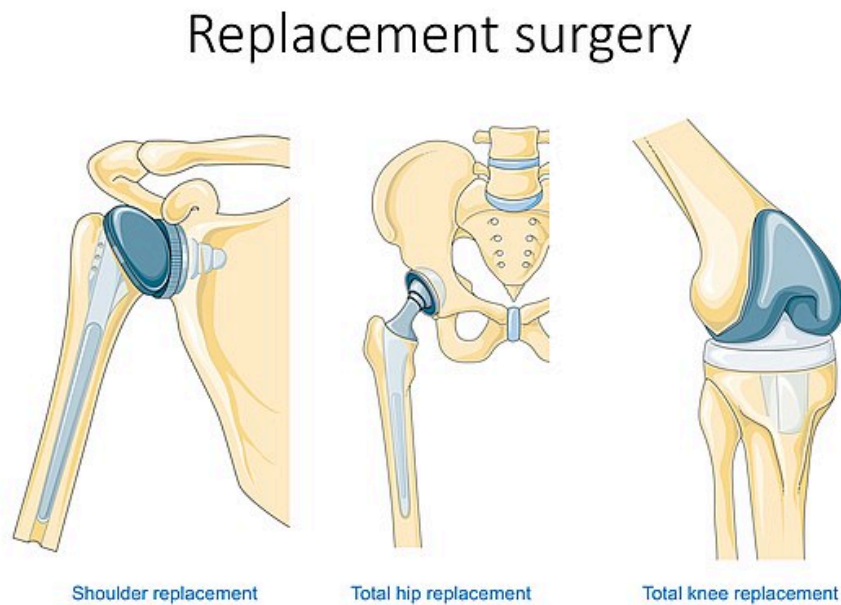


Figure 13.34 Joint Replacement Surgeries

A **total hip replacement** (tō-tāl hīp rē-plās-mēnt) (**THR**), also called a **total**

¹⁶. [“Replacement surgery - Shoulder total hip and total knee replacement – Smart-Servier.jpg”](#) by [Laboratoires Servier](#) is licensed under [CC BY-SA 3.0](#)

hip arthroplasty (tō-tāl hĭp är-thrŏ-plās-tē) (**THA**), refers to replacement of the head of the femur and acetabulum with replacement parts that are either metal, ceramic, or hard plastic. THR may be required due to osteoarthritis, **osteonecrosis** (when parts of a bone die due to decreased blood supply), or a hip fracture from an injury or fall.¹⁷

A **total knee replacement** (tō-tāl nē rē-plās-měnt) (**TKR**), also called **total knee arthroplasty** (tō-tāl nē är-thrŏ-plās-tē) (**TKA**), refers to surgical removal of worn surfaces of the knee joint due to severe osteoarthritis. During the surgery, damaged bone and cartilage are replaced with parts made of metal and plastic.

Open and Closed Reduction and Internal Fixation

Open reduction and internal fixation (ō-pěn rĭ-DŮK-shŏn ānd ĭn-těr-nāl fĭk-SĀ-shŏn) (**ORIF**) is a type of surgery used to stabilize and heal a broken bone. During an open reduction, orthopedic surgeons expose the bone and reposition the pieces of fractured bone, so they are back in their proper alignment and heal correctly. In contrast, during closed reduction surgery, a doctor physically moves the bones back into place without surgically exposing the bone. Internal fixation refers to physically reconnecting the bones using screws, plates, wires, or nails. See Figure 13.35¹⁸ for an X-ray illustration of femur fracture repaired with internal fixation using screws.

17. National Institute of Arthritis and Musculoskeletal and Skin Disease. (2023, August). *Hip replacement surgery*. National Institutes of Health. <https://www.niams.nih.gov/health-topics/hip-replacement-surgery>

18. “[Femur-fractura-nail-artificial-bone.png](#)” by Fry72 Karel Frydryšek is licensed under [CC BY-SA 4.0](#)

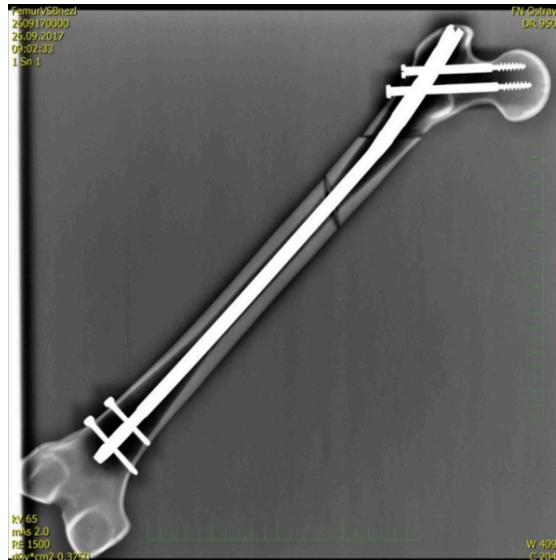

Figure 13.35 Internal Fixation of a Femur Fracture

13.8 Skeletal System

Learning Activities

Interactive Learning Activity: Practice labeling the skeletal system.



An interactive H5P element has been excluded from this version of the text. You can view it online here:

<https://wtcs.pressbooks.pub/medterm/?p=451#h5p-87>

Interactive Learning Activity: Study skeletal system medical terms discussed in this chapter using these flashcards.



An interactive H5P element has been excluded from this version of the text. You can view it online here:

<https://wtcs.pressbooks.pub/medterm/?p=451#h5p-187>

Interactive Learning Activity: Test your knowledge on these skeletal system terms and concepts.



An interactive H5P element has been excluded from this version of the text. You can view it online here:

<https://wtcs.pressbooks.pub/medterm/?p=451#h5p-93>

Interactive Learning Activity: Using the sample documentation provided, drag the terms on the right to their appropriate spaces within the documentation.



An interactive H5P element has been excluded from this version of the text. You can view it online here:

<https://wtcs.pressbooks.pub/medterm/?p=451#h5p-89>

Interactive Learning Activity: Using the sample documentation provided, drag the terms on the right to their appropriate spaces within the documentation.



An interactive H5P element has been excluded from this version of the text. You can view it online here:

<https://wtcs.pressbooks.pub/medterm/?p=451#h5p-90>



Interactive Learning Activity: Practice identifying and defining word parts for terms discussed in this chapter.



An interactive H5P element has been excluded from this version of the text. You can view it online here:

<https://wtcs.pressbooks.pub/medterm/?p=451#h5p-206>

► You can also print this as a [Chapter 13 Practice Worksheet](#) and check your answers with this [Answer Key PDF](#).

13.9 Glossary

Acetabulum (ăs-ě-TĀB-yŭ-lŭm): The socket of the hip bone, into which the head of the femur fits. ([Chapter 13.4](#))

Acromion (ă-KRŌ-mē-ŏn): An extension of the scapula that forms the high point of the shoulder. ([Chapter 13.4](#))

Anterior cruciate ligament (ăn-TĪR-ē-ŏr KRŪ-shē-āt LĪG-ă-měnt) (ACL): A ligament in the knee joint that connects the femur to the tibia and crosses in front of the PCL that provides stability to the knee. ([Chapter 13.4](#))

Arthritis (är-THRĪ-tīs): A general term for conditions affecting the joints and surrounding tissues, leading to pain, swelling, stiffness, and limited movement. It includes various types such as osteoarthritis and rheumatoid arthritis. ([Chapter 13.6](#))

Arthrocentesis (ar-thrō-sen-TĒ-sīs): A surgical puncture to aspirate fluid from a joint, such as the knee. ([Chapter 13.7](#))

Arthrodesis (ar-THROD-ě-sīs): The surgical immobilization of a joint by fusion of the adjacent bones. ([Chapter 13.7](#))

Arthroplasty (AR-thrŏ-plas-tē): Surgical repair of a joint. ([Chapter 13.7](#))

Arthroscopy (är-THRŌ-skō-pē): A common procedure performed by orthopedic surgeons to view the inside of a joint to diagnose and/or to repair joint problems. ([Chapter 13.7](#))

Articular disks (är-TĪK-yŭ-lăr dĭsks): Fibrocartilage structures in some synovial joints that act as cushions and improve the fit between the bones. ([Chapter 13.4](#))

Below-the-knee amputation (bĭ-lŏ-thē-nē âm-pyŭ-TĀ-shŏn) (BKA): A procedure performed by an orthopedic surgeon who removes the foot, ankle, part of the tibia, fibula, and corresponding soft tissue structures. ([Chapter 13.7](#))

Body (bŏd-ē): The middle portion of the sternum ([Chapter 13.4](#))

Bone mineral density (bŏn mĭn-ěr-ăl dĕn-sĭ-tē): A test that measures calcium and other minerals in bone. ([Chapter 13.7](#))

Bursa (BŪR-să): A small fluid-filled sac that acts as a cushion between a bone and other moving parts, such as muscles, tendons, or skin. ([Chapter 13.4](#))

- Bursectomy (bŭr-SĚK-tō-mē):** Surgical removal of a bursa. ([Chapter 13.4](#))
- Bursitis (bŭr-SĪ-tīs):** Inflammation of a bursa, usually occurring in the knee, elbow, or shoulder. ([Chapter 13.4](#))
- Calcaneus (kāl-KĀ-nē-ŭs):** The heel bone. ([Chapter 13.4](#))
- Calcium (KĀL-sē-ŭm) (Ca+):** A mineral essential for developing and maintaining healthy bones and teeth. ([Chapter 13.4](#))
- Carpals (KĀR-pālz):** The bones of the wrist. ([Chapter 13.4](#))
- Cartilage (KĀR-tī-līj):** A resilient and smooth elastic tissue that covers and protects the ends of bones at joints. ([Chapter 13.4](#))
- Cartilaginous joints (kär-tī-LĀJ-ī-nŭs joints):** Joints where bones are connected by cartilage, allowing more movement than fibrous joints but less than synovial joints. ([Chapter 13.4](#))
- Cervical (SŬR-vī-kāl):** Pertaining to the neck or the cervical vertebrae in the neck region. ([Chapter 13.4](#))
- Clavicle (KLĀV-ī-kŭl):** The collarbone, a long bone that serves as a strut between the shoulder blade and the sternum. ([Chapter 13.4](#))
- Closed or simple fracture (klōzd ōr sīm-pŭl):** A type of bone fracture where the skin over the fracture site remains intact, and the bone does not pierce through the skin. ([Chapter 13.6](#))
- Coccyx (KÖK-sĭks):** The tailbone, formed by the fusion of coccygeal vertebrae. ([Chapter 13.4](#))
- Comminuted (kōm-ī-nŭ-těd):** A bone is crushed into pieces. ([Chapter 13.6](#))
- Cranioplasty (KRĀ-nē-ō-plās-tē):** Surgical repair of the skull. ([Chapter 13.4](#))
- Craniotomy (krā-nē-ŌT-ō-mē):** A surgical procedure involving an incision through the cranium to access the brain. ([Chapter 13.4](#))
- Cranium (KRĀ-nē-ŭm):** The skull, especially the part encasing the brain. ([Chapter 13.4](#))
- Crepitus (krěp-ī-tŭs):** Describes a popping, clicking, or crackling sound when moving a joint that is associated with osteoarthritis. It typically reflects air movement in the joint and is harmless. ([Chapter 13.6](#))
- DEXA scan (DĚK-să skăn):** Shortened name for a central dual energy X-ray absorptiometry scan. These scans use radiation to measure how much calcium and other minerals are in a specific area of the bone. ([Chapter 13.7](#))

Disectomy (dīs-KEK-tō-mē): Surgical removal of an intervertebral disk. ([Chapter 13.4](#))

Diskitis (dīs-KĪ-tīs): Inflammation of an intervertebral disk. ([Chapter 13.4](#))

Dislocation (dīs-lō-KĀ-shōn): A condition where the bones in a joint become displaced from their normal alignment. ([Chapter 13.4](#))

Doctor of Osteopathic Medicine (dōk-tōr ōf ōs-tē-ō-PĀTH-ĭk mēd-ĭ-sĭn (DO): A medical specialist who uses a whole-person approach to help prevent illness and injury by looking beyond symptoms to understand how lifestyle and environmental factors impact a person's well-being. They practice medicine according to science and technology, but also consider options to complement medications and surgery. ([Chapter 13.7](#))

Ethmoid (ĒTH-moid): Related to the ethmoid bone, located between the eyes and forming part of the nasal cavity. ([Chapter 13.4](#))

False ribs (FÔLS rĭbz): Ribs 8-10, which are connected to the sternum via cartilage. ([Chapter 13.4](#))

Femur (FĒ-mŭr): The thigh bone, the longest and strongest bone in the body. ([Chapter 13.4](#))

Fibrous joints (FĪ-brŭs joints): Joints where bones are joined by fibrous tissue, typically allowing very little movement. ([Chapter 13.4](#))

Fibula (FĪB-yŭ-lă): The smaller and thinner bone of the lower leg located on the lateral side. ([Chapter 13.4](#))

Floating ribs (FLŌ-ă-tĭng rĭbz): The last two pairs of ribs, which are not attached to the sternum. ([Chapter 13.4](#))

Fracture (FRĀK-chŭr): A medical condition where there is a break in the continuity of the bone. It can range from minor cracks to complete breaks and can occur in any bone in the body. ([Chapter 13.6](#))

Frontal (FRŪN-tăĭ): Pertaining to the forehead or the frontal bone of the skull. ([Chapter 13.4](#))

Gout (gowt): A type of inflammatory arthritis that causes pain and swelling in the joints, usually as flares that last for one or two weeks and then resolve. Gout flares often begin in the big toe or a lower limb when high levels of serum uric acid build up in the body. ([Chapter 13.6](#))

Greenstick (grĕn-stĭk): Bone is partially broken, a condition that occurs in children. ([Chapter 13.6](#))

- Hallux (HĀL-lŭks):** The big toe. ([Chapter 13.4](#))
- Herniated disk (hŭr-nē-Ā-tīd dĭsk):** A condition where a disk protrudes beyond the normal confines of the vertebrae. ([Chapter 13.4](#))
- Humerus (HYŌŌ-mēr-ŭs):** The upper arm bone, extending from the shoulder to the elbow. ([Chapter 13.4](#))
- Hyoid (HĪ-oid):** A U-shaped bone in the neck that supports the tongue. ([Chapter 13.4](#))
- Ilium (ĪL-ē-ŭm):** The large, broad bone forming the upper part of each half of the pelvis. ([Chapter 13.4](#))
- Impacted (īm-pāk-tĕd):** One fragment of the bone is driven into the other, usually as a result of compression. ([Chapter 13.6](#))
- Inferior conchae (ĪN-fēr-ē-ŏr KŌN-kē):** Referring to the lowermost scroll-like bones on the lateral walls of the nasal cavity. ([Chapter 13.4](#))
- Intercostal (ĭn-tĕr-KŌS-tāl):** Located between the ribs. ([Chapter 13.4](#))
- Intercostal retractions (ĭn-tĕr-KŌS-tāl rē-trāk-SHŏnz):** The inward movement of the muscles between the ribs, typically a sign of respiratory distress. ([Chapter 13.4](#))
- Intervertebral disks (ĭn-tĕr-VĒRT-ĕ-brāl dĭsks):** Pertaining to the space or structure between two vertebrae. ([Chapter 13.4](#))
- Ischium (ĪS-kē-ŭm):** The curved bone forming the base of each half of the pelvis. ([Chapter 13.4](#))
- Joints (jŏyntz):** The locations where two or more bones meet, allowing for movement or stability in the skeleton. ([Chapter 13.4](#))
- Kyphosis (kī-FŌ-sīs):** An excessive outward curvature of the spine, causing a hunching of the back. It can result from degenerative diseases, developmental problems, osteoporosis, or trauma. ([Chapter 13.6](#))
- Lacrimal (LĀK-rĭ-māl):** Related to the lacrimal bones, small bones forming part of the eye socket. ([Chapter 13.4](#))
- Laminectomy (lām-ĭ-NĒK-tō-mē):** Surgical removal of a portion of the vertebral bone called the lamina. ([Chapter 13.4](#))
- Lateral collateral ligament (LĀT-ĕr-āl KŌL-ă-TĒR-āl LĪG-ă-mĕnt) (LCL):** A ligament on the outer side of the knee joint connecting the femur to the fibula. ([Chapter 13.4](#))

Lateral malleolus (LĀT-ēr-ăl MĀL-ē-ō-lūs): The bony prominence on the outside of the ankle, formed by the lower end of the fibula. ([Chapter 13.4](#))

Ligaments (LĪG-ă-měnts): Bands of tough, fibrous connective tissue that connect bones to other bones at joints. ([Chapter 13.4](#))

Lordosis (lor-DŌ-sīs): An excessive inward curvature of the spine, often affecting the lower back. It can be caused by obesity, poor posture, or other underlying conditions. ([Chapter 13.6](#))

Lumbar (LŪM-bār): Related to the lower back or the lumbar vertebrae. ([Chapter 13.4](#))

Lupus (lū-pūs): Common name for systemic lupus erythematosus; a chronic autoimmune disease that can affect many parts of the body. ([Chapter 13.6](#))

Mandible (MĀN-dī-bŭl): The lower jawbone. ([Chapter 13.4](#))

Manubrium (mă-NŪ-brē-ŭm): The upper part of the sternum. ([Chapter 13.4](#))

Maxillary (MĀK-sī-lār-ē): Pertaining to the maxilla or the upper jawbone. ([Chapter 13.4](#))

Medial collateral ligament (MĒ-dē-ăl KŌL-ă-TĒR-ăl LĪG-ă-měnt) (MCL): A ligament on the inner side of the knee, connecting the femur to the tibia. ([Chapter 13.4](#))

Medial malleolus (MĒ -dē-ăl MĀL-ē-ō-lūs): The bony prominence on the inside of the ankle, formed by the lower end of the tibia. ([Chapter 13.4](#))

Meniscectomy (měn-ī-SĚK-tō-mē): Surgical removal of all or part of a torn meniscus. ([Chapter 13.4](#))

Meniscitis (men-ī-SĪT-īs): Inflammation of a meniscus, typically in the knee. ([Chapter 13.4](#))

Meniscus (mě-NĪS-kŭs): A C-shaped piece of cartilage in the knee joint that acts as a shock absorber between the femur and tibia. ([Chapter 13.4](#))

Metacarpals (mět-ă-KĀR-pălz): The bones of the hand between the wrist and the fingers. ([Chapter 13.4](#))

Metatarsals (mět-ă-TĀR-sălz): The bones in the midfoot and forefoot. ([Chapter 13.4](#))

Myeloma (mī-ě-LŌ-mă): A type of cancer that originates in the bone marrow. ([Chapter 13.4](#))

Nasal (NĀ-zăl): Pertaining to the nasal bones of the nose. ([Chapter 13.4](#))

Oblique (ō-blēk): Bone is broken at an angle. ([Chapter 13.6](#))

Occipital (ōk-SĪP-ĭ-tāl): Pertaining to the occipital bone at the back and base of the skull. ([Chapter 13.4](#))

Open or compound fracture (ō-pĕn ōr kŏm-pound): A severe type of bone fracture where the broken bone pierces through the skin, creating an open wound. This type increases the risk of infection. ([Chapter 13.6](#))

Open reduction and internal fixation (ō-pĕn rĭ-DŪK-shŏn ānd ĭn-tĕr-nāl fĭk-SĀ-shŏn) (ORIF): A type of surgery used to stabilize and heal a broken bone using screws, plates, wires, or nails to reconnect bones. ([Chapter 13.7](#))

Orthopedics (or-thŏ-pē-dĭks): A branch of medicine that treats disorders and diseases related to the musculoskeletal system. ([Chapter 13.7](#))

Orthopedists (or-thŏ-pē-dĭsts): Medical doctors who specialize in the prevention, diagnosis, treatment, and surgery of disorders and diseases related to the musculoskeletal system. ([Chapter 13.7](#))

Osteoarthritis (ŏs-tē-ō-ār-THRĪ-tĭs): A degenerative joint disease in which the tissues in the joint break down over several years. It is the most common type of arthritis and frequently occurs as people age. ([Chapter 13.6](#))

Osteoblasts (ŏs-tē-ō-BLĀSTS): Cells that form new bone tissue. ([Chapter 13.4](#))

Osteoclasts (ŏs-tē-ō-KLĀSTS): Cells that break down and resorb bone tissue. ([Chapter 13.4](#))

Osteocytes (ŏs-tē-Ō-SĪTS): Mature bone cells that maintain bone tissue. ([Chapter 13.4](#))

Osteomalacia (ŏs-tē-ō-mă-LĀ-sē-ă): Softening of bones due to a deficiency of vitamin D or calcium. ([Chapter 13.4](#))

Osteomyelitis (ŏs-tē-ō-mĭ-ĕ-LĪT-ĭs): Inflammation of bone and bone marrow, usually caused by infection. ([Chapter 13.4](#), [Chapter 13.6](#))

Osteonecrosis (ŏs-tē-ō-nĕ-KRŌ-sĭs): Death of bone tissue due to a lack of blood supply. ([Chapter 13.4](#), [Chapter 13.7](#))

Osteopathy (ŏs-tē-ŏ-pă-thē): A branch of medical practice that emphasizes the treatment of medical disorders through the manipulation and massage of the bones, joints, and muscles. ([Chapter 13.7](#))

Osteopenia (ŏs-tē-ō-PĒ-nē-ă): Reduced bone mass of lesser severity than osteoporosis. ([Chapter 13.4](#), [Chapter 13.6](#))

Osteoporosis (ös-tē-ō-pō-RŌ-sīs): A condition where bones become weak and brittle, often due to loss of tissue as a result of hormonal changes or deficiency of calcium or vitamin D. It increases the risk of fractures. ([Chapter 13.4](#), [Chapter 13.6](#))

Osteosarcoma (ös-tē-ō-sär-KŌ-mă): A type of malignant bone tumor. ([Chapter 13.4](#))

Palatine (PĀL-ă-tīn): Related to the palatine bones of the skull, forming parts of the nasal cavity and hard palate. ([Chapter 13.4](#))

Parietal (pă-rī-ĒT-ăl): Pertaining to the parietal bones of the skull, located at the sides and top of the cranium. ([Chapter 13.4](#))

Patella (pă-TĒL-ă): The kneecap, a small bone in front of the knee joint. ([Chapter 13.4](#))

Pelvis (PĒL-vīs): The large bony structure near the base of the spine which includes the two hip bones, the sacrum, and the coccyx to which the legs are attached. ([Chapter 13.4](#))

Phalanges (fă-LĀN-jēz): The bones of the fingers and toes. ([Chapter 13.4](#))

Phalanx (FĀ-lăngks): A single bone of the fingers or toes. ([Chapter 13.4](#))

Posterior cruciate ligament (pös-TĪR-ē-ör KRŪ-shē-āt LĪG-ă-měnt) (PCL): A ligament in the knee that crosses behind the ACL and connects the femur to the tibia. ([Chapter 13.4](#))

Prosthesis (PRŌS-thē-sīs): An artificial body part. ([Chapter 13.7](#))

Pubic symphysis (PYŪ-bīk SĪM-fī-sīs): The joint between the two pubic bones at the front of the pelvis. ([Chapter 13.4](#))

Pubis (PYŪ-bīs): The front part of the pelvic girdle, situated at the anterior part of the pelvis. ([Chapter 13.4](#))

Radiologist (RĀ-dē-ō-jīst): A physician who specializes in diagnosing and treating injuries and diseases using medical imaging (radiology) procedures such as X-rays, computed tomography (CT), magnetic resonance imaging (MRI), nuclear medicine, positron emission tomography (PET), and ultrasound. ([Chapter 13.7](#))

Radiology technologist (rā-dē-ŌL-ō-jē tēk-nŌL-ō-jīst): Commonly called an X-ray tech, is a health care professional who is specially trained to perform medical imaging like X-rays, CT scans, MRIs, and PET scans. ([Chapter 13.7](#))

Radius (RĀ-dē-ūs): The lateral bone of the forearm, on the same side as the thumb. ([Chapter 13.4](#))

Rheumatoid arthritis (rū-mă-toid är-thrī-tīs) (RA): A chronic autoimmune disease that affects the joints. ([Chapter 13.6](#))

Rheumatologists (rū-mă-tōl-ō-jīsts): Physicians who specialize in the diagnosis and treatment of musculoskeletal diseases and systemic autoimmune conditions commonly referred to as rheumatic diseases. ([Chapter 13.7](#))

Rheumatology (rū-mă-tōl-ō-jē): The study of inflammatory or infectious conditions of the joints and other parts of the musculoskeletal system. ([Chapter 13.7](#))

Rickets (RĪK-īts): A disease in children caused by extreme and prolonged vitamin D deficiency. ([Chapter 13.6](#))

Sacrum (SĀ-krŭm): A triangular bone at the base of the spine, formed by the fusion of sacral vertebrae. ([Chapter 13.4](#))

Scapula (SKĀP-yŭ-lă): The shoulder blade, a large triangular bone on the back of the shoulder. ([Chapter 13.4](#))

Scoliosis (skō-lē-ō-sīs): An abnormal lateral curvature of the spine, often diagnosed in childhood or adolescence. It can vary in severity and may require treatments such as bracing or surgery in more severe cases. ([Chapter 13.6](#))

Sphenoid (SFĒ-noid): Pertaining to the sphenoid bone, a complex bone at the base of the skull. ([Chapter 13.4](#))

Spiral (spī-răl): Bone has twisted apart. ([Chapter 13.6](#))

Spondylosis (spŏn-dī-LŌ-sīs): A painful condition of the spine resulting from the degeneration of intervertebral disks. ([Chapter 13.4](#))

Sternum (STŪR-nŭm): The breastbone, a long flat bone in the center of the chest. ([Chapter 13.4](#))

Stress (strēs): Small crack in a bone. ([Chapter 13.6](#))

Synovectomy (sĭn-ō-VĚK-tō-mē): Surgical removal of the synovial membrane from a joint. ([Chapter 13.4](#))

Synovial fluid (sĭ-NŌ-vē-ăl FLŌŌ-id): A viscous fluid found in the cavities of synovial joints, reducing friction between the articular cartilage during movement. ([Chapter 13.4](#))

Synovial joints (sĭ-NŌ-vē-ăl joints): Highly movable joints where two bones are separated by a joint cavity containing synovial fluid. ([Chapter 13.4](#))

Synovial membrane (sĭ-NŌ-vē-ăl MĚM-brān): The lining of the inner surface of capsules of synovial joints, secreting synovial fluid for lubrication. ([Chapter 13.4](#))

Systemic lupus erythematosus (sĭs-tēm-ĭk lū-pŭs ěr-ěth-ěm-ă-tō-sŭs): Commonly referred to as lupus; a chronic autoimmune disease that can affect many parts of the body. ([Chapter 13.6](#))

Tarsals (TĀR-sălz): The bones in the rear part of the foot (the heel and the instep). ([Chapter 13.4](#))

Temporal (TĚM-pō-răl): Related to the temporal bones of the skull, located at the lower sides. ([Chapter 13.4](#))

Temporomandibular joint (tēm-pō-rō-MĀN-dĭ-bŭ-lăr) (TMJ): The hinge joint connecting the temporal bone of the skull with the mandible. ([Chapter 13.4](#))

Tendon (TĚN-dŏn): A fibrous connective tissue that attaches muscle to bone. ([Chapter 13.4](#))

Thoracic (thō-RĀS-ĭk): Pertaining to the thorax or the thoracic vertebrae in the upper back. ([Chapter 13.4](#))

Tibia (TĪB-ē-ă): The shin bone, the larger and stronger of the two bones in the lower leg located on the medial side. ([Chapter 13.4](#))

Total hip arthroplasty (tō-tăl hĭp ār-thrŏ-plăs-tē) (THA): Also called a total hip replacement (THR), the replacement of the head of the femur and acetabulum with replacement parts that are either metal, ceramic, or hard plastic. ([Chapter 13.7](#))

Total hip replacement (tō-tăl hĭp rē-plăs-mĕnt) (THR): Also called a total hip arthroplasty (THA), the replacement of the head of the femur and acetabulum with replacement parts that are either metal, ceramic, or hard plastic. ([Chapter 13.7](#))

Total knee arthroplasty (tō-tăl nē ār-thrŏ-plăs-tē) (TKA): Also called total knee replacement (TKR), surgical removal of worn surfaces of the knee joint due to severe osteoarthritis. ([Chapter 13.7](#))

Total knee replacement (tō-tăl nē rē-plăs-mĕnt) (TKR): Also called total

knee arthroplasty (TKA), surgical removal of worn surfaces of the knee joint due to severe osteoarthritis. ([Chapter 13.7](#))

Transverse (trăns-vûrs): Bone is broken straight across. ([Chapter 13.6](#))

True ribs (TRŌŌ rîbz): The first seven pairs of ribs, which attach directly to the sternum. ([Chapter 13.4](#))

Ulna (ŮL-nă): The medial bone of the forearm, on the same side as the pinky finger. ([Chapter 13.4](#))

Vertebrae (VŮR-tĭ-brā): The individual bones that make up the vertebral column (spine). ([Chapter 13.4](#))

Vertebral column (vŭr-TĒ-brāl KŌL-ŭm): The spinal column or backbone, consisting of multiple vertebrae. ([Chapter 13.4](#))

Vomer (VŌ-měr): A thin, flat bone forming the lower part of the nasal septum. ([Chapter 13.4](#))

Xiphoid process (Zĭ-foïd PRŌ-sēs): The small, cartilaginous projection at the lower end of the sternum. ([Chapter 13.4](#))

X-rays (ěks-rāz): Use a form of radiation that travels through the body and strikes an X-ray detector, forming an image that represents the “shadows” of objects inside the body. ([Chapter 13.7](#))

Zygomatic (zĭ-gō-MĀT-ĭk): Related to the cheekbone or zygomatic bone. ([Chapter 13.4](#))

PART XIV

CHAPTER 14 MUSCULAR SYSTEM TERMINOLOGY

14.1 Muscular System

Introduction

Learning Objectives

- Apply the rules of medical language to build, analyze, spell, pronounce, abbreviate, and define terms as they relate to the muscular system
- Identify meanings of key word components of the muscular system
- Categorize diagnostic, therapeutic, procedural, or anatomic terms related to the muscular system
- Use terms related to the muscular system
- Use terms related to the diseases and disorders of the muscular system

Introduction to the Muscular System

When most people think of muscles, they think of the muscles that move our arms and legs. These are called skeletal muscles because they move the skeleton. However, there are two additional types of muscles, including smooth muscle and the cardiac muscle. The basic function of all types of muscle is to create movement.

This chapter will review common word components related to the muscular system to assist learners in analyzing, building, and defining medical terms. Other terms, whose definitions cannot be easily built from word components,

will be described in context based on the anatomy and physiology of the muscular system and common diseases and disorders. Medical specialists, diagnostic tests, and procedures related to the muscular system will also be discussed.

View a supplementary YouTube video¹ on muscles:

▶◀ [Muscles, Part 2 – Organismal Level: Crash Course Anatomy & Physiology #22](https://www.youtube.com/watch?v=I80Xx7pA9hQ)

1. CrashCourse. (2015, June 15). *Muscles, Part 2 – Organismal level: Crash Course Anatomy & Physiology #22* [Video]. YouTube. All rights reserved. <https://www.youtube.com/watch?v=I80Xx7pA9hQ>

14.2 Word Components Related To The Muscular System

This section will describe common word components related to the muscular system. These word components help build definitions for many medical terms. Other common prefixes are described in [Chapter 1.3](#), and common suffixes are described in [Chapter 1.5](#).

PREFIXES RELATED TO THE MUSCULAR SYSTEM

- **a-**: Absence of, without
- **ab-**: Away from
- **ad-**: Towards
- **brady-**: Slow
- **dys-**: Painful, difficult, abnormal, labored
- **hyper-**: Above, excessive
- **inter-**: Between
- **intra-**: Within, in
- **poly-**: Many, much
- **sub-**: Below, under
- **supra-**: Above
- **sym-**: Together, joined
- **syn-**: Together, joined

WORD ROOTS WITH A COMBINING VOWEL RELATED TO THE MUSCULAR SYSTEM

- **ankyl/o**: Stiff or bent
- **electr/o**: Electricity; electrical activity
- **fasci/o**: Fascia
- **fibr/o**: Fibrous connective tissue
- **kinesi/o**: Movement, motion
- **kyph/o**: Hump
- **lamin/o**: Lamina (thin, flat plate or layer)
- **leimy/o**: Smooth (visceral) muscle that lines the walls of internal organs
- **my/o**: Muscle
- **myel/o**: Spinal cord, bone marrow
- **myos/o**: Muscle
- **myocardi/o**: Heart muscle
- **plant/o**: Sole of the foot
- **rhabd/o**: Rod-shaped, striated
- **sarc/o**: Flesh, connective tissue
- **ten/o**: Tendon
- **tend/o**: Tendon
- **tendin/o**: Tendon

SUFFIXES RELATED TO THE MUSCULAR SYSTEM

- **-ad**: Toward
- **-al**: Pertaining to
- **-algia**: Pain

- **-ar**: Pertaining to
- **-asthenia**: Weakness
- **-centesis**: Surgical puncture to aspirate fluid
- **-desis**: Surgical fixation, fusion
- **-ectomy**: Excision, surgical removal, cutting out
- **-gram**: The record, radiographic image
- **-graphy**: Process of recording, radiographic imaging
- **-ic**: Pertaining to
- **-itis**: Inflammation
- **-lysis**: Loosening, separating, dissolution
- **-oid**: Resembling
- **-oma**: Tumor
- **-osis**: Abnormal condition
- **-penia**: Abnormal reduction
- **-physis**: Growth
- **-plasty**: Surgical repair
- **-rrhaphy**: Suturing, repairing
- **-sarcoma**: Malignant tumor
- **-schisis**: Split, fissure
- **-scopy**: Process of viewing, visual examination
- **-tome**: Instrument used to cut
- **-tomy**: Incision, cut into
- **-trophy**: Nourishment, development

14.3 Examples of Muscular Terms Easily Defined By Their Word Components

Here are examples of common medical terms related to the muscular system that can be easily defined by breaking the terms into their word components.

Bradykinesia

1. Break down the medical term into word components:
Brady/kines/ia
2. Label the word components: **Brady** = P; **kines** = WR; **ia** = S
3. Define the word components: **Brady** = slow; **kines** = movement; **ia** = condition of
4. Create a final definition of the medical term:
The condition of slow movement

Fibromyalgia

1. Break down the medical term into word components:
Fibr/o/my/algia
2. Label the word components: **Fibr** = WR; **o** = CV; **my** = WR; **algia** = S
3. Define the word components: **Fibr** = fibrous connective

tissue; **my** = muscle; **algia** = pain

4. Create a final definition of the medical term: **Pain in the fibrous connective tissue of muscles**

Rhabdomyolysis

1. Break down the medical term into word components:
Rhabd/o/my/o/lysis
2. Label the word components: **Rhabd** = WR; **o** = CV; **my** = WR; **o** = CV; **lysis** = S
3. Define the word components: **Rhabd** = striated (skeletal); **my** = muscle; **lysis** = dissolution
4. Create a final definition of the medical term: **Dissolution of striated skeletal muscle**



Interactive Learning Activity: Practice defining and pronouncing medical terms related to the muscular system by breaking them down into word parts.



An interactive H5P element has been excluded from this version of the text. You can view it online here:

<https://wtcs.pressbooks.pub/medterm/?p=4833#h5p-76>

- ▶ You can also print these flashcard activities as a [Chapter 14](#)

▶ [Student Companion Worksheet](#) and check your answers with this [Answer Key](#).

14.4 Anatomy of the Muscular System

There are three major types of muscle tissue categorized as smooth, cardiac, and skeletal muscle. See Figure 14.1¹ for an illustration of these three types of muscle. Cardiac and skeletal muscles are **striated** (STRĪ-ā-těd), meaning they contain functional units called sarcomeres. Sarcomeres are composed of two protein filaments called **actin** (ĀK-tin)² and **myosin** (MĪ-ō-sin) that are responsible for muscular contraction.

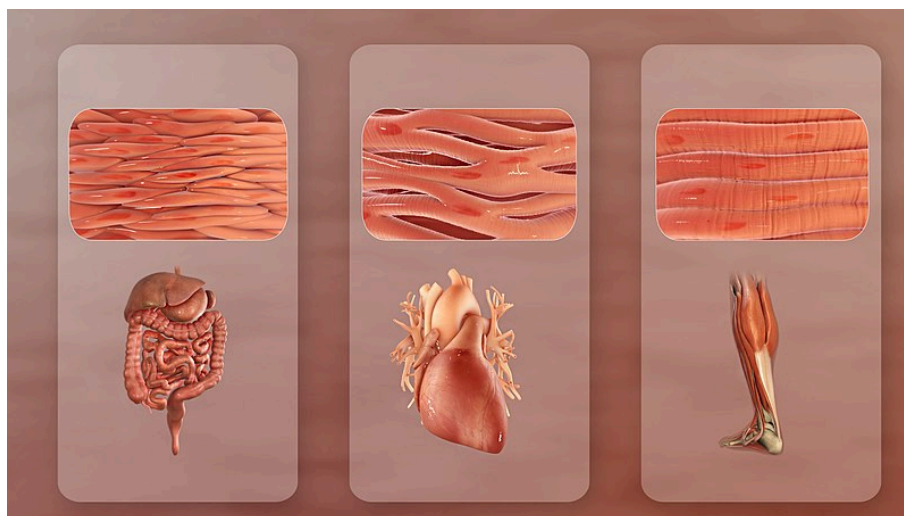


Figure 14.1 Muscle Types a) Smooth Muscle b) Cardiac Muscle c) Skeletal Muscle

1. “Types_Of_Muscle.jpg” by www.scientificanimations.com is licensed under [CC BY-SA 4.0](https://creativecommons.org/licenses/by-sa/4.0/)
2. This work is a derivative of [Anatomy and Physiology](https://openstax.org/books/anatomy-and-physiology) by [OpenStax](https://openstax.org) licensed under [CC BY 4.0](https://creativecommons.org/licenses/by/4.0/). Access for free at <https://openstax.org/books/anatomy-and-physiology/pages/1-introduction>

SMOOTH MUSCLE

Smooth muscle (SMŎŎTH MŬS-ăl) is responsible for involuntary muscle movement. Smooth muscle is present in the following areas³:

- Walls of hollow organs, like the urinary bladder, uterus, stomach, and intestines, where muscle contractions cause the movement of fluids and other substances
- Walls of passageways, such as the arteries and veins of the circulatory system, where it causes vasodilation and vasoconstriction
- Tracts of the respiratory, urinary, and reproductive systems, where contraction and relaxation affect the movement of air, urine, and reproductive fluids
- Eyes, where it functions to change the size of the pupil
- Skin, where it causes hair to stand erect in response to cold temperature or fear, commonly called goose bumps

CARDIAC MUSCLE

Cardiac muscle (KÄR-dē-ăk MŬS-ăl) is only found in the heart. Highly coordinated contractions of cardiac muscle pump blood throughout the circulatory system. Cardiac muscle fiber cells are extensively branched and connected to one another at their ends to allow the heart to contract in a wavelike pattern and work as a pump.⁴

3. This work is a derivative of Anatomy & Physiology by [OpenStax](#) and is licensed under [CC BY 4.0](#). Access for free at <https://openstax.org/details/books/anatomy-and-physiology-2e>

4. This work is a derivative of [Anatomy and Physiology](#) by [OpenStax](#) licensed

SKELETAL MUSCLE

Skeletal muscles (SKĚL-ě-tăl MŮS-ălz) are located throughout the body. They are under voluntary control and primarily produce movement of the arms, legs, back, and neck and maintain posture by resisting gravity. Small, constant adjustments of the skeletal muscles are needed to hold the body upright or balanced in any position.⁵

Skeletal muscles also have several additional functions. Ring-shaped skeletal muscles called sphincters are located throughout the body at the openings of internal tracts to control the movement of substances. These skeletal muscles allow voluntary control of functions such as swallowing, defecation, and urination in the digestive and urinary systems.⁶

Skeletal muscles, such as the rectus abdominus, protect internal organs (particularly abdominal and pelvic organs) by acting as an external barrier against trauma and supporting the weight of the organs.⁷

Skeletal muscles also contribute to maintaining homeostasis by generating heat. This heat generation is very noticeable during exercise, when sustained muscle movement causes a person's body temperature to rise, or conversely

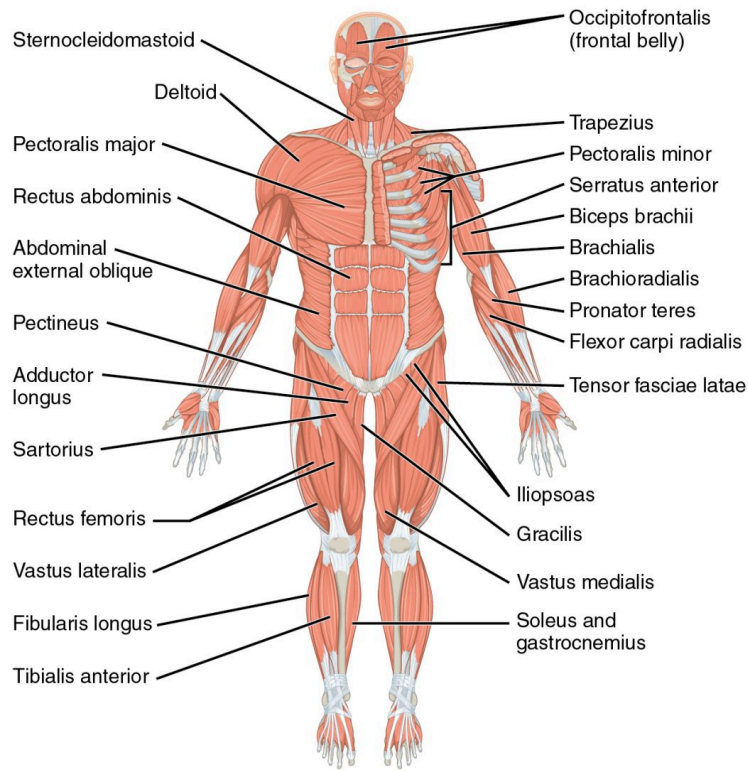
under [CC BY 4.0](https://openstax.org/books/anatomy-and-physiology/pages/1-introduction). Access for free at <https://openstax.org/books/anatomy-and-physiology/pages/1-introduction>

5. This work is a derivative of [Anatomy and Physiology](https://openstax.org/books/anatomy-and-physiology/pages/1-introduction) by [OpenStax](https://openstax.org/books/anatomy-and-physiology/pages/1-introduction) licensed under [CC BY 4.0](https://openstax.org/books/anatomy-and-physiology/pages/1-introduction). Access for free at <https://openstax.org/books/anatomy-and-physiology/pages/1-introduction>
6. This work is a derivative of [Anatomy and Physiology](https://openstax.org/books/anatomy-and-physiology/pages/1-introduction) by [OpenStax](https://openstax.org/books/anatomy-and-physiology/pages/1-introduction) licensed under [CC BY 4.0](https://openstax.org/books/anatomy-and-physiology/pages/1-introduction). Access for free at <https://openstax.org/books/anatomy-and-physiology/pages/1-introduction>
7. This work is a derivative of [Anatomy and Physiology](https://openstax.org/books/anatomy-and-physiology/pages/1-introduction) by [OpenStax](https://openstax.org/books/anatomy-and-physiology/pages/1-introduction) licensed under [CC BY 4.0](https://openstax.org/books/anatomy-and-physiology/pages/1-introduction). Access for free at <https://openstax.org/books/anatomy-and-physiology/pages/1-introduction>

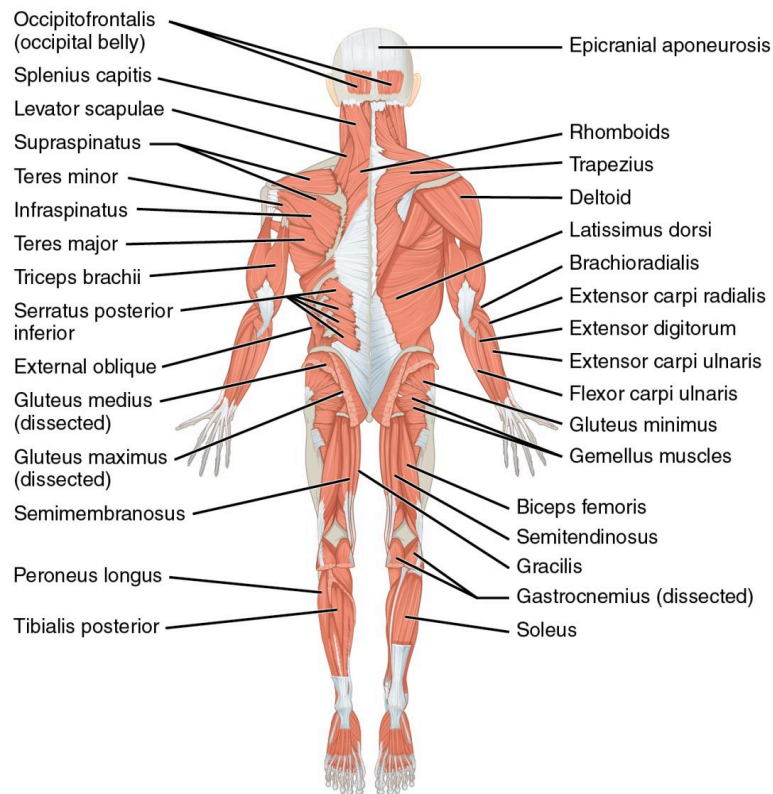
during cold environmental temperatures when shivering produces random skeletal muscle contractions to generate heat.⁸

See Figure 14.2⁹ for an illustration of the major skeletal muscles of the body. For the anterior and posterior views in this figure, superficial muscles are shown on the right side of the body, and deep muscles are shown on the left side of the body. For the legs, superficial muscles are shown in the anterior view while the posterior view shows both superficial and deep muscles.¹⁰

8. This work is a derivative of [Anatomy and Physiology](#) by [OpenStax](#) licensed under [CC BY 4.0](#). Access for free at <https://openstax.org/books/anatomy-and-physiology/pages/1-introduction>
9. "[1105_Anterior_and_Posterior_Views_of_Muscles.jpg](#)" by OpenStax is licensed under [CC BY 4.0](#)
10. This work is a derivative of [Anatomy and Physiology](#) by [OpenStax](#) licensed under [CC BY 4.0](#). Access for free at <https://openstax.org/books/anatomy-and-physiology/pages/1-introduction>



Major muscles of the body.
Right side: superficial; left side:
deep (anterior view)



Major muscles of the body.
Right side: superficial; left side:
deep (posterior view)

Figure 14.2 Muscular System

Muscles are named based on various characteristics, such as the following¹¹:

- **Body location:** The area of the body, for example, biceps, triceps, and quadriceps
- **Size:** The size of the muscle, such as maximus (largest) and minimus (smallest)
- **Shape:** The shape of the muscle, such as deltoid (triangular) or trapezius (trapezoid)
- **Action:** The action of the muscle, such as flexor (i.e., to flex) or adductor (i.e., towards midline of body)
- **Fiber direction:** The direction of the muscle fibers (such as external oblique)

Major Skeletal Muscles

Major skeletal muscles include the following¹²:

- **Biceps brachii** (BĪ-sěps bră-ki): Muscle on the anterior upper arm.
- **Biceps brachialis** (bră-kē-ĀL-īs): Muscle located in the upper and lower arm that flexes the elbow joint and rotates the forearm.
- **Deltoid** (DĒL-toid): A large triangular muscle covering the shoulder joint.
- **Gastrocnemius** (găs-trök-NĒ-mē-ūs): The chief muscle of the calf of the

11. This work is a derivative of [Anatomy and Physiology](#) by [OpenStax](#) licensed under [CC BY 4.0](#). Access for free at <https://openstax.org/books/anatomy-and-physiology/pages/1-introduction>

12. This work is a derivative of [Anatomy and Physiology](#) by [OpenStax](#) licensed under [CC BY 4.0](#). Access for free at <https://openstax.org/books/anatomy-and-physiology/pages/1-introduction>

leg.

- **Gluteus maximus** (glŪ-tē-ŭs MÄK-sĭ-mŭs): The largest and outermost of the three gluteal muscles in the buttocks.
- **Latissimus dorsi** (lă-tĭs-ĭ-mŭs DŌR-sĭ): A large muscle in the back.
- **Pectoralis major** (pĕk-tŏr-ÄL-ĭs MÄ-jŏr): A thick, fan-shaped muscle situated on the chest.
- **Quadriceps** (kwŎD-rĭ-sĕps): A large muscle group on the front of the thigh.
- **Rectus abdominis** (RĚK-tŭs äb-DŎM-ĭ-nĭs): A paired muscle running vertically on each side of the anterior wall of the abdomen.
- **Triceps brachii** (TRĭ-sĕps bră-ki): Muscle on the posterior of the upper arm.

TENDONS

Muscles attach to bones via **tendons** (TĚN-dŏnz). A tendon is a flexible but inelastic cord of strong fibrous collagen tissue. For example, consider the Achilles tendon, hamstring, and rotator cuff. The **Achilles tendon** (ə-KĪL-ēz TĚN-dŏn) attaches the calf muscles to the heel bone. The **hamstring** (HÄM-strĭng) tendons refer to five tendons at the back of a person's knee that connect a group of three hamstring muscles to bones in the pelvis, knee, and lower leg. The **rotator cuff** (rŏ-TÄ-tŏr KŬF) is a group of muscles and tendons that stabilize the shoulder.¹³ See Figure 14.3¹⁴ for an illustration of the tendon that attaches the quadriceps muscle to the top of the patella.

13. This work is a derivative of [Anatomy and Physiology](#) by [OpenStax](#) licensed under [CC BY 4.0](#). Access for free at <https://openstax.org/books/anatomy-and-physiology/pages/1-introduction>

14. "[Quadriceps tendon.svg](#)" by InjuryMap is licensed under [CC BY-SA 4.0](#)

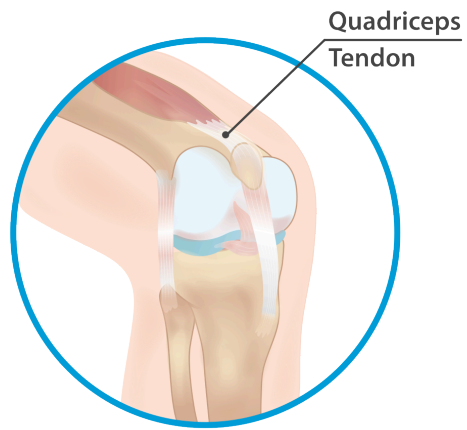


Figure 14.3 Tendon

14.5 Physiology of the Muscular System

The main function of the muscular system is movement. Muscles work as antagonistic (opposing) pairs. As one muscle contracts, another muscle relaxes. This contraction pulls on the bones and assists with movement. Contraction is the shortening of muscle fibers whereas relaxation is the lengthening of fibers. This sequence of relaxation and contraction is stimulated by the nervous system.¹

There are many types of actions that are caused by the contraction and relaxation of muscles, such as flexion, extension, abduction, adduction, rotation, dorsiflexion, plantar flexion, supination, and pronation. These muscle actions are summarized in Table 14.5. See Figures 14.4² and 14.5³ for illustrations of these movements.

Table 14.5 Muscle Actions

1. This work is a derivative of [Anatomy and Physiology](#) by [OpenStax](#) licensed under [CC BY 4.0](#). Access for free at <https://openstax.org/books/anatomy-and-physiology/pages/1-introduction>
2. "[Body_Movements_I.jpg](#)" by Tonye Ogele CNX is licensed under [CC BY-SA 3.0](#)
3. "[Body_Movements_II.jpg](#)" by Tonye Ogele CNX is licensed under [CC BY-SA 3.0](#)

Action	Description
Flexion (FLĚK-shǒn)	Movement that decreases the angle between two bones, such as bending the arm at the elbow.
Extension (ěk-STĚN-shǒn)	Movement that increases the angle between two bones, such as straightening the arm at the elbow.
Abduction (ăb-DŮK-shǒn)	Movement of a limb away from the midline of the body.
Adduction (ă-DŮK-shǒn)	Movement of a limb toward the midline of the body.
Rotation (rō-TĀ-shǒn)	Circular movement around a central point. Internal rotation is toward the center of the body, and external rotation is away from the center of the body.
Dorsiflexion (dôr-sĭ-FLĚK-shǒn)	Decreasing the angle of the foot and the leg (i.e., the foot moves upward toward the knee). This movement is the opposite of plantar flexion.
Plantar Flexion (PLĀN-tăř FLĚK-shǒn)	Increasing the angle of the foot and leg (i.e., the foot moves downward toward the ground, such as when pressing down on a gas pedal in a car).
Supination (sū-pi- NĀ-shŭn)	Movement of the hand or foot turning upward. When applied to the hand, it is the act of turning the palm upwards. When applied to the foot, it is the outward roll of the foot/ankle during normal movement.
Pronation (prō-NĀ-shŭn)	Movement of the hand or foot turning downward. When applied to the hand, it is the act of turning the palm downward. When applied to the foot, it is the inward roll of the foot/ankle during normal movement.
Eversion (ē-VĚR-zhŭn)	Excessive movement involving turning outward the sole of the foot away from the body's midline, a common cause of an ankle sprain.
Inversion (in-VĚR-zhŭn)	Excessive movement involving turning inward the sole of the foot towards the median plane, a common cause of an ankle sprain.

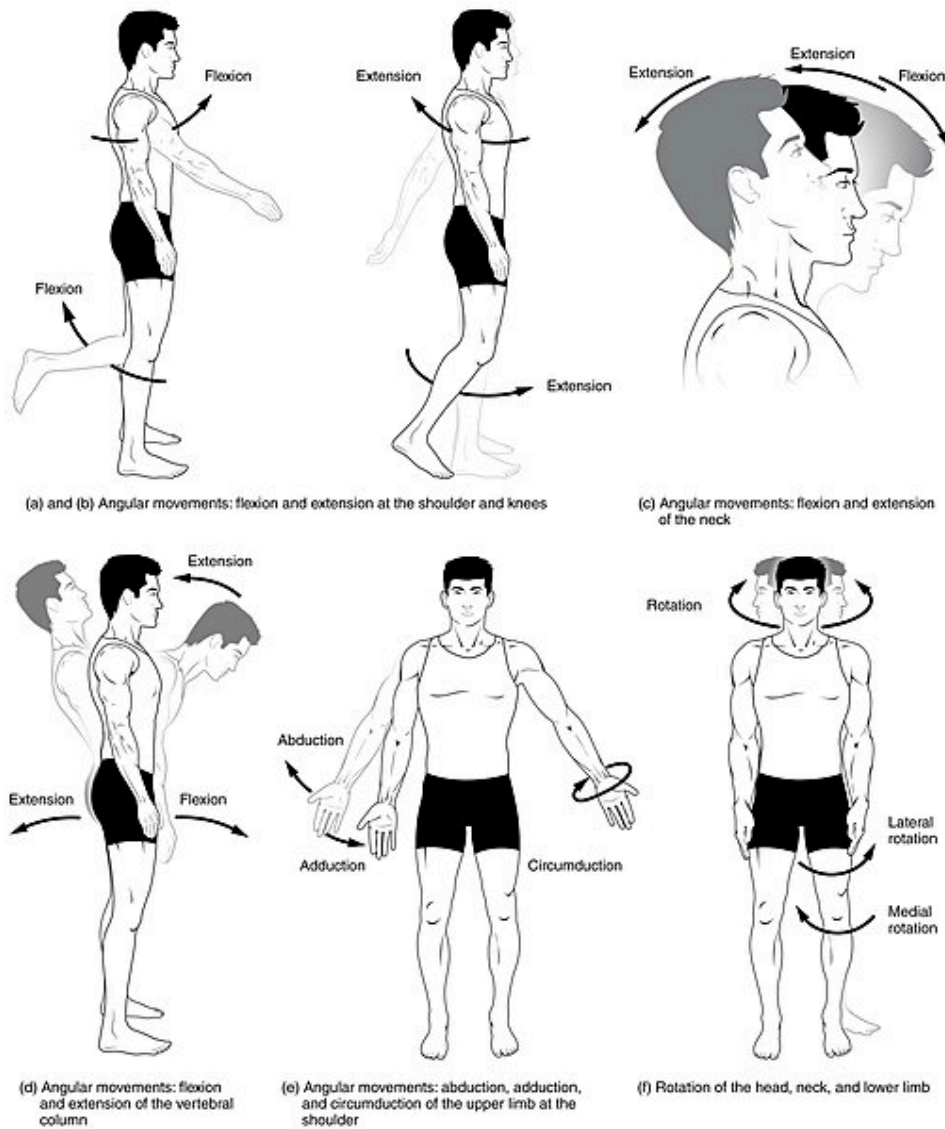


Figure 14.4 Flexion, Extension, Adduction, Abduction, Circumduction, and Rotation

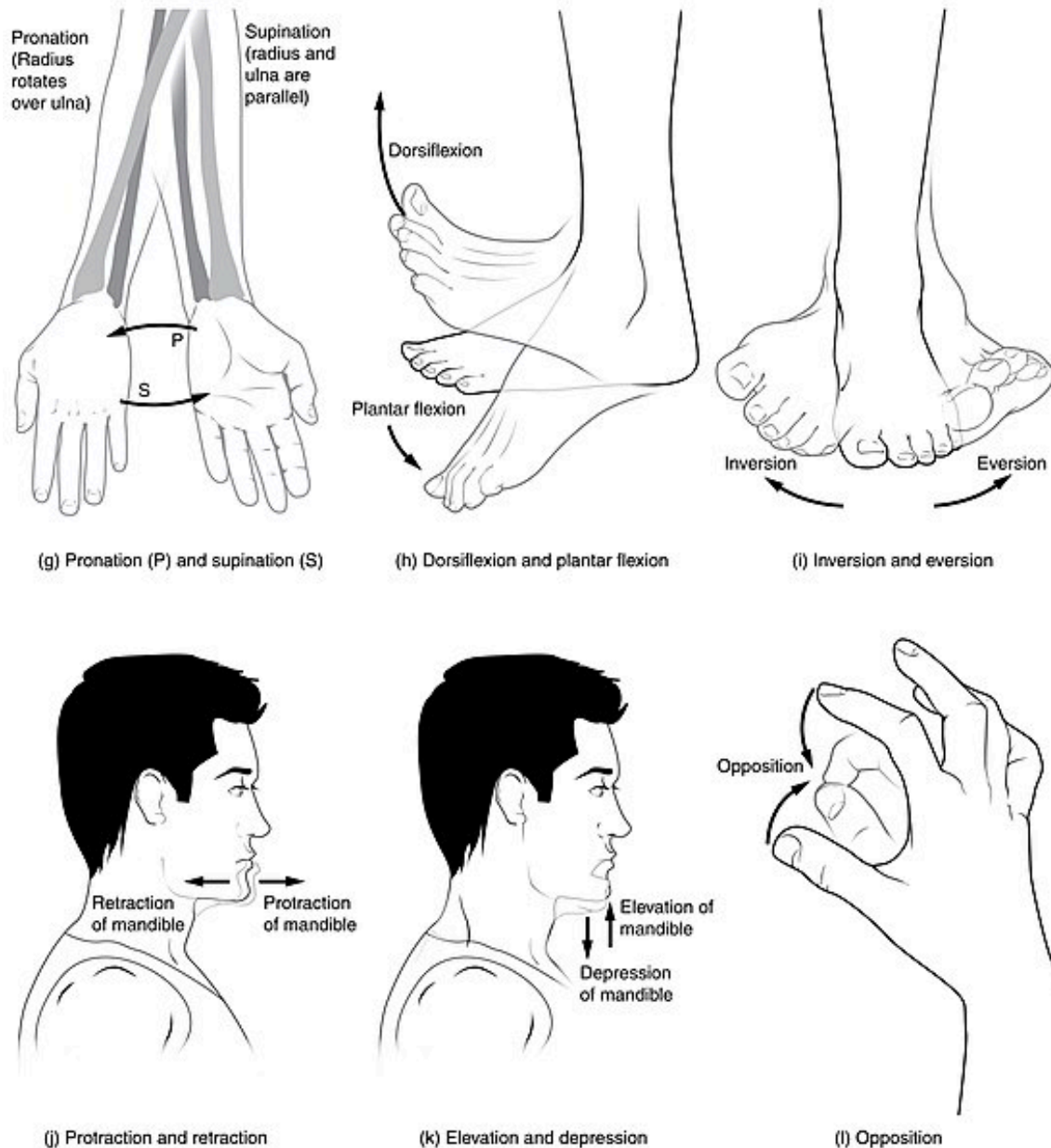


Figure 14.5 Pronation, Supination, Dorsiflexion, Plantar Flexion, Inversion, Eversion, Protraction, Retraction, Elevation, Depression, and Opposition



View a supplementary YouTube video⁴ demonstrating flexion and extension:



One or more interactive elements has been excluded from this version of the text. You can view them online here: <https://wtcs.pressbooks.pub/medterm/?p=420#oembed-1>



View a supplementary YouTube video⁵ demonstrating abduction and adduction:



One or more interactive elements has been excluded from this version of the text. You can view them online here: <https://wtcs.pressbooks.pub/medterm/?p=420#oembed-2>

4. RegisteredNurseRN. (2021, March 3). *Flexion and extension anatomy: Shoulder, hip, forearm, neck, leg, thumb, wrist, spine, finger* [Video]. YouTube. All rights reserved. Reused with permission.
<https://www.youtube.com/watch?v=p4xbehGmkmk>
5. RegisteredNurseRN. (2021, March 29). *Abduction and adduction of wrist, thigh, fingers, thumb, arm | Anatomy body movement terms* [Video]. YouTube. All rights reserved. Reused with permission.
<https://www.youtube.com/watch?v=qcxE9uql8g4>



View a supplementary YouTube video⁶ demonstrating eversion and inversion of the foot:



One or more interactive elements has been excluded from this version of the text. You can view them online here: <https://wtcs.pressbooks.pub/medterm/?p=420#oembed-3>



View a supplementary YouTube video⁷ demonstrating plantar flexion and dorsiflexion of the foot:



One or more interactive elements has been excluded from this version of the text. You can view them online here: <https://wtcs.pressbooks.pub/medterm/?p=420#oembed-4>

6. RegisteredNurseRN. (2021, January 11). *Inversion and eversion of the foot, ankle | Body movement terms anatomy* [Video]. YouTube. All rights reserved. Reused with permission. <https://www.youtube.com/watch?v=4HuxLWQykxk>
7. RegisteredNurseRN. (2020, December 29). *Dorsiflexion and plantar flexion of the foot | Anatomy body movement terms* [Video]. YouTube. All rights reserved. Reused with permission. <https://www.youtube.com/watch?v=e6WugOzgFIM>



View a supplementary YouTube video⁸ by Dr. Mike that summarizes joint movements: [Joint Movements](#)

Other terms related to the muscular system include the following:

- **Bradykinesia** (brăd-ē-kĭ-NĒ-sē-ă): Slow movement
- **Dyskinesia** (DIS-kĭ-NĒ-sē-ă): Difficult movement
- **Dystrophy** (DIS-trŏ-fē): Abnormal development
- **Hyperkinesia** (hĭ-pĕr-kĭ-NĒ-zh(ē-)ă): Excessive movement
- **Hypertrophy** (hĭ-PĚR-trŏ-fē): Excessive development
- **Myalgia** (mĭ-AL-j(ē-)ă): Painful muscles
- **Myasthenia** (mĭ-ăs-THĒ-nē-ă): Muscle weakness
- **Polymyositis** (pol-ē-mĭ-ŏ-SĪ-tĭs): Inflammation of many muscles

8. Dr Matt & Dr Mike. (2021, February 7). *Joint movements* [Video]. YouTube. All rights reserved. <https://www.youtube.com/watch?v=tAJjXvumL7E>

14.6 Diseases and Disorders of the Muscular System

This section will provide an overview of common diseases and disorders of the muscular system.

CEREBRAL PALSY

Cerebral palsy (sĕr-Ē-brăĭ pōl-zē) (**CP**) is a group of disorders that affects the ability to move and maintain balance and posture. CP is the most common motor disability in childhood. “Cerebral” means having to do with the brain, and “palsy” means weakness or problems with using the muscles. CP is caused by abnormal brain development or damage to the developing brain that affects the ability to control muscles.¹

The symptoms of CP vary from person to person. A person with severe CP might require the use of special equipment to walk or might not be able to walk at all and need lifelong care. A person with mild CP, on the other hand, might walk a little awkwardly, but otherwise not require specialized care. Doctors classify CP according to the main type of movement disorder involved. Depending on which areas of the brain are affected, one or more of the following movement disorders can occur:²

1. Centers for Disease Control and Prevention. (2023, October 6). *What is cerebral palsy?* <https://www.cdc.gov/ncbddd/cp/facts.html>
2. Centers for Disease Control and Prevention. (2023, October 6). *What is cerebral palsy?* <https://www.cdc.gov/ncbddd/cp/facts.html>

- **Spasticity** (spās-TĪS-ĭ-tē): Stiff muscles
- **Dyskinesia** (dĭs-kĭ-NĒ-zē-ă): Uncontrollable movements
- **Ataxia** (ă-TĂK-sē-ă): Poor balance and coordination

There is no cure for CP, but treatment can improve the quality of life for people who have the condition. After CP is diagnosed, a team of health professionals works with the child and family to develop a plan to help the child reach their optimal potential. Common treatments include medications; surgery; braces; and physical, occupational, and speech therapy.³

See Figure 14.6⁴ for an image of David Smith who has cerebral palsy and has won several Paralympian awards. Paralympians are athletes with a range of impairments who compete in the Paralympics, a competition similar to the Olympics. Paralympic athletes inspire people around the world with their performance and focus on moving forward and never giving up.⁵

3. Centers for Disease Control and Prevention. (2023, October 6). *What is cerebral palsy?* <https://www.cdc.gov/ncbddd/cp/facts.html>

4. “[David Smith and his Boccia medals \(cropped\).jpg](#)” by [Richard Gillin](#) from St Albans, UK is licensed under [CC BY-SA 2.0](#)

5. International Paralympic Committee. (n.d.). *FAQ*. <https://www.paralympic.org/frequently-asked-questions>



Figure 14.6 David Smith, a Paralympian With Cerebral Palsy

CONTRACTURE

A **contracture** (kŏn-TRÄK-chŭr) is a condition of shortening and hardening of muscles, tendons, or other tissue, often leading to deformity and rigidity of joints. Contractures are caused by immobility and can be the result of several disorders such as a stroke, cerebral palsy, or muscular dystrophy. Contractures may be prevented and/or treated with braces, physical therapy, and range-of-motion exercises. See Figure 14.7⁶ for an image of a hand contracture.

6. “[Freeman-Sheldon_syndrome.JPG](#)” by [MI Poling](#) at [English Wikipedia](#) is licensed under [CC BY-SA 2.5](#)

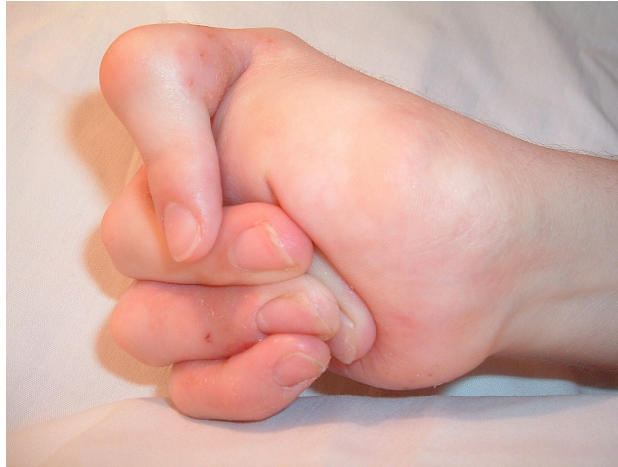

Figure 14.7 Hand Contracture

FIBROMYALGIA

Fibromyalgia (fī-brō-mī-AL-jē-ă) is defined as pain in muscle fibers. It is a condition that causes widespread pain, sleep problems, fatigue, and often emotional distress. Fibromyalgia affects about 2% of the adult population in the United States. The cause of fibromyalgia is not known, but it can be effectively treated and managed. Fibromyalgia is diagnosed by health care providers based on the patient's history, physical examination, X-rays, and blood work.⁷

Fibromyalgia is treated by a doctor or team of health care professionals who specialize in the treatment of fibromyalgia. A combination of treatments is typically prescribed, which may include the following⁸:

7. Centers for Disease Control and Prevention. (2020, January 6). *Fibromyalgia*. <https://www.cdc.gov/arthritis/basics/fibromyalgia.htm>

8. Centers for Disease Control and Prevention. (2020, January 6). *Fibromyalgia*. <https://www.cdc.gov/arthritis/basics/fibromyalgia.htm>

- Medications, including prescription drugs and over-the-counter pain relievers
- Aerobic exercise and muscle strengthening exercise
- Patient education classes
- Stress management techniques such as meditation, yoga, and massage
- Good sleep habits to improve the quality of sleep
- Cognitive behavioral therapy, a type of talk therapy that helps people change the way they think about their life circumstances

MUSCULAR DYSTROPHY

Muscular dystrophy (mŭs'kyŭ-lăř DĪS-trŏ-fē) (**MD**) refers to group of diseases caused by abnormal muscle development due to gene mutations. Muscular dystrophy can run in families, or a person can be the first in their family to have muscular dystrophy. Over time, muscle weakness decreases mobility and makes it difficult to perform everyday tasks. There are many types of muscular dystrophy, each affecting specific muscle groups. Each type has signs and symptoms that appear at different ages and vary in severity.⁹

An example of one type of MD is Duchenne muscular dystrophy (DMD), a genetic disorder characterized by progressive muscle degeneration and weakness due to the alterations of a muscle protein called dystrophin. DMD symptom onset is in early childhood, usually between the ages 2 and 3. The disease primarily affects boys. Muscle weakness is the principal symptom of DMD and begins by first affecting the proximal muscles (those closest to the core of the body) and later affecting the distal limb muscles. The child with DMD might have difficulty jumping, running, and walking. Other symptoms

9. Centers for Disease Control and Prevention. (2022, November 21). *What is muscular dystrophy?* <https://www.cdc.gov/ncbddd/musculardystrophy/facts.html>

include enlargement of the calves, a waddling gait, and lumbar lordosis (an inward curve of the spine). The heart and respiratory muscles are affected as well. Progressive weakness and scoliosis result in impaired pulmonary function, which can eventually cause acute respiratory failure. Treatment of DMD requires multidisciplinary care to coordinate specialized assessments and interventions needed to maximize function and quality of life. Due to recent advances in cardiology and pulmonology, people with DMD are living longer than ever and often well into adulthood.¹⁰

The impact of DMD can be significantly minimized by keeping the body as flexible, upright, and mobile as possible. As muscle deteriorates, a person with muscular dystrophy often develops contractures. If not treated, contractures can become severe, causing discomfort and restricting mobility and flexibility. Contractures can affect the knees, hips, feet, elbows, wrists, and fingers. However, there are many ways to minimize and postpone contractures. Range-of-motion exercises, performed on a regular schedule, help delay contractures by keeping tendons from shortening prematurely. Braces on the lower legs also can help keep the limbs stretched and flexible, delaying the onset of contractures. Eventually, a wheelchair is needed, typically by about age 12. Although a child and parents may dread using a wheelchair, many people find that when they start to use one, they are more mobile, energetic, and independent than when trying to walk without assistance.¹¹ See Figure 14.8¹² for an image of child with MD using a specialized wheelchair called an “Easy Stand” that supports him while sitting and also allows him to stand for periods of time.

¹⁰. Muscular Dystrophy Association. (n.d.). *Duchenne muscular dystrophy*.
<https://www.mda.org/disease/duchenne-muscular-dystrophy>

¹¹. Muscular Dystrophy Association. (n.d.). *Duchenne muscular dystrophy*.
<https://www.mda.org/disease/duchenne-muscular-dystrophy>

¹². “3576255511_4c36222845_b.jpg” by EasyStand is licensed under [CC BY-NC-ND 2.0](#)



Figure 14.8 Child With MD in an EasyStand Wheelchair

MYASTHENIA GRAVIS

Myasthenia gravis (mī-ās-THĒ-nē-ă GRĂ-vīs) (**MG**) is a chronic, autoimmune neuromuscular disease that causes weakness in voluntary muscles, including those required for breathing and swallowing. Onset of symptoms can be rapid and include the following¹³:

- **Myasthenia** (mī-ās-THĒ-nē-ă): Abnormal weakness of voluntary muscles
- **Ocular myasthenia** (Ō-kyŭ-lăr mī-ās-THĒ-nē-ă): Weakness of the eye muscles
- **Ptosis** (TŌ-sīs): Drooping of one or both eyelids (See Figure 14.9¹⁴ for an image of ptosis.)

13. National Institute of Neurological Disorders and Stroke. (2023, November). *Myasthenia gravis*. National Institutes of Health. <https://www.ninds.nih.gov/health-information/disorders/myasthenia-gravis>

- **Diplopia** (dĭ-PLŌ-pē-ă): Blurred or double vision
- **Dysphagia** (dĭs-FĀ-jē-ă): Difficulty swallowing
- **Dyspnea** (dĭsp-NĒ-ă): Shortness of breath
- **Dysarthria** (dĭs-ĀR-thrē-ă): Impaired speech

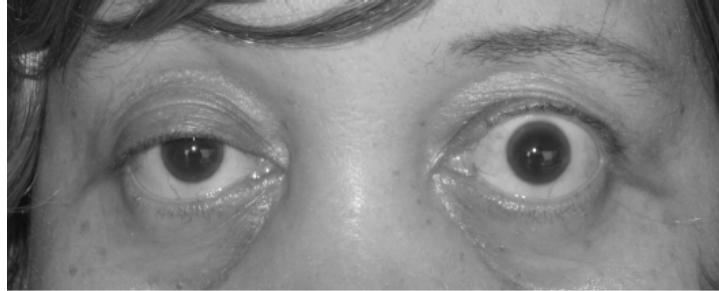

Figure 14.9 Ptosis Related to Myasthenia Gravis

Sometimes the muscles that control breathing weaken to the point where a person needs a ventilator to breathe. This is called a myasthenic crisis and requires immediate emergency medical care. A myasthenic crisis may be triggered by infection, stress, surgery, or an adverse reaction to medication.¹⁵

MG is diagnosed by health care providers based on a physical exam, blood tests, and electromyography (EMG). Read more about EMG in the “[Medical Specialists, Diagnostic Testing, and Procedures Related to the Muscular System](#)” section. MG is treated with medications that improve neuromuscular transmission and increase muscle strength. Immunosuppressive medications may be prescribed to impact the autoimmune response. In some cases, a

14. “[Ptosis_myasthenia_gravis.jpg](#)” by Mohankumar Kurukumbi, Roger L Weir, Janaki Kalyanam, Mansoor Nasim, Annapurni Jayam-Trouth is licensed under [CC BY 2.0](#)

15. National Institute of Neurological Disorders and Stroke. (2023, November). *Myasthenia gravis*. National Institutes of Health. <https://www.ninds.nih.gov/health-information/disorders/myasthenia-gravis>

thymectomy (i.e., removal of the thymus) may be performed to rebalance the immune system and decrease MG symptoms.¹⁶

PARALYSIS

Paralysis (păr-ă-LĪ-sīs) occurs when an injury or medical condition disrupts the nerve signals to the muscles, resulting in being unable to make voluntary movements. Common causes of paralysis include spinal cord injuries and strokes. Paralysis can be localized, where it affects specific areas of the body, such as the face. For example, Bell's palsy temporarily paralyzes facial muscles. Paralysis can also be generalized where it affects a larger area of the body. There are categories of generalized paralysis based on its extent. Common categories include hemiplegia, paraplegia, and quadriplegia/¹⁷tetraplegia

- **Hemiplegia** (hēm-ē-PLĒ-jē-ă): Paralysis affects one side of the body, for example, an arm and a leg on the same side.
- **Paraplegia** (păr-ă-PLĒ-jē-ă): Paralysis affects both legs and sometimes the torso.
- **Quadriplegia or Tetraplegia** (kwōd-rĭ-PLĒ-jē-ă or tēt-ră-PLĒ-jē-ă): Paralysis involves all limbs, with little or no movement from the neck down.

¹⁶. National Institute of Neurological Disorders and Stroke. (2023, November). *Myasthenia gravis*. National Institutes of Health. <https://www.ninds.nih.gov/health-information/disorders/myasthenia-gravis>

¹⁷. Cleveland Clinic. (2021, June 10). *Paralysis*. <https://my.clevelandclinic.org/health/diseases/15345-paralysis>

See Figure 14.10¹⁸ for an illustration of paraplegia, hemiplegia, and tetraplegia (quadriplegia), where pink indicates the area of muscle paralysis. Because muscle paralysis is caused by disruption of nerve signals, the cervical (C), thoracic (T), and lumbar (L) nerves are labelled in the image.

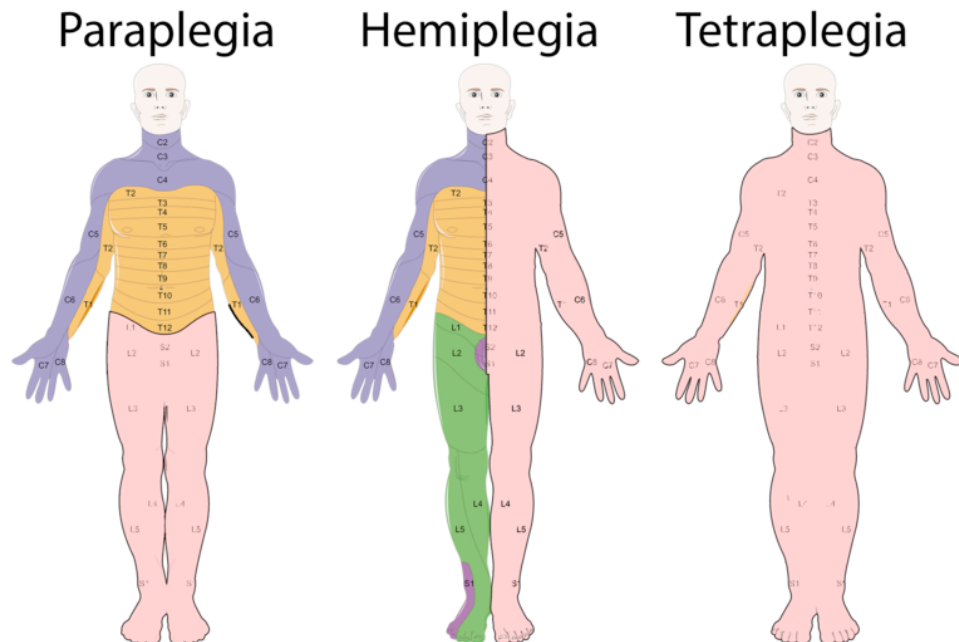


Figure 14.10 Paraplegia, Hemiplegia, and Tetraplegia (Quadriplegia)

Paralysis is also classified by its effect on muscles in terms of being flaccid or spastic¹⁹:

- **Flaccid** (FLĂS-ĭd): The muscles **atrophy** (ĂT-rŏ-fē) (i.e., shrink) due to loss of function.

18. “[Neurological Levels %26 Types of Paralysis.png](#)” by Servier Medical Art is licensed under [CC BY 2.0](#)

19. Cleveland Clinic. (2021, June 10). *Paralysis*. <https://my.clevelandclinic.org/health/diseases/15345-paralysis>

- **Spastic** (spās-TĪK): The muscles tighten, causing uncontrollable jerks and spasms.

There is no cure for permanent paralysis caused by spinal nerve damage because the spinal cord can't heal itself. However, rehabilitative services like physical and occupational therapy can help people with paralysis live independently and enjoy quality of life. Equipment used for rehabilitative/restorative care may include the following²⁰:

- **Adaptive equipment** (ă-DĂP-tiv ĭ-KWĪP-měnt): Equipment that allows people to feed themselves or drive.
- **Assistive equipment** (ă-SĪS-tiv ĭ-KWĪP-měnt): Equipment that enhances mobility, such as wheelchairs, scooters, crutches, and canes.
- **Orthotic/prosthetic devices** (ör-THÖT-ĭk/prös-THĚT-ĭk dĩ-VĪS-ěz): Devices that support the limbs and prevent contractures, such as braces.
- **Voice-activated technology** (vois-ăk-TĪV-ā-těd tĕk-NÖL-ö-jĕ): Technology that doesn't require the need for touch or movement, such as computers, lighting systems, and phones.

See Figure 14.11²¹ for an image of Mark Manion, founder of “Mark Speaks Out.” Mark was permanently disabled during a cross-country biking trip when he was struck by a drunk driver. He travels the country educating and inspiring audiences on how he has effectively coped with his life circumstances.

20. Cleveland Clinic. (2021, June 10). *Paralysis*. <https://my.clevelandclinic.org/health/diseases/15345-paralysis>

21. “[USMC-100519-M-3215R-002.jpg](#)” by unknown author for [United States Marine Corps](#) is licensed in the [Public Domain](#)



Figure 14.11 Mark Manion

RHABDOMYOLYSIS

Rhabdomyolysis (rab-dō-mī-OL-ĭ-sĭs) refers to the breakdown of muscles that causes damage to the kidney. When muscle is damaged, a protein called **myoglobin** (mī-Ō-glō-bĭn) is released into the bloodstream and is filtered out

of the body by the kidneys. Myoglobin breaks down into substances that damage kidney cells.²² See Figure 14.12²³ for an illustration of rhabdomyolysis.

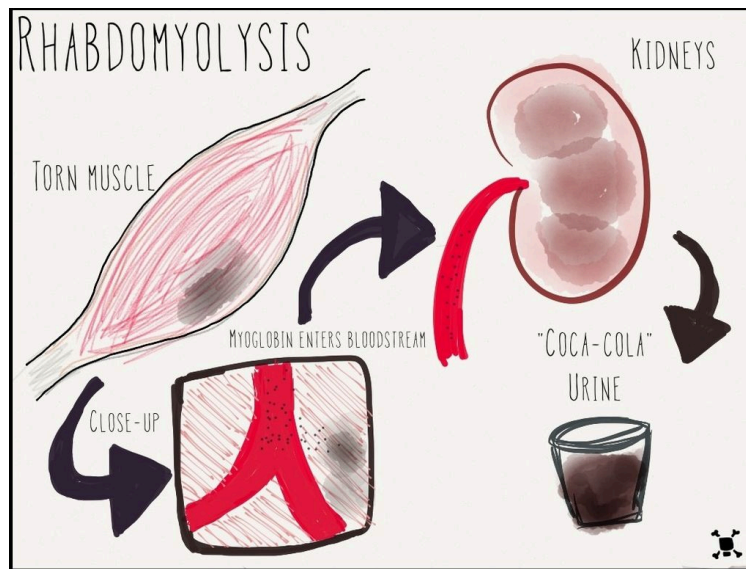


Figure 14.12 Rhabdomyolysis

Rhabdomyolysis may be caused by injury or any other condition that damages skeletal muscle. Potential causes of rhabdomyolysis include the following conditions²⁴:

- Trauma or crush injuries
- Use of drugs such as cocaine, amphetamines, statins, heroin, or

22. A.D.A.M. Medical Encyclopedia [Internet]. Atlanta (GA): A.D.A.M., Inc.; c1997-2023. Rhabdomyolysis; [reviewed 2021, Jul 27; cited 2023, Nov 28]. <https://medlineplus.gov/ency/article/000473.htm>

23. "Rhabdo.jpg" by AquapatMedia is licensed under [CC BY-SA 3.0](#)

24. A.D.A.M. Medical Encyclopedia [Internet]. Atlanta (GA): A.D.A.M., Inc.; c1997-2023. Rhabdomyolysis; [reviewed 2021, Jul 27; cited 2023, Nov 28]. <https://medlineplus.gov/ency/article/000473.htm>

phencyclidine (PCP)

- Genetic muscle diseases
- Extremes of body temperature
- Ischemia or death of muscle tissue
- Low phosphate levels
- Seizures or muscle tremors
- Severe exertion, such as marathon running or calisthenics
- Lengthy surgical procedures
- Severe dehydration

Symptoms of rhabdomyolysis include dark, red, or cola-colored urine; decreased urine output; weakness; and **myalgia** (mī-AL-jē-ă) (i.e., muscle pain). Rhabdomyolysis is diagnosed with blood tests, including creatine kinase (CK), myoglobin, and creatinine, as well as urine tests such as urinalysis and urine myoglobin. Rhabdomyolysis is treated with intravenous fluids that contain bicarbonate. In cases causing severe kidney damage, dialysis may be required.²⁵

STRAIN

A **strain** (strān) is an injury to a muscle or tendon from being overstretched or torn, causing pain. Strains can be caused by an injury, overusing a muscle, or using a muscle in the wrong way (such as twisting the back while lifting a heavy object). A strain is different from a **sprain** (sprān), which is an injury to a

25. A.D.A.M. Medical Encyclopedia [Internet]. Atlanta (GA): A.D.A.M., Inc.; c1997-2023. Rhabdomyolysis; [reviewed 2021, Jul 27; cited 2023, Nov 28]. <https://medlineplus.gov/ency/article/000473.htm>

joint when a ligament is stretched or torn. See Figure 14.13²⁶ for an illustration of a muscle strain and tear. Initial treatments for strains and sprains are similar and can be easily recalled by the mnemonic called RICE, which stands for the following²⁷:

- **Rest:** Rest the strain or sprain for at least 24 hours. The health care provider may recommend not putting any weight on the injured area for 48 to 72 hours, so crutches may be needed for lower extremity injuries.
- **Ice:** Apply ice as soon as possible after the injury to reduce swelling. The ice should not be applied directly to the skin but should be wrapped in a cloth to avoid tissue injury. Ice should be applied for 5 to 20 minutes, four to eight times a day, for the first 48 hours or until swelling improves.
- **Compression:** Compress the area with an elastic wrap or bandage to reduce swelling.
- **Elevate:** Elevate the injured limb above your heart whenever possible to help prevent or limit swelling.
-

26. "[Calf_muscle_strain_and_tear.svg](#)" by InjuryMap is licensed under [CC BY-SA 4.0](#)

27. Mayo Clinic. (2022, March 22). *Sprain: First aid*. <https://www.mayoclinic.org/first-aid/first-aid-sprain/basics/art-20056622>

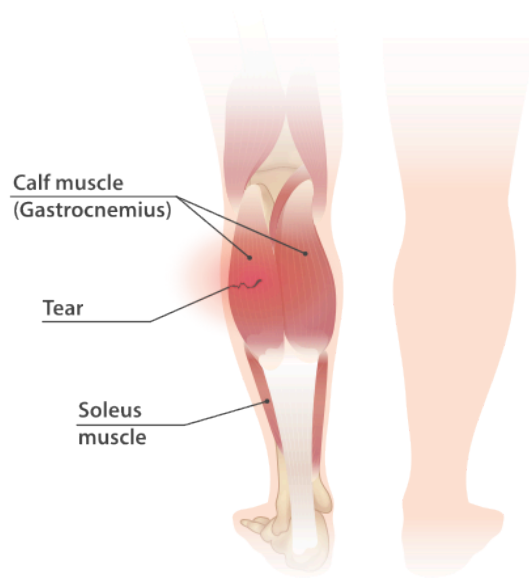


Figure 14.13 Strain

TENDONITIS

Tendonitis (ten-dŏ-NĪT-ĭs) refers to inflammation of a tendon, causing pain around a joint. Tendonitis usually happens after repeated injury to an area such as the wrist or ankle. Common forms of tendonitis are named after the sports that increase their risk, such as tennis elbow, golfer's elbow, pitcher's shoulder, swimmer's shoulder, and jumper's knee. Health care providers diagnose tendonitis based on medical history, a physical exam, and possible imaging tests. Initial treatment is focused on reducing pain and swelling with RICE (rest, ice, compression, and elevation). Other treatments may include ultrasound, physical therapy, steroid injections, and surgery in severe cases.²⁸

28. MedlinePlus [Internet]. Bethesda (MD): National Library of Medicine (US); [updated 2022, Apr. 4]. Tendinitis; [cited 2017, Mar. 16]. <https://medlineplus.gov/tendinitis.html>

14.7 Medical Specialists, Diagnostic Testing, and Procedures Related to Muscular System

MEDICAL SPECIALISTS

There are several types of health care professionals who help treat muscular disorders and diseases and help patients achieve optimal independence and quality of life.

Orthopedists and Orthopedic Surgeons

Orthopedists (ôr-THĒ-pě-dĭsts) are medical doctors who complete specialized training in the prevention, diagnosis, treatment, and surgery of disorders and diseases related to the musculoskeletal system. Some orthopedists are generalists, while others specialize in certain areas of the body, such as the hip and knee, foot and ankle, shoulder and elbow, hand, or spine. Orthopedic surgeons explore nonsurgical options first, such as pain medication or rehabilitation, but also have the expertise to perform surgery to repair an injury or correct a condition, if necessary. They treat patients of all ages, from newborns to the elderly, and treat conditions such as fractures, sports injuries, joint replacements, and spinal deformity.¹

1. American Academy of Orthopaedic Surgeons. (n.d.). *Orthopaedic surgeons:*

- ▶ For more details about orthopedists, see the [American Academy of Orthopaedic Surgeons' web page](#).

Neurologist

Neurologists (nū-rŎL-ŏ-jĭsts) are physicians who specialize in the diagnosis and treatment of disorders and conditions related to the brain, spinal cord, nerves, and muscles. They perform diagnostic testing related to the muscular system, such as electromyograms and muscle biopsies.²

- ▶ For additional information about neurologists, visit the [American Academy of Neurology's web page](#).

Kinesiologist

Kinesiology (kī-nē-sē-ŎL-ŏ-jē) is an academic discipline that studies physical activity and its impact on health and quality of life. It includes areas of study such as exercise science, sports management, athletic training, sports medicine, exercise psychology, fitness leadership, physical education, and pre-professional training for physical therapy, occupational therapy, medicine, and other health-related fields. **Kinesiologists** (kī-nē-sē-ŎL-ŏ-jĭsts) are health

Restoring mobility and keeping our nation in motion. <https://www.aaos.org/about/what-is-an-orthopaedic-surgeon>

2. American Academy of Neurology. (n.d.). *What is a neurologist?* <https://www.aan.com/tools-and-resources/medical-students/careers-in-neurology/what-is-a-neurologist>

care professionals with a degree in kinesiology or related discipline. Kinesiologists work in a variety of settings that assist people with pain management, injury prevention, and health promotion through biomechanics.³

- ▶ To read more information about kinesiologists, visit the [American Kinesiology Association's website](#). To learn more about careers in kinesiology, visit the [Zippia Kinesiologist Overview web page](#).

Occupational Therapists and Occupational Therapy Assistants

Occupational therapists (ŏk-yŭ-pā-shŏn-ăl THĚR-ă-pĭsts) (**OT**) and **occupational therapy assistants** (ŏk-yŭ-pā-shŏn-ăl THĚR-ă-pē ă-SĪS-tănts) (**OTA**) use everyday life activities (i.e., occupations) to promote health and well-being for people who have experienced an injury, disease, or condition that makes it difficult to participate in daily activities. This includes any meaningful activity that a person wants to accomplish, such as taking care of themselves and their family members, working, volunteering, or going to school. Occupational therapists work in a variety of settings, including hospitals, schools, clinics, skilled nursing facilities, community centers, health care facilities, and patient's homes.⁴

3. American Kinesiology Association. (n.d.) *About AKA*.
<https://americankinesiology.org>

4. American Occupational Therapy Association. (n.d.). *What is occupational therapy?* <https://www.aota.org/about/what-is-ot>

Occupational therapy can help people participate in life activities and provide recommendations for the following⁵:

- Activities of daily living (such as bathing, dressing, and eating)
- Adaptive equipment (such as shower chairs or equipment to make daily tasks easier)
- Caregiver and family training
- Planning and making the most of daily routines
- Returning to work, school, and leisure activities
- Techniques to aid in memory, concentration, and executive functioning
- Fall prevention, home safety, and accessibility

To become an occupational therapist (OT), a master's degree in occupational therapy is required. To become an OTA, an associate's degree from an accredited OTA program is required and a state-administered national exam must be passed to obtain licensure or certification. OTs evaluate a patient, create an intervention plan to improve their ability to perform daily activities and reach their goals, and determine if outcomes are being met.

Occupational therapy assistants (OTAs) implement the intervention plan and help patients recover, improve, and maintain skills needed for daily living and working. To become an OTA, an associate's degree from an accredited OTA program is required.

- ▶ Read additional information about occupational therapy on the [American Occupational Therapy Association web page](https://www.aota.org/about/what-is-ot). Read more information about occupational therapy jobs on the Bureau of Labor Statistic's web pages on [Occupational Therapists](#) and [Occupational Therapy Assistants and Aides](#).

5. American Occupational Therapy Association. (n.d.). *What is occupational therapy?* <https://www.aota.org/about/what-is-ot>

Physical Therapists and Physical Therapist Assistants

Physical therapists (FĪZ-ĭ-căl THĔR-ă-pĭsts) (**PT**) are movement experts who improve a person's quality of life through prescribed exercise, hands-on care, and patient education. PTs examine a person and develop a treatment plan to improve their ability to move, reduce or manage pain, restore function, and prevent disability. They work with people of all ages and abilities and in a variety of settings. They help people rehabilitate from injuries, manage chronic conditions, avoid surgery and prescription drugs, and create healthy habits. To become a licensed PT in the United States, a Doctor of Physical Therapy degree must be earned from an accredited physical therapy education program and a state licensure exam must be passed.⁶

Physical therapist assistants (FĪZ-ĭ-căl THĔR-ă-pĭst ă-SĪS-tănts) (**PTA**) provide physical therapy services under the direction and supervision of a physical therapist. PTAs implement components of patient care, obtain data related to the treatments provided, and collaborate with the PT to modify care as necessary. To become an PTA, an associate degree from an accredited PTA program is required and a state-administered national exam must be passed to obtain licensure or certification.⁷

- ▶ To learn more about careers in physical therapy, visit the [American Physical Therapy Association](https://www.apta.org/your-career/careers-in-physical-therapy). Read more information about physical therapy jobs on the Bureau of Labor Statistic's web pages on [Physical Therapists](https://www.bls.gov/ooh/healthcare/physical-therapists.htm) and [Physical Therapist Assistants and Aides](https://www.bls.gov/ooh/healthcare/physical-therapist-assistants-aides.htm).

6. American Physical Therapy Association. (n.d.). *Careers in physical therapy*. <https://www.apta.org/your-career/careers-in-physical-therapy>

7. American Physical Therapy Association. (n.d.). *Careers in physical therapy*. <https://www.apta.org/your-career/careers-in-physical-therapy>

Chiropractors

Chiropractors (kī-RŎP-răk-tŏrs) evaluate and treat musculoskeletal and neurological systems, including muscles, ligaments, tendons, bones, and nerves. Chiropractors use spinal manipulations to relieve pain in joints and muscles. Modern chiropractors have also developed a variety of different therapies to address patients' needs and use a holistic approach that generally excludes drugs or surgery.⁸ Chiropractors must complete a Doctor of Chiropractic (DC) degree to obtain a license to practice. They mostly work in solo or group chiropractic offices.

- ▶ Read more information about the chiropractic profession at the [American Chiropractic Association](#). Additional information about chiropractor jobs is available on the Bureau of Labor Statistic's web page on [chiropractors](#).

Massage Therapists

Massage therapists (MĂ-sāj THĚR-ă-pĭsts) treat patients by applying pressure to manipulate the body's soft tissues and joints. Licensed and/or certified massage therapists typically complete a postsecondary education that combines study and experience, although standards and requirements vary by state regulations.

- ▶ Read more information about massage therapy jobs on the Bureau of Labor Statistic's web page on [Massage Therapists](#).

8. American Chiropractic Association. (n.d.). *Origins and history of chiropractic*. <https://www.acatoday.org/about/history-of-chiropractic>

DIAGNOSTIC TESTING

Common diagnostic tests for muscular disorders include electromyograms, magnetic resonance imaging (MRI), and range-of-motion testing.

Electromyogram

An **electromyogram** (ē-lĕk-trō-mī-Ō-grām) (**EMG**) is a diagnostic procedure that assesses the function of nerve cells that control muscles. Electrodes, either attached to the skin or inserted into the muscle, record electrical impulses. An EMG can identify functional problems with the peripheral nerves, muscles, or with the signals between the nerves and the muscles. During a needle EMG, a needle electrode inserted directly into a muscle records the electrical activity in that muscle. A nerve conduction study, another part of an EMG, uses surface electrodes applied to the skin to measure the speed and strength of signals traveling between two or more points. EMG results are used to diagnose muscle and nerve disorders.⁹ See Figure 14.14¹⁰ for an image demonstrating the basics of an EMG.

9. Mayo Clinic. (2019, May 21). *Electromyography (EMG)*.

<https://www.mayoclinic.org/tests-procedures/emg/about/pac-20393913>

10. “Electromyography.png” by PRATYUSH AGRAWAL is licensed under [CC BY-SA 4.0](#)

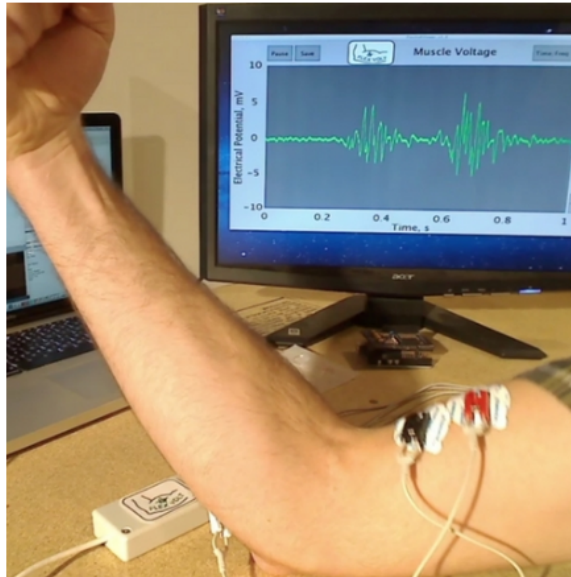


Figure 14.14 Electromyography

Magnetic Resonance Imaging

Magnetic resonance imaging (măg-NĚT-ĭk rĕz-ŏ-năns ĬM-ă-jĭng) (**MRI**) uses radio frequency waves and a strong magnetic field to produce three-dimensional, detailed anatomical images. MRIs are often used for diagnosis and monitoring of muscular and neurological disorders. To obtain an MRI image, a patient is placed inside a large magnet and must remain very still during the imaging process in order not to blur the image. Contrast agents may be intravenously administered to a patient before or during the MRI to enhance the image. MRIs differ from computed tomography (CT) in that they do not use the ionizing radiation of X-rays. The brain, spinal cord and nerves, muscles, ligaments, and tendons are seen much more clearly with MRI than with regular X-rays and CT. For this reason, an MRI is often used to image knee and shoulder injuries. However, people with metal implants, such as pacemakers, vagus nerve stimulators, implantable cardioverter-defibrillators, loop recorders, insulin pumps, cochlear implants, deep brain stimulators, and

capsules from capsule endoscopy, should not enter an MRI machine.¹¹ See Figure 14.15¹² for an image of an MRI machine.

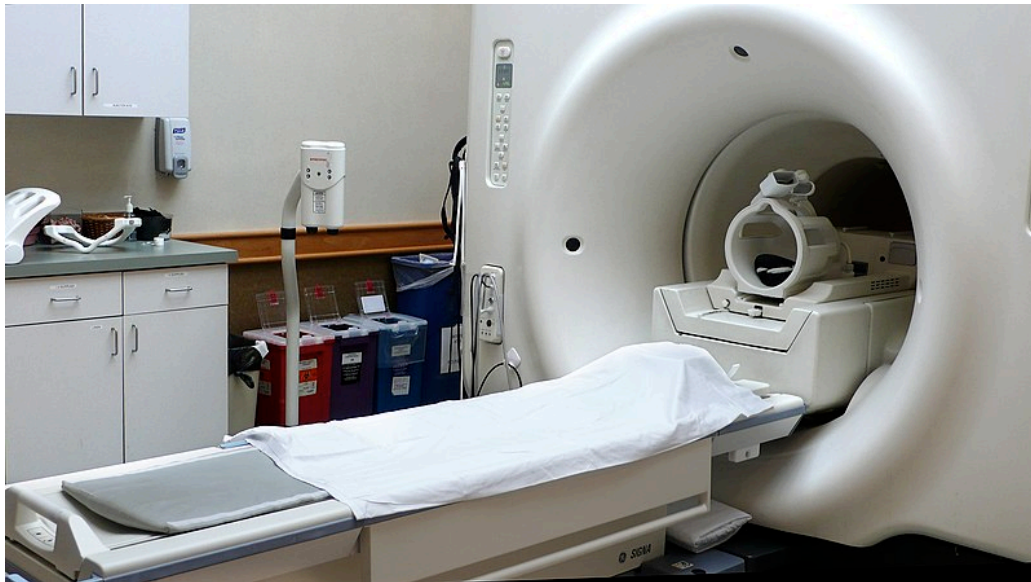

Figure 14.15 Magnetic Resonance Imaging (MRI) Machine

Range of Motion

Range-of-motion testing (rānj ōv mō-shōn tēs-tīng) (**ROM**) is a diagnostic procedure performed by a trained health care professional that is used to determine the amount of movement around a patient's specific joint. See

11. National Institute of Biomedical Imaging and Bioengineering. (n.d.). *Magnetic resonance imaging (MRI)*. National Institutes of Health.
<https://www.nibib.nih.gov/science-education/science-topics/magnetic-resonance-imaging-mri>

12. "Scan_MRI.jpg" by [liz west](#) from Boxborough, MA is licensed under [CC BY 2.0](#)

Figure 14.16¹³ for an image of a child undergoing range-of-motion testing of the shoulder.



Figure 14.16 Range-of-Motion Testing of the Shoulder

ROM exercises are used to treat musculoskeletal disorders and prevent contractures. **Active range of motion** (ăk-tīv rānj ōv mō-shŏn) (**AROM**) refers to joint movements the person can independently achieve when their

13. "[New Horizons 2012 in Peru 120621-F-HI762-602.jpg](#)" by Master Sgt. Kelly Ogden, United States Air Force is licensed in the [Public Domain](#)

opposing muscles contract and relax. **Passive range of motion** (pās-iv rānj ōv mō-shŏn) (**PROM**) refers to joint movements that occur when an outside force, such as a therapist, causes movement of a patient's joint.

PROCEDURES

Surgical procedures related to the muscular system include tenomyoplasty, tenorrhaphy, and myorrhaphy. **Tenomyoplasty** (tĕn-ō-Mĭ-ō-plās-tē) refers to surgical repair of a tendon and muscle. **Tenorrhaphy** (tĕn-OR-ă-fē) refers to suturing of a tendon. **Myorrhaphy** (mĭ-OR-ă-fē) refers to suturing of a muscle.

14.8 Muscular Learning Activities

Interactive Learning Activity: Study muscular system medical terms discussed in this chapter using these flashcards.



An interactive H5P element has been excluded from this version of the text. You can view it online here:

<https://wtcs.pressbooks.pub/medterm/?p=429#h5p-188>

Interactive Learning Activity: Test yourself on these terms related to the muscular system.



An interactive H5P element has been excluded from this version of the text. You can view it online here:

<https://wtcs.pressbooks.pub/medterm/?p=429#h5p-82>

14.9 Glossary

Abduction (ăb-DŮK-shŏn): The movement of a limb or other part away from the midline of the body or from another part. ([Chapter 14.5](#))

Achilles tendon (ə-KĪL-ēz TĚN-dŏn): A tendon of the back of the leg, and the thickest in the human body, attaching the calf muscles to the heel bone. ([Chapter 14.4](#))

Actin (ĂK-tin): A protein that forms (along with myosin) the contractile filaments of muscle cells and is involved in motion in other types of cells. ([Chapter 14.4](#))

Active range of motion (ăk-tĭv rānj ōv mō-shŏn) (AROM): The degree of movement a joint can be moved by a muscle contraction. ([Chapter 14.7](#))

Adaptive equipment (ă-DĂP-tĭv ĭ-KWĪP-mĕnt): Devices or tools used to assist individuals with disabilities in performing tasks and activities, aiming to enhance independence and functionality. ([Chapter 14.6](#))

Adduction (ă-DŮK-shŏn): The movement of a body part toward the body's midline. ([Chapter 14.5](#))

Assistive equipment (ă-SĪS-tĭv ĭ-KWĪP-mĕnt): Tools or devices that aid in performing daily tasks and activities, especially designed for people with disabilities, similar to adaptive equipment but may include a broader range of tools. ([Chapter 14.6](#))

Ataxia (ă-TĂK-sē-ă): The lack of muscle control or coordination of voluntary movements, such as walking or picking up objects. ([Chapter 14.6](#))

Atrophy (ĂT-rŏ-fē): The gradual wasting away, decrease in size, or degeneration of muscle or tissue. ([Chapter 14.6](#))

Biceps brachialis (BĪ-sĕps brā-kē-ĂL-ĭs): A muscle in the upper arm that acts to flex the elbow, situated underneath the biceps brachii. ([Chapter 14.4](#))

Biceps brachii (BĪ-sĕps BRĀ-kē-ĭ): A muscle of the upper arm that flexes the elbow and rotates the forearm. ([Chapter 14.4](#))

Bradykinesia (brād-ē-kĭ-NĒ-zē-ă): Slowness of movement, a common symptom of Parkinson's disease. ([Chapter 14.5](#))

Cardiac muscle (KĂR-dē-ăk MŪS-ăl): Specialized, involuntary muscle tissue

found only in the heart, responsible for pumping blood throughout the body. ([Chapter 14.4](#))

Cerebral palsy (sěr-Ē-brāl pôl-zē) (CP): A group of disorders affecting movement and muscle tone or posture caused by damage that occurs to the immature, developing brain, most often before birth. ([Chapter 14.6](#))

Chiropractors (kī-RŎP-rāk-tōrs): Health care professionals focused on the diagnosis and treatment of neuromuscular disorders, with an emphasis on treatment through manual adjustment and/or manipulation of the spine. ([Chapter 14.7](#))

Contracture (kõn-TRĀK-chŭr): The permanent tightening of muscles, tendons, skin, and other tissues, leading to a decrease in flexibility and mobility. ([Chapter 14.6](#))

Deltoid (DĚL-toid): A large, triangular muscle covering the shoulder joint and responsible for lifting the arm away from the body. ([Chapter 14.4](#))

Diplopia (dĩ-PLŎ-pē-ă): Double vision. ([Chapter 14.6](#))

Dorsiflexion (dôr-sĩ-FLĚK-shõn): The backward flexion or bending of a hand or foot. ([Chapter 14.5](#))

Dysarthria (dĩs-ĀR-thrē-ă): Slurred or slow speech that can be difficult to understand. ([Chapter 14.6](#))

Dyskinesia (dĩs-kĩ-NĚ-zē-ă): Abnormality or impairment of voluntary movement. ([Chapter 14.5](#), [Chapter 14.6](#))

Dysphagia (dĩs-FĀ-jē-ă): Difficulty or discomfort in swallowing. ([Chapter 14.6](#))

Dyspnea (dĩsp-NĚ-ă): Difficult or labored breathing. ([Chapter 14.6](#))

Dystrophy (DĪS-trŏ-fē): A disorder in which an organ or tissue of the body wastes away. ([Chapter 14.5](#))

Electromyogram (ĩ-lĚk-trŏ-mĩ-Ŏ-grām) (EMG): A diagnostic test that measures the electrical activity of muscles. ([Chapter 14.7](#))

Eversion (ē-VĚR-zhŭn): The action of turning outward the sole of the foot away from the body's midline. ([Chapter 14.5](#))

Extension (Ěk-STĚN-shõn): A straightening movement that increases the angle between body parts. ([Chapter 14.5](#))

Fibromyalgia (fĩ-brŏ-mĩ-ĀL-jē-ă): A disorder characterized by widespread

musculoskeletal pain accompanied by fatigue, sleep, memory, and mood issues. ([Chapter 14.6](#))

Flaccid (FLĀS-ĭd): Lacking firmness, resilience, or muscle tone. ([Chapter 14.6](#))

Flexion (FLĚK-shŏn): The action of bending or the condition of being bent, especially the bending of a limb or joint. ([Chapter 14.5](#))

Gastrocnemius (găs-trŏk-NĒ-mē-ŭs): The major calf muscle, responsible for plantar flexing the foot at the ankle joint and flexing the leg at the knee joint. ([Chapter 14.4](#))

Gluteus maximus (glū-TĒ-ŭs MĀK-sĭ-mŭs): The largest and most superficial of the three gluteal muscles, responsible for movement of the hip and thigh. ([Chapter 14.4](#))

Hamstring (HĀM-strĭng): Any of the five tendons at the back of a person's knee. ([Chapter 14.4](#))

Hemiplegia (hĕm-ē-PLĒ-jē-ă): Paralysis of one side of the body. ([Chapter 14.6](#))

Hyperkinesia (hī-pĕr-kĭ-NĒ-zē-ă): Excessive movement; an abnormally high level of activity. ([Chapter 14.5](#))

Hypertrophy (hī-PĚR-trŏ-fĕ): The enlargement of an organ or tissue from the increase in size of its cells. ([Chapter 14.5](#))

Inversion (in-VĚR-zhŭn): The process of turning inward the sole of the foot towards the body's midline. ([Chapter 14.5](#))

Kinesiologists (kī-nē-sē-ŌL-ŏ-jĭsts): Specialists in the study of human movement. ([Chapter 14.7](#))

Kinesiology (kī-nē-sē-ŌL-ŏ-jĕ): The study of the mechanics of body movements. ([Chapter 14.7](#))

Latissimus dorsi (lă-tĭs'ĭ-mŭs DŌR-sĭ): A broad, flat muscle on the back that helps control movement of the shoulder. ([Chapter 14.4](#))

Magnetic resonance imaging (măg-NĚT-ĭk rĕz-ŏ-năns ĪM-ă-jĭng) (MRI): A medical imaging technique used to form pictures of the anatomy and the physiological processes of the body. ([Chapter 14.7](#))

Massage therapists (MĀ-sāj THĚR-ă-pĭsts): Professionals who practice manual manipulation of soft body tissues (muscle, connective tissue, tendons, and ligaments) to enhance a person's health and well-being. ([Chapter 14.7](#))

Muscular dystrophy (mŭs'kyŭ-lăř DĭS-trŏ-fē) (MD): A group of diseases that cause progressive weakness and loss of muscle mass. ([Chapter 14.6](#))

Myalgia (mī-ĀL-jē-ă): Pain in a muscle or group of muscles. ([Chapter 14.5](#), [Chapter 14.6](#))

Myasthenia (mī-ăs-THĒ-nē-ă): Muscle weakness. ([Chapter 14.5](#), [Chapter 14.6](#))

Myasthenia gravis (mī-ăs-THĒ-nē-ă GRĀ-vĭs) (MG): A chronic autoimmune neuromuscular disease that causes weakness in the skeletal muscles, which are responsible for breathing and moving parts of the body, including the arms and legs. ([Chapter 14.6](#))

Myoglobin (mī-Ō-glŏ-bĭn): A red protein containing heme that carries and stores oxygen in muscle cells. ([Chapter 14.6](#))

Myorrhaphy (mī-ŌR-ă-fē): The surgical suturing of a muscle. ([Chapter 14.7](#))

Myosin (Mĭ-ŏ-sin): A type of protein filament that interacts with actin in muscle contraction and is also involved in cellular transport. ([Chapter 14.4](#))

Neurologists (nŭ-rŌL-ŏ-jĭsts): Physicians who specialize in the treatment of diseases and disorders of the nervous system. ([Chapter 14.7](#))

Occupational therapists (ŏk-yŭ-pā-shŏn-ăl THĒR-ă-pĭsts) (OT): Health professionals who help people recover, develop, and maintain daily living and work skills. ([Chapter 14.7](#))

Occupational therapy assistants (ŏk-yŭ-pā-shŏn-ăl THĒR-ă-pē ă-SĭS-tănts) (OTA): Professionals who work under the direction of occupational therapists to assist patients in developing, recovering, and improving the skills needed for daily living and working. ([Chapter 14.7](#))

Ocular myasthenia (Ō-kyŭ-lăř mī-ăs-THĒ-nē-ă): A form of myasthenia gravis that primarily affects the muscles that control eye and eyelid movement. ([Chapter 14.6](#))

Orthopedists (ŏr-THĒ-pĕ-dĭsts): Medical doctors who specialize in the diagnosis, correction, prevention, and treatment of patients with skeletal deformities. ([Chapter 14.7](#))

Orthotic/prosthetic devices (ŏr-THŌT-ĭk/prŏs-THĒT-ĭk dĭ-VĭS-ĕz): Apparatuses used to support, align, prevent, or correct deformities, or to improve the function of movable parts of the body. Orthotic devices are

typically used to support weak or ineffective joints or muscles, whereas prosthetic devices replace missing body parts. ([Chapter 14.6](#))

Paralysis (pǎr-ă-LĪ-sīs): The loss of the ability to move (and sometimes to feel anything) in part or most of the body, typically as a result of illness, poison, or injury. ([Chapter 14.6](#))

Paraplegia (pǎr-ă-PLĒ-jē-ă): Paralysis of the legs and lower body, typically caused by spinal injury or disease. ([Chapter 14.6](#))

Passive range of motion (pās-iv rānj ōv mō-shǒn) (PROM): The extent of movement a joint can be moved by an external force without muscle contraction. ([Chapter 14.7](#))

Pectoralis major (pěk'tō-rĂ-līs MĀ-jör): A thick, fan-shaped muscle situated at the chest of the body, making up the bulk of the male chest. ([Chapter 14.4](#))

Physical therapists (FĪZ-ĭ-căl THĒR-ă-pĭsts) (PT): Healthcare professionals who provide services to individuals to develop, maintain, and restore maximum movement and functional ability throughout life. ([Chapter 14.7](#))

Physical therapist assistants (FĪZ-ĭ-căl THĒR-ă-pĭst ă-SĪS-tǎnts) (PTA): Skilled health care workers who work under the supervision of a physical therapist to provide therapy services. ([Chapter 14.7](#))

Plantar flexion (PLĂN-tăr FLĒK-shǒn): The movement of the foot in which the foot or toes flex downward toward the sole. ([Chapter 14.5](#))

Polymyositis (pöl-ē-mī-ō-SĪ-tīs): Inflammation of many muscles. ([Chapter 14.5](#))

Pronation (prō-NĀ-shŭn): The act of turning the palm downward or when applied to the foot, the inward roll of the foot/ankle. ([Chapter 14.5](#))

Ptosis (TŌ-sīs): Drooping of the upper eyelid due to paralysis or disease, or as a congenital condition. ([Chapter 14.6](#))

Quadriceps (KWŎD-rĭ-sěps): A large muscle group that includes the four prevailing muscles on the front of the thigh. ([Chapter 14.4](#))

Quadriplegia or tetraplegia (kwöd-rĭ-PLĒ-jē-ă or tět-ră-PLĒ-jē-ă): Paralysis of all four limbs; tetraplegia is another term for the same condition. ([Chapter 14.6](#))

Range-of-motion testing (rānj ōv mō-shǒn tēs-tĭng) (ROM): A procedure that measures the extent of movement in a particular joint. ([Chapter 14.7](#))

Rectus abdominis (RĚK-tŭs ăb-DŌM-ĭ-nīs): A paired muscle running

vertically on each side of the anterior wall of the human abdomen. ([Chapter 14.4](#))

Rhabdomyolysis (răb-dō-mī-ŎL-ĭ-sĭs): A serious syndrome due to a direct or indirect muscle injury, resulting from the death of muscle fibers and release of their contents into the bloodstream. ([Chapter 14.6](#))

Rotation (rō-TĀ-shŏn): Circular movement around a central point. Internal rotation is toward the center of the body, and external rotation is away from the center of the body. ([Chapter 14.5](#))

Rotator cuff (RŌ-tā-tŏr kŭf): A group of muscles and tendons surrounding the shoulder joint, keeping the head of the humerus firmly within the shallow socket of the shoulder. ([Chapter 14.4](#))

Skeletal muscles (SKĚL-ĕ-tăl MŬS-ălz): Voluntary muscles attached to the skeleton, responsible for movement, posture, and balance. ([Chapter 14.4](#))

Smooth muscle (SMŎŎTH MŬS-ăl): Involuntary, non-striated muscle that is found in the walls of internal organs such as the stomach, intestine, and blood vessels, controlling their movements. ([Chapter 14.4](#))

Spastic (spăs-TĪK): Relating to or affected by muscle spasm or increased reflexes. ([Chapter 14.6](#))

Spasticity (spăs-TĪS-ĭ-tē): A feature of altered skeletal muscle performance with a combination of paralysis, increased tendon reflex activity, and hypertonia. ([Chapter 14.6](#))

Sprain (sprān): An injury to ligaments caused by a wrench or twist, typically resulting in pain, swelling, and difficulty in movement. ([Chapter 14.6](#))

Strain (strān): An injury to a muscle or tendon in which the muscle fibers tear as a result of overstretching, often causing pain and inflammation. ([Chapter 14.6](#))

Striated (STRĪ-ā-tĕd): Muscle tissue characterized by the presence of striations, or alternating light and dark bands, typically found in skeletal and cardiac muscles. ([Chapter 14.4](#))

Supination (sū-pi-NĀ-shŭn): The act of turning the palm upwards or when applied to the foot, the outward roll of the foot/ankle. ([Chapter 14.5](#))

Tendonitis (tĕn-dŏ-NĪ-tĭs): Inflammation of a tendon, often causing pain and swelling. ([Chapter 14.6](#))

Tendons (TĔN-dŏns): Tough bands of fibrous connective tissue that usually

connect muscle to bone and are capable of withstanding tension. ([Chapter 14.4](#))

Tenomyoplasty (těn-ō-Mī-ō-plās-tē): A surgical procedure involving the repair of both muscle and tendon. ([Chapter 14.7](#))

Tenorrhaphy (těn-ŎR-ă-fē): The surgical suturing of a tendon. ([Chapter 14.7](#))

Triceps brachii (TRĪ-sěps BRĀ-kē-ī): A major muscle of the upper arm that extends the elbow. ([Chapter 14.4](#))

Voice-activated technology (vois-ăk-TĪV-ā-těd těk-NŎL-ŏ-jē): Technology that is controlled through voice commands rather than manual operation, often used to assist individuals with mobility or dexterity issues. ([Chapter 14.6](#))

PART XV

CHAPTER 15 SENSORY SYSTEM TERMINOLOGY

15.1 Sensory System Introduction

Learning Objectives

- Apply the rules of medical language to build, analyze, spell, pronounce, abbreviate, and define terms as they relate to the sensory system
- Identify meanings of key word components of the sensory system
- Categorize diagnostic, therapeutic, procedural, or anatomic terms related to the sensory system
- Use terms related to the sensory system
- Use terms related to the diseases and disorders of the sensory system

Introduction to the Sensory Systems

Most people consider the five major senses to be taste, smell, touch, hearing, and sight. These are referred to as the “special senses” because they have organs devoted to the senses, such as the eye, ear, tongue, and nose.

This chapter will review common word components related to the systems of special senses to assist learners in analyzing, building, and defining medical terms. Other terms, whose definitions cannot be easily built from word components, will be described in context based on the anatomy and physiology of sensory systems and common diseases and disorders. Medical

specialists, diagnostic tests, and procedures related to sensory systems will also be discussed.

15.2 Word Components Related to the Sensory Systems

This section will describe common word components related to the sensory systems. These word components help build definitions for many medical terms. Other common prefixes are described in [Chapter 1.3](#), and common suffixes are described in [Chapter 1.5](#).

PREFIXES RELATED TO THE SENSORY SYSTEMS

- **a-** or **an-**: Absence of, without, no, or not (negates meaning)
- **bi-**: Two
- **bin-**: Two
- **endo-**: Within, in

WORD ROOTS WITH A COMBINING VOWEL RELATED TO THE SENSORY SYSTEMS

- **acous/o**: Hearing

- **audi/o**: Hearing
- **audit/o**: Hearing
- **aur/i** or **aur/o**: Ear
- **blephar/o**: Eyelid
- **cochle/o**: Cochlea
- **conjunctiv/o**: Conjunctiva
- **cor/o**: Pupil
- **core/o**: Pupil
- **corne/o**: Cornea
- **cry/o**: Cold
- **cyst/o**: Bladder, sac, or cyst
- **dacry/o**: Tear, tear duct
- **dipl/o**: Two, double
- **ir/o**: Iris
- **irid/o**: Iris
- **is/o**: Equal
- **kerat/o**: Cornea
- **labyrinth/o**: Labyrinth, inner ear
- **lacrim/o**: Tear, tear duct
- **mastoid/o**: Mastoid bone
- **myring/o**: Tympanic membrane
- **ocul/o**: Eye
- **ophthalm/o**: Eye
- **opt/o**: Vision
- **ossicul/o**: Ossicle
- **ot/o**: Ear
- **phac/o**: Lens
- **phak/o**: Lens
- **phot/o**: Light
- **pupill/o**: Pupil
- **retin/o**: Retina
- **salping/o**: Tube
- **scler/o**: Sclera
- **staped/o**: Stapes, middle ear

- **ton/o**: Tension, pressure
- **tympan/o**: Middle ear, tympanic membrane
- **vestibul/o**: Vestibule
- **xer/o**: Dry

SUFFIXES RELATED TO THE SENSORY SYSTEMS

- **-al**: Pertaining to
- **-algia**: Pain
- **-ar**: Pertaining to
- **-ary**: Pertaining to
- **-eal**: Pertaining to
- **-ectomy**: Excision or surgical removal
- **-gram**: Record, radiographic image
- **-graphy**: Process of recording
- **-ia**: Condition of, diseased or abnormal state
- **-ic**: Pertaining to
- **-itis**: Inflammation
- **-logist**: Specialist who studies and treats
- **-logy**: Study of
- **-malacia**: Softening
- **-meter**: Instrument used to measure
- **-metry**: Process of measuring
- **-oma**: Tumor, swelling
- **-opia**: Vision as it relates to condition
- **-osis**: Abnormal condition
- **-pathy**: Disease
- **-pexy**: Surgical fixation
- **-phobia**: Abnormal fear, aversion to specific things
- **-plasty**: Surgical repair

- **-plegia**: Paralysis
- **-ptosis**: Prolapse, drooping, sagging
- **-rrhea**: Flow, discharge
- **-sclerosis**: Hardening
- **-scope**: Instrument used to view
- **-scopy**: Process of viewing
- **-stomy**: Creation of artificial opening
- **-tomy**: Incision, cut into

15.3 Examples of Sensory Terms Easily Defined By Their Word Components

Here are examples of common medical terms related to the sensory systems that can be easily defined by breaking the terms into their word components.

Audiologist

1. Break down the medical term into word components:
Audi/o/logist
2. Label the word components: **Audi** = WR; **o** = CV; **logist** = S
3. Define the word components: **Audi** = hearing; **logist** = physician who specializes in diagnosing and treating
4. Create a final definition of the medical term: **Specialist who diagnoses and treats hearing**

Ophthalmoscopy

1. Break down the medical term into word components:
Ophthalm/o/scopy
2. Label the word components: **Ophthalm** = WR; **o** = CV; **scopy** = S
3. Define the word components: **Ophthalm** = eye; **scopy**

= process of viewing

4. Create a final definition of the medical term: **Process of viewing the eye**

Tympanoplasty

1. Break down the medical term into word components:
Tympan/o/plasty
2. Label the word components: **Tympan** = WR; **o** = CV; **plasty** = S
3. Define the word components: **Tympan** = tympanic membrane; **plasty** = surgical repair
4. Create a final definition of the medical term: **Surgical repair of the tympanic membrane**



Interactive Learning Activity: Practice defining and pronouncing sensory system medical terms by breaking them into word parts.



An interactive H5P element has been excluded from this version of the text. You can view it online here:

<https://wtcs.pressbooks.pub/medterm/?p=6081#h5p-62>

- ▶ You can also print these flashcard activities as a [Chapter 15](#)

▶ [Student Companion Worksheet](#) and check your answers with this [Answer Key](#).

15.4 Anatomy and Physiology of the Sensory Systems

VISION

Vision is the special sense of sight based on the transduction of light stimuli received through the eyes. See Figure 15.1¹ for an illustration of the eye. The bony orbits surround the eyeballs, protecting them and anchoring the soft tissues of the eye. The eyelashes and eyelids help protect the eye by blocking particles from landing on the surface of the eye.²

1. "[1411_Eye_in_The_Orbit.jpg](#)" by OpenStax College is licensed under [CC BY 3.0](#)

2. This work is a derivative of Anatomy & Physiology by [OpenStax](#) and is licensed under [CC BY 4.0](#). Access for free at <https://openstax.org/details/books/anatomy-and-physiology-2e>

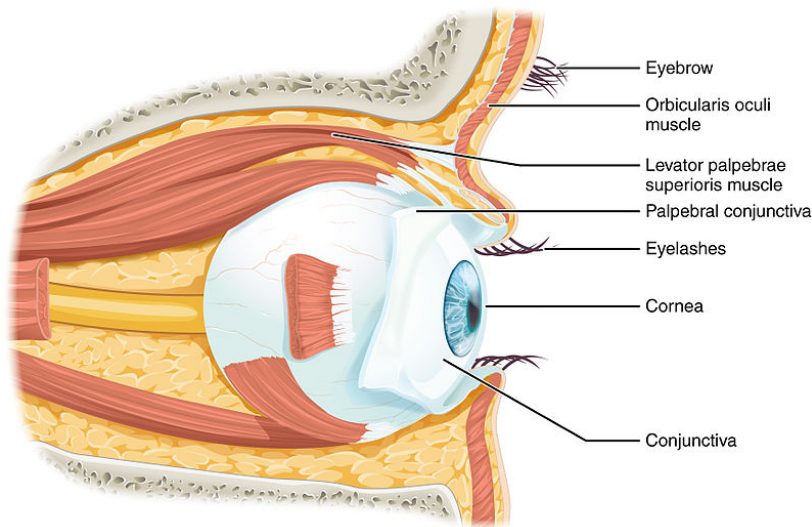


Figure 15.1 The Eye

The inner surface of each lid is a thin membrane known as the **conjunctiva** (kŏn-jŭnk-tī-va). The conjunctiva extends over the white areas of the eye called the **sclera** (sklĕr-ă), connecting the eyelids to the eyeball. The **iris** (ir-ĭs) is the colored part of the eye. The iris is a smooth muscle that opens and closes the **pupil** (pŭ-pĭl), the hole at the center of the eye that allows light to enter. The iris constricts the pupil in response to bright light and dilates the pupil in response to dim light. The **cornea** (KOR-nĕ-ă) is the transparent front part of the eye that covers the iris, pupil, and anterior chamber. The cornea, with the anterior chamber and lens, refracts light and contributes to vision. The innermost layer of the eye is the **retina** (RĕT-ĭ-nă). The retina contains the nervous tissue and specialized cells called photoreceptors for the initial processing of visual stimuli. These nerve cells of the retina leave the eye and enter the brain via the **optic nerve** (OP-tik nerve). See Figure 15.2³ for an illustration of these structures of the eye.⁴

3. "[1413_Structure_of_the_Eye.jpg]" by OpenStax College is licensed under [CC BY 3.0](#)

4. This work is a derivative of Anatomy & Physiology by [OpenStax](#) and is licensed

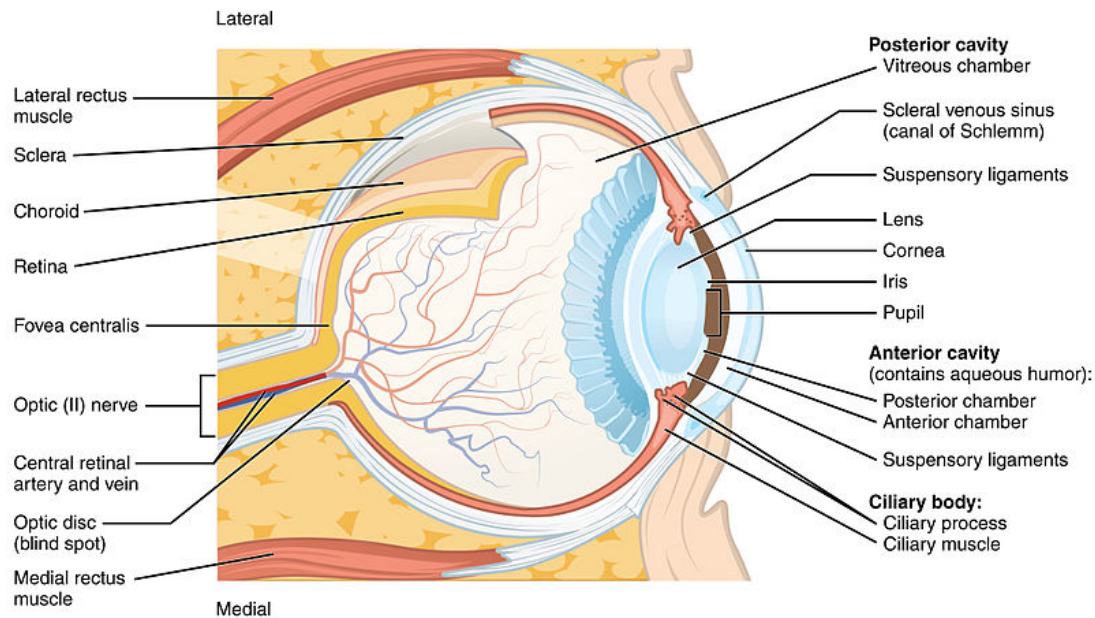


Figure 15.2 Structures of the Eye

Tears are produced by the **lacrimal gland** (LAK-rĭ-măl gland) that is located beneath the lateral edges of the nose. Tears are continuously produced by the lacrimal duct and secreted through a duct onto the surface of the eye to wash away foreign particles. Movement of the eye occurs by the contraction of six voluntary extraocular extrinsic muscles that originate from the bones of the orbit and insert into the surface of the eyeball.⁵

under [CC BY 4.0](https://openstax.org/details/books/anatomy-and-physiology-2e). Access for free at <https://openstax.org/details/books/anatomy-and-physiology-2e>

5. This work is a derivative of Anatomy & Physiology by [OpenStax](https://openstax.org/details/books/anatomy-and-physiology-2e) and is licensed under [CC BY 4.0](https://openstax.org/details/books/anatomy-and-physiology-2e). Access for free at <https://openstax.org/details/books/anatomy-and-physiology-2e>

View a supplementary YouTube video⁶ from Crash
Course on vision: [Vision: Crash Course Anatomy & Physiology #18](#)

AUDITORY

Hearing is a special sense based on the transduction of sound waves into a neural signal that is made possible by the structures of the ear. See Figure 15.3⁷ for an illustration of the ear structures.⁸

6. CrashCourse. (2015, May 11). *Vision: Crash Course Anatomy & Physiology #18* [Video]. YouTube. All rights reserved.
<https://www.youtube.com/watch?v=o0DYP-u1rNM>

7. "5dfc7e834c03e3e7dbbf82de10413b92379a1a57.png" by Clark, et al., is licensed under [CC BY 4.0](#). Access for free at <https://openstax.org/books/biology-2e/pages/1-introduction>.

8. This work is a derivative of *Anatomy & Physiology* by [OpenStax](#) and is licensed under [CC BY 4.0](#). Access for free at <https://openstax.org/details/books/anatomy-and-physiology-2e>

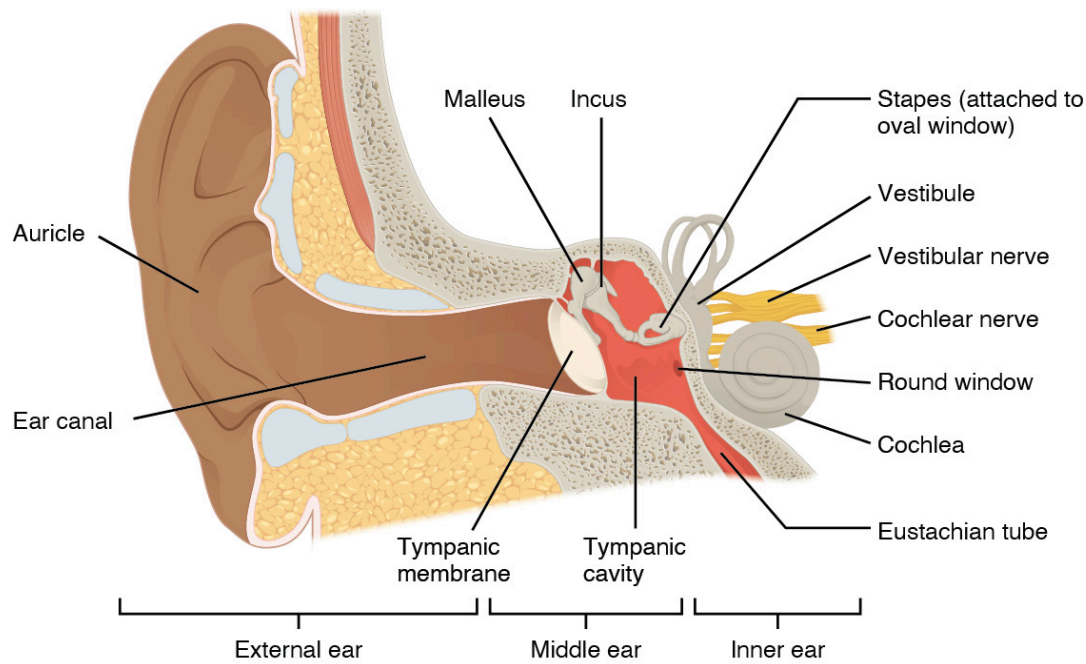


Figure 15.3 Structures of the Ear

The large, fleshy structure on the lateral aspect of the head is the **auricle** (AW-rĭ-kl), also known as the **pinna** (PĪN-ă). The C-shaped curves of the auricle direct sound waves toward the ear canal. At the end of the ear canal is the **tympanic membrane** (tĭm-păn-ik mem-brăn), commonly referred to as the eardrum, that vibrates from sound waves. The auricle, ear canal, and tympanic membrane are referred to as the external ear.⁹

The middle ear consists of a space with three small bones called the malleus, incus, and stapes, the Latin names that roughly translate to “hammer,” “anvil,” and “stirrup.” The **malleus** (MĂL-ē-ŭs) is attached to the tympanic membrane and articulates with the incus. The **incus** (ĪN-kŭs), in turn, articulates with the stapes. The **stapes** (stā-pēz) is attached to the inner ear, where the sound waves are converted into a neural signal. The middle ear

9. This work is a derivative of Anatomy & Physiology by OpenStax and is licensed under CC BY 4.0. Access for free at <https://openstax.org/details/books/anatomy-and-physiology-2e>

is also connected to the pharynx through the **Eustachian tube** (yōō-STĀ-shēn tūb) that helps equalize air pressure across the tympanic membrane. The Eustachian tube is normally closed but will pop open when the muscles of the pharynx contract during swallowing or yawning.¹⁰

The **inner ear** (IN-er ĒR) is often described as a bony labyrinth because it is composed of a series of semicircular canals. The semicircular canals have two separate regions called the **cochlea** (KŎK-lē-ă) and the **vestibule** (ves-tĭ-bŭl) that are responsible for hearing and balance. The neural signals from these two regions travel together from the inner ear to the brain via the **vestibulocochlear nerve** (ves-tĭ-bŭl-ō-KŎ-klē-ar nerve). See Figure 15.4¹¹ for an illustration of the transmission of sound from the outer ear to the middle ear and to the inner ear.¹²

10. This work is a derivative of Anatomy & Physiology by [OpenStax](#) and is licensed under [CC BY 4.0](#). Access for free at <https://openstax.org/details/books/anatomy-and-physiology-2e>

11. “[Outer_Ear.jpg](#)” by [Nzachariah3](#) and is licensed under [CC BY 3.0](#)

12. This work is a derivative of Anatomy & Physiology by [OpenStax](#) and is licensed under [CC BY 4.0](#). Access for free at <https://openstax.org/details/books/anatomy-and-physiology-2e>

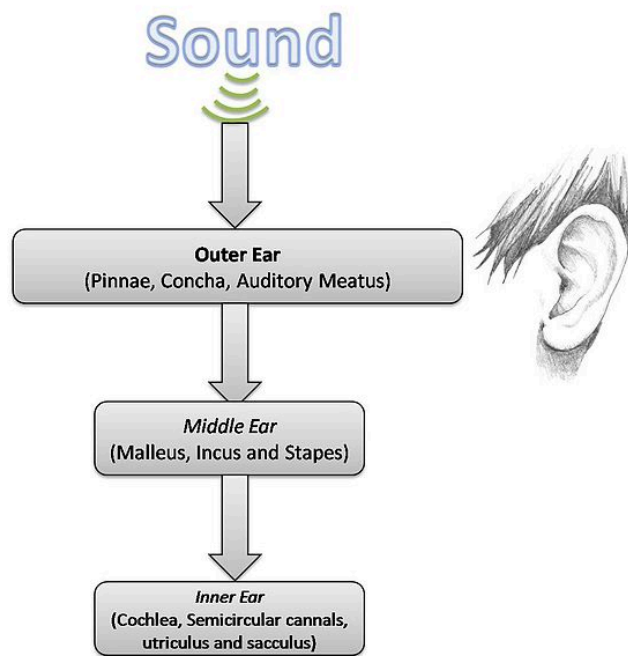


Figure 15.4 Pathway of Sound Vibrations

Hearing

The cochlea encodes auditory stimuli for frequencies between 20 and 20,000 Hz, which is the range of sound that human ears can detect. The hair cells along the length of the cochlear duct, which are each sensitive to a particular frequency, allow the cochlea to separate auditory stimuli by frequency, just as a prism separates visible light into its component colors. See Figure 15.5¹³ for an illustration of the cochlea.¹⁴

13. "1406_Cochlea.jpg" by OpenStax College is licensed under [CC BY 4.0](#)

14. This work is a derivative of Anatomy & Physiology by [OpenStax](#) and is licensed under [CC BY 4.0](#). Access for free at <https://openstax.org/details/books/anatomy-and-physiology-2e>

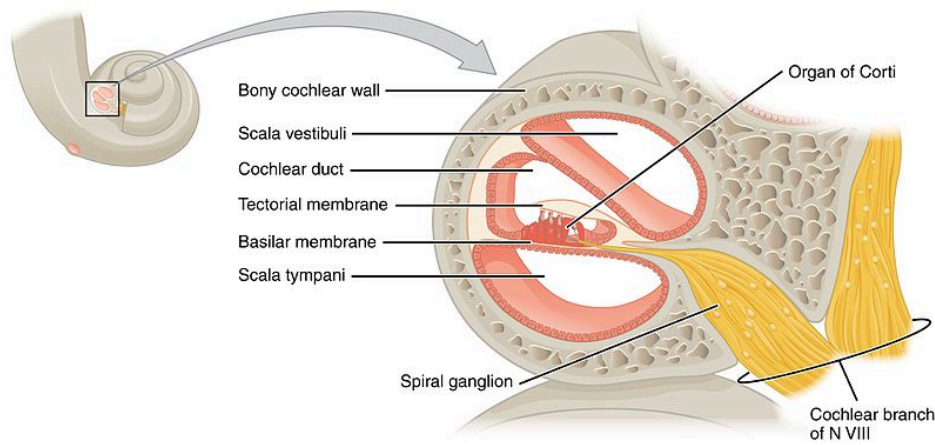


Figure 15.5 Cochlea

Balance

Along with hearing, the inner ear is also responsible for the sense of balance. There are three semicircular canals (superior, posterior, and lateral) extending from the vestibule filled with fluid that work to maintain balance. Hair cells within the vestibule sense head position, head movement, and body motion. Medical conditions affecting the semicircular canals cause incorrect balance signals to be sent to the brain, resulting in a spinning type of dizziness called **vertigo** (VUR-tĭ-gō).¹⁵



View a supplementary YouTube video¹⁶ from Crash

15. This work is a derivative of Anatomy & Physiology by OpenStax and is licensed under CC BY 4.0. Access for free at <https://openstax.org/details/books/anatomy-and-physiology-2e>

16. CrashCourse. (2015, May 4). *Hearing & balance: Crash Course*



Course on hearing and balance: [Hearing & Balance: Crash Course Anatomy & Physiology #17](#)

TASTE

Taste is the special sense associated with the tongue. The surface of the tongue contains raised bumps called papillae that contain the structures for taste transmission. Within the structure of the papillae are taste buds that contain specialized receptor cells for the transduction of taste stimuli. These receptor cells are sensitive to the chemicals contained within foods that are ingested, and they release neurotransmitters based on the amount of the chemical in the food. Until recently, only four tastes were recognized: sweet, salty, sour, and bitter. Recent research has suggested that there may also be additional tastes for fats and glutamates (tomatoes, cheese, and mushrooms).¹⁷

Anatomy & Physiology #17 [Video]. YouTube. All rights reserved.

<https://www.youtube.com/watch?v=le2j7GpC4JU>

17. This work is a derivative of Anatomy & Physiology by [OpenStax](#) and is licensed under [CC BY 4.0](#). Access for free at <https://openstax.org/details/books/anatomy-and-physiology-2e>

SMELL

Olfaction (smell) is a special sense based on receptors in a small region of the nasal cavity that are responsive to chemical stimuli. Scent receptor messages travel to the brain, where smells are interpreted and can even become associated with long-term memories and emotional responses.¹⁸ See Figure 15.6¹⁹ for an illustration of olfaction. In this illustration, the olfactory bulb (1) contains mitral cells (2) that receive information from the olfactory cells (3). The olfactory cells are found within the nasal epithelium (4) and pass their information through the cribriform plate (5) of the ethmoid bone.

18. This work is a derivative of Anatomy & Physiology by [OpenStax](#) and is licensed under [CC BY 4.0](#). Access for free at <https://openstax.org/details/books/anatomy-and-physiology-2e>

19. “[Cenveo – Drawing Anatomy of the Structures Involved in Smell \(Olfaction\) – Numbered labels](#)” by Cenveo is licensed under [CC BY 4.0](#)

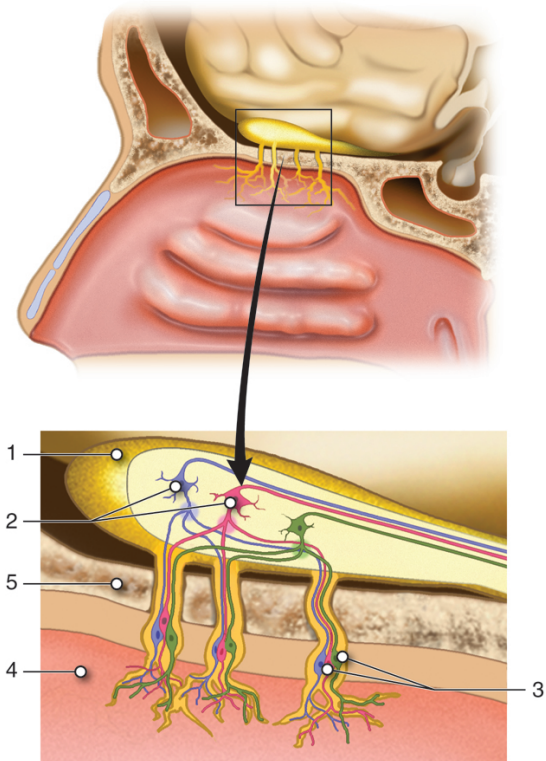


Figure 15.6 Olfaction

View a supplementary YouTube video²⁰ from Crash
 Course on taste and smell: [Taste & Smell: Crash Course
 Anatomy & Physiology #16](https://www.youtube.com/watch?v=mFm3yA1nsIE)

20. CrashCourse. (2015, April 27). *Taste & smell: Crash Course Anatomy & Physiology #16* [Video]. YouTube. All rights reserved.
<https://www.youtube.com/watch?v=mFm3yA1nsIE>

TOUCH

Touch is considered a general sense, as opposed to the special senses that were previously discussed in this section. Many of the receptors for touch are located in the skin, but receptors are also found in muscles, tendons, joint capsules, ligaments, and in the walls of visceral organs. These receptors detect sensations such as pressure, vibration, light touch, tickle, itch, temperature, pain, and proprioception (i.e., the sense of location, movement, and action of our body parts).²¹

21. This work is a derivative of [Anatomy and Physiology](https://openstax.org/books/anatomy-and-physiology) by [OpenStax](https://openstax.org/books/anatomy-and-physiology) licensed under [CC BY 4.0](https://creativecommons.org/licenses/by/4.0/). Access for free at <https://openstax.org/books/anatomy-and-physiology/pages/1-introduction>

15.5 Diseases and Disorders Related to the Sensory Systems

EYE DISEASES AND DISORDERS

Astigmatism

Astigmatism (ă-STIG-mă-tizm) refers to blurry vision due to the irregular curvature of the cornea or lens. It is treated with corrective glasses or contact lenses.

Blindness

The term “blindness” covers a broad spectrum of visual impairments due to injury, disease, or a congenital condition. **Total blindness** (TŌ-tăl BLĪND-něss) is a term used to describe those who have complete lack of light perception.

Low vision (LŌ VIZH-ŭn) is a term used to describe those individuals whose vision cannot be fully corrected by conventional methods such as glasses, contact lenses, medicine, surgery, magnification aids, or assistive technology.

Visual impairment (VIZH-ŭ-al Im-PĀR-měnt) is a term used to describe decreased visual function that interferes with an individual’s ability to perform activities of daily living, such as reading, driving, and watching TV. **Legal blindness** (LĒ-găl BLĪND-něss), a term used for establishing disability benefits

and rehabilitation training, refers to **visual acuity** (VIZH-u-ăl ă-KŪ-īt-ē) (**VA**) of 20/200 or less in the best-seeing eye after correction.¹

Cataract

A **cataract** (KAT-ă-rakt) is a progressive disease of the lens that causes cloudiness and a lack of transparency. Cataracts are very common in older adults. Over half of all Americans aged 80 or older either have cataracts or have had surgery to remove cataracts. See Figure 15.7² for an image of a cataract. Cataracts develop slowly, and symptoms include faded colors, blurred or double vision, halos around light, and trouble seeing at night. See Figure 15.8³ for a simulated image of a person's vision who has cataracts. Decreased vision due to cataracts may result in trouble reading and driving and increases the risk of falling. Patients often undergo surgery for cataracts. During cataract surgery, the doctor removes the clouded lens and replaces it with a new, artificial lens.⁴

1. This work is a derivative of [StatPearls](#) by Lee & Mesfin and is licensed under [CC BY 4.0](#)
2. “[Cataract in human eye.png](#)” by Rakesh Ajuja, MD is licensed under [CC BY-SA 3.0](#)
3. “[Eye disease simulation, cataract.jpg](#)” by [National Eye Institute, National Institutes of Health](#) is in the [Public Domain](#).
4. National Eye Institute. (2023, November 15). *Cataracts*. National Institutes of Health. <https://www.nei.nih.gov/learn-about-eye-health/eye-conditions-and-diseases/cataracts>

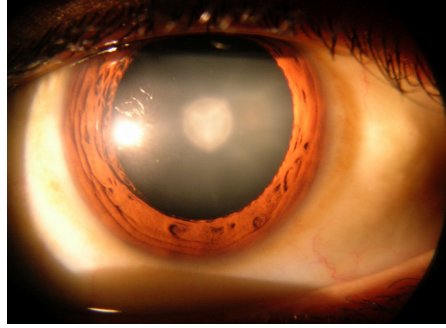


Figure 15.7 Cataract



*Figure 15.8 Simulated
Vision With Cataracts*

Color Blindness

Color blindness, also called color vision deficiency, makes it difficult to differentiate between certain colors. Color blindness tends to run in families as a genetic condition, but it can also occur due to damage to the eye or to the brain. There's no cure for color blindness, but special glasses and contact lenses can help people differentiate between colors. Most people who have

color blindness are able to use visual strategies related to color selection and don't have problems participating in everyday activities.⁵

Conjunctivitis

Conjunctivitis (kŏn-jŭnk-tĭ-VĪT-ĭs) is a viral or bacterial infection that causes swelling and redness in the conjunctiva and sclera. See Figure 15.9⁶ for an image of conjunctivitis. The eye may feel itchy and painful with crusty yellow drainage present. Bacterial conjunctivitis is treated with antibiotic eye drops. Viral conjunctivitis is typically mild and resolves on its own.⁷

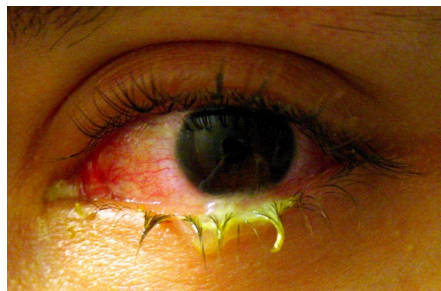

Figure 15.9 Conjunctivitis

Diabetic Retinopathy

Diabetic retinopathy (ret-ĭn-ŌP-ă-thē) is a complication caused by diabetes

5. National Eye Institute. (2023, November 15). *Color blindness*. National Institutes of Health. <https://www.nei.nih.gov/learn-about-eye-health/eye-conditions-and-diseases/color-blindness>
6. “Swollen eye with conjunctivitis.jpg” by Tanalai at English Wikipedia is licensed under [CC BY 3.0](https://creativecommons.org/licenses/by/3.0/)
7. National Eye Institute. (2019, July 8). *Causes of pink eye*. National Institutes of Health. <https://www.nei.nih.gov/learn-about-eye-health/eye-conditions-and-diseases/pink-eye/causes-pink-eye>

mellitus. Fluid leakage from blood vessels causes the retinal tissue to swell, resulting in cloudy or blurred vision. If left untreated, diabetic retinopathy can cause blindness. There are various treatments for diabetic retinopathy, such as laser surgery to seal leaking blood vessels or the injection of medications into the eye to decrease inflammation. People with advanced cases of diabetic retinopathy may require surgery to remove and replace the gel-like fluid in the back of the eye, called the vitreous humor. Surgery may also be needed to repair a retinal detachment, a separation of the light-receiving lining in the back of the eye.⁸

Glaucoma

Glaucoma (glaw-KŌ-mă) is a disease that causes vision loss due to increased pressure inside the eye damaging the optic nerve. Treatment includes prescription eye drops to lower the pressure inside the eye and slow the progression of the disease. If not treated appropriately, glaucoma can cause blindness. Symptoms of glaucoma include gradual loss of peripheral vision. See Figure 15.10⁹ for a simulated image of a person's vision with glaucoma.¹⁰

8. American Optometric Association. (n.d.). *Diabetic retinopathy*. <https://www.aoa.org/healthy-eyes/eye-and-vision-conditions/diabetic-retinopathy?sso=y>
9. “Eye disease simulation, glaucoma.jpg” by National Eye Institute, National Institutes of Health is in the Public Domain.
10. National Eye Institute. (2023, November 15). *Glaucoma*. National Institutes of Health. <https://www.nei.nih.gov/learn-about-eye-health/eye-conditions-and-diseases/glaucoma>



Figure 15.10 Simulated Vision With Glaucoma

Macular Degeneration

Age-related **macular degeneration** (MǎK-yǔ-lǎr Dě-gě-n-ě-RĀ-shǔn) is a common condition that causes blurred central vision. It is the leading cause of vision loss for people 50 and older. See Figure 15.11¹¹ for a simulated image of a person's vision who has macular degeneration. There are two types of macular degeneration: dry (nonexudative) and wet (exudative). During dry macular degeneration, cellular debris called drusen accumulates and scars the retina. In the wet (exudative) form, which is more severe, blood vessels grow behind the retina and leak exudate fluid, causing hemorrhaging and scarring. There is no treatment for dry macular degeneration, but laser therapy can be used to help treat wet (exudative) macular degeneration.¹²

11. [“Eye disease simulation, age-related macular degeneration.jpg”](#) by [National Eye Institute, National Institutes of Health](#) is in the [Public Domain](#).

12. National Eye Institute. (2021, June 22). *Age-related macular degeneration*. National Institutes of Health. <https://www.nei.nih.gov/learn-about-eye-health/eye-conditions-and-diseases/age-related-macular-degeneration>



Figure 15.11 Simulated Vision With Macular Degeneration

Myopia

Myopia (mī-Ō-pē-ă), also known as nearsightedness, means normal near vision but far-away objects appear blurry. Myopia occurs when the eyeball grows too long from front to back or when there are problems with the shape of the cornea or the lens. These problems make light focus in front of the retina, instead of on it, causing blurriness. See Figure 15.12¹³ for a simulated image of a person's vision who has myopia. Nearsightedness usually becomes apparent between ages 6 and 14. It is corrected with glasses, contacts, or LASIK surgery.¹⁴

13. “[Eye disease simulation, myopia.jpg](#)” by [National Eye Institute, National Institutes of Health](#) is in the [Public Domain](#).

14. National Eye Institute. (2020, August 28). *Types of refractive errors*. National Institutes of Health. <https://www.nei.nih.gov/learn-about-eye-health/eye-conditions-and-diseases/refractive-errors/types-refractive-errors#section-id-6802>



Figure 15.12 Simulated Vision With Myopia

Night Blindness (Nyctalopia)

Nyctalopia (nik-ta-LŌ-pē-ă) refers to poor vision at night or in dim light. It is also associated with an inability to quickly adapt from a well-illuminated to a poorly illuminated environment. Nyctalopia is not a disease in itself, but rather a symptom of an underlying eye problem, usually a retinal problem.¹⁵

Nystagmus

Nystagmus (nīs-TĂG-mūs) is a disorder that causes involuntary, rhythmic eye movements. Most nystagmus disorders are caused by an underlying medical condition. The repetitive movements can make it impossible for someone to keep their eyes fixed and focused on any given object. Individuals can be born with congenital nystagmus, or it can occur as a result of another condition or a side effect of medication.¹⁶

15. Cleveland Clinic. (2020, December 1). *Night blindness (nyctalopia)*. <https://my.clevelandclinic.org/health/symptoms/10118-night-blindness-nyctalopia>

16. All About Vision. (2019, March 4). *Nystagmus*. <https://www.allaboutvision.com/conditions/nystagmus.htm>

Hyperopia and Presbyopia

Hyperopia (hī-pĕr-Ō-pē-ă) refers to impaired near vision, commonly referred to as “farsightedness” because distance vision is normal but near vision is impaired. When it occurs in middle-aged and older adults, it is referred to as **presbyopia** (prez-bī-Ō-pē-ă). As people age, the lens in the eye gets harder and less flexible and stops focusing light correctly on the retina. Presbyopia can be corrected with glasses and/or contacts.¹⁷ See Figure 15.13¹⁸ for a simulated image of a person’s vision who has presbyopia.

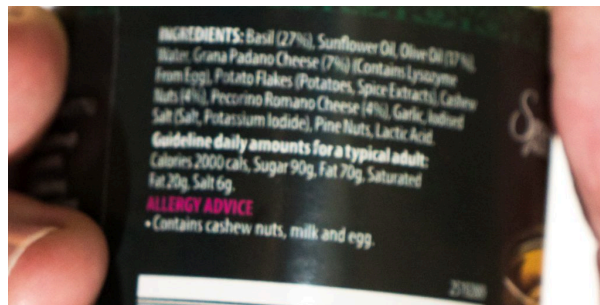


Figure 15.13 Presbyopia

Retinal Detachment

Retinal detachment occurs when the retina is pulled away or separated from its normal position. Sudden flashing lights, floaters, and the appearance of a dark shadow in the center of one’s vision are symptoms of a retinal tear. A retinal tear is a medical emergency because it can lead to a retinal detachment. If left untreated, retinal detachment can lead to blindness.

17. National Eye Institute. (2020, August 28). *Types of refractive errors*. National Institutes of Health. <https://www.nei.nih.gov/learn-about-eye-health/eye-conditions-and-diseases/refractive-errors/types-refractive-errors#section-id-6802>

18. “Pesto ingredients – blurred.jpg” by Colin is licensed under CC BY-SA 4.0

Ophthalmologists repair the retinal detachment using laser surgery, freezing treatment, and/or other types of surgery to fix the retinal tear and reattach the retina to the back of the eye.¹⁹

Strabismus

Usually, the eyes move together as a pair, but with **strabismus** (stră-BĪZ-mŭs), the eyes don't move together in coordination. One eye might drift in, out, up, or down. If not managed, amblyopia can develop. **Amblyopia** (am-blē-Ō-pē-ă), commonly known as lazy eye, develops when there is a breakdown in how the brain and the eye work together. Over time, the brain relies more and more on the other, stronger eye, while vision in the weaker eye gets worse.²⁰

Stye

A **stye** (stī) is a bacterial infection of an oil gland of the eyelid, causing a red, tender bump. See Figure 15.14²¹ for an image of a stye. Treatment includes applying warm compresses to the eyelid and prescription eyedrops.²²

19. National Eye Institute. (2023, November 15). *Retinal detachment*. National Institutes of Health. <https://www.nei.nih.gov/learn-about-eye-health/eye-conditions-and-diseases/retinal-detachment>
20. National Eye Institute. (2022, September 22). *Amblyopia (lazy eye)*. National Institutes of Health. <https://www.nei.nih.gov/learn-about-eye-health/eye-conditions-and-diseases/amblyopia-lazy-eye>
21. “[External hordeolum.jpg](#)” by [Inrankabirhossain](#) is licensed under [CC BY-SA 4.0](#)
22. National Eye Institute. (2023, November 15). *Blepharitis*. National Institutes of Health. <https://www.nei.nih.gov/learn-about-eye-health/eye-conditions-and-diseases/blepharitis>

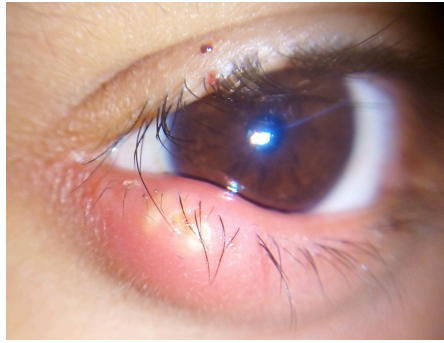


Figure 15.14 Stye

EAR DISEASES AND DISORDERS

Hearing Loss

Hearing loss is classified as conductive hearing loss or sensorineural hearing loss. **Conductive hearing loss** (kŏn-DUC-tĭv HĒR-ing LŎS) occurs when something in the external or middle ear is obstructing the transmission of sound. For example, cerumen impaction or a perforated tympanic membrane can cause conductive hearing loss. **Sensorineural hearing loss** (sĕn-sō-rĕ-NOOR-ăĭ HĒR-ing LŎS) is caused by pathology of the inner ear, nerve damage, or damage to the auditory areas of the brain. **Presbycusis** (prĕz-bĭ-KŪ-sĭs) is sensorineural hearing loss that occurs with aging due to gradual nerve degeneration.²³

23. This work is a derivative of Open RN [Nursing Skills 2e](#) and is licensed by [CC BY 4.0](#)

Cerumen Impaction

Cerumen impaction (sě-ROO-měň Im-PĀK-shŭn) is earwax buildup that blocks the ear canal and can cause symptoms of hearing loss. See Figure 15.15 for an image of cerumen impaction.²⁴ Cerumen can be removed via irrigation of the ear canal, ear drops to dissolve the wax, or manual removal.²⁵ See Figure 15.15 for an image of an ear irrigation procedure, commonly performed by nurses in a clinic setting.²⁶

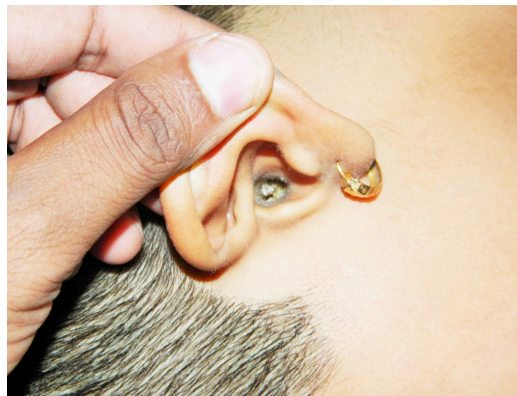

Figure 15.15 Cerumen Impaction

24. “[Ear Wax.JPG](#)” by [Anand2202](#) is licensed under [CC BY-SA 4.0](#)

25. This work is a derivative of [StatPearls](#) by Mankowski & Raggio and is licensed under [CC BY 4.0](#)

26. “150915-F-GO352-025.jpg” by Staff Sgt. Jason Huddleston for U.S. Air Force is licensed under [CC0](#). Access for free at <https://www.59mdw.af.mil/News/Article-Display/Article/647342/photo-essay-559th-medical-group-at-a-glance/>

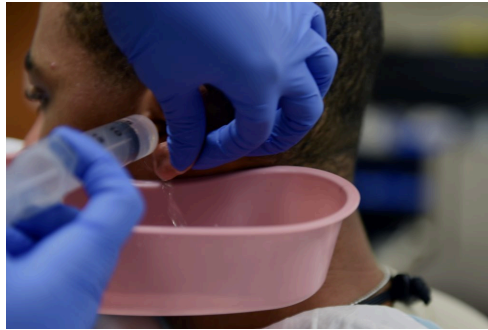


Figure 15.16 Ear Irrigation Procedure

Otitis Externa

Otitis externa (ō-TĪ-tĭs eks-TUR-nă) is an external ear inflammation and/or infection. See Figure 15.17²⁷ for an image of otitis externa. It is also known as “swimmer’s ear” because it commonly occurs in swimmers due to the continuous exposure to water that washes away the protective wax in their ear canals. Otitis externa causes a reddened and swollen ear canal with associated yellow, white, or grey debris. Patients often report itching in the ear canal with pain that is worsened by pulling upwards and outwards on the auricle. Otitis externa is treated with antibiotic drops placed in the affected ear canal.²⁸

27. “Otitis externa.gif” by S. Bhjimji MD is licensed under [CC BY 4.0](https://creativecommons.org/licenses/by/4.0/). Access for free at <https://www.ncbi.nlm.nih.gov/books/NBK556055/>

28. This work is a derivative of [StatPearls](https://www.statpearls.com/) by Medina-Blasini & Sharman and is licensed under [CC BY 4.0](https://creativecommons.org/licenses/by/4.0/)

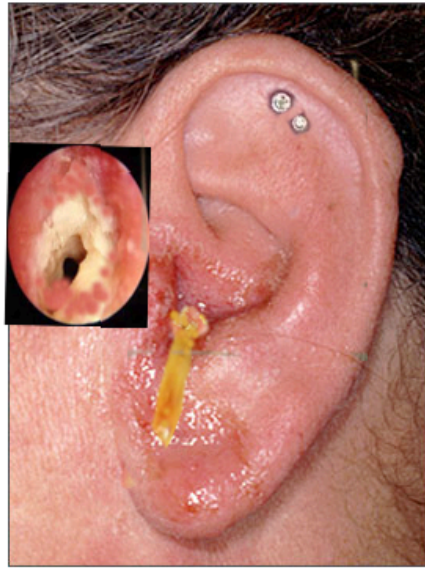

Figure 15.17 Otitis Externa

Otitis Media

Otitis media (ō-Tĭ-tīs MĒ-dē-ă) refers to a middle ear infection. Ear infections are common in children between the ages of 6 months and 2 years because of the size and shape of their Eustachian tubes. Acute otitis media typically occurs after an upper respiratory infection when the Eustachian tube becomes inflamed and the middle ear fills with fluid, causing ear pain and irritability. This fluid can become infected, causing purulent fluid and low-grade fever. Otitis media is diagnosed by a health care provider using an **otoscope** (Ō-tō-skōp) to examine the tympanic membrane for bulging and purulent fluid. If not treated, acute otitis media can potentially cause perforation of the tympanic membrane. Treating early acute otitis media with antibiotics is controversial in the United States due to the effort to prevent antibiotic resistance. However, the treatment goals are to control pain and treat infection with antibiotics if a bacterial infection is present.²⁹

29. This work is a derivative of [StatPearls](#) by Danishyar & Ashurst and is licensed under [CC BY 4.0](#)

Some children develop recurrent ear infections that cause intermittent hearing loss affecting their language development. For children experiencing recurring infections, a surgery called **myringotomy** (mĭr-ĭn-GŎT-ō-mē) is performed by an otolaryngologist. During myringotomy surgery, a tympanostomy tube is placed in the tympanic membrane to drain fluid from the middle ear and prevent infection from developing.³⁰ See Figure 15.18³¹ for an image of a tympanostomy tube in the ear.

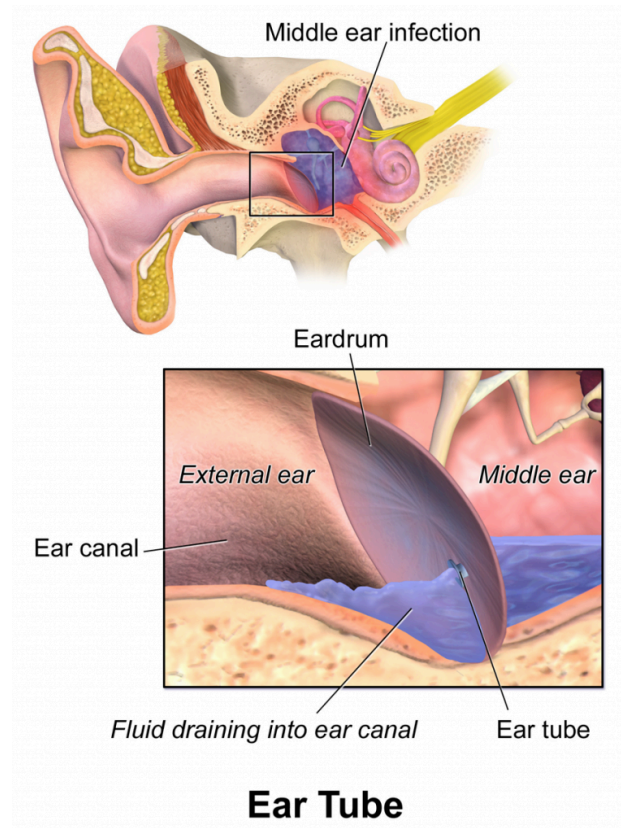


Figure 15.18 Tympanostomy Tube

30. This work is a derivative of [StatPearls](#) by Danishyar & Ashurst and is licensed under [CC BY 4.0](#)

31. "[Ear Tube.png](#)" by [BruceBlaus](#) is licensed under [CC BY-SA 4.0](#)

Otosclerosis

Otosclerosis (ō-tō-sklĕ-RŌ-sĭs) is abnormal bone formation of the middle ear that can cause hearing loss. Treatment for mild otosclerosis is use of a hearing aid, while more severe otosclerosis is treated with surgery called **stapedectomy** (stā-pĕ-DEK-tŏ-mē).³²

Presbycusis

Presbycusis (prez-bĭ-KŪ-sĭs) refers to hearing impairment that occurs with aging. One in three people in the U.S. between the ages of 65 and 74 has hearing loss, and nearly half of those older than 75 have difficulty hearing. Having trouble hearing can make it hard to understand and follow a doctor's advice; respond to warnings; and hear phones, doorbells, and smoke alarms. As we age, changes in the inner ear, middle ear, and nerve pathways from the ear to the brain are common. Long-term exposure to noise and some medical conditions can also play a role in hearing loss. Recent research suggests that certain genes make some people more susceptible to hearing loss as they age. Hearing loss may be treated with hearing aids or cochlear implants.³³

Tinnitus

Tinnitus (tĭ-NĪ-tŭs) is a ringing, buzzing, roaring, hissing, or whistling sound in the ears. The noise may be intermittent or continuous. Tinnitus can be caused by cerumen impaction, noise trauma, or ototoxic medications, such as diuretics or high doses of aspirin. Military personnel have a high incidence of tinnitus due to noise trauma from loud explosions and gunfire. There are no

32. National Institute on Deafness and Other Communication Disorders. (2022, March 16). *Otosclerosis*. National Institutes of Health.
<https://www.nidcd.nih.gov/health/otosclerosis>

33. National Institute on Deafness and Other Disorders. (2023, March 17). *Age-related hearing loss (presbycusis)*. National Institutes of Health.
<https://www.nidcd.nih.gov/health/age-related-hearing-loss>

medications to treat tinnitus, but patients can be referred to an otolaryngologist for treatment such as cognitive therapy or noise masking.³⁴

Vertigo

Vertigo (VUR-tĭ-gō) is a type of dizziness that is often described by patients as, “the room feels as if it is spinning.” Benign positional vertigo (BPV) is a common condition caused by crystals becoming lodged in the semicircular canals in the vestibule of the inner ear that send false signals of movement to the brain. BPV can be treated by trained professionals using a specific set of maneuvers that guide the crystals back to the chamber where they are supposed to be in the inner ear.³⁵

OLFACTORY DISORDERS

Anosmia

Trauma to the face and certain medications can damage the olfactory nerve and cause the loss of smell, known as **anosmia** (a-NOZ-mē-ă). There are also temporary causes of anosmia, such as the inflammatory response related to upper respiratory infections or allergies. The sense of smell is important because it is often the first warning signal alerting us to the smoke of a fire, spoiled food, or the odor of a natural gas leak or dangerous fumes. Anosmia can also result in the loss of taste. A person with an impaired sense of taste

34. This work is a derivative of [StatPearls](#) by Grossan & Peterson and is licensed under [CC BY 4.0](#)

35. Woodhouse, S., & Doriangricchia, J. P. (2022, November). *Benign paroxysmal positional vertigo (BPPV)*. Vestibular Disorders Association. <https://vestibular.org/article/diagnosis-treatment/types-of-vestibular-disorders/benign-paroxysmal-positional-vertigo-bppv/>

may require additional spice and seasonings on their food, and in severe cases, cause the loss of their desire to eat.³⁶

³⁶. National Institute on Deafness and Other Communication Disorders. (2023, July 31). *Smell disorders*. National Institutes of Health.
<https://www.nidcd.nih.gov/health/smell-disorders>

15.6 Medical Specialties, Diagnostic Testing, and Procedures Related to the Sensory System

MEDICAL SPECIALISTS

Several medical specialists help diagnose and treat conditions related to the eye. An **ophthalmologist** (öp-thäl-MÖL-ō-jĭst) is a physician who specializes in treating eye diseases and performs eye surgery. An **optometrist** (öp-TÖM-ě-trĭst) is a doctor who has received a Doctor of Optometry (op-TOM-ě-trē) degree. Optometrists perform eye exams and vision tests and prescribe corrective lenses. **Opticians** (öp-TĭSH-ănz) are technicians trained to design, verify, and fit eyeglass lenses and frames, contact lenses, and other devices to correct eyesight. They use prescriptions supplied by ophthalmologists or optometrists, but do not test vision or write prescriptions for visual correction.¹

1. American Association for Pediatric Ophthalmology and Strabismus (2019, February 26). *Difference between an ophthalmologist, optometrist, and optician*. <https://aapos.org/glossary/difference-between-an-ophthalmologist-optometrist-and-optician>

- ▶ Read additional information on the American Association for Pediatric Ophthalmology and Strabismus: [Difference Between An Ophthalmologist, Optometrist, and Optician web page](#).

Audiology (od-ē-OL-ō-jē) is the study of hearing. **Audiologists** (od-ē-OL-ō-jīstz) are specialists who study and treat hearing. They perform diagnostic testing like audiometry and provide hearing loss interventions, such as hearing aids. **Otology** (ō-TŌL-ō-jē) refers to the study of the ear. An **otolaryngologist** (ō-tō-RĪ-nō-lār-ĭn-GŎL-ō-jīst) is a physician who specializes in ear, nose, and throat (ENT) treatments and conditions.²

- ▶ Read additional information about audiologists on the American Academy of Audiology's [What is An Audiologist?](#) web page.

Ophthalmic Medical Assistant

Ophthalmic medical assistants work in ophthalmology and optometry practices and in retail optical settings. Ophthalmic assistants perform prescreening and specialty testing, assist with dispensing glasses and contact lenses, and perform office management duties, including maintaining patient information and billing and insurance processes.

2. Johns Hopkins Medicine. (n.d.). *Hearing loss*.

<https://www.hopkinsmedicine.org/health/conditions-and-diseases/hearing-loss>

Optometric Technician

Optometric technicians work under the supervision of an optometrist or ophthalmologist. Optometric technicians assist an optometrist during eye exams and other optometric procedures.

DIAGNOSTIC TESTING

Eye Exams

Common tools used to screen individuals for vision problems are the Snellen chart, a near vision chart, and Ishihara plates. If a vision problem is identified, the patient is referred to an optometrist for further vision testing. An **ophthalmoscope** (op-THAL-mŏ-skōp) is an instrument used to view the eye, and **ophthalmoscopy** (op-thal-MOS-kŏ-pē) is the process of viewing the eye.

Snellen Chart

Distant vision is tested by using the Snellen chart. See Figure 15.19³ for an image of the Snellen chart. The patient is placed 20 feet away from the chart and asked to cover one eye and read the letters from the lowest line they can see clearly. This is repeated with the other eye. A person with normal **visual acuity** (VIZH-u-ăl ă-KŪ-īt-ē) or sharpness or clearness of vision is documented as having 20/20 vision. A person with impaired vision has a different lower denominator of this fraction. For example, a vision measurement of 20/30 indicates that the patient has decreased distant vision and can see letters clearly at 20 feet that a person with normal vision can see clearly at 30 feet.⁴

3. "[Snellen chart.jpg](#)" by [Jeff Dahl](#) is licensed under [CC BY-SA 3.0](#)

4. Sue, S. (2007). Test distance vision by using a Snellen chart. *Community Eye Health*, 20(63), 52. <https://www.ncbi.nlm.nih.gov/pmc/articles/PMC2040251/>

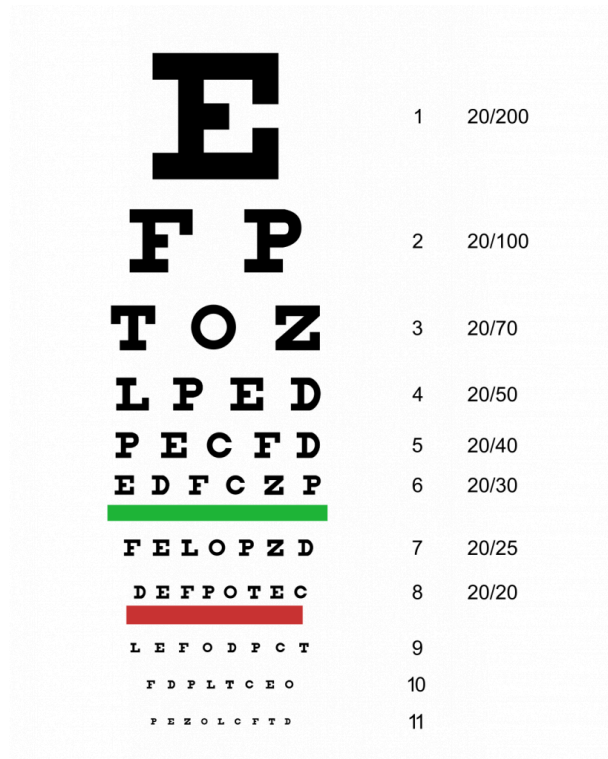


Figure 15.19 Snellen Chart

Near Vision Chart

Near vision is assessed by having a patient read from a prepared card that is held 14 inches away from the eyes. See Figure 15.20⁵ for an image of a prepared card used to assess near vision.

5. "111012-F-ZT401-067.JPG" by Airman 1st Class Brooke P. Beers for U.S. Air Force is in the [Public Domain](https://www.pacaf.af.mil/News/Article-Display/Article/593609/keeping-sight-all-right/). Access for free at <https://www.pacaf.af.mil/News/Article-Display/Article/593609/keeping-sight-all-right/>

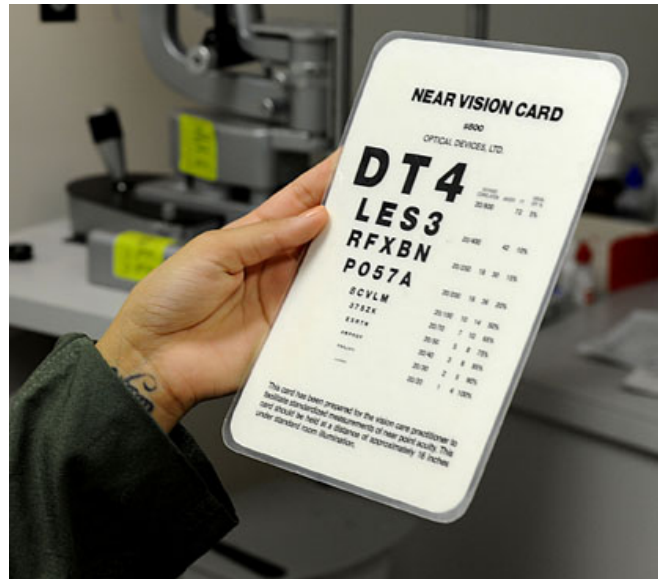

Figure 15.20 Near Vision Card

Ishihara Plates

Ishihara plates are commonly used to assess color vision. Each of the colored dotted plates shows either a number or a path. See Figure 15.21⁶ for an example of Ishihara plates. A person with color blindness is not able to distinguish the numbers or paths from the other colored dots on the plate.

6. This work is a derivative of “[Ishihara 9.png](#)” and “[Ishihara 1.png](#)” by [Shinobu Ishihara](#) and in the [Public Domain](#).

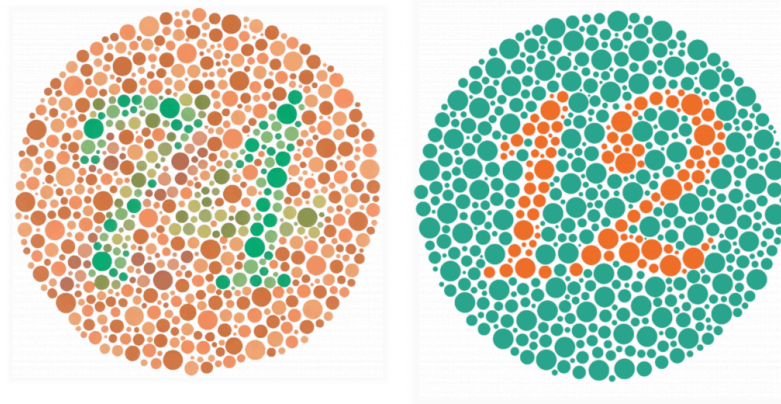


Figure 15.21 Ishihara Plates

Ear Exams

An **otoscope** (Ō-tō-skōp) is an instrument used to view the ear, and **otoscopy** (ō-TŌS-kō-pē) is the process of viewing the ear.

Audiometry

Audiometry (od-ē-OM-ě-trē) refers to diagnostic testing that measures hearing. This includes tests of mechanical sound transmission (middle ear function), neural sound transmission (cochlear function), and speech discrimination ability (central integration). A complete evaluation of a patient's hearing is done by trained personnel using instruments designed specifically for this purpose. For example, an **audiometer** (od-ē-OM-ět-ěr) is an electric instrument consisting of a tone generator, a bone conduction oscillator for measuring cochlear function, and earphones for air conduction testing. Sounds are played through headphones to one ear at a time, and the patient is asked to respond if they hear each sound. An **audiogram** (OD-ē-ō-gram) is a chart that shows the results of a hearing test. It shows how well sounds are heard in terms of frequency (high-pitched sounds versus low-pitched sounds) and intensity (loudness).⁷

⁷ Johns Hopkins Medicine. (n.d.). *Hearing loss*.

<https://www.hopkinsmedicine.org/health/conditions-and-diseases/hearing-loss>

15.7 Sensory System Learning Activities

Interactive Learning Activity: Practice labeling the parts of the eye, Activity 1.



An interactive H5P element has been excluded from this version of the text. You can view it online here:

<https://wtcs.pressbooks.pub/medterm/?p=401#h5p-66>

Interactive Learning Activity: Practice labeling the parts of the eye, Activity 2.



An interactive H5P element has been excluded from this version of the text. You can view it online here:

<https://wtcs.pressbooks.pub/medterm/?p=401#h5p-69>

Interactive Learning Activity: Practice labeling the parts of the ear.



An interactive H5P element has been excluded from this version of the text. You can view it online here:

<https://wtcs.pressbooks.pub/medterm/?p=401#h5p-64>

Interactive Learning Activity: Study sensory system medical terms discussed in this chapter using these

flashcards.



An interactive H5P element has been excluded from this version of the text. You can view it online here:

<https://wtcs.pressbooks.pub/medterm/?p=401#h5p-191>

Interactive Learning Activity: Check your knowledge of sensory system terminology.



An interactive H5P element has been excluded from this version of the text. You can view it online here:

<https://wtcs.pressbooks.pub/medterm/?p=401#h5p-74>

Interactive Learning Activity: Using the sample documentation provided, drag the terms on the right to their appropriate spaces within the documentation.



An interactive H5P element has been excluded from this version of the text. You can view it online here:

<https://wtcs.pressbooks.pub/medterm/?p=401#h5p-71>

Interactive Learning Activity: Using the sample documentation provided, drag the terms on the right to their appropriate spaces within the documentation.



An interactive H5P element has been excluded from this version of the text. You can view it

online here:

<https://wtcs.pressbooks.pub/medterm/?p=401#h5p-72>



Interactive Learning Activity: Practice identifying and defining word parts for terms discussed in this chapter.



An interactive H5P element has been excluded from this version of the text. You can view it online here:

<https://wtcs.pressbooks.pub/medterm/?p=401#h5p-210>

- ▶ You can also print this as a [Chapter 15 Practice Worksheet](#) and check your answers with this [Answer Key PDF](#).

15.8 Glossary

Amblyopia (am-blē-Ō-pē-ă): Often called “lazy eye,” a vision development disorder where an eye fails to achieve normal visual acuity. ([Chapter 15.5](#))

Anosmia (a-NŌZ-mē-ă): Loss or impairment of the sense of smell, which can be temporary or permanent. ([Chapter 15.5](#))

Astigmatism (ă-STIG-mă-tizm): A vision condition that causes blurred vision due to the irregular curvature of the cornea or lens. ([Chapter 15.5](#))

Audiogram (AW-dē-ō-gram): A graphic record of the results of a hearing test, typically showing hearing sensitivity at different frequencies. ([Chapter 15.6](#))

Audiologists (aw-dē-OL-ŏ-jĭsts): Health care professionals specializing in diagnosing, managing, and treating hearing or balance problems. ([Chapter 15.6](#))

Audiology (aw-dē-OL-ŏ-jē): The study of hearing. ([Chapter 15.6](#))

Audiometer (aw-dē-OM-ĕt-ĕr): An electronic device used in audiometry to generate pure tones of controlled intensity for hearing testing. ([Chapter 15.6](#))

Audiometry (aw-dē-OM-ĕ-trē): The testing of a person’s hearing ability, usually by producing sounds of different frequencies and intensities. ([Chapter 15.6](#))

Auricle (AW-rĭ-kl): The large fleshy structure on the lateral aspect of the head, directing sound waves into the ear canal. ([Chapter 15.4](#))

Cataract (KAT-ă-rakt): A progressive disease of the lens causing cloudiness and lack of transparency, leading to vision impairment. ([Chapter 15.5](#))

Cerumen impaction (sĕ-ROO-mĕn Im-PĂK-shŭn): The buildup of earwax (cerumen) in the ear canal, which can lead to symptoms such as hearing loss, tinnitus, or discomfort. ([Chapter 15.5](#))

Cochlea (KŌK-lē-ă): A part of the inner ear involved in hearing; it converts sound waves into neural signals. ([Chapter 15.4](#))

Conductive hearing loss (kŏn-DUC-tĭv HĒR-ing LŌS): Hearing loss caused by problems with the ear canal, eardrum, or middle ear and its little bones (the malleus, incus, and stapes). ([Chapter 15.5](#))

Conjunctiva (kǒn-jǔnk-TI-va): The inner surface of each lid, a thin membrane that extends over the white areas of the eye called the sclera, connecting the eyelids to the eyeball. ([Chapter 15.4](#))

Conjunctivitis (kǒn-jǔnk-tǐ-VĪT-ĭs): An infection or inflammation of the conjunctiva, causing redness, swelling, and often discharge in the eye. ([Chapter 15.5](#))

Cornea (KOR-nē-ă): The transparent front part of the eye covering the iris, pupil, and anterior chamber, playing a key role in focusing vision. ([Chapter 15.4](#))

Diabetic retinopathy (ret-ĭn-OP-ă-thē): A complication of diabetes mellitus causing fluid leakage from blood vessels in the retina, leading to vision impairment. ([Chapter 15.5](#))

Eustachian tube (yōō-STĀ-shən tūb): A tube connecting the middle ear to the pharynx, helping equalize air pressure across the tympanic membrane. ([Chapter 15.4](#))

Glaucoma (glăw-KŌ-mă): A group of eye conditions that damage the optic nerve, often caused by abnormally high pressure in the eye. ([Chapter 15.5](#))

Hyperopia (hī-pěr-Ō-pē-ă): Also known as farsightedness, a condition where distant objects can be seen more clearly than close ones. ([Chapter 15.5](#))

Incus (ĪN-kŭs): A small anvil-shaped bone in the middle ear, connecting the malleus to the stapes. ([Chapter 15.4](#))

Inner ear (IN-er ĒR): The part of the ear that includes the cochlea, vestibule, and semicircular canals, responsible for processing sound and maintaining balance. ([Chapter 15.4](#))

Iris (IR-ĭs): The colored part of the eye, a smooth muscle that controls the diameter and size of the pupil. ([Chapter 15.4](#))

Lacrimal gland (LAK-rĭ-măĭ glănd): A gland located beneath the lateral edges of the nose that produces tears. ([Chapter 15.4](#))

Legal blindness (LĒ-găĭ BLĪND-nĕss): A defined level of visual impairment that has been established as a threshold for eligibility for governmental disability benefits; typically, visual acuity of 20/200 or less in the best-corrected eye. ([Chapter 15.5](#))

Low vision (LŌ VIZH-ŭn): A condition where an individual has significant visual impairment that cannot be fully corrected with standard glasses,

contact lenses, medicine, or surgery, and which interferes with daily activities. ([Chapter 15.5](#))

Macular degeneration (MĀK-yŭ-lǎr Dě-gĕn-ě-RĀ-shŭn): A common eye condition among older adults that leads to loss of vision in the center of the visual field (the macula) due to damage to the retina. ([Chapter 15.5](#))

Malleus (MĀL-ē-ŭs): A small bone in the middle ear attached to the tympanic membrane, resembling a hammer. ([Chapter 15.4](#))

Myopia (mī-Ō-pē-ă): Also known as nearsightedness, a common vision condition where distant objects appear blurry. ([Chapter 15.5](#))

Myringotomy (mŭr-ĭn-GŎT-ō-mē): A surgical procedure where a small incision is made in the eardrum to relieve pressure or drain fluid. ([Chapter 15.5](#))

Nyctalopia (nik-ta-LŌ-pē-ă): Poor vision at night or in dimly lit environments, commonly known as night blindness. ([Chapter 15.5](#))

Nystagmus (nŭs-TĀG-mŭs): Involuntary rhythmic movement of the eyes, which can impair vision and affect balance. ([Chapter 15.5](#))

Ophthalmologist (ŏp-thăl-MŎL-ō-jŭst): A physician who specializes in diagnosing and treating eye disorders and performing eye surgery. ([Chapter 15.6](#))

Ophthalmoscope (op-THAL-mŏ-skŏp): An instrument used to examine the interior structures of the eye. ([Chapter 15.6](#))

Ophthalmoscopy (op-thal-MOS-kŏ-pē): The examination of the interior of the eye, particularly the retina, using an ophthalmoscope. ([Chapter 15.6](#))

Optic nerve (OP-tik nerv): The nerve that transmits visual information from the retina to the brain. ([Chapter 15.4](#))

Opticians (ŏp-TĪSH-ăns): Technicians who design, verify, and fit eyeglass lenses and frames, contact lenses, and other devices to correct eyesight. ([Chapter 15.6](#))

Optometrist (ŏp-TŎM-ě-trĭst): A health care professional who examines eyes for vision and health problems and prescribes corrective lenses. ([Chapter 15.6](#))

Otitis externa (ō-TĪ-tĭs eks-TUR-nă): Inflammation or infection of the outer ear canal, often referred to as “swimmer’s ear.” ([Chapter 15.5](#))

Otitis media (ō-TĪ-tĭs MĒ-dē-ă): Inflammation or infection of the middle ear,

common in children and often associated with upper respiratory infections. ([Chapter 15.5](#))

Otolaryngologist (ō-tō-lăr-ĭn-GŎL-ō-jĭst): A physician who specializing in ear, nose, and throat disorders, also known as an ENT doctor. ([Chapter 15.6](#))

Otology (ō-TŎL-ō-jē): The study of the ear and its diseases. ([Chapter 15.6](#))

Otosclerosis (ō-tō-sklĕ-RŌ-sĭs): A hearing loss condition caused by abnormal bone growth in the middle ear. ([Chapter 15.5](#))

Otoscope (Ō-tō-skōp): An instrument used for visual examination of the ear canal and tympanic membrane. ([Chapter 15.5](#), [Chapter 15.6](#))

Otoscopy (ō-TŎS-kō-pē): The examination of the ear canal and eardrum with an otoscope. ([Chapter 15.6](#))

Pinna (PĪN-ă): Another term for the auricle, the visible part of the ear that resides outside of the head. ([Chapter 15.4](#))

Presbycusis (prez-bĭ-KŪ-sĭs): Age-related hearing loss, often due to gradual nerve degeneration and other changes in the inner ear. ([Chapter 15.5](#))

Presbyopia (prez-bĭ-Ō-pē-ă): An age-related condition in which the ability to focus on close objects decreases over time. ([Chapter 15.5](#))

Pupil (PŪ-pĭl): The hole at the center of the eye that allows light to enter, its size is controlled by the iris. ([Chapter 15.4](#))

Retina (RĚT-ĭ-nă): The innermost layer of the eye, containing photoreceptors and nerve cells for initial processing of visual stimuli. ([Chapter 15.4](#))

Sclera (sklĕr-ă): The white, outer layer of the eyeball that extends from the cornea to the optic nerve at the back of the eye. ([Chapter 15.4](#))

Sensorineural hearing loss (sĕn-sō-rĕ-NOOR-ăĭ HĒR-ing LŎS): A type of hearing loss resulting from damage to the inner ear (cochlea) or to the nerve pathways from the inner ear to the brain. ([Chapter 15.5](#))

Stapedectomy (stā-pĕ-DEK-tŏ-mē): A surgical procedure to remove part or all of the stapes bone and replace it with a prosthesis to improve hearing. ([Chapter 15.5](#))

Stapes (STĀ-pēz): A stirrup-shaped bone in the middle ear, attached to the inner ear where sound waves are converted into neural signals. ([Chapter 15.4](#))

Strabismus (stră-BĪZ-mŭs): A condition where the eyes do not properly align with each other when looking at an object. ([Chapter 15.5](#))

Stye (STĭ): An infection of an oil gland in the eyelid, leading to a painful, red swelling on the eyelid. ([Chapter 15.5](#))

Tinnitus (tĭ-Nĭ-tŭs): A condition characterized by hearing ringing, buzzing, or other noises in the ear in the absence of external sound. ([Chapter 15.5](#))

Total blindness (TŌ-tāl BLĪND-nĕss): The complete absence of visual perception, characterized by the inability to perceive light or discern any visual images. ([Chapter 15.5](#))

Tympanic membrane (tĭm-PĀN-ik MEM-brān): Also known as the eardrum, it vibrates in response to sound waves. ([Chapter 15.4](#))

Vertigo (VUR-tĭ-gō): A sensation of spinning or dizziness, often caused by issues with the inner ear or vestibular system. ([Chapter 15.4](#), [Chapter 15.5](#))

Vestibule (ves-tĭ-bŭl): A part of the inner ear that contributes to balance and spatial orientation. ([Chapter 15.4](#))

Vestibulocochlear nerve (vēs-tĭ-bŭl-ō-KŌ-klē-ār nerv): The nerve that carries auditory and balance information from the inner ear to the brain. ([Chapter 15.4](#))

Visual acuity (VIZH-u-āl ā-KŪ-ĭt-ē): The sharpness or clearness of vision, typically measured with a Snellen chart. ([Chapter 15.5](#), [Chapter 15.6](#))

Visual impairment (VIZH-ŭ-al Im-PĀR-mĕnt): A decrease in the ability to see to a significant degree, which may cause problems not fixable by usual means, such as glasses or medication. ([Chapter 15.5](#))

PART XVI

CHAPTER 16 NERVOUS SYSTEM TERMINOLOGY

16.1 Nervous System Introduction

Learning Objectives


- Apply the rules of medical language to build, analyze, spell, pronounce, abbreviate, and define terms as they relate to the nervous system
- Identify meanings of key word components of the nervous system
- Categorize diagnostic, therapeutic, procedural, or anatomic terms related to the nervous system
- Use terms related to the nervous system
- Use terms related to the diseases and disorders of the nervous system

Introduction to the Nervous System

The nervous system includes the brain, the spinal cord, and a complex system of nerves. It uses electrical signals and chemical substances called neurotransmitters for communication across body parts.

This chapter will review common word components related to the nervous system to assist learners in analyzing, building, and defining medical terms. Other terms, whose definitions cannot be easily built from word components, will be described in context based on the anatomy and physiology of the nervous system and common diseases and disorders. Medical specialists,

diagnostic tests, and procedures related to the nervous system will also be discussed.

View a supplementary YouTube video¹ on the nervous
 system by Crash Course: [The Nervous System, Part 1: Crash Course Anatomy & Physiology #8](https://www.youtube.com/watch?v=qPix_X-9t7E)

1. CrashCourse. (2015, February 23). *The nervous system, Part 1: Crash Course Anatomy & Physiology #8* [Video]. YouTube. All rights reserved. https://www.youtube.com/watch?v=qPix_X-9t7E

16.2 Word Components Related to the Nervous System

This section will describe common word components related to the nervous system. These word components help build definitions for many medical terms. Other common prefixes are described in [Chapter 1.3](#), and common suffixes are described in [Chapter 1.5](#).

PREFIXES RELATED TO THE NERVOUS SYSTEM

- **a-**: Absence of, without, no, not
- **an-**: Absence of, without, no, not
- **dys-**: Abnormal, difficult, labored
- **hemi-**: Half
- **hyper-**: Above, excessive
- **inter-**: Between
- **intra-**: Within
- **pan-**: All, total
- **para-**: Beside, beyond, around, abnormal
- **poly-**: Many, much
- **post-**: After
- **pre-**: Before
- **sub-**: Below, under

WORD ROOTS WITH COMBINING VOWELS RELATED TO THE NERVOUS SYSTEM

- **alges/o**: Sensitivity to pain
- **cephal/o**: Head
- **cerebell/o**: Cerebellum
- **cerebr/o**: Cerebrum
- **dur/o**: Dura mater, hard
- **encephal/o**: Brain
- **esthesi/o**: Sensation, sensitivity
- **gangli/o**: Ganglion
- **ganglion/o**: Ganglion
- **gli/o**: Glia, gluey substance
- **mening/o**: Meninges
- **meningi/o**: Meninges
- **ment/o**: Mind
- **mon/o**: One, single
- **myel/o**: Spinal cord
- **neur/o**: Nerve
- **phas/o**: Speech
- **poli/o**: Gray matter
- **pont/o**: Pons (structure in the brain)
- **psych/o**: Mind
- **quadr/i**: Four
- **radic/o**: Nerve root
- **radicul/o**: Nerve root
- **rhiz/o**: Nerve root
- **thalam/o**: Thalamus
- **thec/o**: Sheath
- **vag/o**: Vagus nerve

SUFFIXES RELATED TO THE NERVOUS SYSTEM

- **-al**: Pertaining to
- **-algia**: Pain
- **-algesia**: Sensitivity to pain
- **-cele**: Hernia, protrusion
- **-cyte**: Cell
- **-ectomy**: Excision, surgical removal, cutting out
- **-genic**: Producing, originating, causing
- **-gram**: The record, radiographic image
- **-graph**: Instrument used to record
- **-graphy**: Process of recording, radiographic imaging
- **-ia**: Condition of, diseased state or abnormal state
- **-ic**: Pertaining to
- **-iatrist**: Specialist, physician
- **-iatry**: Specialty, treatment
- **-ictal**: Seizure, attack
- **-itis**: Inflammation
- **-lepsy**: Seizure
- **-logist**: Specialist who studies and treats
- **-logy**: Study of
- **-lysis**: Loosening, dissolution, separating
- **-malacia**: Softening
- **-oid**: Resembling
- **-oma**: Tumor
- **-osis**: Abnormal condition
- **-paresis**: Slight paralysis
- **-pathy**: Disease
- **-phasia**: Speech
- **-plasty**: Surgical repair
- **-plegia**: Paralysis
- **-praxia**: To perform, action

- **-sclerosis:** Hardening
- **-rrhaphy:** Suturing, repairing
- **-tomy:** Incision, cut into

16.3 Examples of Nervous System Terms Easily Defined By Their Word Components

Here are examples of common medical terms related to the nervous system that can be easily defined by breaking the terms into their word components.

Encephalitis

1. Break down the medical term into word components:
Encephal/itis
2. Label the word components: **Encephal** = WR; **itis** = S
3. Define the word components: **Encephal** = brain; **itis** = inflammation
4. Create a final definition of the medical term:
Inflammation of the brain

Neuralgia

1. Break down the medical term into word components:
Neur/algia
2. Label the word components: **Neur** = WR; **algia** = S

3. Define the word components: **Neur** = nerves; **algia** = pain
4. Create a final definition of the medical term: **Nerve pain**

Psychosis

1. Break down the medical term into word components:
Psych/osis
2. Label the word components: **Psych** = WR; **osis** = S
3. Define the word components: **Psych** = mind; **osis** = abnormal condition
4. Create a final definition of the medical term: **Abnormal condition of the mind**



Interactive Learning Activity: Practice defining and pronouncing medical terms related to the nervous system by breaking them down into word parts.



An interactive H5P element has been excluded from this version of the text. You can view it online here:

<https://wtcs.pressbooks.pub/medterm/?p=6373#h5p-117>

- ▶ You can also print these flashcard activities as a [Chapter 16 Student Companion Worksheet](#) and check your answers with this [Answer Key](#).

16.4 Anatomy of the Nervous System

The nervous system is divided into two main parts called the central nervous system and the peripheral nervous system. See Figure 16.1¹ for an illustration of the nervous system.

1. “[Nervous system diagram.png](#)” by unknown is licensed under [CC BY-NC-SA 3.0](#). Access for free at [https://med.libretexts.org/Bookshelves/Nursing/Book%3A_Clinical_Procedures_for_Safer_Patient_Care_\(Doyle_and_McCutcheon\)/02%3A_Patient_Assessment/2.07%3A_Focused_Assessments](https://med.libretexts.org/Bookshelves/Nursing/Book%3A_Clinical_Procedures_for_Safer_Patient_Care_(Doyle_and_McCutcheon)/02%3A_Patient_Assessment/2.07%3A_Focused_Assessments)

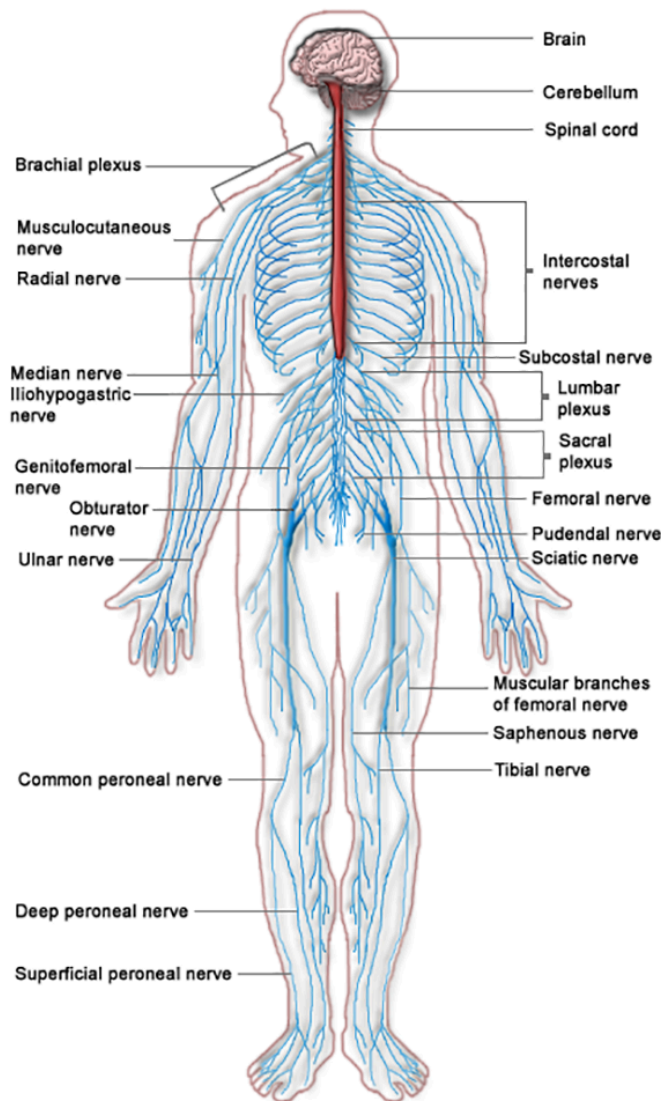


Figure 16.1 Nervous System

The Central Nervous System

The **central nervous system** (SEN-träl NŮR-vŭs SĪS-tēm) (**CNS**) includes the brain and the spinal cord. The brain can be described as the interpretation center, and the spinal cord can be described as the transmission pathway.²

2. This work is a derivative of [Anatomy & Physiology](https://openstax.org/books/anatomy-and-physiology/pages/1-introduction) by [OpenStax](https://openstax.org/books/anatomy-and-physiology/pages/1-introduction) and is licensed under [CC BY 4.0](https://creativecommons.org/licenses/by/4.0/). Access for free at <https://openstax.org/books/anatomy-and-physiology/pages/1-introduction>

Brain

The major regions of the brain are the cerebrum, cerebral cortex, hypothalamus, thalamus, brain stem, and the cerebellum.

The largest portion of our brain is called the **cerebrum** (sě-rē-brŭm). The cerebrum is covered by a wrinkled outer layer of gray matter called the **cerebral cortex** (sě-rē-brăl kôr-těks). The cerebral cortex is involved in complex brain functions including memory, attention, perceptual awareness, thought, language, and consciousness. The cerebral cortex is divided into four lobes named the frontal, parietal, occipital, and temporal lobes. Each lobe has the following specific functions³:

- **Frontal Lobe** (FRŎN-tăl lōb): The frontal lobe is associated with movement. It contains neurons that instruct cells in the spinal cord to move skeletal muscles. The anterior portion of the frontal lobe is called the **prefrontal cortex** (prē-FRŎN-tăl KÔR-těks). The prefrontal cortex provides cognitive functions such as planning and problem-solving that are the basis of our personality, short-term memory, and consciousness. **Broca's area** (brō-kăz ăr-ē-ă) is located in the frontal lobe of the dominant hemisphere and is responsible for the production of language and controlling movements responsible for speech.
- **Parietal Lobe** (pă-rī-ě-tăl lōb): The parietal lobe processes general sensations, including touch, pressure, tickle, pain, itch, and vibration.
- **Temporal Lobe** (tēm-pŏ-răl lōb): The temporal lobe processes auditory information. **Wernicke's area** (wěr-nĭk-kēz ăr-ē-ă) is located in the temporal lobe of the dominant hemisphere and is responsible for the comprehension of written and spoken language. Because regions of the temporal lobe are part of the limbic system, memory is also an important function associated with the temporal lobe. The limbic system is involved

3. This work is a derivative of [Anatomy and Physiology](#) by [OpenStax](#) licensed under [CC BY 4.0](#). Access for free at <https://openstax.org/books/anatomy-and-physiology/pages/1-introduction>

with our behavioral and emotional responses needed for survival, such as feeding, reproduction, and the fight-or-flight responses.

- **Occipital Lobe** (ŏk-SĭP-ĭ-tăl lōb): The occipital lobe primarily processes visual information.

The **cerebellum** (sĕr-ĕ-bĕl-ŭm) is the posterior part of the brain that controls fine motor skills. See Figure 16.2⁴ for an illustration of the cerebellum and the lobes of the cerebral cortex.

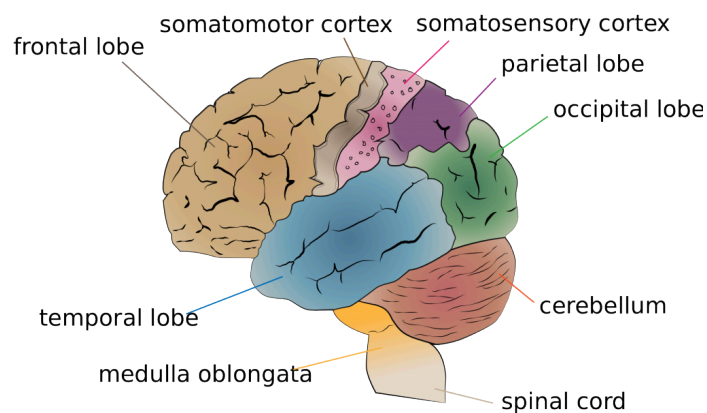


Figure 16.2 Cerebellum and Lobes of the Cerebrum

Deep within the cerebrum are the **hypothalamus** (hĭ-pō-THAL-ă-mŭs) and the **thalamus** (thăl-ă-mŭs). The hypothalamus coordinates the autonomic nervous system and the activity of the pituitary, controlling body temperature, thirst, hunger, and other homeostatic systems. The thalamus is

4. "[Cerebrum lobes.svg](#)" by [Jkwchui](#) is licensed under [CC BY-SA 3.0](#)

the relay center for sensory and motor signals to the cerebral cortex.⁵ See Figure 16.3⁶ for an illustration of the hypothalamus and the thalamus.

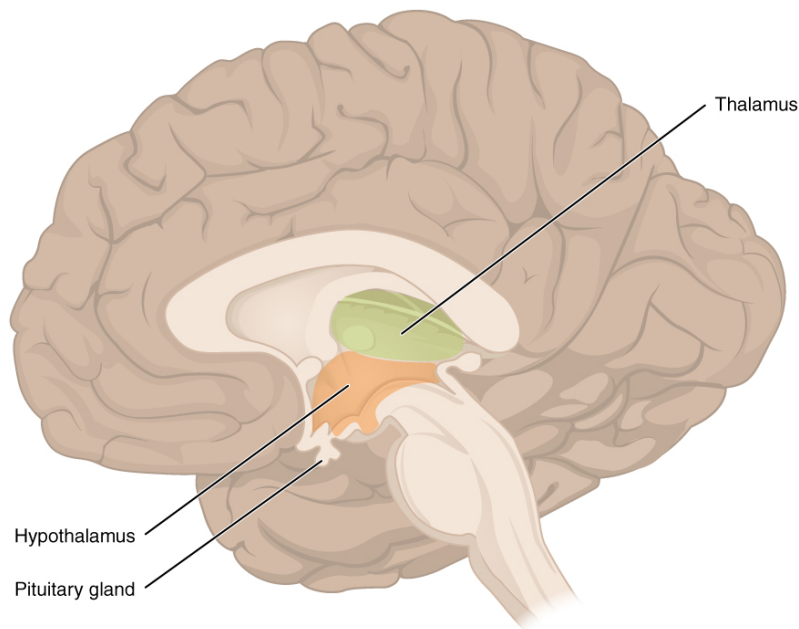


Figure 16.3 Hypothalamus and Thalamus

The **ventricles** (vĕn-trĭ-kŭls) are a group of interconnected, fluid-filled cavities within the brain. The **meninges** (mĕn-ĭn-jĕz) are three layered membranes that cover the brain and spinal cord. The **dura mater** (dŏŏ-ră mĕ-tĕr) is the tough outermost membrane enveloping the brain and spinal cord. The arachnoid layer is the web-like middle layer, and the pia mater is the delicate innermost layer of the meninges. The **brain stem** (brĕn stĕm) connects the spinal cord with the brain. It is composed of three parts, the midbrain, pons, and medulla oblongata. The brain stem regulates several crucial autonomic

5. This work is a derivative of [Anatomy and Physiology](#) by [OpenStax](#) licensed under [CC BY 4.0](#). Access for free at <https://openstax.org/books/anatomy-and-physiology/pages/1-introduction>

6. "[1310_Diencephalon.jpg](#)" by OpenStax is licensed under [CC BY 4.0](#)

functions in the body, including involuntary functions in the cardiovascular and respiratory systems and reflexes like vomiting, coughing, sneezing, and swallowing.⁷

Spinal Cord

The **spinal cord** (spī-nāl kôrd) is a bundle of nerve fibers enclosed in the spine that connects nearly all parts of the body to the brain. It is a continuation of the brain stem that transmits sensory information to the brain and motor impulses to the muscles.⁸

Peripheral Nervous System

The **peripheral nervous system** (pě-rĭF-ěr-ăl NŮR-vŭs SĪS-těm) (**PNS**) consists of the remaining parts of the nervous system outside of the brain and spinal cord, including the cranial nerves that branch out from the brain and the spinal nerves that branch out from the spinal cord. The peripheral nervous system is the communication network between the brain and the body's parts.⁹

Cranial nerves (krā-nē-ăl nĕrvz) are directly connected from the brain to the periphery. They are primarily responsible for the sensory and motor functions of the head and neck. The **vagus nerve** (vā-gŭs nĕrv) is a cranial nerve that

7. This work is a derivative of [Anatomy and Physiology](#) by [OpenStax](#) licensed under [CC BY 4.0](#). Access for free at <https://openstax.org/books/anatomy-and-physiology/pages/1-introduction>
8. This work is a derivative of [Anatomy and Physiology](#) by [OpenStax](#) licensed under [CC BY 4.0](#). Access for free at <https://openstax.org/books/anatomy-and-physiology/pages/1-introduction>
9. This work is a derivative of [Anatomy & Physiology](#) by [OpenStax](#) and is licensed under [CC BY 4.0](#). Access for free at <https://openstax.org/books/anatomy-and-physiology/pages/1-introduction>

innervates the heart and digestive system and is involved in regulating many critical bodily functions.¹⁰

Spinal nerves (spī-nāl nĕrvz) are named based on the level of the spinal cord where they emerge. See Figure 16.4¹¹ for an illustration of spinal nerves. There are eight pairs of cervical nerves designated C1 to C8, twelve thoracic nerves designated T1 to T12, five pairs of lumbar nerves designated L1 to L5, five pairs of sacral nerves designated S1 to S5, and one pair of coccygeal nerves. All spinal nerves are mixed nerves, meaning they can carry both sensory and motor information. Spinal nerves extend outward from the vertebral column to innervate the periphery while also transmitting sensory information back to the brain.¹²

10. This work is a derivative of [Anatomy and Physiology](#) by [OpenStax](#) licensed under [CC BY 4.0](#). Access for free at <https://openstax.org/books/anatomy-and-physiology/pages/1-introduction>
11. “1008694237-vector.png” by [VectorMine](#) on [Shutterstock](#). All rights reserved. Image used with purchased permission.
12. This work is a derivative of [Anatomy and Physiology](#) by [OpenStax](#) licensed under [CC BY 4.0](#). Access for free at <https://openstax.org/books/anatomy-and-physiology/pages/1-introduction>

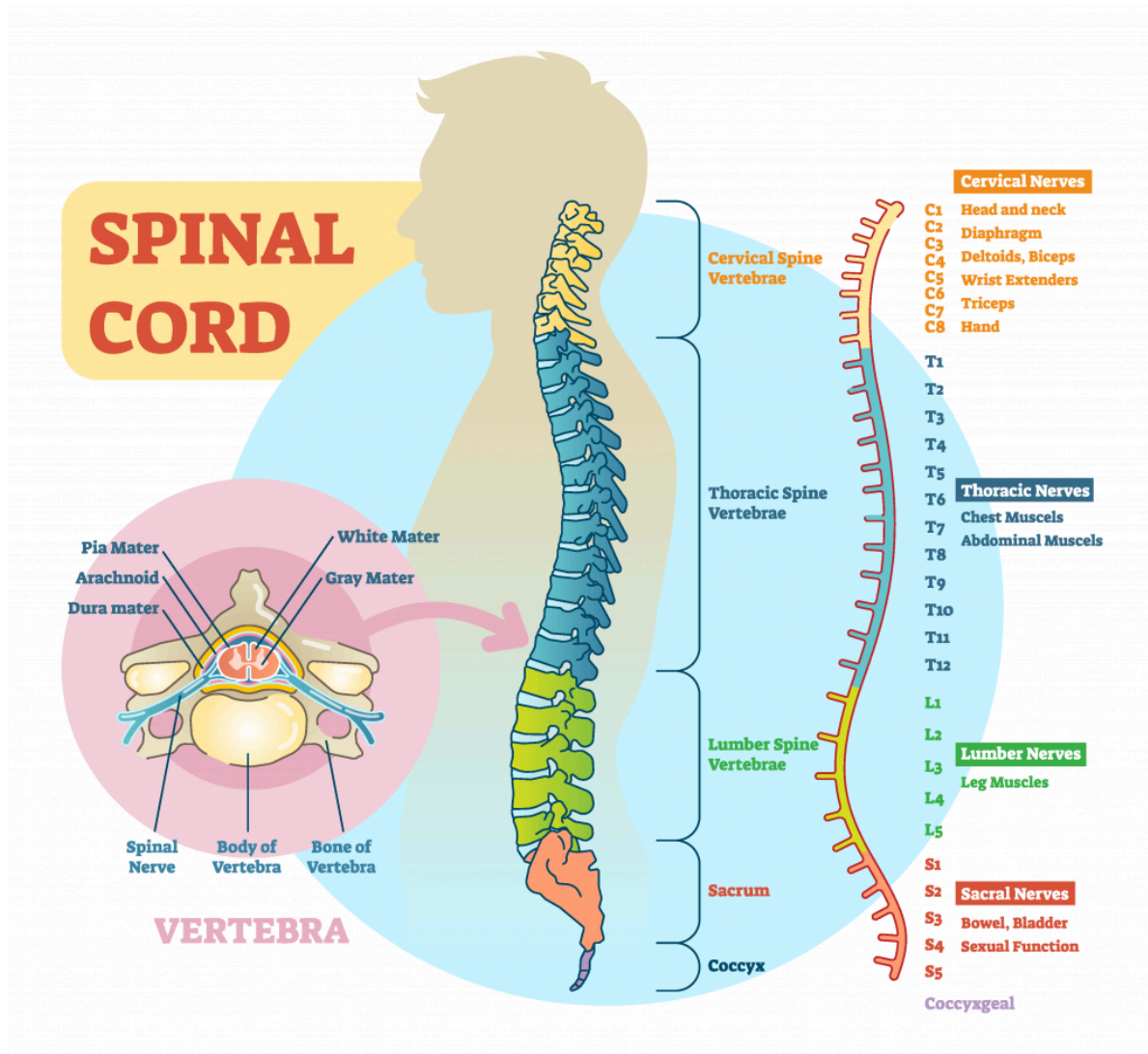


Figure 16.4 Spinal Nerves

Each spinal nerve innervates a specific region of the body¹³:

- C1 provides motor innervation to muscles at the base of the skull.
- C2 and C3 provide both sensory and motor control to the back of the head and behind the ears.
- The phrenic nerve from C3, C4, and C5 innervates the diaphragm to

13. This work is a derivative of [Anatomy and Physiology](#) by [Boundless.com](#) and is licensed under [CC BY-SA 4.0](#)

enable breathing. This is vital because if a patient has an injury where the spinal cord is cut above C3, then spontaneous breathing is not possible.

- C5 through C8 and T1 combine to form the brachial plexus, a tangled array of nerves that serve the upper limbs and upper back.
- The lumbar plexus arises from L1-L5 and innervates the pelvic region and the anterior legs.
- The sacral plexus comes from the lower lumbar nerves L4 and L5 and the sacral nerves S1 to S4. The sciatic nerve is a part of the sacral plexus. If the sciatic nerve becomes compressed due to degeneration of an intervertebral disc, a medical condition called **sciatica** (sī-ăt-ĭ-kă) occurs that causes pain in the back, hip, and outer side of the leg.

If a patient experiences a spinal cord injury, the degree of paralysis can be predicted by the location of the spinal cord injury. The higher up on the spinal cord an injury occurs, the greater loss of function. For example, a spinal cord injury higher on the spinal cord can cause paralysis in most of the body and affect all limbs (tetraplegia or quadriplegia). An injury that occurs lower on the spinal cord may only affect a person's lower body and legs (paraplegia).

Review information about paralysis in "[Diseases and Disorders of the Musculoskeletal System](#)" section of the Musculoskeletal System chapter.

It is also important to remember when a patient has a spinal cord injury and motor nerves are damaged, their sensory nerves may still be intact. If this occurs, the patient can still feel sensation even if they can't move the extremity.

NEURONS

Nervous tissues present in both the CNS and PNS contain two basic types of cells: neurons and neuroglia (glial cells). **Neurons** (nŭr-ŏns) are responsible for the communication that the nervous system provides. They are electrically

active and release chemical signals called neurotransmitters. Neuroglia plays a supporting role for nervous tissue.¹⁴

Neurons provide electrical signals that communicate information about sensations and, in response, stimulate movements. The three-dimensional shape of neurons makes massive numbers of connections within the nervous system. The main part of a neuron is the **cell body** (sěl bōd-ē). A fiber that emerges from the cell body and projects to target cells is called the **axon** (āk-sōn). A single axon can branch repeatedly to communicate with many target cells by sending nerve impulses. **Dendrites** (dēn-drīt-z) conduct information received from other neurons at contact areas called a **synapse** (sīn-āps). A synapse is a junction between two nerve cells, consisting of a tiny gap through which neurotransmitters pass.¹⁵ See Figure 16.5¹⁶ for an illustration of a neuron.

14. This work is a derivative of [Anatomy & Physiology](#) by [OpenStax](#) and is licensed under [CC BY 4.0](#). Access for free at <https://openstax.org/books/anatomy-and-physiology/pages/1-introduction>

15. This work is a derivative of [Anatomy and Physiology](#) by [OpenStax](#) licensed under [CC BY 4.0](#). Access for free at <https://openstax.org/books/anatomy-and-physiology/pages/1-introduction>

16. "[1206_The_Neuron-1.jpg](#)" by OpenStax is licensed under [CC BY 4.0](#)

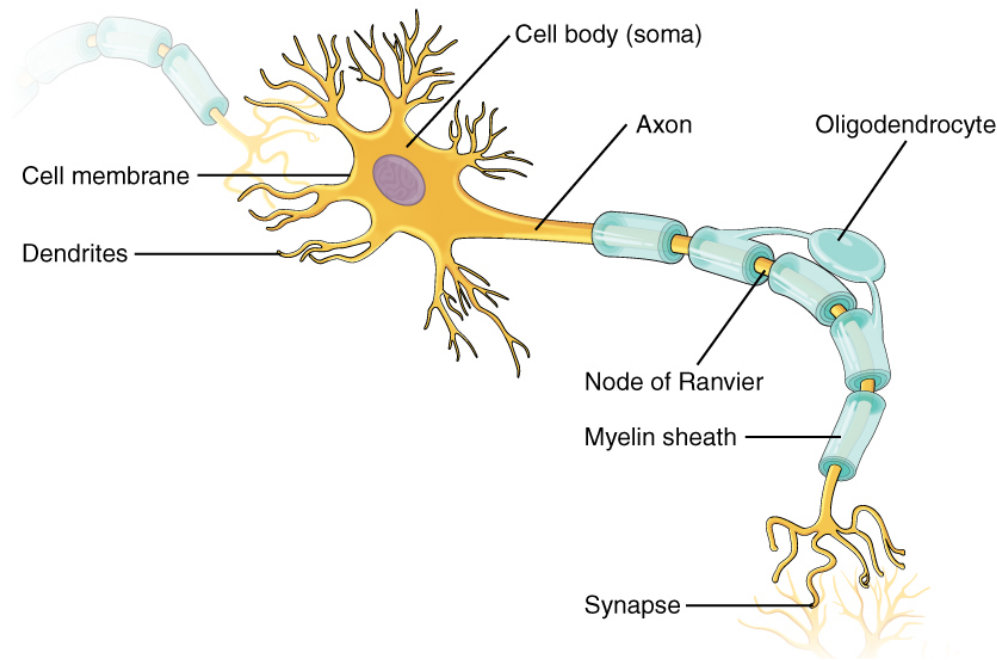


Figure 16.5 Neuron

Many axons are wrapped by an insulating substance called **myelin** (mī-ě-līn), which is made from neuroglia. Myelin acts as insulation much like the plastic or rubber that is used to insulate electrical wires.¹⁷

NEUROTRANSMITTERS

Electrical impulses from neurons signal the release of a **neurotransmitter** (nŭr-ō-trăns-mīt-ěr) into a synapse. Neurotransmitters allow the impulse to be transferred to a neuroreceptor on another neuron, muscle fiber, or other structure. Neuroreceptors are specific for certain neurotransmitters, and the

¹⁷ This work is a derivative of [Anatomy and Physiology](https://openstax.org/books/anatomy-and-physiology/pages/1-introduction) by OpenStax licensed under [CC BY 4.0](https://creativecommons.org/licenses/by/4.0/). Access for free at <https://openstax.org/books/anatomy-and-physiology/pages/1-introduction>

two fit together like a key and lock.¹⁸ See Figure 16.6¹⁹ for an illustration of neuron communication.

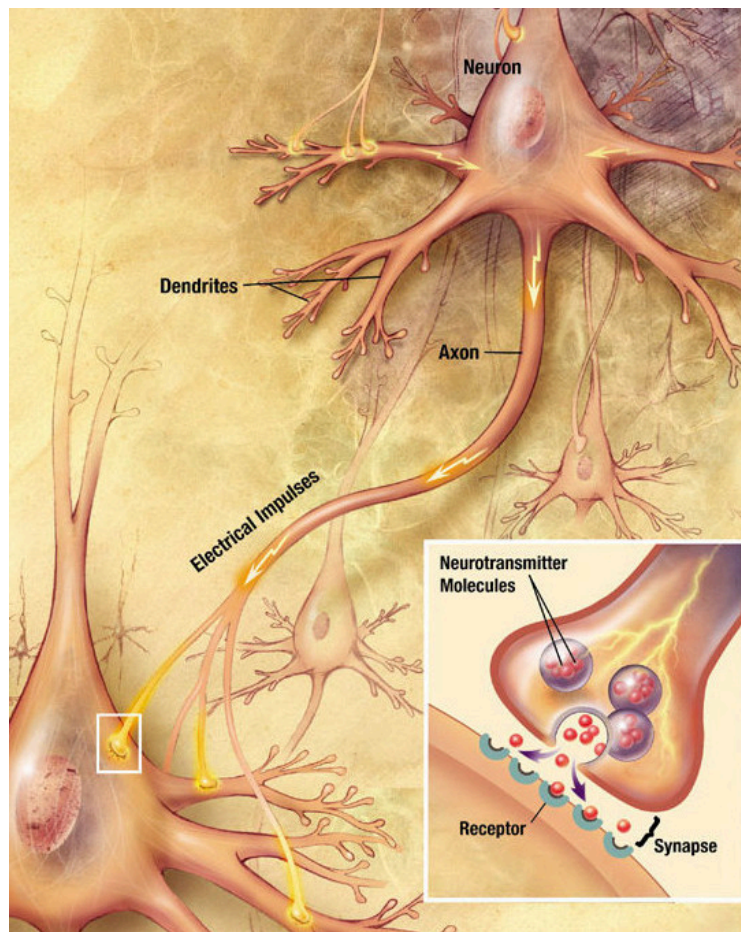


Figure 16.6 Neuron Communication

- ¹⁸. This work is a derivative of [Anatomy and Physiology](#) by [OpenStax](#) licensed under [CC BY 4.0](#). Access for free at <https://openstax.org/books/anatomy-and-physiology/pages/1-introduction>
- ¹⁹. “[Chemical synapse schema cropped.jpg](#)” by [Looie496](#) is licensed under [Public Domain](#). Access for free at [https://med.libretexts.org/Bookshelves/Anatomy_and_Physiology/Book%3A_Anatomy_and_Physiology_\(Boundless\)/10%3A_Overview_of_the_Nervous_System/10.1%3A_Introduction_to_the_Nervous_System/10.1A%3A_Organization_of_the_Nervous_System](https://med.libretexts.org/Bookshelves/Anatomy_and_Physiology/Book%3A_Anatomy_and_Physiology_(Boundless)/10%3A_Overview_of_the_Nervous_System/10.1%3A_Introduction_to_the_Nervous_System/10.1A%3A_Organization_of_the_Nervous_System)

Many nervous system diseases and mental health disorders are related to abnormal impulse transmission and/or imbalanced levels of neurotransmitters. For example, dopamine is a neurotransmitter that influences movement and cognition. Dopamine imbalances are associated with Parkinson's disease, schizophrenia, and substance use disorders. Serotonin is another type of neurotransmitter whose imbalance affects moods and feelings of depression. Medications used to treat many mental health disorders help balance neurotransmitter levels.²⁰

20. This work is a derivative of Open RN [Nursing Pharmacology 2e](#) and Open RN [Nursing Skills 2e](#) both licensed under [CC BY 4.0](#)

16.5 Physiology of the Nervous System

MAJOR FUNCTIONS OF THE NERVOUS SYSTEM

Three main functions of the nervous system are sensation, response, and integration.¹

Sensation

The first major function of the nervous system is sensation (i.e., receiving information about what is happening within or outside the body). Our five senses receive sensations from the outside world, and various receptors within the body receive internal sensations.²

1. This work is a derivative of Anatomy & Physiology by [OpenStax](#) and is licensed under [CC BY 4.0](#). Access for free at <https://openstax.org/details/books/anatomy-and-physiology-2e>
2. This work is a derivative of [Anatomy and Physiology](#) by [OpenStax](#) licensed under [CC BY 4.0](#). Access for free at <https://openstax.org/books/anatomy-and-physiology/pages/1-introduction>

Read more information about the five senses in the “[Sensory System Terminology](#)” chapter.

Paresthesia (par-es-THĒ-zh(ē-)ă) refers to an abnormal sensation in the extremities (i.e., numbness, tingling, and pain), and **anesthesia** (an-ēs-THĒ-zhă) refers to a lack of feeling or sensation.

Response

The nervous system produces a response based on sensations received. For example, if our hand accidentally touches a hot stove, the nervous system automatically and quickly moves the hand away. Responses can be classified as voluntary (such as contraction of skeletal muscle) and involuntary (such as contraction of smooth muscles, regulation of cardiac muscle, and activation of endocrine glands).³

Voluntary responses are governed by the somatic nervous system, and involuntary responses are governed by the autonomic nervous system. The somatic nervous system is responsible for conscious perception, senses, and voluntary motor responses. An example of the somatic nervous system is when a person purposefully takes deep breaths to quell feelings of anxiety.⁴

The autonomic nervous system (ANS) is responsible for involuntary regulation of body processes to maintain homeostasis. For example, sweat

3. This work is a derivative of [Anatomy and Physiology](#) by [OpenStax](#) licensed under [CC BY 4.0](#). Access for free at <https://openstax.org/books/anatomy-and-physiology/pages/1-introduction>

4. This work is a derivative of [Anatomy and Physiology](#) by [OpenStax](#) licensed under [CC BY 4.0](#). Access for free at <https://openstax.org/books/anatomy-and-physiology/pages/1-introduction>

glands are controlled by the autonomic nervous system. When a person receives the sensation of feeling hot, the ANS system processes this information and automatically creates a response of sweating to help cool down the body.⁵

The autonomic nervous system is further divided into the sympathetic nervous system and the parasympathetic nervous system. The sympathetic nervous system is responsible for “fight or flight” responses, and the parasympathetic nervous system controls rest and digestive functions.⁶

Integration

Stimuli are interpreted and acted upon by the brain during a process referred to as integration. The brain analyzes stimuli with other perceived stimuli, memories of previous stimuli, or the person’s emotional state and generates a specific response. For example, a person may receive an internal sensation from the bladder for the need to urinate. However, the brain analyzes that stimulus and integrates it with the awareness of being in a public area and postpones the response to urinate until there is time to locate a nearby restroom.⁷

5. This work is a derivative of [Anatomy and Physiology](#) by [OpenStax](#) licensed under [CC BY 4.0](#). Access for free at <https://openstax.org/books/anatomy-and-physiology/pages/1-introduction>
6. This work is a derivative of [Anatomy and Physiology](#) by [OpenStax](#) licensed under [CC BY 4.0](#). Access for free at <https://openstax.org/books/anatomy-and-physiology/pages/1-introduction>
7. This work is a derivative of [Anatomy and Physiology](#) by [OpenStax](#) licensed under [CC BY 4.0](#). Access for free at <https://openstax.org/books/anatomy-and-physiology/pages/1-introduction>

HIGHER MENTAL FUNCTIONS

The cerebral cortex performs higher mental functions referred to as cognitive abilities. The responsibilities for these cognitive abilities are distributed across regions of the cortex, and specific locations can be said to be responsible for particular functions. For this reason, if a particular area of the brain becomes injured or diseased, specific cognitive abilities are affected.⁸

Cognitive abilities can be classified by four areas: orientation and memory, language and speech, sensorium, and judgment and abstract reasoning⁹:

- **Orientation and Memory:** **Orientation** (or-ē-ĕn-TĀ-shŏn) is the patient's awareness of their immediate circumstances. In the medical field, this is typically referred to as "being oriented to person, place, and time." An adult with normal cognitive functioning is aware of their name, where they are and why, and the date. This function occurs in the prefrontal cortex, and it can be temporarily or permanently affected by many medical conditions. **Memory** (MĕM-ŏ-rē) refers to how the brain stores and remembers information. It is a function of the temporal lobe.
- **Language** (LĀNG-gwij) **and Speech** (spēch): Wernicke's area and Broca's area are involved in speech and language. See Figure 16.7¹⁰ for an illustration of the location of Wernicke's area and Broca's area in the brain. Both areas are found in a person's dominant hemisphere, which for most

8. This work is a derivative of [Anatomy and Physiology](#) by [OpenStax](#) licensed under [CC BY 4.0](#). Access for free at <https://openstax.org/books/anatomy-and-physiology/pages/1-introduction>

9. This work is a derivative of [Anatomy and Physiology](#) by [OpenStax](#) licensed under [CC BY 4.0](#). Access for free at <https://openstax.org/books/anatomy-and-physiology/pages/1-introduction>

10. "[1605_Brocas_and_Wernickes_Areas-02.jpg](#)" by OpenStax College is licensed under [CC BY 3.0](#)

people is the left side of the brain. **Aphasia** (ă-FĀ-zh-ē-ă) is the inability to speak. Aphasia associated with Broca's area is known as an **expressive aphasia** (eks-PRĒS-iv ă-FĀ-zh-ē-ă), which means that speech production is compromised, leading to broken, slow, or hesitant speech. **Receptive aphasia** (rĭ-SEP-tiv ă-FĀ-zh-ē-ă) is associated with Wernicke's area, which is a loss of understanding of speech content.

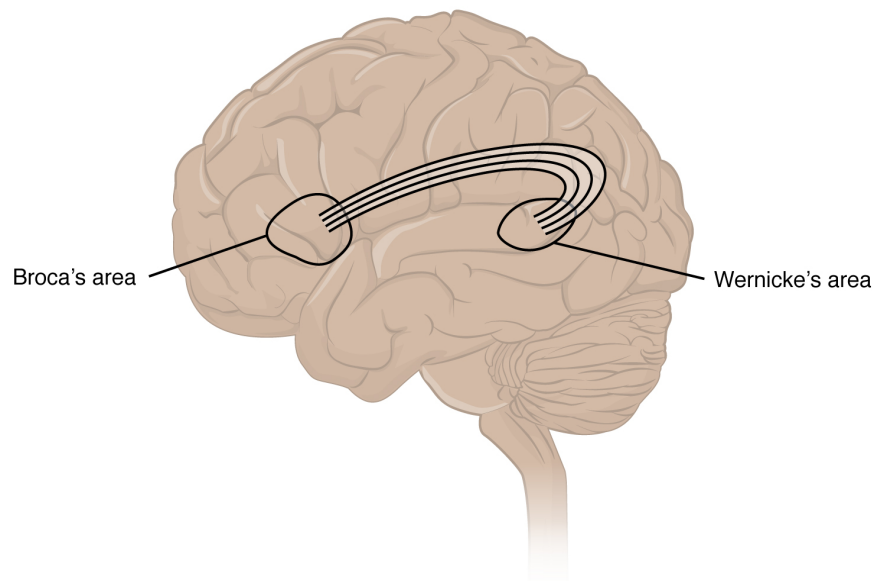


Figure 16.7 Broca's Area and Wernicke's Area

- **Sensorium** (sĕn-SAWR-ē-ŭm): Sensorium refers to interpretation of sensory stimuli, as previously discussed in this section. The cerebral cortex has several regions responsible for sensory perception.
- **Abstract reasoning** (ăb-străkt RĒ-zŏn-ĭng) **and judgment** (JŬJ-mĕnt): Abstract reasoning and judgment refer to making sense of concepts and making appropriate decisions. For example, when your alarm goes off in the morning, you must decide whether to hit the snooze button or jump out of bed. You use judgement and abstract reasoning to decide if the ten extra minutes of sleep is worth rushing through your morning routine or risking being late. The decision you make can potentially impact the rest of your day. The prefrontal cortex is responsible for these functions of planning and making decisions.¹¹

11. This work is a derivative of [Anatomy and Physiology](#) by [OpenStax](#) licensed under [CC BY 4.0](#). Access for free at <https://openstax.org/books/anatomy-and-physiology/pages/1-introduction>

16.6 Diseases and Disorders of the Nervous System

AMYOTROPHIC LATERAL SCLEROSIS

Amyotrophic lateral sclerosis (ā-mī-ō-TRŎF-ik LĀT-ěr-ăl sklě-RŎ-sīs) (**ALS**), also known as Lou Gehrig's disease, is a neurological disorder that affects motor neurons and the control of voluntary muscle movement and breathing. As motor neurons degenerate and die, they stop sending messages to the muscles, causing them to weaken, twitch, and shrink. Eventually, the brain loses its ability to control voluntary movements, such as walking, talking, chewing, and breathing. However, cognitive abilities are not affected. Medications are available that may prolong survival, reduce the rate of decline, or help manage symptoms, but there is no known treatment to cure ALS.¹

ALZHEIMER'S DISEASE

Alzheimer's disease (ălts-hī-měrz dĩ-zēz) (**AD**) is a common neurological disorder that causes worsening cognitive abilities and the inability to

1. National Institute of Neurological Disorders and Stroke. (2023, November 28). *Amyotrophic lateral sclerosis*. National Institutes of Health. <https://www.ninds.nih.gov/health-information/disorders/amyotrophic-lateral-sclerosis-als>

remember and make decisions. An estimated 6.7 million Americans aged 65 and older are living with Alzheimer's disease, and over 33% of people aged 85 or older have Alzheimer's disease. AD is caused by a type of protein that abnormally clumps together and damages healthy neurons. As the neurons die, the brain irreversibly shrinks and progressively loses more function.² See Figure 16.8³ for an illustration comparing a healthy brain to one that has shrunk due to severe Alzheimer's disease.

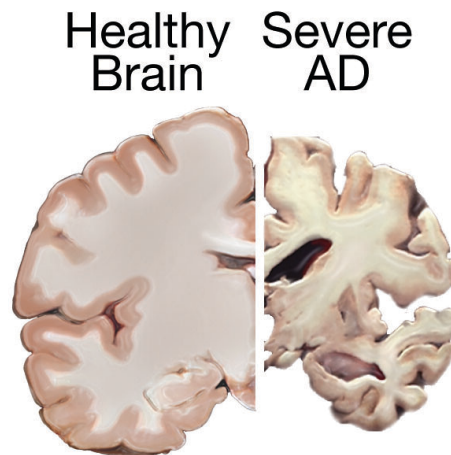


Figure 16.8 Comparison of Healthy Brain Tissue to Severe Alzheimer's Disease

AD develops over many years before memory problems occur. AD gradually causes behavior and personality changes, difficulty recognizing family and friends, and a severe loss of mental function. People with severe AD cannot communicate and are completely dependent on others for their care. There

2. Alzheimer's Association. (2023). *Alzheimer's disease: Facts and figures*. <https://www.alz.org/alzheimers-dementia/facts-figures>

3. "Broca's Area and Wernicke's Area" by NIH Image Gallery from Bethesda, Maryland, USA is licensed in the [Public Domain](#).

are no treatments that can stop the progression of AD, but medications can temporarily slow its worsening.⁴

ATTENTION DEFICIT HYPERACTIVITY DISORDER

Attention deficit hyperactivity disorder (ă-těn-shŭn dĕf-ĭ-sĭt hĭ-pĕr-ăk-tĭv-ĭ-tē dĭs-ôr-dĕr) (**ADHD**) is a neurodevelopmental disorder that is typically diagnosed in childhood and often lasts into adulthood. Children with ADHD may have trouble paying attention, controlling impulsive behaviors (i.e., act without thinking about what the result will be), or being overly active. ADHD is treated with a combination of behavior therapy and medication.⁵

CARPAL TUNNEL SYNDROME

Carpal tunnel syndrome (KÄR-păl TŬN-ĕl SĬN-drôm) is a common neurological disorder that occurs when the median nerve, which runs from the forearm into the palm of the hand, becomes pressed or squeezed at the wrist. The median nerve passes through the carpal tunnel, a narrow, rigid passageway of ligament and bones at the base of the hand. The median

4. National Institute of Neurological Diseases and Stroke. (2023, November 28). *Alzheimer's disease*. National Institutes of Health. <https://www.ninds.nih.gov/health-information/disorders/alzheimers-disease>

5. Centers for Disease Control and Prevention. (2023, October 16). *Attention-deficit/hyperactivity disorder*. <https://www.cdc.gov/ncbddd/adhd/index.html>

nerve provides feeling to the thumb, index, middle finger, and part of the ring finger. Compression of this nerve causes the symptoms of numbness, tingling, weakness, and pain.⁶ See Figure 16.9⁷ for an illustration of carpal tunnel syndrome.

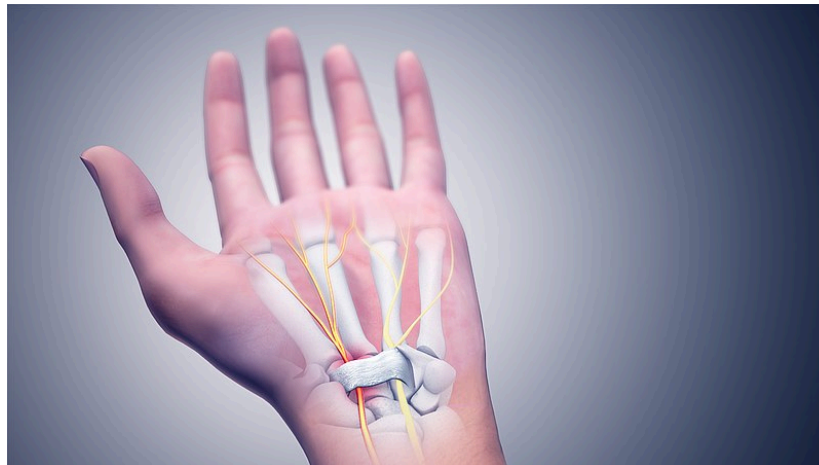


Figure 16.9 Carpal Tunnel Syndrome

Carpal tunnel syndrome may be diagnosed with a nerve conduction study that measures how quickly impulses are transmitted along a nerve. An electromyography test may also be used, where a fine needle is inserted into a muscle, and electrical activity is viewed on a screen to determine the severity of damage to the median nerve. Treatment includes wearing a splint at night while sleeping to keep the wrist straight and medications to reduce

6. National Institute of Neurological Disorders and Stroke. (2023, November 28). *Carpal tunnel syndrome*. National Institutes of Health. <https://www.ninds.nih.gov/health-information/disorders/carpal-tunnel-syndrome>

7. “[Carpal Tunnel Syndrome.jpg](#)” by www.scientificanimations.com is licensed under [CC BY-SA 4.0](https://creativecommons.org/licenses/by-sa/4.0/)

inflammation in the carpal tunnel. If these treatments are not effective, carpal tunnel release surgery is performed to release pressure on the nerve.⁸

CEREBRAL PALSY

Cerebral palsy is a neurological condition that affects muscles. Read about cerebral palsy in the “[Diseases and Disorders of the Muscular System](#)” section of the “Muscular System Terminology” chapter.

MENTAL HEALTH DISORDERS

Many mental health disorders, such as anxiety, bipolar disorder, obsessive compulsive disorder (OCD), and schizophrenia can be caused by imbalanced levels of neurotransmitters. Mental health disorders are treated with a combination of medications, psychotherapy, and support groups.

- ▶ Read additional information about common mental health disorders in the “[Disorders of the CNS System](#)” in the “Central Nervous System” chapter in *Open RN Nursing Pharmacology*, 2e. For more detailed information, view chapters on these

8. National Institute of Neurological Disorders and Stroke. (2023, November 28). *Carpal tunnel syndrome*. National Institutes of Health. <https://www.ninds.nih.gov/health-information/disorders/carpal-tunnel-syndrome>

- ▶ disorders in Open RN *[Nursing: Mental Health and Community Concepts](#)*.

MULTIPLE SCLEROSIS

Multiple sclerosis (MŬL-tŭ-pl sklĕ-RŌ-sĭs) (**MS**) is a neurological disease with symptom onset generally between the ages of 20 to 40 years. MS is an autoimmune disease causing the immune system to mistakenly attack myelin in the brain, optic nerves, and the spinal cord. Myelin is a substance that coats and protects axons of the neurons. See Figure 16.10⁹ for an illustration of MS. MS is a chronic disease that affects people differently. Some people have mild disease with little to no disability, whereas others will have a steadily worsening disease that leads to increased disability.¹⁰

9. “[Multiple_Sclerosis.jpg](#)” by BruceBlaus is licensed under [CC BY-SA 4.0](#)

10. National Institute of Neurological Disorders and Stroke. (2023, November 28). *Multiple sclerosis*. National Institutes of Health. <https://www.ninds.nih.gov/health-information/disorders/multiple-sclerosis>

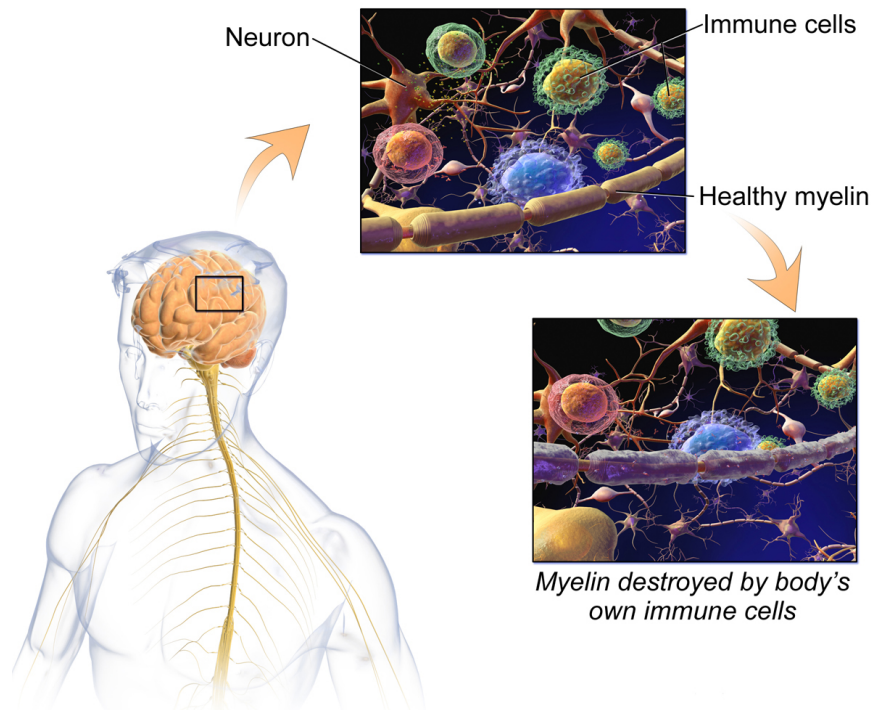


Figure 16.10 Multiple Sclerosis

MS symptoms include muscle weakness; vision loss; dizziness; tingling, numbness, or pain in nerves across the body; bladder control issues; and balance problems. There is no cure for MS, but there are medications and treatments that can reduce the number and severity of relapses and delay the long-term disability progression of the disease.¹¹

PARALYSIS

Paralysis is caused by a neurological condition that affects the muscles. Read

11. National Institute of Neurological Disorders and Stroke. (2023, November 28). *Multiple sclerosis*. National Institutes of Health. <https://www.ninds.nih.gov/health-information/disorders/multiple-sclerosis>

about paralysis in the “[Diseases and Disorders of the Muscular System](#)” section of the “Muscular System Terminology” chapter.

PARKINSON’S DISEASE

Parkinson’s disease (pär-kĭn-sŏnz dĭ-zēz) (**PD**) is a nervous system disorder that affects movement and worsens over time. As neurons in parts of the brain are damaged, people with PD have symptoms of tremors, rigidity in the limbs or the trunk of the body, slowed voluntary movements, and impaired balance. See Figure 16.11¹² for an illustration of someone with an appearance of typical PD symptoms. As symptoms progress, people may have difficulty walking, talking, or completing simple tasks. There is no cure for PD, but medications or surgery can help improve motor symptoms.¹³

¹². “[Sir_William_Richard_Gowers_Parkinson_Disease_sketch_1886.jpg](#)” by unknown author is licensed in the [Public Domain](#).

¹³. National Institute of Neurological Disorders and Stroke. (2023, November 28). *Parkinson’s disease*. National Institutes of Health. <https://www.ninds.nih.gov/health-information/disorders/parkinsons-disease>

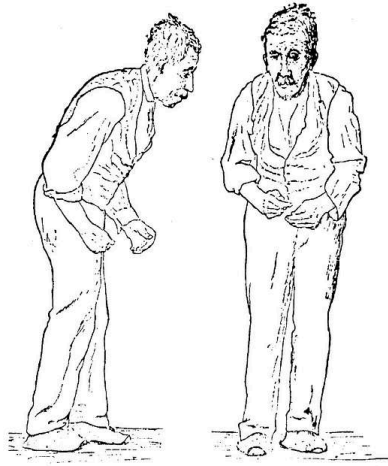

Figure 16.11 Parkinson's Disease

POST-TRAUMATIC STRESS DISORDER

Post-traumatic stress disorder (pōst-TRŌ-măt-ĭk strēs dīs-ôr-děr) (**PTSD**) is diagnosed in individuals who have been exposed to a traumatic event with chronic stress symptoms lasting more than one month that are so severe they interfere with relationships, school, or work. Anyone can develop PTSD at any age, including war veterans; children who have experienced trauma; or adults who have experienced a physical or sexual assault, abuse, accident, disaster, being a refugee, or some other serious event.¹⁴

Symptoms of PTSD include mentally reexperiencing the event; feeling tense, easily startled, or experiencing angry outbursts; avoiding activities that are reminders of the trauma; and loss of interest in activities one typically

14. National Institute of Mental Health. (2023, May). *Post-traumatic stress disorder*. National Institutes of Health. <https://www.nimh.nih.gov/health/topics/post-traumatic-stress-disorder-ptsd>

enjoys. PTSD treatments include medications, psychotherapy, or a combination of both.¹⁵

SEIZURES

A **seizure** (sē-zhŭrz) is a sudden, uncontrolled electrical disturbance in the brain that causes changes in behaviors, movements, or changes in levels of consciousness. During a seizure, large numbers of brain cells are abnormally activated, like an electrical storm in the brain. Seizures may alter consciousness and produce abnormal motor activity. Symptoms may include muscle jerking; becoming limp or rigid; brief muscle twitching; or changes in sensations, emotions, or thinking. Epilepsy is a neurological disease that causes recurrent seizures. Seizures are diagnosed with electroencephalograms (EEGs), CT scans, and MRIs. Epilepsy is treated with medications.¹⁶

STROKE

A stroke is also called a **cerebrovascular accident** (sĕr-ĕ-brō-VĀS-kyŭ-lăr ħk-sĭ-dĕnt) (**CVA**). It is a sudden interruption of blood flow to the brain and requires immediate emergency care. Diagnosing and treating a stroke is often

¹⁵. National Institute of Mental Health. (2023, May). *Post-traumatic stress disorder*. National Institutes of Health. <https://www.nimh.nih.gov/health/topics/post-traumatic-stress-disorder-ptsd>

¹⁶. Epilepsy Foundation. (2019, October 1). *Understanding seizures*. <https://www.epilepsy.com/what-is-epilepsy/understanding-seizures>

referred to as “time is brain.” With timely treatment it is possible to save brain cells and greatly reduce the damage or death that can occur due to stroke. Brain cells die because they stop getting the oxygen and nutrients needed to function or they are damaged by sudden bleeding in or around the brain. Knowing the signs of stroke and calling 911 immediately can help save someone’s life.¹⁷

People who have a stroke may not realize what is happening, ignore the signs, or may not be able to call for emergency help on their own. Call 911 immediately if you notice someone is having one or more of the following symptoms¹⁸ :

- Sudden numbness or weakness of an arm or leg, especially on one side of the body
- Sudden confusion, trouble speaking, or understanding
- Sudden loss of vision or trouble seeing in one or both eyes
- Sudden trouble walking, dizziness, or loss of balance or coordination
- Sudden unusually severe headache with no known cause

There are two types of strokes called ischemic and hemorrhagic. An ischemic stroke is the loss of blood flow to an area because vessels are blocked or narrowed. This can be caused by plaque that has built up and blocked the vessel, or a blood clot that has travelled from another area of the body and lodged in the brain. A hemorrhagic stroke is bleeding into the brain because of a damaged blood vessel. Accumulated blood fills a region of the cranium and presses against the tissue in the brain, referred to as **intracranial**

17. National Institute of Neurological Disorders and Stroke. (2023, November 28). *Stroke*. National Institutes of Health. <https://www.ninds.nih.gov/health-information/disorders/stroke>

18. National Institute of Neurological Disorders and Stroke. (2023, November 28). *Stroke*. National Institutes of Health. <https://www.ninds.nih.gov/health-information/disorders/stroke>

pressure (în-tră-KRĀ-nē-ăl PRĚSH-ŭr).¹⁹ See Figure 16.12²⁰ for an illustration comparing ischemic and hemorrhagic strokes, and Figure 16.13²¹ for an image containing a radiographic image of a hemorrhagic stroke.

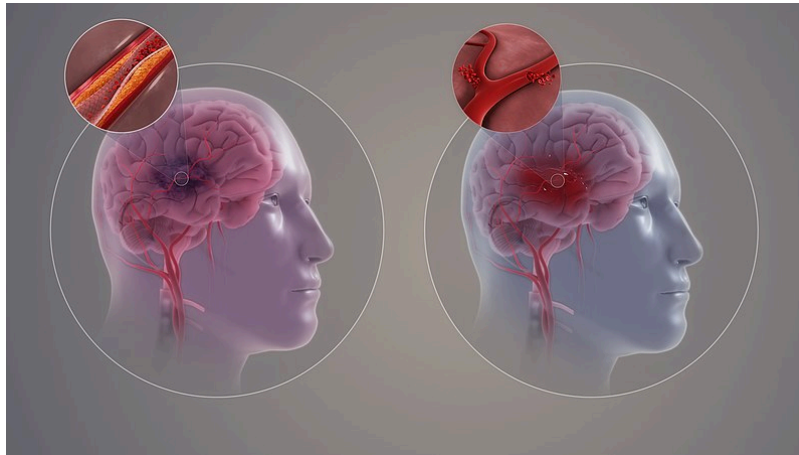


Figure 16.12 Comparison of Ischemia and Hemorrhagic Strokes

- ¹⁹. National Institute of Neurological Disorders and Stroke. (2023, November 28). *Stroke*. National Institutes of Health. <https://www.ninds.nih.gov/health-information/disorders/stroke>
- ²⁰. “Types_of_Stroke.jpg” by <https://www.scientificanimations.com/> is licensed under [CC BY-SA 4.0](#)
- ²¹. “1602_The_Hemorrhagic_Stroke-02.jpg” by OpenStax College is licensed under [CC BY 3.0](#)

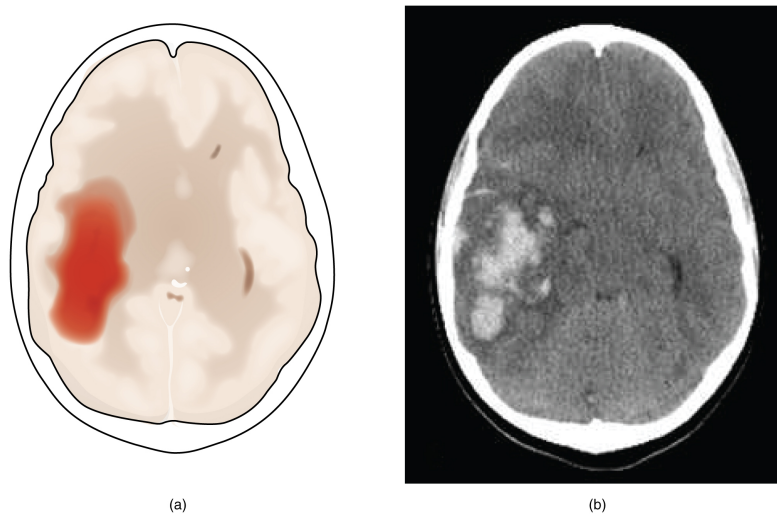


Figure 16.13 Hemorrhagic Stroke

Subarachnoid hemorrhage (sŭb-ă-răk-NOYD HĚM-ör-īj) refers to bleeding in the space between the brain and the surrounding membrane (subarachnoid space). The primary symptom is a sudden, severe headache, often described by patients as the worst headache they have ever felt.²²

Transient ischemic attacks (trăn-zhěnt ĩs-kē-mĭk ă-tăks) (**TIA**s) are temporary periods of symptoms similar to a stroke, but irreversible damage to the brain cells do not occur. However, TIAs are considered warning signs of an impending stroke and the opportunity to prevent it.²³

Strokes are often diagnosed with diagnostic imaging tests like CT scans or MRIs. A cerebral angiogram may be performed for an ischemic stroke, where a catheter is inserted into the arteries supplying the brain and a dye is

22. Mayo Clinic. (2022, August 31). *Subarachnoid hemorrhage*.
<https://www.mayoclinic.org/diseases-conditions/subarachnoid-hemorrhage/symptoms-causes/syc-20361009>

23. Mayo Clinic. (2022, March 26). *Transient ischemic attack*.
<https://www.mayoclinic.org/diseases-conditions/transient-ischemic-attack/symptoms-causes/syc-20355679>

injected to reveal the blockage site. Treatment of strokes depends on the cause and may include medications or surgery.²⁴

TRAUMATIC BRAIN INJURY

A **traumatic brain injury** (trô-măt-ĭk brān ĨN-jŭ-rē) (**TBI**) can be caused by a forceful bump, blow, or jolt to the head or body or from an object that pierces the skull and enters the brain. Some types of mild TBI, like a concussion, can cause temporary or short-term problems with normal brain function, including problems with how the person thinks, understands, moves, communicates, and acts. A serious TBI can lead to severe, permanent disability or death.²⁵

Symptoms of a TBI may include loss of consciousness; headache; blurred vision; unequal eye pupil size; nausea and vomiting; clear fluids draining from the nose or ears; sensitivity to light, a condition called **photophobia** (fō-tō-FŌ-bē-ă); ringing in the ears; or other neurological symptoms. TBI is diagnosed using standardized concussion tools and diagnostic testing such as CT scans and MRIs, if necessary.²⁶

24. National Institute of Neurological Disorders and Stroke. (2023, November 28). *Stroke*. National Institutes of Health. <https://www.ninds.nih.gov/health-information/disorders/stroke>

25. National Institute of Neurological Disorders and Stroke. (2023, November 28). *Traumatic brain injury (TBI)*. National Institutes of Health. <https://www.ninds.nih.gov/health-information/disorders/traumatic-brain-injury-tbi>

26. National Institute of Neurological Disorders and Stroke. (2023, November 28). *Traumatic brain injury (TBI)*. National Institutes of Health.

There are many types of TBIs, including concussions, hematomas, skull fractures, and chronic traumatic encephalopathy²⁷:

- **Concussion** (kŏn-KŬSH-ŭn): A concussion is a temporary, mild TBI that may take several months to heal. A concussion can be caused by a blow to the head, sports injury, fall, motor vehicle accident, weapons blast, or a rapid acceleration/deceleration of the brain within the skull, such as an infant being shaken.
- **Hematoma** (hĕm-ă-TŌ-mă): A hematoma refers to bleeding in and around the brain caused by a ruptured blood vessel. Different types of hematomas form depending on where the blood collects. For example, **subdural hematomas** (sŭb-DŪ-răł hĕm-ă-TŌ-măz) are common in the elderly after experiencing a TBI from a fall. It involves bleeding below the dura mater, the membrane directly under the skull.
- **Skull fracture** (skŭl FRĂK-chŭr): Skull fractures are cracks in one or more of the bones that form the skull. They can cause damage to the membranes, blood vessels, and brain under the fracture. Helmets and seat belts significantly help prevent skull fractures and TBI.
- **Chronic traumatic encephalopathy** (KRŎN-ĭk trô-măt-ĭk ěn-sĕf-ăl-ŌP-ă-thĕ): Chronic traumatic encephalopathy occurs in people with extraordinary exposure to multiple blows to the head, such as boxers and football players. It is a delayed consequence after many years and a progressive neurological disorder associated with symptoms that may include problems with thinking, understanding, and communicating; motor disorders (affecting movement); problems with impulse control

<https://www.ninds.nih.gov/health-information/disorders/traumatic-brain-injury-tbi>

27. National Institute of Neurological Disorders and Stroke. (2023, November 28). *Traumatic brain injury (TBI)*. National Institutes of Health.

<https://www.ninds.nih.gov/health-information/disorders/traumatic-brain-injury-tbi>

and depression; confusion; and irritability.

Treatments are based on the cause and severity of the TBI. For example, mild concussions are commonly treated with rest and pain reliever medications, whereas severe TBIs may require surgery to drill a hole into the skull and drain fluids to relieve pressure inside the skull.²⁸

28. National Institute of Neurological Disorders and Stroke. (2023, November 28). *Traumatic brain injury (TBI)*. National Institutes of Health. <https://www.ninds.nih.gov/health-information/disorders/traumatic-brain-injury-tbi>

16.7 Medical Specialists, Diagnostic Testing, and Procedures Related to the Nervous System

MEDICAL SPECIALISTS

Neurology (noo-ROL-ŏ-jē) is the study of the nervous system. **Psychiatry** (sī-KĪ-ă-trē) is the study of disorders of the mind. **Psychology** (sī-KOL-ŏ-jē) is the study of the mind.

Neurologist

A **neurologist** (nū-RŎL-ŏ-jĭst) is a physician who specializes in the diagnosis and treatment of disorders and conditions related to the brain, spinal cord, nerves, and muscles. **Neurosurgeons** (nū-RŎ-sŭrj- ŭnz) perform surgeries on the nervous system.

► Read additional information about neurologists on the [American Academy of Neurology's web page](#).

Psychiatrist

A **psychiatrist** (sī-KĪ-ă-trĭst) is a medical doctor who specializes in mental

health and substance disorders. Because they are physicians, psychiatrists can order or perform a full range of medical laboratory and psychological tests. Mental health diagnoses are based on criteria established in *Diagnostic and Statistical Manual of Mental Disorders (DSM-5)*, which contains descriptions, symptoms, and other criteria for diagnosing mental disorders. Psychiatrists prescribe a variety of treatments, including talk therapy, medications, psychosocial interventions, and other treatments such as **electroconvulsive therapy** (ē-lek-trō-kŏn-VŬL-sĭv THĔR-ă-pē) (**ECT**), depending on the needs of each patient. ECT is the application of electrical currents to the brain, typically used to treat severe depression that has not responded to other treatments.

- ▶ Read more information about psychiatrists on the [American Psychiatric Association's web page](#).

Psychologist

Psychologists (sĭ-KŎL-ŏ-jĭstz) are professionals with graduate degrees, and many have doctoral degrees (i.e., PhD, PsyD, or EdD). They specialize in helping people learn to cope with stressful situations, overcome substance use disorders, and manage chronic mental health disorders, and they also perform psychological tests.

- ▶ Read more information about psychologists on the [American Psychological Association's web page](#).

Social Workers

Social workers (SŌ-shăl WŬR-kĕrz) help people prevent and cope with

problems in their everyday lives. Social workers typically need a bachelor's or master's degree in social work (BSW or MSW) from an accredited program.

- ▶ Read more about [social workers](#) on the Bureau of Labor Statistics' web page.

Counselors

Substance use and mental health counselors advise people on issues such as those relating to alcoholism, substance use disorders, or depression.

Education and training requirements vary for entering these occupations by state. For example, in Wisconsin there are associate degree programs available in substance use disorder counseling. Mental health counseling typically requires a master's degree.

- ▶ Read more about counselors on the Bureau of Labor Statistics' [web page](#).

DIAGNOSTIC TESTS RELATED TO THE NERVOUS SYSTEM

Cerebral Angiography

Cerebral angiography (SĔR-ă-brīl, an-jē-OG-ră-fē) uses X-rays and special dye to see how blood flows through the brain. Specially trained health care providers perform this procedure in an operating room. During the

procedure, a provider inserts a catheter into an artery in the wrist or groin area, injects contrast material through the catheter, and then takes X-rays of the blood vessels. Cerebral angiograms provide more detailed images of blood vessels than other imaging tests, like CT or MRI scans.¹

Electroencephalogram (EEG)

An **electroencephalogram** (ě-lek-trō-ěň-SEF-ă-lŏ-gram) (**EEG**) is a test to measure the electrical activity of the brain. The test is performed by an electroencephalogram (EEG) technologist in a laboratory, health care provider's office, or hospital. Flat metal disks called electrodes are placed on many spots on the scalp. The electrodes are connected by wires to a recording machine that changes the electrical signals into patterns that can be seen on a monitor or drawn on paper.² See Figure 16.14³ for an image of an EEG.

1. Cleveland Clinic. (2023, August 8). *Cerebral angiogram*.
<https://my.clevelandclinic.org/health/diagnostics/13476-cerebral-angiogram>
2. A.D.A.M. Medical Encyclopedia [Internet]. Atlanta (GA): A.D.A.M., Inc.; c1997-2023. EEG; [reviewed 2023, Jan 1; cited 2023, Dec 7].
<https://medlineplus.gov/ency/article/003931.htm>
3. "Three_quarter_view_of_EEG_subject.jpg" by Chris Hope and shared by Tim Sheerman-Chase is licensed under [CC BY 2.0](#)

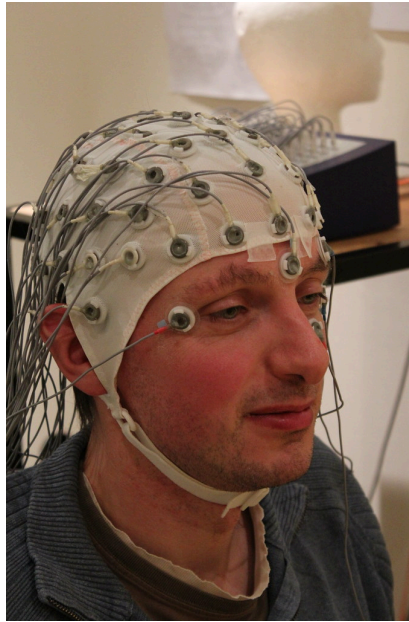


Figure 16.14 EEG

Electromyography (EMG)

An **electromyogram** (ē-lĕk-trō-mī-Ō-grām) (**EMG**) is a diagnostic procedure that assesses the function of nerve cells that control muscles. Electrodes, either attached to the skin or inserted into the muscle, record electrical impulses. An EMG can identify functional problems with the peripheral nerves, muscles, or with the signals between the nerves and the muscles. A nerve conduction study, another part of an EMG, uses surface electrodes applied to the skin to measure the speed and strength of signals traveling between two or more points. EMG results are used to diagnose muscle and nerve disorders.⁴

Lumbar Puncture (Spinal Tap)

A **lumbar puncture** (LŬM-bār PŬNK-chŭr), which is also called a spinal tap, is

4. Mayo Clinic. (2019, May 21). *Electromyography (EMG)*. <https://www.mayoclinic.org/tests-procedures/emg/about/pac-20393913>

a test used to diagnose nervous system infections and other conditions. During a lumbar puncture, a needle is inserted into the space between two vertebrae in the lumbar region to remove a sample of cerebrospinal fluid (CSF). CSF is the fluid that surrounds the brain and spinal cord to protect them from injury.⁵ See Figure 16.15⁶ for an illustration of a lumbar puncture.

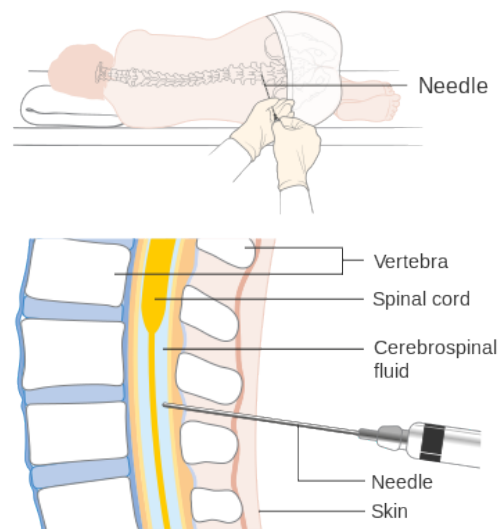


Figure 16.15 Lumbar Puncture

5. Mayo Clinic. (2022, April 30). *Lumbar puncture (spinal tap)*.
<https://www.mayoclinic.org/tests-procedures/lumbar-puncture/about/pac-20394631>
6. “[Diagram showing how you have a lumbar puncture CRUK_157.svg](#)” by Cancer Research UK is licensed under [CC BY-SA 4.0](#)

PROCEDURES RELATED TO THE NERVOUS SYSTEM

Carotid Endarterectomy

A **carotid endarterectomy** (kă-rōt-ĭd ěnd-ă-r-tĕr-ĔK-tō-mĕ) is the surgical removal of plaque blocking the carotid arteries in the neck. The carotid arteries are the main blood vessels that carry oxygen and blood to the brain. This procedure is performed to prevent or treat a stroke.⁷

7. Johns Hopkins Medicine. (n.d.). *Carotid endarterectomy*.

<https://www.hopkinsmedicine.org/health/treatment-tests-and-therapies/carotid-endarterectomy>

16.8 Nervous System Learning Activities

Interactive Learning Activity: Practice labeling parts of the brain.



An interactive H5P element has been excluded from this version of the text. You can view it online here:

<https://wtcs.pressbooks.pub/medterm/?p=543#h5p-119>

Interactive Learning Activity: Study nervous system medical terms discussed in this chapter using these flashcards.



An interactive H5P element has been excluded from this version of the text. You can view it online here:

<https://wtcs.pressbooks.pub/medterm/?p=543#h5p-192>

Interactive Learning Activity: Test your knowledge of these nervous system terms.



An interactive H5P element has been excluded from this version of the text. You can view it online here:

<https://wtcs.pressbooks.pub/medterm/?p=543#h5p-124>

Interactive Learning Activity: Using the sample documentation provided, drag the terms on the right to their appropriate spaces within the documentation.



An interactive H5P element has been excluded from this version of the text. You can view it online here:

<https://wtcs.pressbooks.pub/medterm/?p=543#h5p-121>

Interactive Learning Activity: Using the sample documentation provided, drag the terms on the right to their appropriate spaces within the documentation.



An interactive H5P element has been excluded from this version of the text. You can view it online here:

<https://wtcs.pressbooks.pub/medterm/?p=543#h5p-122>

Interactive Learning Activity: Using the sample documentation provided, drag the terms on the right to their appropriate spaces within the documentation.



An interactive H5P element has been excluded from this version of the text. You can view it online here:

<https://wtcs.pressbooks.pub/medterm/?p=543#h5p-123>

Interactive Learning Activity: Using the sample documentation provided, drag the terms on the right to their appropriate spaces within the documentation.





An interactive H5P element has been excluded from this version of the text. You can view it online here:

<https://wtcs.pressbooks.pub/medterm/?p=543#h5p-79>



Interactive Learning Activity: Practice identifying and defining word parts for terms discussed in this chapter.



An interactive H5P element has been excluded from this version of the text. You can view it online here:

<https://wtcs.pressbooks.pub/medterm/?p=543#h5p-208>

- ▶ You can also print this as a [Chapter 16 Practice Worksheet](#) and check your answers with this [Answer Key PDF](#).

16.9 Glossary

Abstract reasoning (ăb-străkt RĒ-zōn-īng): The ability to analyze information, detect patterns and relationships, and solve problems on a complex, intangible level. ([Chapter 16.5](#))

Alzheimer's disease (ălts-hī-měrz dī-zēz) (AD): A progressive neurodegenerative disorder characterized by memory loss, language deterioration, and impaired ability to mentally manipulate visual information. ([Chapter 16.6](#))

Amyotrophic lateral sclerosis (ā-mī-ō-TRŌF-ik LĀT-ěr-ăl sklě-RŌ-sīs) (ALS): A progressive neurodegenerative disease that affects nerve cells in the brain and spinal cord, causing muscle weakness and atrophy. ([Chapter 16.6](#))

Anesthesia (an-ēs-THĒ-zhă): The loss of sensation or feeling in a part or all of the body, often induced for medical procedures. ([Chapter 16.5](#))

Aphasia (ă-FĀ-zh-ē-ă): A condition characterized by either partial or total loss of the ability to communicate verbally or using written words. ([Chapter 16.5](#))

Attention deficit hyperactivity disorder (ă-těn-shŭn dėf-ī-sīt hī-pěr-ăk-tīv-ī-tē dīs-ôr-děr) (ADHD): A neurodevelopmental disorder characterized by a persistent pattern of inattention and/or hyperactivity-impulsivity that interferes with functioning or development. ([Chapter 16.6](#))

Axon (ăk-sŏn): The long, slender projection of a nerve cell that typically conducts electrical impulses away from the neuron's cell body. ([Chapter 16.4](#))

Brain stem (brān stēm): The central trunk of the brain, consisting of the medulla oblongata, pons, and midbrain, and continuing downward to form the spinal cord. ([Chapter 16.4](#))

Broca's area (brō-kăz ār-ē-ă): A region in the frontal lobe of the brain with functions linked to speech production. ([Chapter 16.4](#))

Carotid endarterectomy (kă-rŏt-īd ěnd-ăr-těr-ĚK-tŏ-mē): A surgical procedure to remove plaque from the carotid arteries and restore blood flow to the brain, often used to prevent stroke. ([Chapter 16.7](#))

Carpal tunnel syndrome (KĀR-păl TŪN-ěl SĪN-drŏm): A condition caused

by compression of the median nerve within the carpal tunnel of the wrist, leading to pain, numbness, and tingling in the hand. ([Chapter 16.6](#))

Cell body (sěl bōd-ē): The spherical part of the neuron that contains the nucleus and connects to the dendrites and axon. ([Chapter 16.4](#))

Central nervous system (SEN-trāl NŮR-vŭs SĪS-tēm) (CNS): The part of the nervous system consisting of the brain and spinal cord, responsible for processing and transmitting information throughout the body. ([Chapter 16.4](#))

Cerebellum (sēr-ě-běl-ŭm): A major structure of the hindbrain that is responsible for fine motor coordination, balance, equilibrium, and muscle tone. ([Chapter 16.4](#))

Cerebral angiography (SĚR-ē-brāl ăn-jē-ŎG-ră-fē): A diagnostic imaging technique that uses X-rays to visualize blood flow in the arteries and veins in the brain. ([Chapter 16.7](#))

Cerebral cortex (sě-RĚ-brāl KÔR-těks): The outer layer of the cerebrum, playing a key role in memory, attention, perception, cognition, awareness, thought, language, and consciousness. ([Chapter 16.4](#))

Cerebrovascular accident (sēr-ě-brō-VĀS-kyŭ-lăr ăk-sĭ-děnt) (CVA): Also known as a stroke, it is the sudden death of brain cells due to lack of oxygen, caused by blockage of blood flow or rupture of an artery in the brain. ([Chapter 16.6](#))

Cerebrum (sě-RĚ-brŭm): The largest part of the brain, responsible for voluntary muscular activity, vision, speech, taste, hearing, thought, and memory. ([Chapter 16.4](#))

Chronic traumatic encephalopathy (KRŎN-ĭk trô-măt-ĭk ěn-sěf-ăl-ŎP-ă-thē) (CTE): A brain condition associated with repeated blows to the head and repeated episodes of concussion. ([Chapter 16.6](#))

Concussion (kŏn-KŮSH-ŭn): A type of traumatic brain injury caused by a blow to the head or body, a fall, or another injury that jars or shakes the brain inside the skull. ([Chapter 16.6](#))

Cranial nerves (krā-nē-ăl nĕrvz): The 12 pairs of nerves that emerge directly from the brain, as opposed to spinal nerves, with functions largely concerning the head and neck. ([Chapter 16.4](#))

Dendrites (děn-drĭts): Extensions of a neuron that receive signals from other neurons and transmit them toward the cell body. ([Chapter 16.4](#))

Dura mater (dǔǔ-rǎ mā-těr): The thick, tough outer layer of the meninges surrounding the brain and spinal cord. ([Chapter 16.4](#))

Electroconvulsive therapy (ē-lek-trō-kǒn-VŮL-sǐv THĚR-ǎ-pē) (ECT): A medical treatment most commonly used for patients with severe major depression or bipolar disorder that has not responded to other treatments, involving brief electrical stimulation of the brain while the patient is under anesthesia. ([Chapter 16.7](#))

Electroencephalogram (ě-lek-trō-ěn-SĚF-ǎ-lǒ-gram) (EEG): A test that detects electrical activity in the brain using small, flat metal discs (electrodes) attached to the scalp. ([Chapter 16.7](#))

Electromyogram (ē-lěk-trō-MĪ-ǒ-gram) (EMG): A diagnostic test that measures the electrical activity of muscles to help diagnose muscle and nerve disorders. ([Chapter 16.7](#))

Expressive aphasia (eks-PRĚS-ǐv ǎ-FĀ-zh-ē-ǎ): A type of aphasia where a person knows what they want to say but has difficulty communicating it to others. ([Chapter 16.5](#))

Frontal lobe (FRŮN-tǎl lōb): A region of the cerebral cortex associated with reasoning, motor skills, higher-level cognition, and expressive language. ([Chapter 16.4](#))

Hematoma (hēm-ǎ-TŌ-mǎ): A solid swelling of clotted blood within the tissues, often caused by an injury. ([Chapter 16.6](#))

Hypothalamus (hī-pō-THAL-a-mus): A region of the forebrain below the thalamus that coordinates both the autonomic nervous system and the activity of the pituitary, controlling body temperature, thirst, hunger, and other homeostatic systems. ([Chapter 16.4](#))

Intracranial pressure (ǐn-trǎ-KRĀ-nē-ǎl PRĚSH-ŭr): Pressure inside the skull and thus in the brain tissue and cerebrospinal fluid, usually in the context of illness or injury. ([Chapter 16.6](#))

Judgment (JŮJ-měnt): The ability to make considered decisions or come to sensible conclusions. ([Chapter 16.5](#))

Language (LĀNG-gwǐj): The method of human communication, either spoken or written, consisting of the use of words. ([Chapter 16.5](#))

Lumbar puncture (LŮM-bǎr PŮNK-chŭr): A medical procedure where a needle is inserted into the lower part of the spinal column to collect

cerebrospinal fluid for diagnostic testing or to relieve pressure. ([Chapter 16.7](#))

Memory (MĚM-ō-rē): The faculty by which the mind stores and remembers information. ([Chapter 16.5](#))

Meninges (mĕn-ĭn-jēz): The three membranes that envelop the brain and spinal cord, providing protection for these structures. ([Chapter 16.4](#))

Multiple sclerosis (MŮL-tĭ-pl sklĕ-RŌ-sĭs) (MS): An autoimmune disease that affects the brain and spinal cord, leading to demyelination, inflammation, and scarring, resulting in a range of symptoms including physical, mental, and sometimes psychiatric problems. ([Chapter 16.6](#))

Myelin (mĭ-ĕ-lĭn): The protective fatty layer that wraps around the nerve fibers (axons), facilitating the fast transmission of electrical signals. ([Chapter 16.4](#))

Neurologist (nū-RŌL-ō-jĭst): A physician who specializes in the diagnosis and treatment of disorders of the nervous system, brain, spinal cord, nerves, and muscles. ([Chapter 16.7](#))

Neurology (noo-ROL-ō-jē): The study of the nervous system. ([Chapter 16.7](#))

Neurons (nŭr-ōns): Nerve cells that are the basic building blocks of the nervous system, responsible for transmitting information throughout the body. ([Chapter 16.4](#))

Neurosurgeons (nū-RŌ-sŭrj-ŭnz): Surgeons who specialize in surgery on the nervous system, including the brain and spinal cord. ([Chapter 16.7](#))

Neurotransmitter (nŭr-ō-trāns-mĭt-ēr): Chemical substances that transmit nerve signals across a synapse from one neuron to another. ([Chapter 16.4](#))

Occipital lobe (ōk-SĪP-ĭ-tāl lōb): The rearmost lobe in each cerebral hemisphere of the brain, responsible for processing visual information. ([Chapter 16.4](#))

Orientation (or-ē-ĕn-TĀ-shŏn): The patient's awareness of their immediate circumstances (i.e., being oriented to person, place, and time). ([Chapter 16.5](#))

Paresthesia (par-es-THĒ-zh(ē)-ă): An abnormal sensation, such as tingling, pricking, or numbness, typically with no apparent physical cause. ([Chapter 16.5](#))

Parietal lobe (pă-rĭ-ĕ-tāl lōb): The upper middle lobe of the cerebrum, involved in processing sensory information such as touch, temperature, and pain. ([Chapter 16.4](#))

Parkinson's disease (pär-kĭn-sönz dĭ-zēz) (PD): A progressive nervous system disorder that affects movement, often including tremors, muscle rigidity, and changes in speech and gait. ([Chapter 16.6](#))

Peripheral nervous system (pě-rĭF-ēr-āl NŮR-vŭs SĪS-tēm) (PNS): The part of the nervous system outside the CNS, consisting mainly of the nerves that extend from the brain and spinal cord. ([Chapter 16.4](#))

Photophobia (fō-tō-FŌ-bē-ă): An extreme sensitivity to light, often causing discomfort or pain in the eyes. ([Chapter 16.6](#))

Post-traumatic stress disorder (pōst-TRŌ-măt-ĭk strēs dĭs-ôr-dēr) (PTSD): A mental health condition triggered by experiencing or witnessing a terrifying event, characterized by flashbacks, nightmares, severe anxiety, and uncontrollable thoughts about the event. ([Chapter 16.6](#))

Prefrontal cortex (prē-FRŌN-tāl KÔR-těks): The front part of the frontal lobe, involved in complex behaviors such as planning, and contributing to personality development. ([Chapter 16.4](#))

Psychiatrist (sĭ-KĪ-ă-trĭst): A medical doctor specializing in the diagnosis, prevention, study, and treatment of mental disorders, including prescribing medication. ([Chapter 16.7](#))

Psychiatry (sĭ-KĪ-ă-trē): The medical specialty devoted to diagnosing, preventing, studying, and treating mental disorders. ([Chapter 16.7](#))

Psychologists (sĭ-KŌL-ō-jĭstz): Professionals who study cognitive, emotional, and social processes and behavior by observing, interpreting, and recording how individuals relate to one another and to their environments. ([Chapter 16.7](#))

Psychology (sĭ-KOL-ō-jē): The study of the mind and its functions, especially those affecting behavior. ([Chapter 16.7](#))

Receptive aphasia (rĭ-SEP-tĭv ă-FĀ-zh-ē-ă): A form of aphasia where individuals have trouble understanding spoken or written language. ([Chapter 16.5](#))

Sciatica (sĭ-ăt-ĭ-kă): Pain affecting the back, hip, and outer side of the leg, caused by compression or irritation of the sciatic nerve. ([Chapter 16.4](#))

Seizure (sē-zhŭr): An uncontrolled electrical disturbance in the brain, which can cause changes in behavior, movements, feelings, and levels of consciousness. ([Chapter 16.6](#))

Sensorium (sĕn-SAWR-ĕ-ŭm): The sensory apparatus or faculties considered as a whole. ([Chapter 16.5](#))

Skull fracture (skŭl FRĀK-chŭr): A break in one or more of the bones in the skull, often caused by a blow to the head. ([Chapter 16.6](#))

Social workers (SŌ-shāl WŪR-kĕrz): Professionals who provide a wide range of services to help people cope with and overcome challenges in their everyday lives, including mental health and substance abuse counseling. ([Chapter 16.7](#))

Speech (spĕch): The expression of thoughts and feelings by articulating sounds. ([Chapter 16.5](#))

Spinal cord (spī-nāl kôrd): The cylindrical bundle of nerve fibers and associated tissue enclosed in the spine, connecting nearly all parts of the body to the brain. ([Chapter 16.4](#))

Spinal nerves (spī-nāl nĕrvz): Nerves that originate in the spinal cord and branch out to provide motor and sensory functions to the body. ([Chapter 16.4](#))

Subarachnoid hemorrhage (sŭb-ă-răk-NOYD HĚM-ôr-ĭj): A type of stroke caused by bleeding into the space surrounding the brain, leading to sudden severe headache and other symptoms. ([Chapter 16.6](#))

Subdural hematoma (sŭb-DŪ-rāl hĕm-ă-TŌ-mă): A type of hematoma, usually associated with traumatic brain injury, involving bleeding in the outermost meningeal layer, just under the skull. ([Chapter 16.6](#))

Synapse (sĭn-ăps): The junction between two nerve cells, consisting of a minute gap across which impulses pass by diffusion of a neurotransmitter. ([Chapter 16.4](#))

Temporal lobe (tĕm-pŏ-rāl lōb): A region of the cerebral cortex responsible for processing auditory information and is also involved in memory storage. ([Chapter 16.4](#))

Thalamus (thāl-ă-mŭs): A small structure within the brain located just above the brain stem between the cerebral cortex and the midbrain with multiple functions, including relaying sensory and motor signals to the cerebral cortex. ([Chapter 16.4](#))

Transient ischemic attacks (trăn-zhĕnt ĭs-KĒ-mĭk ă-tăks) (TIAs): Often called a “mini-stroke,” a temporary period of symptoms similar to those of a stroke, indicating a high risk of a full-blown stroke in the future. ([Chapter 16.6](#))

Traumatic brain injury (trô-măt-ĭk brān ĨN-jŭ-rē) (TBI): A form of brain injury caused by a blow, jolt, or other traumatic injury to the head or body, causing temporary or permanent damage. ([Chapter 16.6](#))

Vagus nerve (VĀ-gŭs nĕrv): A cranial nerve that extends from the brain stem to the abdomen, playing critical roles in the heart, lungs, and digestive tract functioning. ([Chapter 16.4](#))

Ventricles (vĕn-trĭ-kŭls): Hollow, fluid-filled cavities within the brain that help to protect the brain and reduce its weight. ([Chapter 16.4](#))

Wernicke's area (wĕr-nĭk-kēz ă-r-ē-ă): A region of the brain that is important for language development, located in the temporal lobe. ([Chapter 16.4](#))

PART XVII

CHAPTER 17 ENDOCRINE SYSTEM TERMINOLOGY

17.1 Endocrine System Introduction

Learning Objectives


- Apply the rules of medical language to build, analyze, spell, pronounce, abbreviate, and define terms as they relate to the endocrine system
- Identify meanings of key word components of the endocrine system
- Categorize diagnostic, therapeutic, procedural, or anatomic terms related to the endocrine system
- Use terms related to the endocrine system
- Use terms related to the diseases and disorders of the endocrine system

Introduction to Endocrine System

The endocrine system is the body's "chemical messenger system." The major glands of the endocrine system secrete specialized chemical messengers called hormones into the bloodstream. The hormones travel to target organs and tissues where they initiate specific physiological responses.

This chapter will review common word components related to the endocrine system to assist learners in analyzing, building, and defining medical terms. Other terms, whose definitions cannot be easily built from word components, will be described in context based on the anatomy and

physiology of the endocrine system and common diseases and disorders. Medical specialists, diagnostic tests, and procedures related to the endocrine system will also be discussed.

 View a supplementary YouTube video¹ on the endocrine system from Crash Course: Endocrine System, Part 1 – Glands & Hormones: Crash Course Anatomy & Physiology #23

1. CrashCourse. (2015, June 22). *Endocrine system, Part 1 – Glands & hormones: Crash Course Anatomy & Physiology #23* [Video]. YouTube. All rights reserved. <https://www.youtube.com/watch?v=eWHH9je2zG4>

17.2 Word Components Related to the Endocrine System

This section will describe common word components related to the endocrine system. These word components help build definitions for many medical terms. Other common prefixes are described in [Chapter 1.3](#), and common suffixes are described in [Chapter 1.5](#).

PREFIXES RELATED TO THE ENDOCRINE SYSTEM

- **eu-**: Good, normal
- **hyper-**: Above, excessive
- **hypo-**: Below, under, deficient
- **oxy-**: Rapid, sharp, acid
- **pan-**: All, total
- **para-**: Around, beside, beyond, abnormal
- **poly-**: Many or much
- **syn-**: Joined, together
- **tetr-**: Four
- **tri-**: Three

WORD ROOTS WITH COMBINING

VOWELS RELATED TO THE ENDOCRINE SYSTEM

- **acr/o**: Extremities, height
- **aden/o**: Gland
- **adren/o**: Adrenal glands
- **adrenal/o**: Adrenal glands
- **calc/i**: Calcium
- **cortic/o**: Cortex, outer layer of a body organ
- **dips/o**: Thirst
- **endocrin/o**: Endocrine
- **glyc/o**: Sugar
- **home/o**: Sameness
- **kal/i**: Potassium
- **myx/o**: Mucus
- **natr/o**: Sodium
- **parathyroid/o**: Parathyroid gland
- **phys/o**: Growing
- **pituitar/o**: Pituitary gland
- **somat/o**: Body
- **thyr/o**: Thyroid gland
- **thyroid/o**: Thyroid gland

SUFFIXES RELATED TO THE ENDOCRINE SYSTEM

- **-drome**: Run, running together
- **-ectomy**: Excision, cut out
- **-emia**: In the blood

- **-ia**: Condition of, abnormal state, diseased state
- **-ism**: State of
- **-itis**: Inflammation
- **-logist**: Specialist who studies and treats
- **-logy**: Study of
- **-megaly**: Enlarged, enlargement
- **-oid**: Resembling
- **-oma**: Tumor
- **-pathy**: Disease
- **-plasia**: Condition of, formation, development, growth
- **-tomy**: Incision, cut into

17.3 Examples of Endocrine Terms Easily Defined By Their Word Components

Here are examples of common medical terms related to the endocrine system that can be easily defined by breaking the terms into their word components.

Hyperglycemia

1. Break down the medical term into word components:
Hyper/glyc/emia
2. Label the word components: **Hyper** = P; **glyc** = WR; **emia** = S
3. Define the word components: **Hyper** = excessive; **glyc** = sugar; **emia** = in the blood
4. Create a final definition of the medical term: **Excessive sugar in the blood**

Polydipsia

1. Break down the medical term into word components:
Poly/dips/ia
2. Label the word components: **Poly** = P; **dips** = WR; **ia** = S

3. Define the word components: **Poly** = much; **dips** = thirst; **ia** = condition of
4. Create a final definition of the medical term: **Condition of much thirst**

Adrenalectomy

1. Break down the medical term into word components: **Adrenal/ectomy**
2. Label the word components: **Adrenal** = WR; **ectomy** = S
3. Define the word components: **Adrenal** = adrenal gland; **ectomy** = removal
4. Create a final definition of the medical term: **Excision of the adrenal gland(s)**



Interactive Learning Activity: Practice defining and pronouncing endocrine system medical terms by breaking them down into word parts.



An interactive H5P element has been excluded from this version of the text. You can view it online here:

<https://wtcs.pressbooks.pub/medterm/?p=6397#h5p-127>

- ▶ You can also print these flashcard activities as a [Chapter 17](#)

▶ [Student Companion Worksheet](#) and check your answers with this [Answer Key](#).

17.4 Anatomy of the Endocrine System

The endocrine system includes the pineal, pituitary, thyroid, parathyroid, and adrenal glands, as well as the pancreas, ovaries, and testes. See Figure 17.1¹ for an illustration of the endocrine system.²

1. “e73bab44e2c1a6d18058e8ac13c76807add6c209.jpg” by Betts et al., is licensed under [CC BY 4.0](https://creativecommons.org/licenses/by/4.0/). Access for free at <https://openstax.org/books/anatomy-and-physiology/pages/17-1-an-overview-of-the-endocrine-system>
2. This work is a derivative of [Anatomy and Physiology](https://openstax.org/books/anatomy-and-physiology) by [OpenStax](https://openstax.org) licensed under [CC BY 4.0](https://creativecommons.org/licenses/by/4.0/). Access for free at <https://openstax.org/books/anatomy-and-physiology/pages/1-introduction>

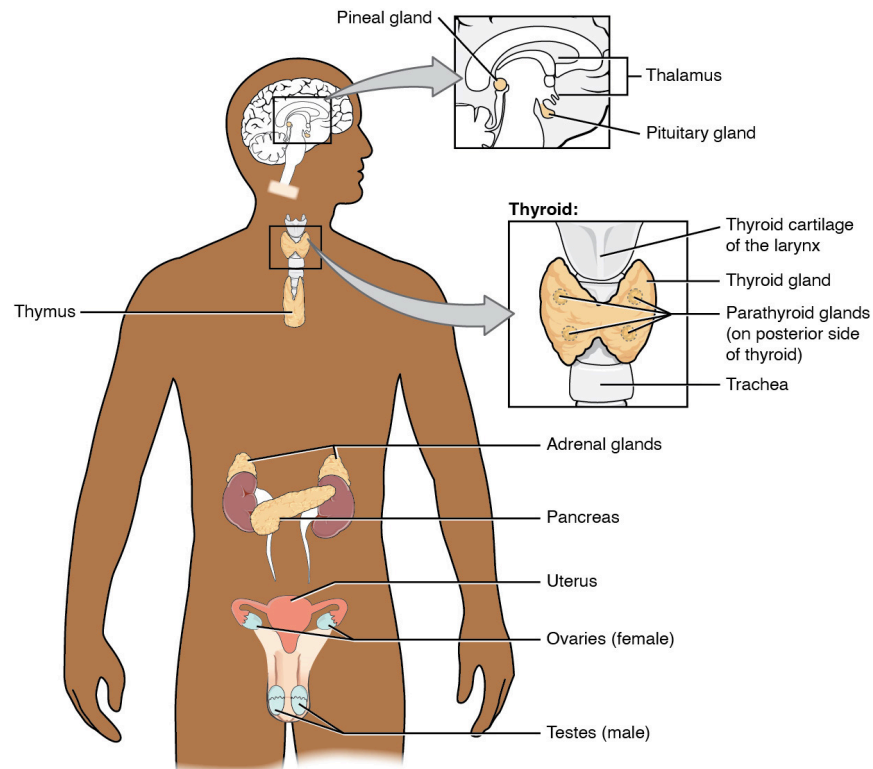


Figure 17.1 Endocrine System

Endocrine glands secrete **hormones** (HÖR-mōnz) as chemical messengers. Hormones are transported via the bloodstream throughout the body, where they bind to receptors on target cells, triggering a characteristic response. This long-distance communication is the fundamental function of the endocrine system.³

Pineal Gland

The **pineal gland** (PĪ-nē-ăl gland) is a small cone-shaped structure that extends from a ventricle of the brain. The pineal gland produces the hormone

3. This work is a derivative of [Anatomy and Physiology](https://openstax.org/books/anatomy-and-physiology/pages/1-introduction) by OpenStax licensed under CC BY 4.0. Access for free at <https://openstax.org/books/anatomy-and-physiology/pages/1-introduction>

melatonin (MĚL-ă-tō-nĭn). Melatonin affects reproductive development and daily physiological cycles.⁴

Pituitary Gland

The **pituitary gland** (pĭ-TŪ-ĭ-tĕr-ē gland) is about the size of a pea. It is a protrusion off the bottom of the hypothalamus at the base of the brain. There are two parts of the pituitary gland called the anterior and the posterior pituitary.

Anterior Pituitary Gland

The anterior pituitary gland secretes several hormones that stimulate the other endocrine glands. These hormones include **human growth hormone** (HYOO-măŋ GRŌTH HŌR-mŏn) (**HGH**), **thyroid-stimulating hormone** (THĪ-rŏid-STĪM-yŭ-lăt-ing HŌR-mŏn) (**TSH**), **adrenocorticotrophic hormone** (ă-drē-nō-kŏr-tĭ-kŏ-TRŌP-ik HŌR-mŏn) (**ACTH**), **follicle-stimulating hormone** (FŎL-ĭ-kŭl STĪM-yŭ-lăt-ing HŌR-mŏn) (**FSH**), **luteinizing hormone** (LŪ-tē-ĭ-nĭz-ing HŌR-mŏn) (**LH**), **beta endorphin** (BĀ-tă ěn-DŌR-fĭn), and **prolactin** (prŏ-LĀK-tĭn).⁵

Hypopituitarism (hĭ-pŏ-pĭ-TŪ-ĭt-ă-rizm) refers to deficient pituitary gland activity. Human growth hormone (HGH) deficiency, also known as **dwarfism** (DWŌR-fĭz-əm), is a condition caused by insufficient amounts of human growth hormone in the body. In contrast, **gigantism** (jĭ-GĀN-tĭz-əm) is caused by excessive human growth hormone in childhood that causes excessive growth and height.

4. This work is a derivative of [Anatomy and Physiology](#) by [OpenStax](#) licensed under [CC BY 4.0](#). Access for free at <https://openstax.org/books/anatomy-and-physiology/pages/1-introduction>
5. National Cancer Institute. (n.d.). *Endocrine glands & their function*. National Institutes of Health. <https://training.seer.cancer.gov/anatomy/endocrine/glands/>

Posterior Pituitary Gland

The posterior pituitary secretes **antidiuretic hormone** (ăn-tī-dī-yū-RĚT-ik HŌR-mōn) (**ADH**) that acts on the kidneys. Its effect is to regulate water reabsorption and control fluid balance. For example, if a person becomes dehydrated, the posterior pituitary releases ADH to stimulate additional water reabsorption by the kidneys and return more water to the bloodstream. In contrast, if a person becomes overhydrated from drinking too much water without other substances, the posterior pituitary decreases ADH release. In response, the kidneys decrease water reabsorption, and the excessive water is eliminated in urine output. The posterior pituitary gland also secretes the hormone oxytocin. **Oxytocin** (ők-sē-TŌ-sĭn) is a hormone that stimulates labor contractions and lactation after delivery.⁶

Thyroid Gland

The **thyroid gland** (THĪ-rōid gland) is a butterfly-shaped endocrine gland located in the neck, just below the larynx. It helps to regulate metabolic processes in the body by producing and releasing thyroid hormones called **thyroxine** (thī-RŌK-sĭn) (**T4**) and **triiodothyronine** (trī-ī-ō-dō-THĪ-rō-nĕn) (**T3**). These hormones are critical for regulating the **basal metabolic rate** (BĀ-săl MĚT-ă-bŏl-ĭk RĀT) (**BMR**), the rate at which the body burns energy while at rest. T3 and T4 control how the body uses energy and oxygen, impacting processes such as digestion, heart rate, and temperature regulation. The thyroid also secretes **calcitonin** (kăl-sĭ-TŌ-nĭn), a hormone that lowers blood calcium levels.⁷

6. This work is a derivative of [Anatomy and Physiology](#) by [OpenStax](#) licensed under [CC BY 4.0](#). Access for free at <https://openstax.org/books/anatomy-and-physiology/pages/1-introduction>

7. This work is a derivative of [Anatomy and Physiology](#) by [OpenStax](#) licensed under [CC BY 4.0](#). Access for free at <https://openstax.org/books/anatomy-and-physiology/pages/1-introduction>

Euthyroid (yū-THĪ-rōid) refers to normal thyroid gland functioning with the production of the correct amount of thyroid hormones. **Hypothyroidism** (hī-pō-THĪ-rōid-izm) refers to deficient thyroid gland activity. **Hyperthyroidism** (hī-pēr-THĪ-rōid-izm) refers to excessive thyroid gland activity. **Goiter** (GOI-tēr) is the abnormal enlargement of the thyroid gland that is a symptom of either hypothyroidism or hyperthyroidism. Read more information about hypothyroidism and hyperthyroidism in the “[Diseases and Disorders of the Endocrine System](#)” section.

Parathyroid Glands

Four small masses of tissue are embedded on the surface of the thyroid gland called **parathyroid glands** (PĀR-ă-THĪ-rōid glandz). Parathyroid glands secrete **parathyroid hormone** (PĀR-ă-THĪ-rōid HŌR-mōn) (**PTH**) that increases blood calcium levels when necessary to maintain homeostatic balance.⁸

Adrenal Glands

The **adrenal glands** (ă-DRĒ-nal glandz) are small glands located on top of each kidney. There are two parts to each adrenal gland called the adrenal cortex and the adrenal medulla.

The **adrenal cortex** (ă-DRĒ-nal KŌR-těks), the outer part of the adrenal gland, consists of three different regions, with each region producing different types of hormones called mineralocorticoids, glucocorticoids, and androgens. The principal mineralocorticoid is **aldosterone** (ăl-DŌS-tě-rōn), which acts on the kidneys to reabsorb sodium and water and return these substances to the bloodstream. The principal glucocorticoid is **cortisol** (KŌR-tī-sŏl). Cortisol helps control blood glucose, blood pressure, and metabolism. **Androgens** (ĂN-drō-jěnz) contribute to the development and maintenance of male characteristics. Androgens are secreted in minimal amounts in both

8. National Cancer Institute. (n.d.). *Endocrine glands & their function*. National Institutes of Health. <https://training.seer.cancer.gov/anatomy/endocrine/glands/>

sexes by the adrenal cortex, but their effects in females are typically masked by hormones secreted by the ovaries.⁹

The adrenal medulla, the inner part of the adrenal gland, secretes two hormones, **epinephrine** (ěp-ĩ-NĚF-rĩn) and **norepinephrine** (nôr-ěp-ĩ-NĚF-rĩn), also referred to as **catecholamines** (kăt-ě-KŌL-ă-mēns). These hormones are secreted by the nervous system in response to stress.¹⁰

Pancreas

The **pancreas** (PĀN-krē-ăs) is a long, flat gland that lies behind the stomach. The pancreas serves two functions called exocrine and endocrine roles. The **exocrine** (ĚK-sō-krĩn) role refers to the release of digestive enzymes, including amylase and lipase that help to digest food. The **endocrine** (ĚN-dō-krĩn) role refers to the production of hormones called glucagon and insulin that regulate blood glucose levels.¹¹

Glucose (GLŪ-kōs) is the preferred fuel for all body cells. The digestive system breaks down carbohydrate-containing foods and fluids into glucose, where it is absorbed into the bloodstream. Glucose is taken up by cells from the bloodstream for fuel.¹²

9. National Cancer Institute. (n.d.). *Endocrine glands & their function*. National Institutes of Health. <https://training.seer.cancer.gov/anatomy/endocrine/glands/>
10. National Cancer Institute. (n.d.). *Endocrine glands & their function*. National Institutes of Health. <https://training.seer.cancer.gov/anatomy/endocrine/glands/>
11. This work is a derivative of *Anatomy and Physiology* by OpenStax licensed under [CC BY 4.0](https://creativecommons.org/licenses/by/4.0/). Access for free at <https://openstax.org/books/anatomy-and-physiology/pages/1-introduction>
12. This work is a derivative of *Anatomy and Physiology* by OpenStax licensed

Blood glucose levels are maintained by healthy individuals' bodies between 70 mg/dL and 110 mg/dL. **Hyperglycemia** (hī-pěr-glī-SĒ-mē-ă) refers to excessively high blood glucose. **Hypoglycemia** (hī-pō-glī-SĒ-mē-ă) refers to abnormally low blood glucose. Receptors located in the pancreas sense blood glucose levels. Specialized cells called islet cells secrete glucagon or insulin to maintain normal blood glucose levels. For example, if blood glucose levels rise above normal range, **insulin** (ĪN-sū-lĭn) is released, which facilitates the uptake of glucose into cells. However, if blood glucose levels drop below normal range, **glucagon** (GLŪ-kă-gŏn) is released, which stimulates the liver cells to release more glucose into the bloodstream.¹³

Ovaries and Testes

The ovaries and testes are responsible for producing ova and sperm and also secrete hormones.

In females, ovaries secrete **estrogen** (ēs-trō-jĕn) and **progesterone** (prō-JĔS-tĕ-rŏn). At the onset of puberty, estrogen promotes the development of breasts and the maturation of the uterus. Progesterone causes the uterine lining to thicken in preparation for pregnancy. Together, progesterone and estrogen are responsible for the changes that occur in the uterus during the menstrual cycle.¹⁴

under [CC BY 4.0](https://openstax.org/books/anatomy-and-physiology/pages/1-introduction). Access for free at <https://openstax.org/books/anatomy-and-physiology/pages/1-introduction>

13. This work is a derivative of *Anatomy and Physiology* by OpenStax licensed under [CC BY 4.0](https://openstax.org/books/anatomy-and-physiology/pages/1-introduction). Access for free at <https://openstax.org/books/anatomy-and-physiology/pages/1-introduction>

14. National Cancer Institute. (n.d.). *Gonads*. National Institutes of Health. <https://training.seer.cancer.gov/anatomy/endocrine/glands/gonads.html>

In males, testes secrete **testosterone** (tēs-TŌS-tě-rōn). At the onset of puberty, testosterone is responsible for the following actions¹⁵:

- Growth and development of the male reproductive structures
- Increased skeletal and muscular growth
- Enlargement of the larynx accompanied by a deepening voice
- Growth and distribution of body hair

15. National Cancer Institute. (n.d.). *Gonads*. National Institutes of Health.
<https://training.seer.cancer.gov/anatomy/endocrine/glands/gonads.html>

17.5 Physiology of the Endocrine System


The endocrine system communicates with other parts of the body by secreting hormones from the endocrine glands. Hormones are transported primarily via the bloodstream throughout the body. Each hormone binds to receptors on specific target cells, creating a desired response.¹

For example, when a person is exposed to a dangerous situation, the “**fight-or-flight response**” (fīt-ŏr-flīt rĭ-spŏns) occurs. The fight-or-flight response is triggered by the release of epinephrine and norepinephrine hormones from the adrenal gland. These hormones act on target organs like the heart (to beat faster), the lungs (to breathe more efficiently), and blood vessels to the skeletal muscles (to provide more oxygenated blood with glucose for energy). These targeted actions are intended to help the individual to fight or run away from the dangerous situation.²

Although hormones travel throughout the body, they only affect cells with receptors for that particular hormone, called target cells. After the hormone binds to the receptor, a chain of events is initiated that leads to the target cell’s response. Hormones play a critical role in the regulation of physiological

1. This work is a derivative of [Anatomy and Physiology](https://openstax.org/books/anatomy-and-physiology/pages/1-introduction) by [OpenStax](https://openstax.org/books/anatomy-and-physiology/pages/1-introduction) licensed under [CC BY 4.0](https://creativecommons.org/licenses/by/4.0/). Access for free at <https://openstax.org/books/anatomy-and-physiology/pages/1-introduction>
2. This work is a derivative of [Anatomy and Physiology](https://openstax.org/books/anatomy-and-physiology/pages/1-introduction) by [OpenStax](https://openstax.org/books/anatomy-and-physiology/pages/1-introduction) licensed under [CC BY 4.0](https://creativecommons.org/licenses/by/4.0/). Access for free at <https://openstax.org/books/anatomy-and-physiology/pages/1-introduction>

processes such as metabolism, growth and development of body tissues, fluid, electrolyte balance, sleep, and reproduction.³

View a supplementary YouTube video⁴ on hormones by
 Crash Course: [Endocrine System, Part 2 – Hormone Cascades: Crash Course Anatomy & Physiology #24](#)

3. This work is a derivative of [Anatomy and Physiology](#) by [OpenStax](#) licensed under [CC BY 4.0](#). Access for free at <https://openstax.org/books/anatomy-and-physiology/pages/1-introduction>

4. CrashCourse. (2015, June 29). *Endocrine system, Part 2 – Hormone cascades: Crash Course Anatomy & Physiology #24* [Video]. YouTube. All rights reserved. https://www.youtube.com/watch?v=SCV_m9ImN-Q

17.6 Diseases and Disorders of the Endocrine System

ACROMEGALY

Acromegaly (ak-rō-MEG-ă-lē) is an endocrine disorder in adults caused when abnormally high levels of human growth hormone (HGH) trigger additional growth of the bones in the face, hands, and feet. Because the growth plates are closed in adults, the bones grow wider and thicker. In most cases, acromegaly is caused by a benign tumor in the pituitary gland, called a pituitary **adenoma** (ăd-ě-NŌ-mă). Treatment may include surgery, medications, and/or radiation therapy to remove or control tumor size and return HGH levels back to normal.¹ See Figure 17.2² for an image of a man with acromegaly with enlarged bones in the face and hands.

1. National Institute of Diabetes and Digestive and Kidney Disorders. (2020, January). *Acromegaly*. National Institutes of Health.
<https://www.niddk.nih.gov/health-information/endocrine-diseases/acromegaly>
2. “[Man showing the characteristic appearances of acromegaly Wellcome L0062529.jpg](#)” by unknown author via [Wellcome Collection Gallery](#) and is licensed under [CC BY 4.0](#)




Figure 17.2 Acromegaly

ADDISON'S DISEASE

Addison's disease (ăd-ĭ-Sŏnz dĩ-ZĒZ) is a disorder in which the adrenal glands don't produce enough cortisol and aldosterone hormones, also called **adrenal insufficiency** (ă-drē-năl ĭn-sŭ-fĭsh-ĕn-sē). Decreased cortisol results in **hypoglycemia** (hĭ-pŏ-glĭ-SĒ-mē-ă), which is low blood glucose levels. Because aldosterone helps maintain the balance of sodium and potassium in the blood and regulates blood pressure, low aldosterone levels cause **hypotension** (hĭ-pŏ-TĒN-shŭn), which is low blood pressure. Other symptoms of Addison's disease are fatigue, muscle weakness, loss of appetite, weight loss, and abdominal pain. The most serious complication of adrenal

insufficiency is called adrenal crisis. If not treated right away, adrenal crisis can cause death.^{3,4}

Adrenal insufficiency is commonly diagnosed by an ACTH stimulation test. In this diagnostic test, ACTH is administered intravenously (IV), and then blood samples are taken to measure cortisol levels in the blood. The normal response is a rise in blood cortisol levels, but people with Addison's disease have little or no increase in cortisol levels. Treatment of Addison's disease consists of hormone replacement medication to restore normal levels of cortisol and aldosterone.^{5,6}

3. National Institute of Diabetes and Digestive and Kidney Diseases. (n.d.). *Adrenal insufficiency & Addison's disease*. National Institutes of Health. <https://www.niddk.nih.gov/health-information/endocrine-diseases/adrenal-insufficiency-addisons-disease>
4. Mayo Clinic. (2022, December 8). *Addison's disease*. <https://www.mayoclinic.org/diseases-conditions/addisons-disease/symptoms-causes/syc-20350293>
5. National Institute of Diabetes and Digestive and Kidney Diseases. (n.d.). *Adrenal insufficiency & Addison's disease*. National Institutes of Health. <https://www.niddk.nih.gov/health-information/endocrine-diseases/adrenal-insufficiency-addisons-disease>
6. Mayo Clinic. (2022, December 8). *Addison's disease*. <https://www.mayoclinic.org/diseases-conditions/addisons-disease/symptoms-causes/syc-20350293>

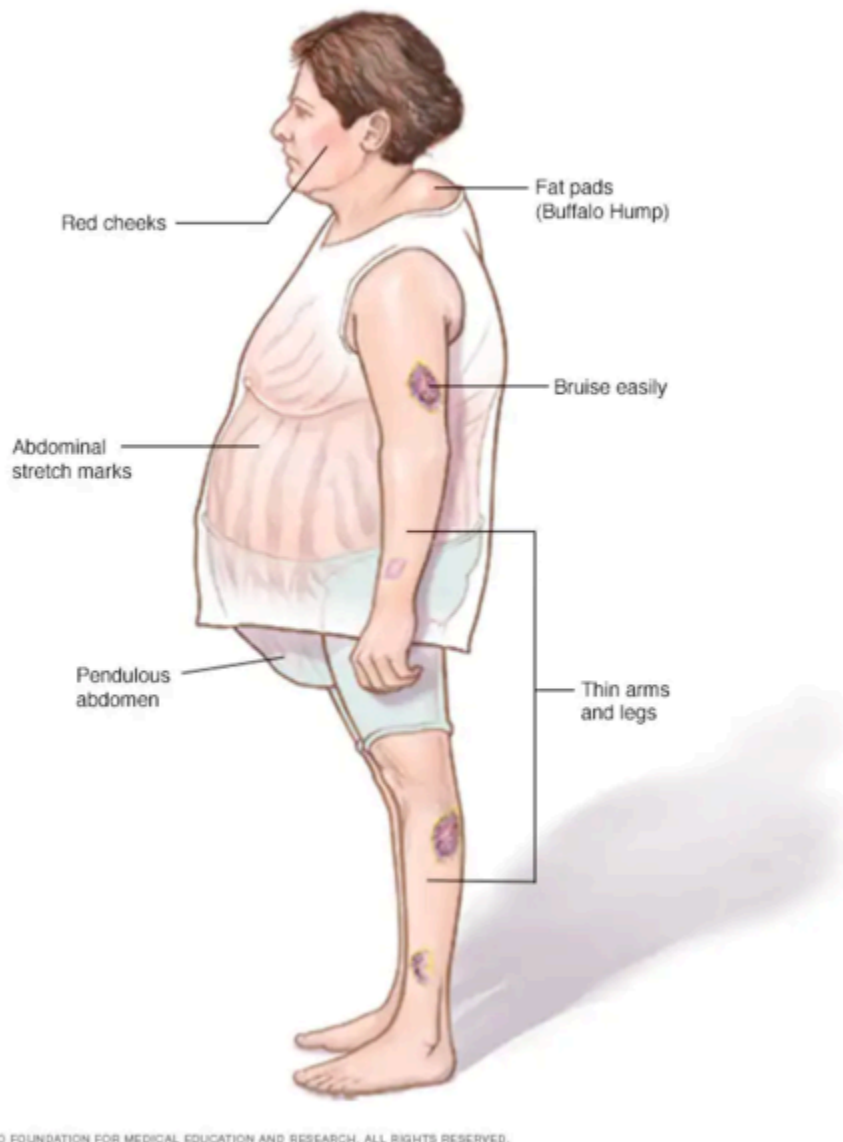
CUSHING'S DISEASE AND CUSHING'S SYNDROME

Cushing's disease (KŪSH-īngz dī-ZĒZ) is a disorder caused by the excessive secretion of cortisol, resulting in **hyperglycemia** (hī-pĕr-glī-SĒ-mē-ă), which is elevated blood glucose levels. A common cause of Cushing's disease is a pituitary tumor. **Cushing's syndrome** (KŪSH-īngz SĪN-drōm) happens when the body makes too much cortisol, or the person is taking medications called glucocorticoids that affect the body the same way as cortisol. A **syndrome** (SĪN-drōm) refers to signs and symptoms that occur together that are characteristic of a specific disorder.

Too much cortisol causes symptoms such as a fatty hump between the shoulders, thin legs and arms, a round face, easy bruising, and pink or purple stretch marks on the skin called **striae** (STRĪ-ē). See Figure 17.3⁷ for an illustration of a person with Cushing's syndrome. It can also cause high blood pressure, bone loss, poor wound healing, and type 2 diabetes. Treatment depends on the cause. If glucocorticoid medications are being taken, their use is reduced or eliminated, if possible. If a tumor is the cause, then it is removed by surgery or reduced in size by radiation therapy. Medications may also be prescribed to control the body's production of cortisol.⁸

7. "[Cushing's Syndrome.webp](#)" by [Mayo Clinic](#) is licensed under [CC BY-SA 4.0](#)

8. Mayo Clinic. (2023, June 7). *Cushing's syndrome*. <https://www.mayoclinic.org/diseases-conditions/cushing-syndrome/symptoms-causes/syc-20351310>



© MAYO FOUNDATION FOR MEDICAL EDUCATION AND RESEARCH. ALL RIGHTS RESERVED.

Figure 17.3 Cushing's Syndrome

DIABETES INSIPIDUS

Diabetes insipidus (dī-ă-BĒ-tēz in-SIP-ĭ-dŭs) (**DI**) is condition caused by a lack of antidiuretic hormone (ADH). It is characterized by large amounts of very dilute urine, referred to as **polyuria** (pŏl-ē-YŌŌR-ē-ă). While most people make 1 to 3 quarts of urine a day, people with diabetes insipidus can make up

to 20 quarts of urine a day. See Figure 17.4⁹ for an image of dilute urine seen in polyuria. DI is often treated with medication that mimics the effects of ADH. Note that diabetes insipidus is not the same as diabetes mellitus. Although both conditions can increase thirst and polyuria, they are not related.¹⁰

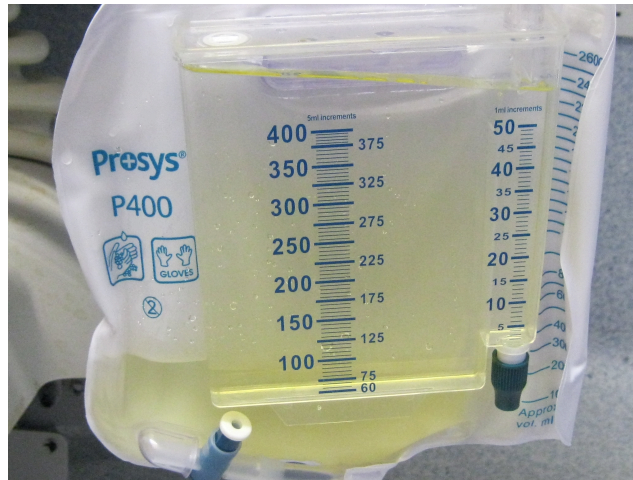

Figure 17.4 Dilute Urine Seen in Polyuria

DIABETES MELLITUS

Diabetes mellitus (dī-ă-BĒ-tēz MĒL-ĭ-tŭs) (**DM**) refers to disorders that cause hyperglycemia (high levels of glucose in the blood). Over time, hyperglycemia damages the blood vessels in the heart, kidneys, feet, and eyes.

9. “31388976010_b0750ceed4_k.jpg” by [John Campbell](#) is licensed in the [Public Domain](#).
10. National Institute of Diabetes and Digestive and Kidney Disease. (2021, September). *Diabetes insipidus*. National Institutes of Health. <https://www.niddk.nih.gov/health-information/kidney-disease/diabetes-insipidus>

There are different types of diabetes called type 1, type 2, and gestational. **Type 1 diabetes** (tīp wŭn dī-ă-BĒ-tēz) is caused by an autoimmune disease that destroys the cells of the pancreas that create insulin. In **type 2 diabetes** (tīp tōō dī-ă-BĒ-tēz), the cells of the body do not use insulin effectively to facilitate the uptake of glucose for energy. Additionally, the pancreas may not be making enough insulin to maintain blood glucose levels within normal range. **Gestational diabetes** (jēs-TĀ-shŭn-ăl dī-ă-BĒ-tēz) refers to a type of diabetes that develops during pregnancy. Gestational diabetes typically goes away after the baby is born, but it increases the risk of the mother for developing type 2 diabetes later in life.

Common symptoms of untreated diabetes are:

- **Polydipsia** (pŏl-ē-DĪP-sē-ă): Excessive thirst
- **Polyuria** (pŏl-ē-YŌŌR-ē-ă): Excessive urine output
- **Polyphagia** (pŏl-ē-FĀ-jē-ă): Excessive hunger/eating

Diabetes mellitus is diagnosed with blood tests that evaluate blood glucose levels, including the following tests:

- **Fasting blood glucose** (FĀST-ing blŭd GLŪ-kōs) (**FBG**): Assesses an individual's blood glucose level when they have had no caloric intake for at least eight hours. The normal fasting blood glucose range is between 70-100 mg/dL. **Hypoglycemia** (hī-pō-glī-SĒ-mē-ă) refers to an abnormally low blood glucose level below 70 mg/dL.
- **Random blood glucose** (răn-dŏm blŭd GLŪ-kōs): Measures the level of glucose in the blood at any given time, without the requirement for fasting.
- **Hemoglobin A1C** (HĒ-mō-glō-bĭn Ā-wŭn-SĒ) (**HbA1C**): Assesses an individual's average blood glucose levels over the preceding two to three months. HbA1C is a form of hemoglobin. When glucose is in the bloodstream, it attaches to hemoglobin, forming glycated hemoglobin. The normal range for HbA1C is typically less than 5.7%.
- **Oral glucose tolerance test** (ŌR-ăl GLŪ-kōs TŌL-ěr-ăns tĕst) (**OGTT**): Evaluates the body's ability to regulate blood glucose levels, especially after consuming a high dose of glucose. The results are typically reported

as blood glucose levels measured at different time points (such as fasting one hour post-glucose consumption and two hours post-glucose consumption). Elevated blood glucose levels at any of these time points indicate diabetes. This test is often performed during pregnancy to assess for gestational diabetes.

People with diabetes must monitor their blood glucose levels and often adjust their medications based on these levels. See Figure 17.4¹¹ for an image of a blood glucose monitor typically used in hospital and home settings.¹²

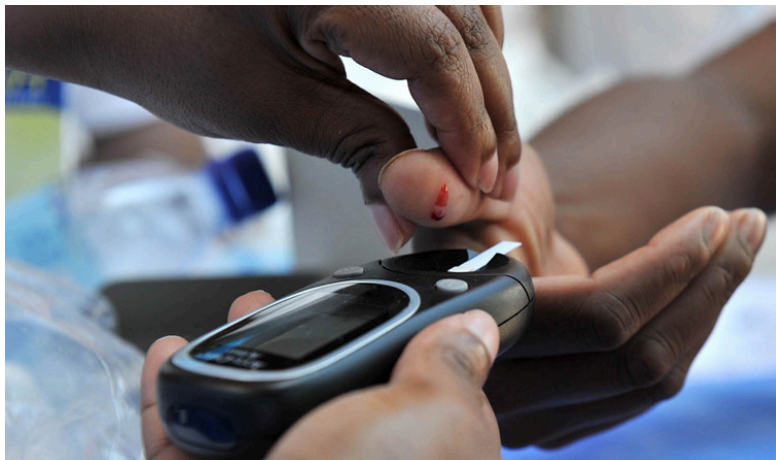


Figure 17.4 Blood Glucose Monitoring Device

Diabetes is treated with insulin injections, oral medications, or inhaler medications. Some people with type 1 diabetes have insulin pumps they wear

11. “8286152103_b624d39f68_c.jpg” by [GovernmentZA](#) is licensed under [CC BY-ND 2.0](#)

12. National Institute of Diabetes and Digestive and Kidney Diseases. (n.d.). *Diabetes*. National Institutes of Health. <https://www.niddk.nih.gov/health-information/diabetes>

outside of their body that deliver steady doses of insulin to mimic the function of the pancreas.¹³

A potentially life-threatening complication of type 1 diabetes is **diabetic ketoacidosis** (dī-ă-BĔT-ĭk kē-tō-ăs-ĭ-DŌ-sĭs) (**DKA**). DKA develops when the body breaks down fatty acids for energy when there isn't enough insulin to facilitate the uptake of glucose into cells. As a result, excessive ketones are created, causing the body to become acidic. Treatment includes intravenous administration of insulin, fluids, and electrolytes to restore normal body functioning.

Gigantism

Gigantism (jĭ-GĀN-tĭz-əm) is a rare endocrine condition characterized by excessive growth and height significantly above average. This condition is caused by the overproduction of human growth hormone (HGH) in childhood, often due to an HGH-secreting pituitary tumor. Treatment for gigantism is based on the cause and may include surgery or radiation to remove or shrink the tumor.¹⁴ See Figure 17.5¹⁵ for an image of an individual with gigantism compared to an individual of average height.

13. National Institute of Diabetes and Digestive and Kidney Diseases. (n.d.). *Diabetes*. National Institutes of Health. <https://www.niddk.nih.gov/health-information/diabetes>

14. Cleveland Clinic. (2022, May 9). *Gigantism*. National Institutes of Health. <https://my.clevelandclinic.org/health/diseases/22954-gigantism>

15. “[Robert Wadlow postcard.jpg](#)” by unknown author is licensed in the [Public Domain](#).



Figure 17.5 Gigantism

Hirsutism

Hirsutism (HĪR-sū-tīz-əm) refers to the overgrowth of hair in women, such as on the chin and face, due excessive production of androgens. See Figure 17.6¹⁶ for an image of hirsutism. Hirsutism is caused by endocrine disorders such as polycystic ovary syndrome (PCOS) and Cushing's syndrome or from side effects of certain medications. Treatment may include medications or hair removal options.¹⁷

16. “[PMC4103002_ircmj-16-9410-g001.png](#)” by Gacaferri Lumezi B. et al., is licensed under [CC BY 3.0](#)

17. Cleveland Clinic. (2022, July 8). *Hirsutism*. <https://my.clevelandclinic.org/health/diseases/14523-hirsutism>

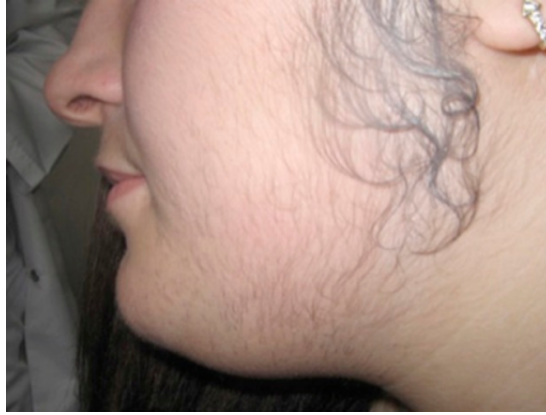

Figure 17.6 Hirsutism

HYPERPARATHYROIDISM

Hyperparathyroidism (hī-pěr-PĀR-ă-THĪ-rōid-izm) refers to a condition in which the parathyroid glands produce too much parathyroid hormone (PTH), leading to **hypercalcemia** (hī-pěr-kāl-SĒ-mē-ă), which is excessive calcium in the blood. Treatment is based on the cause. For example, if the condition is caused by a tumor on one or more of the parathyroid gland(s), a **parathyroidectomy** (păr-ă-thī-royd-ĖK-tō-mē) is performed to remove the affected parathyroid gland.¹⁸

HYPERTHYROIDISM

Hyperthyroidism (hī-pěr-THĪ-rōid-izm) refers to abnormally high levels of thyroid hormones (i.e., T3 and T4) that cause increased metabolism and

18. Mayo Clinic. (2022, May 17). *Hyperparathyroidism*. <https://www.mayoclinic.org/diseases-conditions/hyperparathyroidism/diagnosis-treatment/drc-20356199>

symptoms like unintended weight loss, profuse sweating, and increased heart rate. Conditions that can cause hyperthyroidism are as follows:

- **Grave's disease** (GRĀVZ dī-ZĒZ): An autoimmune disorder of the thyroid gland causing the production of excess thyroid hormones
- **Adenomas** (ăd-ě-NŌ-măz): Overactive thyroid nodules that produce thyroid hormones
- **Thyroiditis** (thī-royd-ĪT-is): Inflammation of the thyroid gland

A classic symptom of Grave's disease is **exophthalmos** (ek-saaf-thal-muhs), which refers to bulging eyes. See Figure 17.7¹⁹ for an image of exophthalmos.

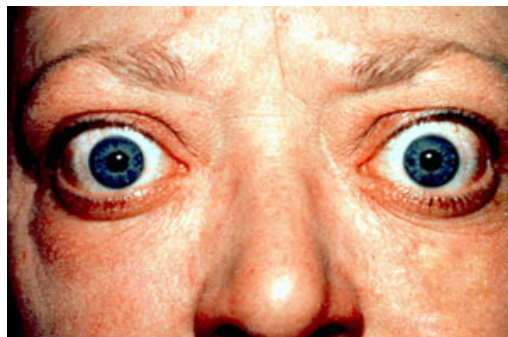

Figure 17.7 Exophthalmos

Several treatments are available for hyperthyroidism, such as antithyroid medications, radioactive iodine therapy, or surgery to remove all or part of the thyroid gland, referred to as a **thyroidectomy** (thī-royd-EK-tō-mē).²⁰

19. “[Proptosis and lid retraction from Graves%27 Disease.jpg](#)” by Jonathan Trobe, M.D. – University of Michigan Kellogg Eye Center is licensed under [CC BY 3.0](#)

20. Mayo Clinic. (2022, November 30). *Hyperthyroidism*.
<https://www.mayoclinic.org/diseases-conditions/hyperthyroidism/symptoms-causes/syc-20373659>

HYPOPARATHYROIDISM

Hypoparathyroidism (hī-pō-pär-ă-THĪ-rōid-izm) is a condition in which the parathyroid glands do not produce enough parathyroid hormone (PTH), leading to **hypocalcemia** (hī-pō-kāl-SĒ-mē-ă), low levels of calcium in the blood. Hypoparathyroidism can be caused by accidental damage to the parathyroid glands during thyroid or neck surgery or due to an autoimmune disease. It is treated with parathyroid hormone replacement and supplements like calcium and vitamin D.²¹

HYPOTHYROIDISM

Hypothyroidism (hī-pō-THĪ-rōid-izm) refers to abnormally low levels of thyroid hormones (T3 and T4) produced by the thyroid gland. Symptoms include unintended weight gain, fatigue, constipation, cold sensitivity, and memory problems. A **goiter** (GOI-tēr) is a symptom of hypothyroidism and hyperthyroidism and is an abnormal enlargement of the thyroid gland. See Figure 17.8²² for an image of a goiter. Hypothyroidism is treated with lifelong thyroid hormone replacement medication and routine blood tests to maintain normal blood levels of thyroid hormones.²³

21. Mayo Clinic. (2022, May 11). *Hypoparathyroidism*. <https://www.mayoclinic.org/diseases-conditions/hypoparathyroidism/symptoms-causes/syc-20355375>

22. “Goiter.JPG” by Dr. J.S.Bhandari, India is licensed under [CC BY-SA 3.0](#)

23. Mayo Clinic. (2022, December 10). *Hypothyroidism*. <https://www.mayoclinic.org/diseases-conditions/hypothyroidism/symptoms-causes/syc-20350284>

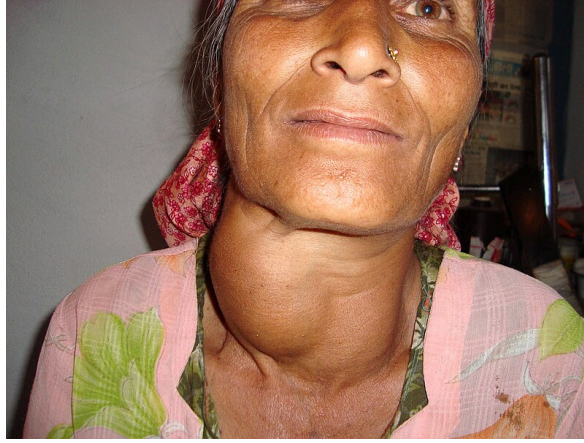


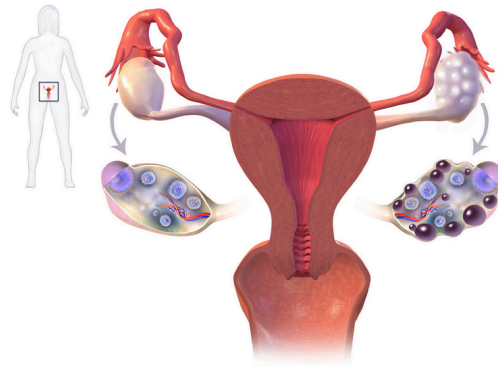
Figure 17.8 Goiter Caused by Hypothyroidism

POLYCYSTIC OVARY SYNDROME

Polycystic ovary syndrome (pŏl-ē-SĭS-tĭk Ō-vă-r-ē SĭN-drŏm) (**PCOS**) is a common hormone problem for women of childbearing age. Women with PCOS have multiple small cysts on the ovaries and may not ovulate. See Figure 17.9²⁴ for an illustration of PCOS. They may have high levels of androgens. PCOS can cause missed or irregular menstrual periods, hirsutism (excessive hair growth), acne, infertility, and unintended weight gain.²⁵

24. “PCOS_28Part_229.png” by BruceBlaus is licensed under CC BY-SA 4.0

25. Johns Hopkins Medicine. (n.d.). *Polycystic ovary syndrome (PCOS)*.
<https://www.hopkinsmedicine.org/health/conditions-and-diseases/polycystic-ovary-syndrome-pcos>



Polycystic Ovary Syndrome

Figure 17.9 PCOS

17.7 Medical Specialists, Diagnostic Testing, and Procedures Related to the Endocrine System

MEDICAL SPECIALISTS

Endocrinology (ĕn-dō-krĭ-NŌL-ŏ-jē) refers to the study of the endocrine system.

Endocrinologists

Endocrinologists (ĕn-dō-krĭ-NŌL-ŏ-jĭsts) are physicians who specialize in diagnosing and treating diseases associated with the endocrine system.

Endocrine surgeons (ĕn-dō-krĭn SŪR-jŏns) treat endocrine disease by removing affected endocrine gland or tissue.

▶ Read more information about endocrinologists on the [American Association of Clinical Endocrinology's web page](#).

Diabetes Nurse Educator

Diabetes nurse educators are registered nurses who specialize in helping people effectively self-manage the chronic disease of diabetes mellitus. They

provide instruction on monitoring blood glucose levels, administering insulin, making healthy diet choices, and caring for feet and skin to prevent complications.¹

- ▶ Read more on Indeed's web page: [How to Become a Diabetes Educator in 5 Steps](#).

Dietitians and Nutritionists

Dietitians and nutritionists often help people diagnosed with diabetes mellitus plan appropriate diets to manage their disease and lead healthy lives. They typically have a bachelor's degree and work in many settings, including hospitals, nursing homes, and clinics.

- ▶ Read more information on the Bureau of Labor's web page about [Dietitians and Nutritionists](#).

Diagnostic Testing

Blood Tests

Blood serum testing is done to determine the levels of various endocrine hormones in the blood if an endocrine disorder is suspected. Additional testing may be performed to monitor electrolyte levels in the blood, such as

1. DailyNurse. (n.d.). *Diabetes educator*. <https://dailynurse.com/diabetes-educator/#:~:text=The%20diabetic%20nurse%20educator%20establishes,glucose%3B%20and%20administration%20of%20insulin>

sodium, potassium, and calcium. Read more about specific blood tests performed for specific diseases in the “[Diseases and Disorders of the Endocrine System](#)” section.

Radioactive Iodine Uptake

A **radioactive iodine uptake** (rā-dē-ō-ĀK-tīv Ī-ō-dīn ŪP-tāk) test evaluates how well the thyroid is functioning by administering radioactive iodine and then measuring how much is taken up by the thyroid. This test is often performed in combination with a thyroid scan.²

Thyroid Scan

A thyroid scan uses a radioactive iodine tracer to examine the structure and function of the thyroid gland. This test is often done in combination with a radioactive iodine uptake test. The scanner detects the location and intensity of the rays given off by the radioactive material, and a computer displays images of the thyroid gland.³

PROCEDURES

Surgeries related to the endocrine system include the following:

2. A.D.A.M. Medical Encyclopedia [Internet]. Atlanta (GA): A.D.A.M., Inc.; c1997-2023. Radioactive iodine uptake; [reviewed 2022, Jan 9; cited 2023, Dec 4). <https://medlineplus.gov/ency/article/003689.htm>
3. A.D.A.M. Medical Encyclopedia [Internet]. Atlanta (GA): A.D.A.M., Inc.; c1997-2023. Thyroid scan; [reviewed 2022, Feb 1; cited 2023, Dec 4). <https://medlineplus.gov/ency/article/003829.htm>

- **Adrenalectomy** (ăd-rē-năl-ĔK-tŏ-mē): Surgical excision of one or more adrenal glands.
- **Hypophysectomy** (hī-pō-fī-SĔK-tŏ-mē): Surgical removal of the pituitary gland.
- **Pancreatectomy** (păn-krē-ă-TĔK-tŏ-mē): Surgical removal of the pancreas.
- **Parathyroidectomy** (păr-ă-thī-rŏi-DĔK-tŏ-mē): Surgical removal of one or more of the parathyroid glands.
- **Thyroidectomy** (thī-rŏi-DĔK-tŏ-mē): Surgical removal of all or part of the thyroid gland.

17.8 Endocrine Learning Activities

Interactive Learning Activity: Practice labelling the parts of the endocrine system.



An interactive H5P element has been excluded from this version of the text. You can view it online here:

<https://wtcs.pressbooks.pub/medterm/?p=569#h5p-128>

Interactive Learning Activity: Study endocrine system medical terms discussed in this chapter.



An interactive H5P element has been excluded from this version of the text. You can view it online here:

<https://wtcs.pressbooks.pub/medterm/?p=569#h5p-193>

Interactive Learning Activity: Test yourself on these endocrine system terms.



An interactive H5P element has been excluded from this version of the text. You can view it online here:

<https://wtcs.pressbooks.pub/medterm/?p=569#h5p-159>

Interactive Learning Activity: Using the sample documentation provided, drag the terms on the right to

their appropriate spaces within the documentation.



An interactive H5P element has been excluded from this version of the text. You can view it online here:

<https://wtcs.pressbooks.pub/medterm/?p=569#h5p-131>

Interactive Learning Activity: Using the sample documentation provided, drag the terms on the right to their appropriate spaces within the documentation.



An interactive H5P element has been excluded from this version of the text. You can view it online here:

<https://wtcs.pressbooks.pub/medterm/?p=569#h5p-132>



Interactive Learning Activity: Practice identifying and defining word parts for terms discussed in this chapter.



An interactive H5P element has been excluded from this version of the text. You can view it online here:

<https://wtcs.pressbooks.pub/medterm/?p=569#h5p-209>

- ▶ You can also print this as a [Chapter 17 Practice Worksheet](#) and check your answers with this [Answer Key PDF](#).

17.9 Glossary

Acromegaly (ak-rō-MEG-ă-lē): A disorder in adults caused by excessive production of growth hormone, leading to enlargement of bones in face, hands, and feet. ([Chapter 17.6](#))

Addison's disease (ăd-ĭ-Sōnz dī-ZĒZ): A disorder where the adrenal glands produce insufficient cortisol and aldosterone, leading to symptoms like hypoglycemia and hypotension. ([Chapter 17.6](#))

Adenoma (ăd-ě-NŌ-mă): A benign tumor that arises in or resembles glandular tissue. ([Chapter 17.6](#))

Adrenal cortex (ă-DRĒ-nal KŌR-těks): The outer portion of the adrenal glands that produces hormones like cortisol, aldosterone, and androgens. ([Chapter 17.4](#))

Adrenalectomy (ăd-rē-năl-ĖK-tŏ-mē): Surgical excision of one or more of the adrenal glands. ([Chapter 17.7](#))

Adrenal glands (ă-DRĒ-nal glandz): Endocrine glands located on top of each kidney, consisting of the adrenal cortex and adrenal medulla, producing various hormones including aldosterone, cortisol, and catecholamines. ([Chapter 17.4](#))

Adrenal insufficiency (ă-drē-năl ĩn-sŭ-fĭsh-ĕn-sē): A medical condition where the adrenal glands fail to produce sufficient amounts of steroid hormones, particularly cortisol and aldosterone, leading to symptoms like fatigue, muscle weakness, and low blood pressure. ([Chapter 17.6](#))

Adrenocorticotrophic hormone (ă-drē-nŏ-kŏr-tĭ-kŏ-TRŌP-ik HŌR-mŏn) (ACTH): A hormone produced by the pituitary gland, stimulating the adrenal cortex to produce cortisol and other hormones. ([Chapter 17.4](#))

Aldosterone (ăl-DŌS-tě-rŏn): A hormone produced by the adrenal cortex that helps regulate blood pressure and electrolyte balance by signaling the kidneys to absorb sodium and excrete potassium. ([Chapter 17.4](#))

Androgens (ĂN-drŏ-jĕnz): Male sex hormones produced in small amounts by both sexes, primarily in the adrenal cortex, and involved in the development of male characteristics. ([Chapter 17.4](#))

Antidiuretic hormone (ăn-tī-dī-yū-RĚT-ik HŌR-mōn) (ADH): A hormone produced by the pituitary gland that regulates water balance in the body by controlling the amount of water reabsorbed by the kidneys. ([Chapter 17.4](#))

Basal metabolic rate (BĀ-sāl MĚT-ă-bŏl-ĭk RĀT) (BMR): The rate at which the body uses energy while at rest to maintain vital functions such as breathing and temperature regulation. ([Chapter 17.4](#))

Beta endorphin (BĀ-tă ěn-DŌR-fĭn): A natural opioid peptide hormone produced in the brain and pituitary gland, involved in pain relief and feelings of well-being. ([Chapter 17.4](#))

Calcitonin (kăl-sĭ-TŌ-nĭn): A hormone produced by the thyroid gland that helps regulate calcium levels in the blood by reducing the concentration of calcium. ([Chapter 17.4](#))

Catecholamines (kăt-ě-KŌL-ă-mēns): Hormones produced by the adrenal medulla, including epinephrine and norepinephrine, which are involved in the body's stress response. ([Chapter 17.4](#))

Cortisol (KŌR-tĭ-sŏl): A glucocorticoid hormone produced by the adrenal cortex, playing a vital role in stress response, metabolism, and immune response regulation. ([Chapter 17.4](#))

Cushing's disease (KŪSH-ĭngz dĭ-ZĚZ): A condition caused by excessive cortisol production, often due to a pituitary tumor, leading to symptoms like weight gain and high blood sugar. ([Chapter 17.6](#))

Cushing's syndrome (KŪSH-ĭngz SĪN-drŏm): A condition characterized by the body's prolonged exposure to high levels of cortisol, which may be caused by the use of steroid medication or by tumors that increase cortisol production. ([Chapter 17.6](#))

Diabetes insipidus (dĭ-ă-BĚ-tēz in-SIP-ĭ-dŭs) (DI): A condition characterized by excessive production of dilute urine, due to a deficiency in antidiuretic hormone (ADH). ([Chapter 17.6](#))

Diabetes mellitus (DM) (dĭ-ă-BĚ-tēz MĚL-ĭ-tŭs): A group of metabolic disorders characterized by high blood sugar levels over a prolonged period due to insulin deficiency and/or resistance. ([Chapter 17.6](#))

Diabetic ketoacidosis (dĭ-ă-BĚT-ĭk kē-tŏ-ăs-ĭ-DŌ-sĭs) (DKA): A serious complication of diabetes that occurs when the body produces high levels of

blood acids called ketones, typically due to a severe lack of insulin. ([Chapter 17.6](#))

Dwarfism (DWÔR-fĭz-əm): A condition characterized by short stature, often resulting from a genetic or medical condition, such as a deficiency in growth hormone. ([Chapter 17.4](#))

Endocrine (ĔN-dō-krĭn): Pertaining to glands that secrete hormones directly into the bloodstream. The pancreas serves an endocrine function by producing hormones like insulin and glucagon. ([Chapter 17.4](#))

Endocrine surgeons (ĕn-dō-krĭn SŪR-jōns): Medical specialists who perform surgical procedures on the endocrine glands, such as the thyroid, parathyroid, and adrenal glands, to treat various endocrine disorders and diseases. ([Chapter 17.7](#))

Endocrinologists (ĕn-dō-krĭ-NŌL-ŏ-jĭsts): Physicians who specialize in studying and treating diseases associated with the endocrine system. ([Chapter 17.7](#))

Endocrinology (ĕn-dō-krĭ-NŌL-ŏ-jē): The study of the structure, function, and disorders of the endocrine system. ([Chapter 17.7](#))

Epinephrine (ĕp-ĭ-NĔF-rĭn): Also known as adrenaline, a hormone produced by the adrenal medulla, playing a key role in the fight-or-flight response by increasing heart rate and blood flow. ([Chapter 17.4](#))

Estrogen (ĔS-trō-jĕn): A group of hormones primarily responsible for the development and regulation of female reproductive system and secondary sex characteristics. ([Chapter 17.4](#))

Euthyroid (yū-THĪ-rōid): A term that describes normal thyroid gland functioning, with the production of the correct amount of thyroid hormones. ([Chapter 17.4](#))

Exocrine (ĔK-sō-krĭn): Referring to glands that secrete their products through ducts to the surface of an organ or tissue or into a vessel. In the context of the pancreas, it refers to the production of digestive enzymes. ([Chapter 17.4](#))

Exophthalmos (ek-saaf-thal-muhs): A medical term for bulging eyes, a symptom of hyperthyroidism. ([Chapter 17.6](#))

Fasting blood glucose (FĀST-ing blŭd GLŪ-kōs) (FBG): A test that

measures blood sugar levels after an individual has not eaten for at least 8 hours, used to diagnose diabetes. ([Chapter 17.6](#))

Fight-or-flight response (fīt-ör-flīt rī-spōns): A physiological reaction characterized by the increased production of hormones like adrenaline and norepinephrine in response to a perceived threat or stress, resulting in various bodily changes like increased heart rate, blood pressure, and energy levels, preparing the body for either confrontation or rapid retreat. ([Chapter 17.5](#))

Follicle-stimulating hormone (FÖL-ī-kŭl STĪM-yū-lāt-ing HÖR-mōn) (FSH): A hormone produced by the pituitary gland that stimulates the growth of ovarian follicles in females and sperm production in males. ([Chapter 17.4](#))

Gestational diabetes (jēs-TĀ-shŭn-ăl dī-ă-BĒ-tēz): A form of diabetes that manifests during pregnancy, involving elevated blood glucose levels, and generally resolves after the baby's birth, although it can increase the risk of developing type 2 diabetes later in life. ([Chapter 17.6](#))

Gigantism (jī-GĀN-tīz-əm): A rare condition caused by excessive production of growth hormone in childhood, leading to abnormal increase in height and size. ([Chapter 17.4](#), [Chapter 17.6](#))

Glucagon (GLŪ-kă-gŏn): A hormone produced by the pancreas that raises blood glucose levels by stimulating the liver to release stored glucose. ([Chapter 17.4](#))

Glucose (GLŪ-kōs): A simple sugar that is an important energy source in living organisms and a component of many carbohydrates. ([Chapter 17.4](#))

Goiter (GOI-těr): An enlargement of the thyroid gland, which can be a symptom of both hypothyroidism and hyperthyroidism or result from iodine deficiency. ([Chapter 17.4](#), [Chapter 17.6](#))

Grave's disease (GRĀVZ dī-ZĒZ): An autoimmune disorder that is the most common cause of hyperthyroidism, where the immune system attacks the thyroid gland causing it to produce too much thyroid hormone. ([Chapter 17.6](#))

Hemoglobin A1C (HĒ-mō-glō-bĭn Ā-wŭn-SĒ) (HbA1C): A blood test that indicates the average level of blood sugar over the past two to three months, used to diagnose and manage diabetes. ([Chapter 17.6](#))

Hirsutism (HĪR-sū-tīz-əm): The excessive growth of dark or coarse hair in a male-like pattern in women, often due to increased androgen levels. ([Chapter 17.6](#))

Hormones (HÖR-mōnz): Chemical messengers secreted by endocrine glands, traveling through the bloodstream to target organs to initiate specific physiological responses. ([Chapter 17.4](#))

Human growth hormone (HYOO-măn GRÖTH HÖR-mōn) (HGH): A hormone produced by the anterior pituitary gland, crucial for growth and metabolic processes in the body. ([Chapter 17.4](#))

Hypercalcemia (hī-pěr-kāl-SĒ-mē-ă): A condition characterized by an abnormally high level of calcium in the blood. ([Chapter 17.6](#))

Hyperglycemia (hī-pěr-glī-SĒ-mē-ă): A condition characterized by an abnormally high level of glucose in the blood, often associated with diabetes. ([Chapter 17.4](#), [Chapter 17.6](#))

Hyperparathyroidism (hī-pěr-PĀR-ă-THĪ-rōid-izm): A condition in which the parathyroid glands produce too much parathyroid hormone, leading to high levels of calcium in the blood (hypercalcemia). ([Chapter 17.6](#))

Hyperthyroidism (hī-pěr-THĪ-rōid-izm): A condition characterized by excessive production of thyroid hormones by the thyroid gland, leading to symptoms like weight loss, increased heart rate, and anxiety. ([Chapter 17.6](#))

Hypocalcemia (hī-pō-kāl-SĒ-mē-ă): Low levels of calcium in the blood, which can be a symptom of hypoparathyroidism. ([Chapter 17.6](#))

Hypoglycemia (hī-pō-glī-SĒ-mē-ă): Low blood sugar levels, which can be a side effect of diabetes treatment. ([Chapter 17.4](#), [Chapter 17.6](#))

Hypoparathyroidism (hī-pō-pār-ă-THĪ-rōid-izm): A condition in which the parathyroid glands produce insufficient parathyroid hormone, leading to low levels of calcium in the blood (hypocalcemia). ([Chapter 17.6](#))

Hypophysectomy (hī-pō-fī-SĚK-tō-mē): Surgical removal of the pituitary gland. ([Chapter 17.7](#))

Hypopituitarism (hī-pō-pī-TŪ-īt-ă-rizm): A condition where the pituitary gland produces insufficient amounts of one or more of its hormones, leading to a variety of symptoms depending on which hormones are affected. ([Chapter 17.4](#))

Hypotension (hī-pō-TĚN-shŭn): Abnormally low blood pressure. ([Chapter 17.6](#))

Hypothyroidism (hī-pō-THĪ-rōid-izm): A condition in which the thyroid

gland doesn't produce enough thyroid hormones, leading to symptoms like fatigue, weight gain, and cold intolerance. ([Chapter 17.4](#), [Chapter 17.6](#))

Insulin (ĪN-sū-lĭn): A hormone produced by the pancreas that regulates blood glucose levels by facilitating the uptake of glucose into cells. ([Chapter 17.4](#))

Luteinizing hormone (LŪ-tē-ĭ-nĭz-ing HŌR-mōn) (LH): A hormone produced by the pituitary gland, involved in triggering ovulation in females and testosterone production in males. ([Chapter 17.4](#))

Melatonin (MĔL-ă-tō-nĭn): A hormone produced by the pineal gland, affecting reproductive development and daily physiological cycles, including sleep patterns. ([Chapter 17.4](#))

Norepinephrine (nôr-ĕp-ĭ-NĔF-rĭn): A hormone produced by the adrenal medulla, involved in the body's response to stress and also acts as a neurotransmitter. ([Chapter 17.4](#))

Oral glucose tolerance test (ŌR-ăL GLŪ-kōs TŌL-ĕr-ăns tĕst) (OGTT): A test where a person consumes a glucose-rich beverage, and their blood sugar levels are tested over several hours to assess glucose metabolism. ([Chapter 17.6](#))

Oxytocin (ŏk-sē-TŌ-sĭn): A hormone produced by the pituitary gland, involved in childbirth, lactation, and social bonding. ([Chapter 17.4](#))

Pancreas (PĀN-krē-ăs): An organ with both exocrine and endocrine functions, producing digestive enzymes and hormones like insulin and glucagon. ([Chapter 17.4](#))

Pancreatectomy (păn-krē-ă-TĔK-tŏ-mē): Surgical removal of the pancreas. ([Chapter 17.7](#))

Parathyroid glands (PĀR-ă-THĪ-rŏid glandz): Small glands located on the thyroid gland that produce parathyroid hormone, which regulates calcium levels in the blood. ([Chapter 17.4](#))

Parathyroid hormone (PĀR-ă-THĪ-rŏid HŌR-mōn) (PTH): A hormone produced by the parathyroid glands that regulates calcium and phosphate balance in the blood and bone metabolism. ([Chapter 17.4](#))

Parathyroidectomy (păr-ă-thī-royd-ĔK-tŏ-mē): A surgical procedure to remove one or more of the parathyroid glands. ([Chapter 17.6](#), [Chapter 17.7](#))

Pineal gland (PĪ-nē-ăL gland): A small cone-shaped structure in the brain

that produces melatonin, influencing reproductive development and physiological cycles. ([Chapter 17.4](#))

Pituitary gland (pĭ-TŪ-ĭ-tĕr-ē gland): A pea-sized gland at the base of the brain, producing various hormones including GH, TSH, ACTH, FSH, LH, endorphins, and prolactin, influencing numerous bodily functions. ([Chapter 17.4](#))

Polycystic ovary syndrome (pŏl-ē-SĪS-tĭk Ō-vār-ē SĪN-drŏm) (PCOS): A hormonal disorder common among women of reproductive age characterized by prolonged or infrequent menstrual periods, excess androgen levels, and polycystic ovaries. ([Chapter 17.6](#))

Polydipsia (pŏl-ē-DĪP-sē-ă): Excessive thirst, often a symptom of diabetes. ([Chapter 17.6](#))

Polyphagia (pŏl-ē-FĀ-jē-ă): Excessive hunger or increased appetite, often a symptom of diabetes. ([Chapter 17.6](#))

Polyuria (pŏl-ē-YŌŌR-ē-ă): Excessive or an abnormally large production or passage of urine, frequently seen in diabetes. ([Chapter 17.6](#))

Progesterone (prŏ-JĔS-tĕ-rŏn): A hormone released by the ovaries that regulates the condition of the endometrium, which is important for maintaining pregnancy. ([Chapter 17.4](#))

Prolactin (prŏ-LĀK-tĭn): A hormone produced by the pituitary gland, primarily involved in milk production in breastfeeding mothers. ([Chapter 17.4](#))

Radioactive iodine uptake (rā-dē-ō-ĀK-tĭv Ī-ŏ-dĭn ŬP-tāk): A diagnostic test that measures how much radioactive iodine is absorbed by the thyroid gland, used to evaluate thyroid function. ([Chapter 17.7](#))

Random blood glucose (răn-dŏm blŭd GLŪ-kŏs): A test measuring the sugar levels in the blood at any given time, regardless of when the last meal was consumed, utilized to monitor and manage blood sugar levels in individuals with diabetes. ([Chapter 17.6](#))

Striae (STRĪ-ē): Streaks or lines on the skin, typically caused by rapid stretching and hormone changes, as seen in Cushing's syndrome. ([Chapter 17.6](#))

Syndrome (SĪN-drŏm): A set of medical signs and symptoms that are correlated with each other and, often, with a specific disease. ([Chapter 17.6](#))

Testosterone (tĕs-TŌS-tĕ-rŏn): The primary male sex hormone responsible

for the development of male reproductive tissues and secondary sexual characteristics. ([Chapter 17.4](#))

Thyroid gland (THĪ-rōid gland): An endocrine gland in the neck producing hormones like thyroxine and triiodothyronine, crucial for regulating metabolism and other body functions. ([Chapter 17.4](#))

Thyroid-stimulating hormone (THĪ-rōid-STĪM-yū-lāt-ing HŌR-mōn) (TSH): A hormone produced by the pituitary gland that stimulates the thyroid gland to produce thyroid hormones. ([Chapter 17.4](#))

Thyroidectomy (thī-rōi-DĚK-tō-mē): Surgical removal of all or part of the thyroid gland. ([Chapter 17.6](#), [Chapter 17.7](#))

Thyroiditis (thī-royd-ĪT-īs): Inflammation of the thyroid gland, which can cause either high or low levels of thyroid hormones. ([Chapter 17.6](#))

Thyroxine (thī-RŌK-sĭn) (T4): A hormone produced by the thyroid gland, involved in regulating metabolism, heart rate, and growth and development in children. ([Chapter 17.4](#))

Triiodothyronine (trī-ī-ō-dō-THĪ-rō-nēn) (T3): A hormone produced by the thyroid gland, playing a vital role in metabolism, heart rate, and body temperature regulation. ([Chapter 17.4](#))

Type 1 diabetes (tīp wŭn dī-ă-BĒ-tēz): An autoimmune condition where the body's immune system attacks and destroys the insulin-producing beta cells in the pancreas, resulting in a lack of insulin and the need for life-long insulin therapy. ([Chapter 17.6](#))

Type 2 diabetes (tīp tōō dī-ă-BĒ-tēz): A chronic condition characterized by insulin resistance, where body cells do not respond effectively to insulin, often combined with a deficiency in insulin production, leading to high blood sugar levels. ([Chapter 17.6](#))

Appendix: Instructor Resource - How to Remix H5P Activities For Your Courses

How to Remix H5P Activities For Your Courses

- In the H5P activity that you would like to remix, press the “Reuse” button located in the bottom left corner of the activity.
- Select the option to “Download as an .h5p file” and to save the content to your device.
- Log in to your H5P account.
 - *Helpful hints: If your institution does not have an H5P subscription, a free basic version of H5P is available at h5p.org. It is helpful to create a folder within your H5P account for remixing content so that your activities are easily accessible.*
- Click on “Content,” then click on “Create New Content,” then click on “Upload.” Select the H5P file that you downloaded to your device, then click on “Use” to upload the activity into your personal H5P account.
- Remix the content according to your preferences. For example, for flashcard activities provided in the book, you can delete or add flashcards. See the demonstration video below. (However, if you use the free, basic version of H5P, the audio pronunciations on the flashcards will not transfer.)
- Click “Save” to save the activity in your H5P account.
- The URL to this remixed activity in your personal H5P account can be added to your course in your learning management system for students to access.



One or more interactive elements has been excluded from this version of the text. You can view them online here: <https://wtcs.pressbooks.pub/medterm/?p=9387#video-9387-1>